

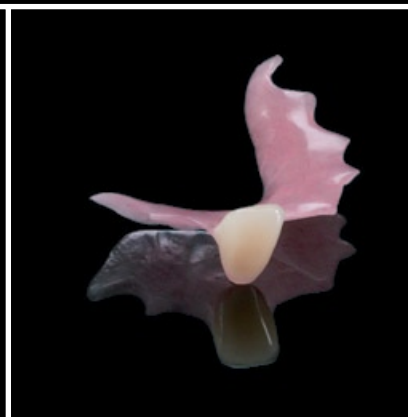

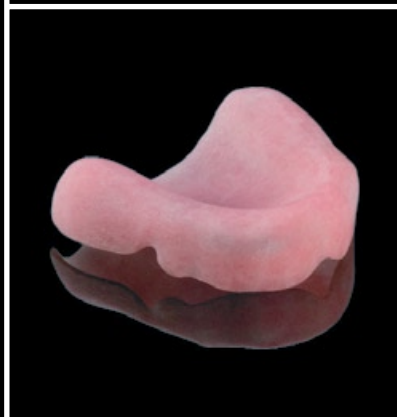## University of British Columbia Launches Graduate Endodontics Program

Drs. Jeff Coil, Ya Shen  
and Markus Haapasalo

Essential reading for Canadian dentists

# ENTERRA™

## VLC Curing Unit



Enterra™  
VLC Curing Unit

### Discover a new dimension in Light Curing applications.

The Enterra VLC Curing Unit offers a simple and efficient solution for fabricating nightguards, flippers, baseplates, provisionals and much more.

**Compact, portable and affordable, the Enterra VLC Curing Unit cures a variety of materials:**

- **Eclipse:** Nightguards, provisional partials.
- **Triad:** Baseplates, custom trays, etc.
- **Radica:** Provisional & Diagnostic Resin.
- **Cristobal+:** Indirect Composite System.

For better dentistry

**DENTSPLY**  
CANADA

For more information on the advantages the Enterra VLC Curing unit can bring to your practice or to schedule an in-office demonstration, please contact your local DENTSPLY Territory Manager at 1.800.263.1437.



Publisher  
**Canadian Dental Association**

Editor-In-Chief  
**Dr. John P. O'Keefe**

Writer/Editor  
**Sean McNamara**

Assistant Editor  
**Natalie Blais**

Coordinator, French  
Translation  
**Vacant**

Coordinator, Publications  
**Rachel Galipeau**

Writer, Electronic Media  
**Emilie Adams**

Manager, Design & Production  
**Barry Sabourin**

Graphic Designer  
**Janet Cadeau-Simpson**

All statements of opinion and supposed fact are published on the authority of the author who submits them and do not necessarily express the views of the Canadian Dental Association. The editor reserves the right to edit all copy submitted to the *JCDA*. Publication of an advertisement does not necessarily imply that the Canadian Dental Association agrees with or supports the claims therein.

**Call CDA for information and assistance** toll-free (Canada) at: 1-800-267-6354; outside Canada: (613) 523-1770

CDA fax: (613) 523-7736

CDA email: reception@cda-adc.ca

Website: www.cda-adc.ca

© Canadian Dental Association 2008

## Mission Statement

The Canadian Dental Association is the national voice for dentistry, dedicated to the advancement and leadership of a unified profession and to the promotion of optimal oral health, an essential component of general health.

### ASSOCIATE EDITORS

Dr. Michael J. Casas  
Dr. Anne Charbonneau  
Dr. Ian R. Matthew  
Dr. Mary E. McNally

### EDITORIAL CONSULTANTS

Dr. James L. Armstrong	Dr. Robert J. Hawkins	Dr. Kathy Russell
Dr. Manal Awad	Dr. Asbjørn Jokstad	Dr. George K.B. Sándor
Dr. Catalena Birek	Dr. Richard Komorowski	Dr. Benoit Soucy
Dr. Gary A. Clark	Dr. Ernest W. Lam	Dr. Susan Sutherland
Dr. Jeff Coil	Dr. Gilles Lavigne	Dr. David J. Sweet
Dr. Pierre C. Desautels	Dr. James L. Leake	Dr. Gordon W. Thompson
Dr. Terry Donovan	Dr. William H. Liebenberg	Dr. David W. Tyler
Dr. Robert V. Elia	Dr. Kevin E. Lung	Dr. Margaret Webb
Dr. Joel B. Epstein	Dr. Debora C. Matthews	Dr. J. Jeff Williams
Dr. Ian M. Furst	Dr. David S. Precious	Dr. James R. Yacyshyn
Dr. Daniel Haas	Dr. Richard B. Price	
Dr. Felicity Hardwick	Dr. N. Dorin Ruse	

### CDA BOARD OF DIRECTORS

President <b>Dr. Deborah Stymiest</b>	<b>Dr. Michael Brown</b>	<b>Dr. Robert MacGregor</b>
President-Elect <b>Dr. Don Friedlander</b>	<b>Dr. Peter Doig</b>	<b>Dr. Jack Scott</b>
Vice-President <b>Dr. Ronald G. Smith</b>	<b>Dr. Steve Goren</b>	<b>Dr. Lloyd Skuba</b>
	<b>Dr. Colin Jack</b>	<b>Dr. Robert Sutherland</b>
	<b>Dr. Gordon Johnson</b>	<b>Dr. Grahame Usher</b>
	<b>Dr. Gary MacDonald</b>	<b>Dr. David Zaporinuk</b>

Cover photo: Courtesy of Bruce McCaughey

The *Journal of the Canadian Dental Association* is published in both official languages — except scientific articles, which are published in the language in which they are received. Readers may request *JCDA* in the language of their choice.

The *Journal of the Canadian Dental Association* is published 10 times per year (July/August and December/January combined) by the Canadian Dental Association. Copyright 1982 by the Canadian Dental Association. Publications Mail Agreement No. 40064661. PAP Registration No. 09961. Return undeliverable Canadian addresses to: Canadian Dental

Association at 1815 Alta Vista Drive, Ottawa, ON K1G 3Y6. Postage paid at Ottawa, Ont. Subscriptions are for 10 issues, conforming with the calendar year. All 2008 subscriptions are payable in advance in Canadian funds. In Canada — \$98 (\$92.45 + GST, #R106845209); United States — \$135; all other — \$225. Notice of change of address should be received before the 10th of the month to become effective the following month. Member: American Association of Dental Editors and Canadian Circulations Audit Board.

ISSN 0709 8936 Printed in Canada

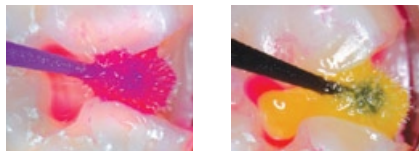
# It will change the way you look at Self-Etch



## Introducing a self-etch adhesive created with vision to inspire new confidence.

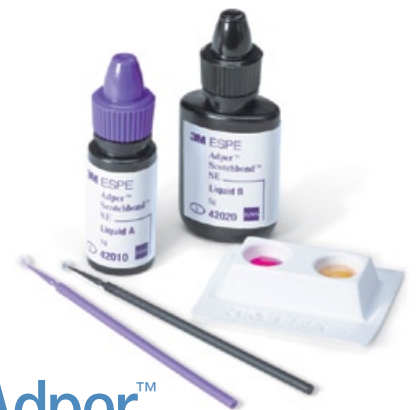You told 3M ESPE the things that interest you – and concern you – about using a self-etch adhesive. And we came back with just what you'd expect: 3M™ ESPE™ Adper™ Scotchbond™ SE Self-Etch Adhesive.

- **Colour change indicator:** Lets you see adhesive placement, coverage and etch activation.
- **Radiopacity:** Reduces the risk of misdiagnosing secondary caries.
- **High bond strength:** Backed by more than 25 years of adhesive experience.



Photos: Courtesy of Dr. Jorge Perdigao, University of Minnesota.

For greater confidence, try the adhesive that's visibly better... from 3M ESPE.

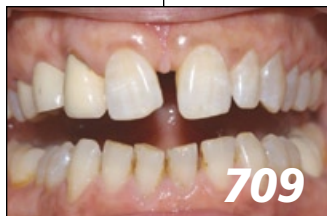
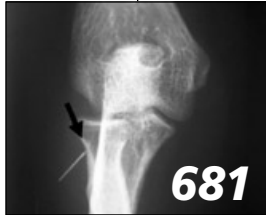
Adper™  
Scotchbond™ SE  
Self-Etch Adhesive

Call 1-888-363-3685 or visit [www.3MESPE.com/CA](http://www.3MESPE.com/CA)

**3M** ESPE

## COLUMNS & DEPARTMENTS



<b>Guest Editorial</b> .....	<b>677</b>
Seniors' Oral Health Unites the Profession	
<b>President's Column</b> .....	<b>679</b>
Seniors Deserve Optimal Care	
<b>Letters</b> .....	<b>681</b>
<b>News &amp; Updates</b> .....	<b>685</b>
<b>You Ask, We Answer</b> .....	<b>699</b>
Resources for the Dental Office	
<b>CDSPI Reports</b> .....	<b>703</b>
Customized Portfolio Offers a Wealth of Advantages	
<b>Cochrane Review Abstracts</b> .....	<b>705</b>
Interventions for replacing missing teeth: bone augmentation techniques for dental implant treatment	
Interventions for replacing missing teeth: antibiotics at dental implant placement to prevent complications	
<b>Clinical Showcase</b> .....	<b>709</b>
Use of Porcelain Veneers, Crowns and an Implant to Resolve an Esthetic Problem	
<b>Classified Ads</b> .....	<b>741</b>
<b>Advertisers' Index</b> .....	<b>748</b>
<b>New Products</b> .....	<b>749</b>

**Oral-B**  
**CROSSACTION**<sup>®</sup>  
**PRO-HEALTH**<sup>™</sup>

ADVANCED PROTECTION  
FROM EVERY ANGLE

**7 oral care benefits**  
**in 1 premium brush**  
**for a cleaner<sup>1</sup> mouth**

<sup>1</sup>vs. a regular manual brush

©2008 P&G 7363JUL15E
P&G Professional Oral Health

Please see our advertisement opposite the Editorial page.

SUNSTAR



# A Complete Line of Adult Toothbrushes to Meet Your Every Patient's Needs!

**NEW**



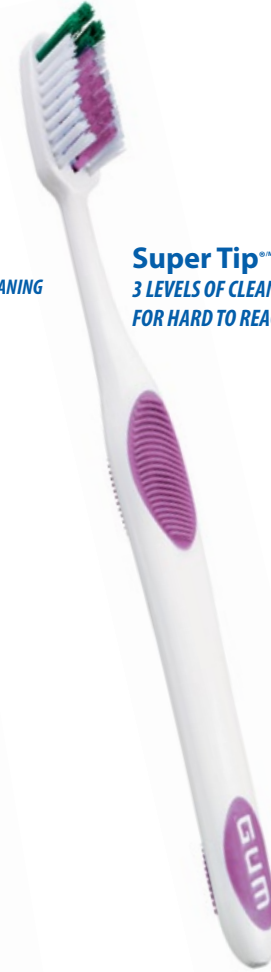**Activital™**  
NEW TRIAD BRISTLE  
TECHNOLOGY DESIGNED  
TO HELP PREVENT  
GINGIVITIS



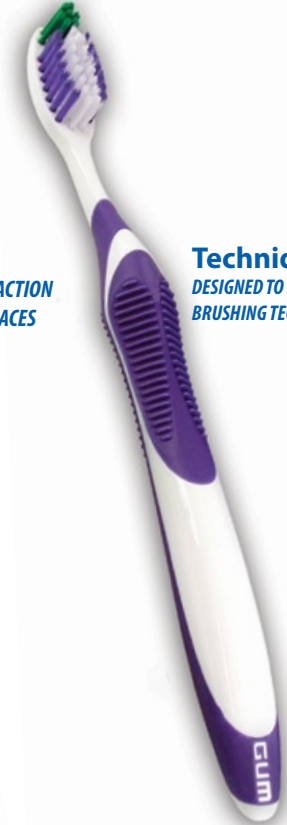**Technique™+**  
DESIGNED FOR ADVANCED  
BRUSHING TECHNIQUE



**Micro Tip™**  
FOR DEEP AND GENTLE CLEANING



**Super Tip™**  
3 LEVELS OF CLEANING ACTION  
FOR HARD TO REACH PLACES



**Technique™**  
DESIGNED TO IMPROVE  
BRUSHING TECHNIQUE

For more information or to place an order call **1 800 265-8353** or speak with your Sunstar Representative

Visit us at [www.GUMbrand.com](http://www.GUMbrand.com)

# SUNSTAR

**PROFESSIONAL ISSUES**

**The Role of the Dentist in Recognizing Elder Abuse** ..... 715

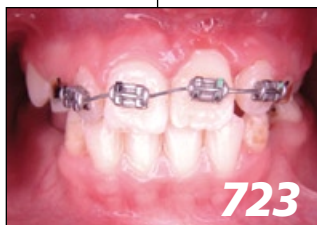*Michael Wiseman*

**APPLIED RESEARCH**

**Efficacy of 3 Techniques in Removing Root Canal Filling Material** ..... 721

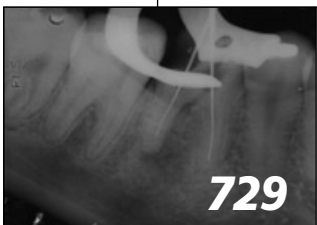*Emre Bodrumlu, Özgür Uzun, Özgür Topuz, Mustafa Semiz*

**CLINICAL PRACTICE**



**Unusual Ectopic Eruption of a Permanent Central Incisor Following an Intrusion Injury to the Primary Tooth** ..... 723

*Ebru Canoglu, Cenk Ahmet Akcan, Erdiñç Baharoglu, H. Cem Gungor, Zafer C. Cehreli*



**Repair of Furcal Perforation with Mineral Trioxide Aggregate: Long-Term Follow-Up of 2 Cases** ..... 729

*Camila M.M. Silveira, Alfonso Sánchez-Ayala, Manuel O. Lagravère, Gibson L. Pilatti, Osnara M.M. Gomes*

**Oral Submucous Fibrosis, a Clinically Benign but Potentially Malignant Disease: Report of 3 Cases and Review of the Literature** ..... 735

*Ajit Auluck, Miriam P. Rosin, Lewei Zhang, Sumanth KN*



CANADIAN  
DENTAL  
ASSOCIATION

"We acknowledge the financial support of the Government of Canada through the Publications Assistance Program towards our mailing costs."  
**Canada**

All matters pertaining to **JCDA** should be directed to: Editor-in-chief,  
*Journal of the Canadian Dental Association*,  
1815 Alta Vista Drive, Ottawa, ON K1G 3Y6  
• Email: rgalipeau@cda-adc.ca  
• Toll-free: 1-800-267-6354  
• Tel.: (613) 523-1770  
• Fax: (613) 523-7736

All matters pertaining to **classified advertising** should be directed to: Mr. John Reid,  
c/o Keith Communications Inc.,  
104-1599 Hurontario St.,  
Mississauga, ON L5G 4S1  
• Toll-free: 1-800-661-5004, ext. 23  
• Tel.: (905) 278-6700  
• Fax: (905) 278-4850

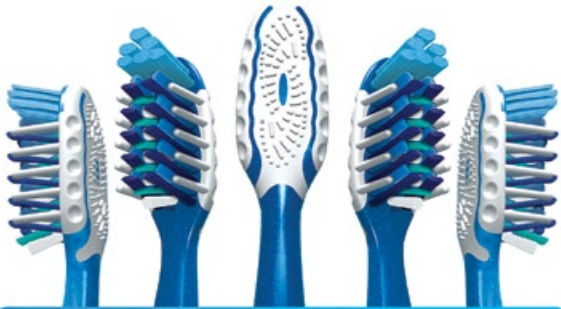All matters pertaining to **display advertising** should be directed to: Mr. Peter Greenhough,  
c/o Keith Communications Inc.,  
104-1599 Hurontario St.,  
Mississauga, ON L5G 4S1  
• Toll-free: 1-800-661-5004, ext. 18  
• Tel.: (905) 278-6700  
• Fax: (905) 278-4850

Publication of an advertisement does not necessarily imply that the Canadian Dental Association agrees with or supports the claims therein. Furthermore, CDA is not responsible for typographical errors, grammatical errors, misspelled words or syntax that is unclear, or for errors in translations.

# INTRODUCING

**Oral-B**  
**CrossAction®**  
**PRO-HEALTH™**

With new tongue cleaner to  
remove odour-causing germs



**ADVANCED PROTECTION  
FROM EVERY ANGLE**

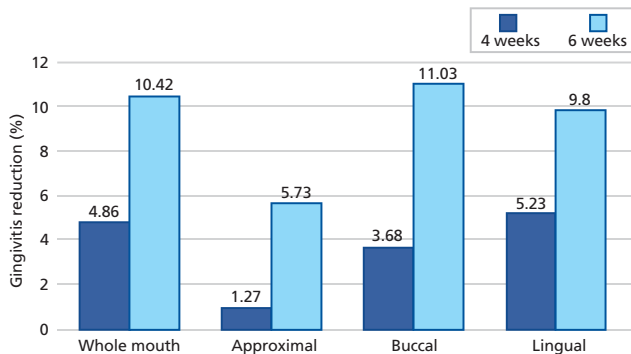
**7 oral care benefits  
in 1 premium brush  
for a cleaner<sup>†</sup> mouth**

<b>REMOVES PLAQUE</b>	Up to <b>90%</b> of plaque in hard-to-reach places <sup>1</sup>
<b>HELPS REDUCE GINGIVITIS</b>	Proven to significantly reduce gingivitis after 4 and 6 weeks of use <sup>2</sup>
<b>CLEANS ALONG THE GUMLINE</b>	With unique CrissCross® bristles <sup>2</sup>
<b>POLISHES AWAY SURFACE STAINS</b>	With varying bristle textures <sup>2</sup>
<b>STIMULATES GUMS</b>	With outer gingival stimulators <sup>2</sup>
<b>REMOVES ODOUR-CAUSING GERMS</b>	With <b>NEW</b> tongue cleaner <sup>2</sup>
<b>GENTLE ON ENAMEL</b>	With soft, end-rounded bristles <sup>2</sup>

**NEW** Oral-B CrossAction PRO-HEALTH leverages the advanced brush head design and bristle configuration of Oral-B® CrossAction® Vitalizer®

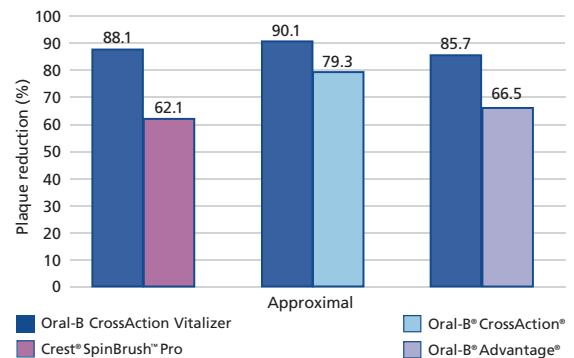
## PROMOTES HEALTHY GUMS BY REDUCING GINGIVITIS<sup>2</sup>

In a clinical trial, the Oral-B CrossAction Vitalizer brush head design demonstrated significant reductions in gingivitis after 4 and 6 weeks of product use<sup>2</sup>



## REMOVES HARD-TO-REACH PLAQUE<sup>3,4</sup>

Clinical research showed that the Oral-B CrossAction Vitalizer brush head provides significantly better approximal plaque removal than three other toothbrushes<sup>3,4</sup>



<sup>†</sup>vs. a regular manual brush.

References: 1. Data on file, P&G; based on one-time brushing studies. 2. Data on file, P&G.  
3. Sharma NC, et al., Am J Dent 2005;18:3-7 4. Sharma NC, et al., J Dent Res 2003;82: Abstr.1392





Dr. Susan Sutherland

## Seniors' Oral Health Unites the Profession

An overarching theme that unifies the efforts of all Canadian dental professionals and their supporting organizations is the promotion of optimal oral health as a critical component of overall health for Canadians of all ages. Providing high-quality oral health care to our aging population, particularly the frail, medically complex and dependent elderly, is presenting an increasing challenge.

Seniors comprise the fastest growing segment of our society. As a result of successful preventive measures and excellent dental care enjoyed by many Canadians, seniors are retaining their natural teeth for much longer than ever before. The elderly no longer accept losing teeth as an inevitable consequence of aging. However, with physical decline and increasing frailty, the maintenance of good oral health is considerably more challenging both for the individual and for their dentist.

Many seniors face a number of obstacles in accessing dental care, including financial barriers for those on limited income with no dental insurance or other third-party funding; geographic barriers for the homebound, especially in rural areas; and physical barriers in some dental offices. The greatest challenge for the dental profession lies in providing adequate care for the most vulnerable seniors, those whose physical and cognitive impairments render them dependent on caregivers for routine activities of daily living, including oral hygiene. For the institutionalized elderly, a lack of public policy and guidelines related to standards for the provision of oral health care, inadequate training and supervision of personal support workers and other long-term care staff, lack of proper facilities and remuneration for oral health care providers, and a shortage of providers with the expertise to offer care in these settings all contribute to the problem.

In 2005, CDA and its provincial partners came together for a national forum on seniors'

oral health care to identify the issues related to the complexities of seniors' oral health. Participants recognized the need for a national approach to adequately address the substantial barriers and profound disparities that comprise the problem. Building on the shared vision from this forum, the CDA Board of Directors tasked its Committee on Clinical and Scientific Affairs (CCSA) to follow up on the ideas generated at the summit. A task force was created, chaired by CCSA member Dr. Chris Wyatt and composed of members whose extensive academic and clinical backgrounds contributed both scientific rigour and practical clinical experience to the process.

The CCSA recently presented its *Report on Seniors' Oral Health Care* to CDA's Board of Directors. The report is both comprehensive and ambitious, requiring a strong commitment on many fronts, locally and nationally, to implement its recommendations. It highlights some of the innovative projects for seniors currently in place and the remarkable successes achieved to date across the country. One of the key roles CDA can play is to act as a repository for these projects and local accomplishments, making them known and available to others across the country. As stated in the report, there is a need to "harness the collective creative capacity and generate the synergies to move the seniors' oral health care agenda forward in a meaningful way."

As we plan for the future, it is important that CDA, along with its provincial partners, continues to examine issues of national importance that affect all dentists and transcend local or provincial mandates. For instance, the next major issue on CCSA's agenda is early childhood caries. This is another area where the clinical and academic expertise of our members from across the country can be brought together to create a unified and comprehensive national strategy with concrete recommendations.

The promotion of a culture of collaborative working relationships among CDA and the provincial members will enable the dental profession to address the important issues facing oral health today. A united dental profession working together has the ability to develop strong national platforms that can be adapted for local circumstances. In this way we can more effectively achieve our shared vision for the optimal oral health of Canadians.

*Susan Sutherland, DDS, MSc  
Chief of dentistry, Sunnybrook Health Sciences Centre  
Chair, CDA Committee on Clinical and Scientific Affairs*

“As we plan for the future, it is important that we continue to examine issues of national importance that affect all dentists and transcend local or provincial mandates.”

# Healthy smile or hidden damage?

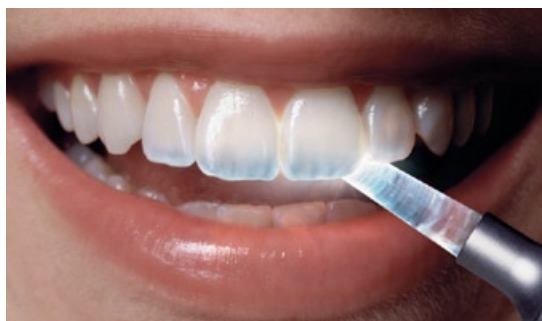
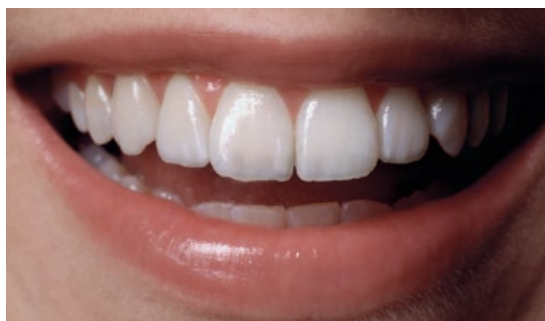
Illustration of increased translucency, a sign of acid wear

## NEW ProNamel™ is specially formulated to help protect against the effects of Acid Erosion and Sensitivity.<sup>1</sup>

- Helps protect against effects of dietary acids
- Microhardening effect
- Low abrasivity
- Contains potassium nitrate to help prevent the pain of sensitive teeth
- Contains detergent – cocamidopropyl betaine
- SLS free
- pH range of 6.7-7.5
- Two great flavours: Mint Essence and Fresh Wave
- Has the benefits of a regular toothpaste including fresh breath, caries protection, and plaque removal (with brushing)
- Recognized by the CDA for the prevention of caries and tooth hypersensitivity

When you identify the signs of acid erosion, such as a slight twinge, complement your regular chairside care by recommending ProNamel™ from Sensodyne®.



Sensodyne® ProNamel™ (with potassium nitrate 5% w/w and 0.254% w/w sodium fluoride) is recommended for sensitive teeth and cavity prevention. Helps protect teeth from acid wear/erosion in adults and children over 12 years. Brushing twice daily builds and maintains protective barrier, to help prevent pain from returning.



The first toothpaste to earn the CDA Seal for reducing tooth hypersensitivity.

Reference: 1. Sensodyne ProNamel product packaging.

**Sensodyne®**  
A tradition of leadership and innovation

# PDF supplied for AAs. See Originals folder

recently visited a long-term care facility to see an 87-year-old female resident with Alzheimer's disease who required my care as a dentist. The staff and family were concerned

*Deborah Stymiest, BSc, DDS  
president@cda-adc.ca*

# Protect Your Office Three Ways — With Three New Ways to Save

Why do thousands of dentists protect their practices with **TripleGuard™ Insurance**? Because it provides three types of superior office coverage (office contents, practice interruption and commercial general liability) in one economical package. And offers valuable options to enhance your office protection — including Building Insurance. You'll also benefit from expert advice and service when customizing your coverage — from licensed advisors who understand dentists best.

And now, dentists can save on TripleGuard™ Insurance — thanks to new premium reductions of 5, 10 or 15 per cent when insuring multiple locations or with the purchase of Building Insurance. For details, speak to an insurance planning advisor at CDSPI Advisory Services Inc.

**1-877-293-9455 Ext. 5002**

**[www.cdspi.com/tripleguard-insurance](http://www.cdspi.com/tripleguard-insurance)**

*TripleGuard™ Insurance is underwritten by Aviva Insurance Company of Canada. The plan is a part of the Canadian Dentists' Insurance Program — a member benefit of the CDA and co-sponsoring provincial dental associations.*

**CDSPI**

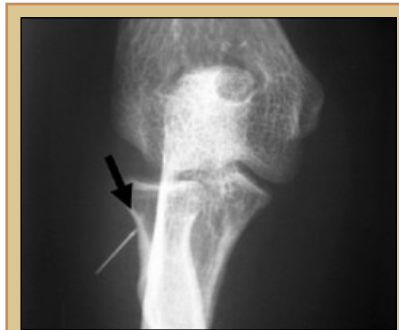D E N T I S T S F I R S T

# Accident with a Gates Glidden Drill

A dental student was trying to remove gutta-percha with a Gates Glidden drill from a root canal while performing endodontic retreatment. The Gates Glidden drill was not removed from the low-speed handpiece when it was put on the handpiece stand, which was at the same height as the elbow of the dental student. While the student was carrying out the treatment, she abruptly moved her right hand and felt a mild pain in her right elbow afterwards. A 32-mm piece of stainless steel #2 Gates Glidden drill was separated and only the handpiece drill end remained in the handpiece unit itself. A small, penetrating wound on her arm could be observed. It was suspected that the separated segment was in the student's elbow.

The student visited a nearby hospital and radiographs of the elbow revealed that the separated piece of the Gates Glidden drill was retained inside the forearm near the elbow joint capsule (Fig. 1). The drill segment was removed by a traumatology surgeon under local anesthesia. The surgeon explained that the drill fragment could have torn the cubital nerve. Tetanus toxoid (0.5 mL) was administered intramuscularly to the student and the enzyme-linked immunosorbent assay (ELISA) test was performed to determine possible HIV infection. The results of the ELISA test were negative. A screening test for hepatitis B was not performed on the student due to recent hepatitis B antibody screening evidence.

Different types of accidents can occur during endodontic treatment, mainly during cleaning and shaping procedures. However, to the best of our knowledge, the penetration of a segment of a Gates Glidden drill into the operator's elbow is quite un-



**Figure 1:** Radiograph of the right elbow showing a separated Gates Glidden drill (arrow) near the joint capsule.

common and has only been reported twice.<sup>1</sup> These types of accidents occur because the operator neglects to remove the Gates Glidden drill from the handpiece. Any instrument used in a root canal can be a source of cross-infection. Thus, simple yet important precautions should be undertaken while using sharp instruments like Gates Glidden drills or endodontic files. This case report is a reminder to dental students and operators of the importance of routinely removing drills or burs from the handpiece immediately after use. This procedure takes only a few seconds and can prevent this type of accident from occurring.

*Dr. Hair Salas-Beltrán  
Department of endodontics  
Catholic Santa Maria University  
Dr. Rosa Nieto-Delgado  
Arequipa, Peru*

## Reference

1. Yang SF, Pai SF. An accident with a Gates Glidden drill in endodontic practice. *J Endod* 2000; 26(1):49-50.

## Riga-Fede Disease

I would like to report a case of Riga-Fede disease in a 33-day-old baby who was referred to our institution for evaluation of an ulcerated area on the ventral surface of the tongue.

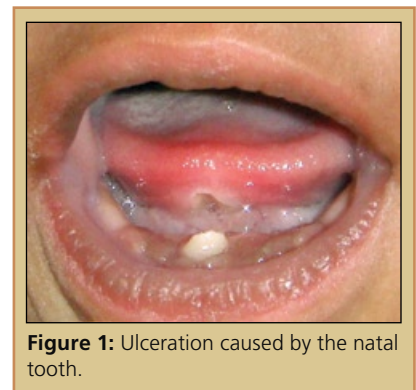
The mother stated that the child had difficulty suckling and related it a tooth that was present since birth. She had also noticed an ulcer on the ventral surface of the baby's tongue 3 days before.

Oral examination revealed one crown in the mandibular anterior region in central incisor position, whitish in colour and exhibiting grade 2 mobility. The ventral surface of the tongue showed a 6 mm × 10 mm ulceration that extended from the anterior border of the tongue to the lingual frenum (Fig. 1). On palpation the ulcerated area was mildly indurated and elicited tenderness. Based on the history and clinical findings, diagnosis of Riga-Fede disease was made.

Considering the hindrance to feeding and tooth mobility, extraction was the suggested treatment. The tooth was removed uneventfully under topical anesthesia. Follow-up after 4 days revealed complete healing of the ulcer and the tooth socket.

Riga-Fede disease may occur in older infants and is associated with eruption of primary lower incisors. It is also seen in children with repetitive tongue-thrusting habits and in children with cerebral palsy, Down's syndrome, familial dysautonomia (Riley-Day syndrome), Gaucher's disease and Lesch-Nyhan syndrome.

Traumatic ulceration of the ventral tongue in infants is most often associated with natal or neonatal



**Figure 1:** Ulceration caused by the natal tooth.

teeth. Constant trauma to the tongue caused by the sharp incisal edge of a natal tooth during suckling results in ulceration on the ventral surface of the tongue.

In the case of mild to moderate irritation to the tongue, conservative treatments such as smoothing the incisal edge or placing a small increment of composite over the incisal edge of the tooth are advised. When the ulceration is large and interferes with feeding, removal of the tooth can be beneficial, as in our case. However, the clinician should be aware of the potential complication of hemorrhage in neonates and precautions like administering vitamin K should be considered if the infant is less than 10 days old.

As Riga-Fede disease can create painful lesions that interfere with proper suckling and feeding, it is important to diagnose the condition early and treat it by eliminating the cause of trauma. Often parental opinion and clinical acumen will enable the clinician to diagnose and treat the condition effectively and prevent untoward complications.

*Dr. Philips Mathew  
Rajah Muthiah Dental College and Hospital  
India*

### **Working Together, the Key to a Successful Oral Health Month in Moncton**

In the Greater Moncton area this year, promoting oral health during dental health month was a community effort born of the collaboration of numerous associations and volunteers. I would like to share our enriching experience with you.

Every year, the Greater Moncton Dental Association attempts to strike a committee responsible for promoting oral health in April. Creating such a committee was a real challenge last year, however. I volunteered to be the organizer, but the job was bigger than I had imagined, and I had only my invaluable staff to help me. We did the best

we could to accomplish our mission. The media were very supportive, and several of our specialists drafted newspaper articles. Several dental clinics opened their doors to elementary schools. All these efforts were appreciated, and contributed to our success.

Following the activities of dental health month 2007, I explained to association members the obstacles involved in creating a committee without greater participation. I proposed as a solution that we solicit the aid of other local associations involved in dental care. To my surprise, the idea was unanimously accepted and I was allocated a budget to put together this multidisciplinary committee.

Encouraged by this unprecedented initiative in the region, I organized a first meeting with the local presidents of associations of hygienists, dental assistants and denturists. I also invited Claude Anglehart and Jeff Arsenault of the Patterson company, and Darcie Robichaud, executive director of dental studies at Oulton College. Representatives of dental insurance companies Blue Cross and Assumption Life also participated in the project. The diversity and enthusiasm of the committee proved to be its greatest asset. This year, we focused on the relationship between a healthy mouth and a healthy body. Our numerous activities included a competition in the local *Times & Transcript* newspaper, weekly interviews on the radio and the distribution of toothbrushes in the pediatric and geriatric departments of municipal hospitals. The committee would also like to thank Sunstar and GlaxoSmithKline for their generosity.

I was really touched by the passion of all these people, and their contributions were instrumental in the success of our mission. Dental health month was just drawing to a close and already the organizing committee was discussing projects for next year. A number of other



Instilling good oral health habits early: Dr. Drapeau-McNally with a parent and young patient.

organizations are seeking to join us. A dental laboratory and 2 municipal hospitals have expressed an interest in being part of the team. We are also targeting the prestigious participation of a well-known speaker to address the staff in hospitals and help us to educate the community. It's clear that dental health month 2009 in Moncton will be even more fantastic than in previous years!

In my view, the sharing that took place between dental health professionals and the community was unparalleled. In closing, I absolutely must encourage you to look within your communities for this energy to help carry the oral health message.

*Dr. Suzanne Drapeau-McNally  
Moncton, New Brunswick*

### **Integrating our Immigrant Dentist Colleagues**

I read your editorial on the need to come up with new dental care models<sup>1</sup>, and I just had to write to you.

I think we should be looking here at how to integrate our immigrant colleagues who were trained elsewhere and proved themselves in their own countries before coming to Canada. In my opinion, they have more to offer in the area of dental care than do denturists or hygienists. I can see allowing them to work as interns, with a provisional licence, under the supervision of local

colleagues, in order to give them the time to prepare for the Board examinations that will allow them to obtain permanent licensure.

There is a problem finding dentists for rural areas. Some dentists who have immigrated to Canada would probably not hesitate to move to these regions, so why not give them that chance instead of trying to create a new profession for hygienists?

I hope that the need to develop new models of oral care will become an opportunity for integrating immigrants.

*Dr. Yméle Manénan Georgette  
Toronto, Ontario*

**Reference**

1. O'Keefe J. Time for new models of care [Editorial]. *J Can Dent Assoc* 2008; 74(6):481.

**Identify Underserved Areas in Canada**

In his article, Dr. Williams explained the problem of getting dentists to locate in rural areas.<sup>1</sup> I'm curious if there is an inventory of areas or towns that feel they are underserved in the provision of dental care? Such a list would allow prospective dentists to investigate various locations and make informed choices.

Currently there are a number of Canadian citizens who have been trained and are practising in other countries, such as Australia. Some of these foreign-trained Canadian dentists would welcome the opportunity to practice in rural or underserved areas of Canada. These are well-trained, experienced dentists who want to come home.

Surely there must be some way to bring both parties together, so that rural populations have quality dental care. It may take some innovative thinking and new ways to determine competency, but I'm sure if our profession truly wants to provide dental care to underserved areas, we can work with both groups to find solutions.

*Dr. Gordon Hayes  
Burlington, Ontario*

**Reference**

1. Williams J. Making the case for rural and remote dental practices in Canada. *J Can Dent Assoc* 2008; 74(6):515-6.

**Erratum**

In the July/August issue of *JCDA*, a modification made to the article on bisphosphonates, osteonecrosis, osteogenesis imperfecta and dental extractions<sup>1</sup> at the copyediting stage resulted in a misinterpretation of the opening sentence of the Conclusion. The first sentence should read: "Osteonecrosis of the jaw is a serious condition; its association with bisphosphonate therapy, cannot, therefore, be taken lightly." *JCDA* regrets the error.

**Reference**

1. Schwartz S, Joseph C, Iera D, Vu D. Bisphosphonates, osteonecrosis, osteogenesis imperfecta and dental extractions : a case series. *J Can Dent Assoc* 2008; 74(6):537-42.

**Natural,  
Clinically Tested,  
OTC Treatments  
for Cold Sores &  
Canker Sores**

**Rapid Relief,  
Rapid Healing  
Naturally**

- Cures most canker sores in just **one day**\*  
\*J. Pharm Sci., Vol. 93, No. 12, Dec. 2004
- Heals cold sores in half the time\*\*  
\*\*J. Alt. Med., Vol. 10, No. 2, June 2005
- Immediate pain relief

**Call for your FREE trial size!**

**1-800-448-1448**  
**www.quantumhealth.com**

**QUANTUM**  
**HEALTH**

*Natural Products that Make a Difference*

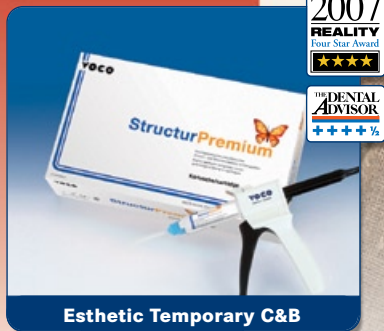# ★ Christmas Comes Early with VOCO



Nano Hybrid Composite



Nano reinforced Hybrid Composite



Esthetic Temporary C&B



Dual-Cured Self-Etch Bond



## FREE OFFER!

Buy any combination of Voco products from our authorized dealers totalling a minimum of \$2,000 net of all taxes to qualify for a free gift or *gift certificate* of equivalent value. Only invoices from October 1 to December 31, 2008 will be considered and purchases from 1 or more invoices can be combined.



<p><b>Level 1</b></p>		
<p><b>Level 1</b></p>	<p><b>Level 2</b></p> <p>80GB iPod Nano Video</p>	<p><b>Level 2</b></p>
<p><b>Level 3</b></p> <p>16GB iPod Touch</p>	<p><b>Level 3</b></p>	<p><b>Level 4</b></p>
<p><b>Level 4</b></p>		

- Level 1** Buy \$2,000 retail and get a Panasonic Portable DVD player DVDSL83K or a Kodak Easy Share Wifi digital photo frame EX-811
  - Level 2** Buy \$2,500 retail and get an 80 GB iPod or Nintendo Wii game system
  - Level 3** Buy \$3,000 retail and get a 16GB iPod Touch or a TomTom Bluetooth 720 GPS
  - Level 4** Buy \$5,000 get a Toshiba 32 inch Flat Panel LCD HDTV model 32A500U or a Callaway FT-i driver
- \*TO RECEIVE YOUR FREE GOODS OR GIFT CERTIFICATES mail your qualifying dealer invoices to: VOCO, 10120 Mortfield Road, Richmond BC V7A 4H5 or fax them to: 604-275-5825. Please allow a minimum of 6 weeks for processing of all claims. Free gifts are subject to substitution if an item is no longer available. Please specify if you would like the gift certificate to be from WalMart, Best Buy, Futureshop or Golf Town.





Back row (from left): Mr. Claude Paul Boivin, CDA executive director, Dr. Ron Smith, CDA vice-president, Mrs. Caroline Daoust, ODQ executive director, Dr. Benoit Soucy, CDA director of clinical and scientific affairs, Dr. Don Friedlander, CDA president-elect.

Front row (from left): Dr. Diane Legault, ODQ president, Dr. Deborah Stymiest, CDA president.

## CDA Representatives Hold Discussions with Quebec Associations

Members of CDA's executive met with representatives of the Order of Dentists of Quebec (ODQ) and the Quebec Dental Surgeons Association (QDSA) in 2 separate meetings in August. These meetings were designed to facilitate the sharing of information and to strengthen CDA's relationship with these important Quebec dental organizations. Items for discussion included labour mobility, accreditation of universities and other issues of mutual concern.

Members of the QDSA delegation included Dr. Serge Langlois, president, Dr. Daniel Pelland, executive director, Dr. Daniel Robin, first vice-president, and Dr. Gerald Dushkin, board member. ✦

## CDA Appears Before House of Commons Finance Committee

In August, CDA was invited to submit a prebudget consultation brief to the Minister of Finance through the House of Commons Standing Committee on Finance. CDA recommended that the federal government pursue initiatives to raise awareness among Canadian seniors (and near-seniors) about the importance of maintaining optimal oral health and to support mechanisms to make sustained oral health an achievable goal for all Canadians.

CDA made several suggestions to help achieve this goal. These include having the federal government partner with CDA and other stakeholders to produce educational materials targeted at seniors about the importance of maintaining optimal oral health, including promoting the linkages between oral health and overall health. CDA also urged the government to promote the use of the newly created tax free savings accounts as an ideal vehicle to encourage Canadians to properly save for oral health care costs in their senior years. ✦

To view the complete prebudget consultation brief, visit [www.cda-adc.ca/en/cda/about\\_cda/government\\_relations/news\\_emerging.asp](http://www.cda-adc.ca/en/cda/about_cda/government_relations/news_emerging.asp)

## UBC Launches New Graduate Endodontics Program



Dr. Jeff Coil, Dr. Ya Shen and Dr. Markus Haapasalo figure prominently in the development and implementation of the new endodontics program at UBC.

In September, the University of British Columbia (UBC) faculty of dentistry began offering a graduate training program in endodontics aimed at producing clinical specialists. Successful graduates of the new 3-year program will receive a combined diploma in endodontics along with an MSc in dentistry, and will be eligible to take the Fellowship Examination of the Royal College of Dentists of Canada.

Interest and demand for this new graduate program is high and the positions for the inaugural 2008 entry year were easily filled. Three students have begun their first year of studies at UBC. Dental schools in Western Canada have never offered such a graduate program before, as prospective graduate endodontics students in Canada previously sought training at the University of Toronto or at schools in the United States. UBC is already receiving applications for the 2009 program, from both Canadian and international students.

UBC is an ideal location for this new program as the province is fortunate to have a dedicated group of endodontic specialists who donate their time to teach both undergraduate and graduate students at the school. "The high skill level of the local endodontic establishment and their willingness to contribute has been one of the major building blocks of endodontic education at the university," believes Dr. Markus Haapasalo, head of the division of endodontics at UBC and acting head of the department of oral biological and medical sciences.

Dr. Haapasalo has been closely involved in the planning and implementation phases of the graduate endodontics program. "The new program will also help to reinforce the bonds between endodontics and other graduate programs at UBC," he explains. "In fact, one of the strongest influences in starting the graduate endodontic program came from Dr. Hannu Larjava, UBC's head of the division of periodontology."

Students in the new program will be conducting original research relating to endodontics. Dr. Haapasalo believes this research can only strengthen endodontic knowledge at the university as it aims to address clinically relevant challenges. "There is exciting research being conducted on endodontic disinfection and biofilms along with studies on the mechanisms and possible causes of instrument fracture," he notes. The latter research focus has been influenced by Dr. Ya Shen of Hong Kong, who joined the UBC endodontics division as a clinical assistant professor in 2007. Dr. Shen is one of the leading experts on research related to instrument properties. The third key figure in the new endodontics program is Dr. Jeff Coil, assistant professor at UBC. For the 2008 session, Dr. Coil will be the program's acting director.

UBC's stature as a leader in the endodontics field will be reinforced with the introduction of this graduate program. As a testament to this reputation, Dr. Haapasalo was one of 5 experts (and the only Canadian) invited recently to contribute to a comprehensive joint continuing education project supported by the American Association of Endodontics and Dentsply.

While the graduate program had to overcome some issues regarding regulations and areas of responsibility between university faculties, Dr. Haapasalo credits the assistance of Dr. Ed Putnins, UBC associate dean of research and graduate studies, in helping to guide the faculty through the most challenging aspects of the process.

The coming academic year should prove to be an exciting time at UBC as the new graduate program is poised to produce quality endodontics research and endodontists. ❖

For more information on the program, visit [www.dentistry.ubc.ca/academic\\_programs/mcd/endo/default.asp](http://www.dentistry.ubc.ca/academic_programs/mcd/endo/default.asp)

## IADR/CADR Meeting Showcases Canadian Oral Health Research

The 86th General Session and Exhibition of the International Association for Dental Research (IADR) and the 32nd Annual Meeting of the Canadian Association for Dental Research (CADR) took place concurrently from July 2 to 5 in Toronto.

The meetings had a total registration of more than 5,000 people representing 70 countries. Over 3,500 research abstracts were presented in a variety of formats including posters, symposia, workshops and oral presentations. In particular, the symposia drew large audiences and covered such diverse topics as oral health literacy, knowledge translation and biomineralization.

The quality of the science was very strong, with many front-line researchers sharing their insights. “The symposia were quite well-received and those in attendance demonstrated an eagerness to learn, even if the topic may have been from outside their normal discipline,” notes Dr. Chris McCulloch of the University of Toronto, who was chair of the joint meeting’s Local Organizing Committee.

The event was significant for Canadian oral health research. “This year’s meeting put Toronto back on the global dental research map,” continues Dr. McCulloch. “Canadians were able to showcase their innovative research in fields such as neuroscience, cell biology, pain and inflammation, and periodontal disease on a world stage.”

The sheer size of the event helped attract Canadian researchers to Toronto, providing a great opportunity to meet with fellow researchers and build a sense of community. “While the idea of bringing together people in dental research from across Canada might not seem radical, it took an event of this magnitude to draw many of these clinician-scientists together,” adds Dr. McCulloch.

CDA president Dr. Deborah Stymiest delivered a speech during the meeting’s opening ceremonies. “Canada is the home of 10 world-class dental faculties and each can be proud of their accomplishments in dental research,” she said. “CDA understands the importance of those institutions for the profession and supports their role in the expansion and dissemination of the body of knowledge of dentistry.”

“This body of knowledge is one of dentistry’s most precious assets and it is essential that those who contribute to its growth know that they have the support and appreciation of clinicians like me who, on a daily basis, benefit from the product of their work,” Dr. Stymiest added.

### Student Presence in Toronto

Dr. McCulloch was particularly encouraged by the number of students attending the IADR/CADR sessions — an estimated 1,300 students from over 35 countries. “There was a strong international student presence, most notably from Brazil,” he says. Two student luncheons were organized by the University of Toronto during the meetings and these were both very well attended, with over 300 students coming to each of the informal lunchtime gatherings. “International dental students were able to meet with University of Toronto dental faculty to discuss their areas of research and potential graduate study opportunities in North America,” notes Dr. McCulloch. The student luncheons were supported by Straumann Canada and the Dentistry Canada Fund.

Canadian students also featured prominently during the meetings, most notably in 2 prominent student oral health research competitions. Students and postdoctoral fellows involved in oral health sciences research in Canada are eligible to submit a manuscript describing their research for the CADR-IMHA Student Research Awards competition. The 2007–2008 award winners were Ms. Amanda Huminicki of the University of Manitoba, Mr. Wailan Chan of the University of Western Ontario, Dr. Hugh Kim of the University of Toronto, Dr. Heather Szabo Rogers of the University of British



CDA president Dr. Deborah Stymiest talked about the value of dental research during her speech at the IADR opening ceremonies.

Columbia, Ms. Samar Khoury of the University of Montreal and Ms. Carol Forster of the University of Toronto.

From this group, the 2 highest ranked investigators were given an opportunity to present their research during the IADR General Session, as part of the IADR/Unilever Hatton Awards competition. Dr. Kim and Ms. Khoury were selected to represent Canada in this year's international contest and they won first prize in the basic science senior category and second prize in the clinical research senior category, respectively.

### IMHA's First Scientific Director Honoured

A significant award was bestowed upon Dr. Cyril Frank, the inaugural scientific director of the Canadian Institutes for Health Research's (CIHR) Institute of Musculoskeletal Health and Arthritis (IMHA). Dr. Frank was given Honorary Membership in the IADR, an award that goes to an individual who has made significant contributions to or supports dental research. "I was deeply honoured and humbled to have been given IADR Honorary Membership," said Dr. Frank. "To have been nominated for this award by several past presidents of such a prestigious international society is even more overwhelming."

Under Dr. Frank's leadership, total financial support for oral health research in Canada doubled between 2000 and 2005 and many new oral health research training programs were initiated, such as the Network for Oral Research Training and Health and the Cell Signals programs. "I remain indebted to the tremendous support that I received from the outstanding leadership of the Canadian dental research community during my time at CIHR," he continued. "I would like all members of the national dental community to know that I believe that they are literally 'the model' for the rest of the health research community in Canada."

Supporters of the IADR/CADR events included Health Canada, the University of Toronto, the University of Western Ontario and CADR. The members of the Local Organizing Committee were Drs. Chris McCulloch, Paul Allison, Richard Ellen, Irwin Fefergrad, Helen Grad and John O'Keefe. ❖



Dr. Jane Aubin, scientific director of IMHA, presented a CADR-IMHA Student Research Award to Ms. Samar Khoury in Toronto.

### Symposium Honours Giants of Orofacial Neurosciences

Over 180 clinicians and scientists attended a special satellite symposium that recognized the contribution of 3 giants in oral and trigeminal neurosciences — Drs. Barry Sessle, James Lund and Alan Hannam. These 3 clinician-scientists all completed their dental training in Australia before emigrating to Canada. Combined, they have trained over 200 graduate students in this country throughout their careers.

Dr. Gilles Lavigne, new CADR president and dean of the University of Montreal faculty of dentistry, was one of the organizers of the event. "The day was a success as the attendees and speakers shared their personal thoughts in honouring these 3 leaders. The event also highlighted the enormous contribution of dentistry in Canada to the field of pain and oromotor control."

Close to 20 lectures were delivered by leaders in the orofacial pain and movement field during the 2-hour lecture sessions dedicated to the research contributions of each of the researchers being honoured.

The symposium was held at the University of Toronto immediately before the IADR General Session. It was sponsored by the IADR Neuroscience Group, the Oral and Bone Health Research Network, the Quebec Pain Research Network, the Canadian Institutes for Health Research (Applied Oral Health Research, Pain M2C, and Cell Signaling in Mucosal Inflammation and Pain training grants and the Placebo Mechanism Research Network) and the University of Toronto Centre for the Study of Pain. ❖

# Briefs

## ► Veterans' Website Adds Oral Health Information

The Veterans Affairs Canada website now features information dedicated to promoting optimal oral health among Canadian veterans and their families. Titled "Your Mouth: It Affects Your Overall Health," the new section reinforces the message that maintaining good oral health is important for seniors. It also outlines the possible links between infections of the mouth and other conditions such as diabetes and pneumonia.

Dr. Brian Barrett, the national dental consultant with Veterans Affairs, stated that the department takes very seriously the maintenance of the oral health of these special Canadians. "As many war service veterans are becoming quite elderly, the maintenance of their dental health is vital to their quality of life as well as the prevention of more serious general health problems," says Dr. Barrett.

To view the new oral health section of the Veterans Affairs Canada website, visit [www.vac-acc.gc.ca/clients/sub.cfm?source=health/dental](http://www.vac-acc.gc.ca/clients/sub.cfm?source=health/dental). ➤

## ► Used Dentures a Charitable Gold Mine

Old dentures have become an important source of funds for one Japanese non-profit organization. The Japan Denture Recycle Association collects used dentures to extract precious metals, which are then sold to metal recycling companies. Half of the funds raised by the association go to UNICEF and the remainder goes to local government offices for welfare projects.

Besides raising funds for a worthwhile cause, the initiative has kept hundreds of pounds of precious metals out of landfills. Dentures contain parts made of gold, silver, palladium and other precious metals that require a great deal of energy when first extracted from the earth. Rare metal recycling companies process these used denture parts to recapture the metals.

A dental technician started the organization in 2006 after learning that an estimated 3.6 million dentures are discarded in Japan each year. If all these dentures were recycled, they would be worth approximately C\$73 million. As of April 2008, the association has recycled about 30,000 dentures, raising more than C\$185,000.

Donation boxes have been placed in various government offices around Japan so citizens can drop off their used dentures. ➤

## UBC Professor Garners Top Teacher Award

**D**r. Christopher Clark of the University of British Columbia is the 2008 recipient of the 3M ESPE National Dentistry Teaching Award. This annual award is presented to a faculty member who has displayed the qualities of an outstanding teacher along with having an exceptional interest in, and enthusiasm for, the learning needs of students.

Dr. Clark's contributions to dental education have come at the local, national and international levels. He took a lead role in the transition of the UBC faculty of dentistry curriculum to a problem-based learning pedagogy in the mid 1990s. He has been widely recognized for his contributions in problem-based learning, leading to several invitations to review dental curricula in other countries.

Dr. Clark has continued to be an innovative dental educator and has coordinated the development of a new community service learning program to the UBC dental curriculum. He is an exemplary educator who has made significant contributions to dental education. ➤



Dr. Christopher Clark

The 3M ESPE National Dentistry Teaching Award is an initiative of the Association of Canadian Faculties of Dentistry and the Dentistry Canada Fund. Nominations for the award can be made by students, alumni and colleagues.

## Toronto Osseointegration Conference Celebrates the Past and Looks to the Future

Nearly 1,000 participants from 38 countries attended the Toronto Osseointegration Conference Revisited, held at the Metro Toronto Convention Centre in early May. They came to listen to 70 of the world's foremost experts on osseointegration and dental implant research, who spoke about where dental implant practice and research has come from, where it is today and where it might be heading in the future.

The date chosen for this conference was not coincidental as it has been 25 years since University of Toronto professor emeritus Dr. George Zarb organized the 1982 Toronto Osseointegration Conference. At that time, only 1 manufacturer was promoting titanium implants in North America. Today, osseointegration and implant dentistry has reached an unprecedented peak. Scores of dentists worldwide are ready to learn more about implant practices and are eager to offer implant solutions to their patients. As a result, the implant market today is saturated with new implant manufacturers, brands, surfaces and marketing strategies.

The 25-year mark seemed an appropriate time to reflect on the accomplishments of implant dentistry and to examine the many significant developments of the current and future application of implants to support intraoral and extraoral prostheses. The aim of the conference was to look back at what the profession has achieved over the last 25 years and to assess new and innovative developments in the field of osseointegration. Each speaker was invited to critically appraise past accomplishments and to suggest in which direction they believe implant dentistry is heading.

The speakers were divided among 24 theme sessions focusing on topics such as treatment planning, patient-centred considerations, interventions and biomaterials. Other sessions examined the assessment of technology and educational requirements. Among the featured speakers were several prominent researchers based in Canada, including Drs. James Anderson, John Davies, Jocelyne Feine, Asbjørn Jokstad, Michael MacEntee, Robert Pilliar, George Sándor, Barry Sessle and Howard Tenenbaum.

Wiley Blackwell will be publishing the proceedings of the conference in a book scheduled for release in November 2008. "It will be a privilege and honour to share the scientific knowledge presented during this conference with dentists and researchers throughout the world," says Dr. Jokstad, scientific chair of the event.

The 2008 Toronto Osseointegration Conference Revisited would not have been possible without the support of industry and the many volunteers who gave their time and energy to make the conference a success. The members of the conference Organizing Committee were Dr. Anne Gussgard, Dr. Barry Chapnick, Dr. Jokstad, Dr. Barry Korzen and Mrs. Raisyl Wagman. The moderators for the theme sessions were recruited from the teaching staff of the University of Toronto faculty of dentistry. A number of post-graduate residents and students also volunteered at the conference.



From left: Dr. Barry Chapnick of the University of Toronto and member of the conference Organizing Committee, Ms. Diane Howard, vice-president of Astra Tech Dental Inc. Canada, and Dr. Lyndon Cooper of the University of North Carolina, vice-president of the American College of Prosthodontics — one of the Scientific Partners of the conference.



The Honourable David R. Peterson, chancellor of the University of Toronto and former premier of Ontario, spoke at the conference's opening ceremonies.

*At the conclusion of the Toronto Osseointegration Conference Revisited, Dr. Asbjørn Jokstad, the conference's scientific chair, shared some of his thoughts on the future of osseointegration and dental implants with JCDA.*

**JCDA:** *In light of the presentations and discussions at the conference, can you briefly speculate on what the future might have in store for implant dentistry?*

**Dr. Jokstad:** Such a question must always be considered with the caveat that everything we know and understand about osseointegration and dental implantology today could be radically different tomorrow. For instance, with the rapid advances taking place in the field of tissue engineering, the practice of using metal screws to place teeth might become obsolete in a short time, especially as researchers become more successful at growing replacement hard tissues.

With the dizzying number of implant brands currently on the market (close to 400!) it would seem logical that the price of dental implant hardware should decrease as a result of increased levels of competition. This should therefore increase the availability and affordability of implant therapy for a larger number of patients.

**JCDA:** *What would you identify as significant trends in dental implant research?*

**Dr. Jokstad:** I believe that one of the more exciting areas of research will be applying the outcomes of nanotechnology research. This could be related to chemically modifying titanium surfaces or using other osseoinductive substances on the surface. In fact, the entire implant–bone interface is ripe for further research. Another interesting area is the use of ceramic implants, such as zirconium-oxide or zirconia. However, there is a definite need for more clinical data on the use of ceramics. Finally, the creation and use of bone morphogenetic proteins opens up the possibility that these and other extracellular matrix proteins might have a variety of vastly different therapeutic uses in the future.

**JCDA:** *What have been some of the most important achievements or developments in implantology since the 1982 conference?*

**Dr. Jokstad:** The principles for the use of implants, established in the 1970s by P.I. Brånemark and his team, have been branded by some in the profession or industry as being too strict or cautious. Yet the fact remains that there is little or no strong evidence that can justify replacing these principles. Perhaps it is because Brånemark demanded such a high standard of quality in his research that these principles have withstood the test of time.

The problem now is that this same level of research quality is not being replicated by enough researchers or dental implant manufacturers. As a result, regulatory agencies are prone to accept a minimum amount of experimental laboratory data rather than demanding rigorous clinical studies to support the introduction of any new implants or interventions. We must consider whether these global agencies are being as effective as they should be. Since we still don't fully understand all aspects of the osseointegration phenomenon, it would seem to me that these agencies should be more demanding in the quality of the supporting research before approving new products or therapies. ♦



Dr. Asbjørn Jokstad, scientific chair of the conference and Nobel Biocare Chair in Prosthodontics at the University of Toronto, with Dr. Anne Gussgard, director of the conference.

To read more about the future of oral implants, consult Dr. Jokstad's review article "Oral implants — the future" in the *Australian Dental Journal* (2008; 53 Suppl 1:589–93).

## Ontario Constituency Honoured by AGD

The Academy of General Dentistry (AGD) bestowed the Ontario constituency with 2 awards during the AGD's Annual Meeting and Exhibits in Orlando, Florida, in July.

Ontario was granted the prestigious Constituent of the Year (COY) Award along with the William W. Howard Academy Constituent Editors (ACE) award. The COY award recognizes AGD constituents that display strengths in every area of constituent activity, such as representing governance and administration, continuing education, communication, membership and public information. The ACE award recognizes excellence in newsletter publishing. The AGD Ontario constituency also received honourable mentions in the Continuing Education Award of Excellence and the Membership Award categories.

"Teamwork, dedication and commitment from the members of the Ontario AGD have led to this great achievement," said Dr. Neil Gajjar, Ontario AGD president. "We look forward to another outstanding year in which we can help advance the field of dentistry and the AGD, as well as ensure the oral health of the public." ♦

For more information, visit [www.agd.org](http://www.agd.org).

## Editors' Group Voices Concerns About the Commercial Influence on Publications

The American Association of Dental Editors (AADE) has published a position statement on the undue commercial influence on professional publications. In a press release, Dr. Michael Maihofer, AADE president, said he believes that "managing the boundary between editorial and advertising content is the greatest challenge facing dental editors today."

In the preamble to the position statement, the AADE states that disguised commercially biased articles in a professional publication can have a negative impact on patient care.

"AADE believes that the interests of readers and patients are paramount for editors, and that patient care should not be compromised by commercially biased editorial content," continued Dr. Maihofer. "The editor is constantly juggling competing interests while trying to produce the best journal possible with available resources."

The AADE makes a number of recommendations, among them, that editors should not be influenced by commercial interest when deciding to publish an article. Equally, pressures from external commercial interests should not influence the content of a published article. Finally, transparency of processes and clear distinctions between editorial and advertising content, such as advertorials, are essential to high-quality dental professional journalism. ♦

For more information on the AADE position statement, visit [www.dentaeditors.org](http://www.dentaeditors.org).



## • Issues in Brief • .....

### Poverty: A Challenge for Our Society, a Challenge for Oral Health Care Professionals

Christophe Bedos, DCD, PhD; Martine Lévesque, MSc

#### Introduction

October 17 marks the 16th edition of the International Day for the Eradication of Poverty, adopted by the United Nations to raise consciousness and mobilize nations in the fight against poverty. This brief is an introduction for oral health professionals to the issue of poverty and oral health.

#### Specific objectives

- Inform oral health care professionals about poverty in Canada.
- Describe the challenges poverty represents for public health and for health professionals.

#### What is poverty?

- The United Nations defines poverty as “a human condition characterized by the sustained or chronic deprivation of the resources, capabilities, choices, security and power necessary for the enjoyment of an adequate standard of living and other civil, cultural, economic, political and social rights.”<sup>1</sup>
- Statistics Canada provides several indicators of low income, among them, before-tax low-income cut-offs, according to which a person living alone with less than \$21,666 per year is considered poor in a big city such as Toronto or Vancouver.<sup>2</sup>

#### Who is poor in Canada?

- In 2006, 4.6 million people were living in poverty in Canada according to before-tax low-income cut-offs. These people represent 14.5% of the population, though this rate varies from province to province.<sup>2</sup>
- Poverty rates also vary greatly from one population category to another. For example, single women leading households with children had a poverty rate of 42.6% in 2006.<sup>2</sup>
- In over 25 years, little ground has been gained with regards to the national poverty rate, which is currently only 1.7 percentage points less than what it was in 1990.<sup>2</sup>
- Canada does not compare very well with many industrialized countries such as Denmark and Finland, where child poverty rates are less than 4%. Canada lags behind, with a rate of 14%.<sup>3</sup>
- Though their economies and gross national products are much smaller than Canada’s, these European countries minimize poverty rates through strong and generous social programs (including health, social, unemployment security) and progressive taxation schemes.<sup>4</sup>

#### Why is poverty a challenge for public health and for the profession?

- There is considerable evidence that low socioeconomic status and poverty constitute the main determinants of poor health in industrialized societies. The poorer people are, the more they are at risk of developing diseases, and ultimately, of dying prematurely.<sup>5</sup>
- Poor people are also more at risk of developing caries and periodontitis, and consequently, of losing their teeth. In Quebec, for example, children 5–6 years of age from low-income families (< \$30,000/year) have more than twice the caries rates of children from more affluent families (> \$50,000/year).<sup>6</sup> These disparities continue into adolescence and adulthood.

- Despite higher needs, impoverished people tend to visit the dentist less frequently for preventive treatment, wait longer when a dental problem occurs and are more at risk of requiring dental extractions when visiting the dentist.<sup>7</sup>
- Studies show that difficult relationships with oral health professionals is one of the reasons why the poor visit the dentist less often. On the one hand, impoverished people feel they are perceived negatively and experience shame in their relationships with dental professionals.<sup>8</sup> On the other hand, dentists admit to feeling frustrated with some of their clients' health behaviours and general way of living.

### Conclusion: Looking toward the future

- Fighting poverty has been justified for reasons ranging from human rights and social justice to economic, political and even religious concerns. Recent efforts on the part of a few provinces (Quebec as well as Newfoundland and Labrador have both developed poverty reduction plans) are fuelling Canadian momentum for the reduction of poverty.
- In addition, the 2002 Royal Commission on the Future of Health Care in Canada stated that social disparities in oral health are contrary to the values of our society, namely equity, fairness and solidarity.<sup>9</sup>
- Oral health professions and their members must embark on the national movement toward poverty reduction and contribute to alleviating its consequences. Efforts must aim to:
  - 1) improve relationships with underserved members of society
  - 2) develop strategies for positive and effective interactions
  - 3) improve access to dental services for poor populations. ♦

---

*Dr. Bedos is an associate professor and head of the division of oral health and society, faculty of dentistry, McGill University, Montreal, Quebec. He is also head of the public health and clinical research branch of the Oral Health and Bone Research Network of the Quebec Health Research Fund (FRSQ). Email: christophe.bedos.1@mcgill.ca*

*Ms. Lévesque is a research coordinator of the 'Listening to Others' project, division of oral health and society, faculty of dentistry, McGill University, Montreal, Quebec. The 'Listening to Others' project is an ongoing collaborative research program for the development of an online course on poverty and oral health. The course ultimately aims for greater understanding and strengthened alliances between the dental professions and people living in poverty.*

### References

1. United Nations, Office of the High Commissioner for Human Rights. Poverty. Available from: <http://www.unhcr.ch/development/poverty-02.html> (accessed 2008 Sept 18).
2. Statistics Canada. Available from: [www.statscan.ca](http://www.statscan.ca).
3. UNICEF. Child poverty in perspective: an overview of child well-being in rich countries. Innocenti Report Card 7, 2007. UNICEF Innocenti Research Centre. Florence.
4. Raphael D. Poverty and policy in Canada : implications for health and quality of life. Toronto: Canadian Scholars Press Inc. 2007.
5. Raphael D, editor. Social determinants of health : Canadian perspectives. Toronto: Canadian Scholar's Press; 2004.
6. Brodeur JM, Olivier M, Benigeri M, Bedos C, Williamson S. Étude 1998-1999 sur la santé buccodentaire des élèves québécois de 5-6 ans et de 7-8 ans. Québec: Ministère de la Santé et des Services sociaux. Gouvernement du Québec; 2001. Report No. 18: Collection analyses et surveillance.
7. Bedos C, Brodeur JM, Benigeri M, Olivier M. Dental care pathway of Quebecers after a broken filling. *Community Dent Health* 2004; 21(4):277-84.
8. Bedos C, Brodeur JM, Boucheron L, Richard L, Benigeri M, Olivier M, and other. The dental care pathway of welfare recipients in Quebec. *Soc Sci Med* 2003; 57(11):2089-99.
9. Leake JL. Why do we need an oral health care policy in Canada? *J Can Dent Assoc* 2006; 72(4):317. Available from: [www.cda-adc.ca/jcda/vol-72/issue-4/317.html](http://www.cda-adc.ca/jcda/vol-72/issue-4/317.html).



## Surveillance Spotlight...

### What is the Role of Inflammation in the Relationship Between Periodontal Disease and General Health?

by Anthony M. Iacopino, DMD, PhD

The International Centre for Oral–Systemic Health, based at the University of Manitoba’s faculty of dentistry, was launched in January 2008. The centre is proud to partner with JCDA to provide summaries of contemporary literature and news in oral–systemic health that may affect modern dental practice. This month’s article discusses the role of inflammation in the relationship between periodontal disease and general health.

Inflammation has become a very important topic in discussions on the major threats to maintaining satisfactory health and healthy living. It appears there are strong associations between chronic systemic inflammation and cardiovascular disease, diabetes, cancer, arthritis, dementia and many other chronic diseases of aging. Two recent publications highlight the nature of chronic inflammation as part of periodontal disease, as a systemic result of periodontal disease and as a major negative factor for overall general health.<sup>1,2</sup>

The relationship between periodontal disease, inflammation and general health has been discussed for several years.<sup>3–5</sup> However, recent studies have provided more comprehensive evidence for the mechanistic linkages. There is increasing acceptance that periodontal disease shares some of the same chronic inflammatory mechanisms of these systemic conditions and that periodontal disease increases the overall systemic inflammatory burden that exacerbates these conditions.

The recent application of new knowledge and concepts regarding inflammation and periodontal disease has led to discussion of new approaches to therapy and comprehensive care that include holistic and interprofessional management of oral and systemic inflammation. The key points to consider within this new paradigm of patient care are:

- 1) Individuals respond differently to periodontal inflammation, systemic inflammatory burden and anti-inflammatory therapies because of genetics, environment, diet, stress and lifestyle choices.
- 2) Anti-inflammatory therapies may be targeted to reduction and elimination of oral biofilms, dampening of the local periodontal inflammatory response, interference with systemic biochemical messengers and mediators, or augmentation of natural body processes that resolve inflammation.
- 3) Smoking and visceral fat accumulations around the waist are perhaps the most important determinants of systemic inflammatory burden and response to periodontal inflammation.
- 4) Multidirectional reinforcement of health and wellness messages focused on systemic inflammatory burden need to be coordinated between the dental, medical and nursing professions, as well as nutritionists and caregivers.

It is likely that there will be continued interest in inflammation as the common denominator in periodontal disease and chronic diseases of aging. The cumulative damage to cells, tissues and organ systems mediated through long-standing inflammation cannot be disputed. The presence of severe periodontal disease contributes significantly to the overall systemic inflammatory burden. Currently, we cannot definitively conclude that periodontal disease causes systemic illness. However, we do know unequivocally that treatment of periodontal disease reduces systemic inflammatory burden, improves the function of vascular elements and provides better oral health. ♦

#### References

1. Williams RC, Barnett AH, Claffey N, Davis M, Gadsby R, Kellett M, Lip GYH, Thackray S. The potential impact of periodontal disease on general health: a consensus view. *Curr Med Res Opin* 2008; 24(6):1635–43.
2. Van Dyke TE. Inflammation and periodontal disease: a reappraisal. *J Periodontol* 2008; 79(8 Suppl):1501–02.
3. Iacopino AM. Periodontitis and diabetes interrelationships: role of inflammation. *Ann Periodontol* 2001; 6(1):125–37.
4. Iacopino AM, Cutler CW. Pathophysiological relationships between periodontitis and systemic disease: recent concepts involving serum lipids. *J Periodontol* 2000; 71(8):1375–84.
5. Cutler CW, Shinedling EA, Nunn M, Jotwani R, Kim BO, Nares S, Iacopino AM. Association between periodontitis and hyperlipidemia: cause or effect? *J Periodontol* 1999; 70(2):1429–34.

*Dr. Iacopino is dean and professor of restorative dentistry, and director of the International Centre for Oral–Systemic Health, at the faculty of dentistry, University of Manitoba, Winnipeg, Manitoba. Email: iacopino@cc.umanitoba.ca.*



Dr. Sneha Abhyankar

### Newfoundland and Labrador Dental Association's New President

Dr. Sneha Abhyankar of Corner Brook, Newfoundland, is the new president of the Newfoundland and Labrador Dental Association (NLDA). Dr. Abhyankar is a BDS graduate of the University

of Bombay in India. She joined the faculty of dentistry at the University of Toronto where she completed a diploma in dental public health and a master's in preventive dentistry. She went on to complete her DDS in Toronto and joined a group practice in Corner Brook, where she has practised since that time.

Dr. Abhyankar has served on the NLDA Continuing Education Committee and with the NLDA executive for the past 2 years. Her mandate as NLDA president includes widening the scope of children's dental plans and proposing a plan to assist seniors' dental coverage. ♦



Mr. Jamie Matera

### DIAC Names President-Elect

In September, the Board of Directors of the Dental Industry Association of Canada (DIAC) announced the election of Mr. Jamie Matera of Toronto as DIAC president-elect. Mr. Matera will continue his current duties as DIAC vice-president and director

of marketing until his 2-year term as DIAC president begins on May 1, 2010.

Mr. Matera is president of Central Dental Laboratories. His appointment will make him the first president to be selected from among DIAC's laboratory members. ♦

To access the websites mentioned in this section, go to the October 2008 JCDA bookmarks at [www.cda-adc.ca/jcda/vol-74/issue-8/index.html](http://www.cda-adc.ca/jcda/vol-74/issue-8/index.html).

Mark these dates on your calendar now!



IN CONJUNCTION WITH



CANADIAN DENTAL ASSOCIATION

# Pacific Dental Conference

March 5th - 7th, 2009 Vancouver, BC

Join your colleagues for an enriching learning experience!

- Joint meeting with the Canadian Dental Association
- Over 12,000 attendees expected
- Over 500 exhibitor booths
- International line-up of speakers
- Up to 12.5 hours of CE credits
- 2 hour drive to world famous Whistler Mountain for skiing



Visit either website for details

Pacific Dental Conference  
Canadian Dental Association

[www.pdconf.com](http://www.pdconf.com)  
[www.cda-adc.ca](http://www.cda-adc.ca)



TM

**Dentistry Canada Fund**  
The Canadian Charity  
for Oral Health



# Oral Health good for *life.*™\*

## Where All the Money Goes

The Dentistry Canada Fund (DCF) is the dental profession's charity for oral health. The Canadian Oxford Dictionary's definition of fund "is a reserve of money or investment set apart for a purpose." Thus, the dental profession has the right to know where all DCF's money goes and for what purpose. The quest to know where all the money goes should not be a surprise. A simple Google search on that phrase indicated about 42,000,000 links!!

Basically, DCF's funds are in 2 main categories. One is the **Endowment Fund**, where the principal is held in perpetuity and invested in accordance with DCF's investment policy. Once a designated fund grows beyond \$10,000, the annual interest, less an administration fee, is disbursed as a charitable grant or award. An endowment fund's purpose can be restricted by the donor for the purpose of education, research or public outreach.

The other category is an **Externally Restricted Fund**, where the principal is again invested by DCF-approved policy. The interest earned goes back into the principal, where both the principal and interest income become available for education, research and outreach.

**Outlined below is where all DCF's money goes.  
In 2007, 122 recipients received \$208,781**

<u>EDUCATION</u>	<u>Grant</u>	<u>Amount</u>
Lorne MacLachlan Fellowship	1	\$ 4,900
Library Grant	1	66,448
DCF Eaton Award	1	1,000
Thomas Curry Fellowship	1	850
DCF Education Grants	4	15,815
CDA Student Conference Grants	1	10,000
Procter & Gamble Scholarships	18	9,000
3M Teaching Award	1	5,000
3M Student Clinician Awards	9	9,000
Dentsply Student Clinician Awards	1	12,000
Ivoclar Technology Scholarships	8	7,500
Financial/Travel Grants	8	6,250
Pierre Fauchard Scholarships	12	4,200
	<b>66</b>	<b>\$152,563</b>
<u>RESEARCH</u>		
Murray McDonald Lecture	1	\$ 2,113
Dentsply Henry Thornton Award	1	1,000
CDHA Research Grant	1	4,152
Biennial Research Award	1	2,160
Johnson-Johnson Fellowships	1	3,500
DCF Research Grant	1	4,500
	<b>6</b>	<b>\$ 17,425</b>
<u>PUBLIC OUTREACH</u>		
BC Save A Smile Grants	39	18,293
Humanitarian Grants	9	12,500
CDA Project Grant	1	5,000
PFA Project Grant	1	3,000
	<b>50</b>	<b>\$ 38,793</b>

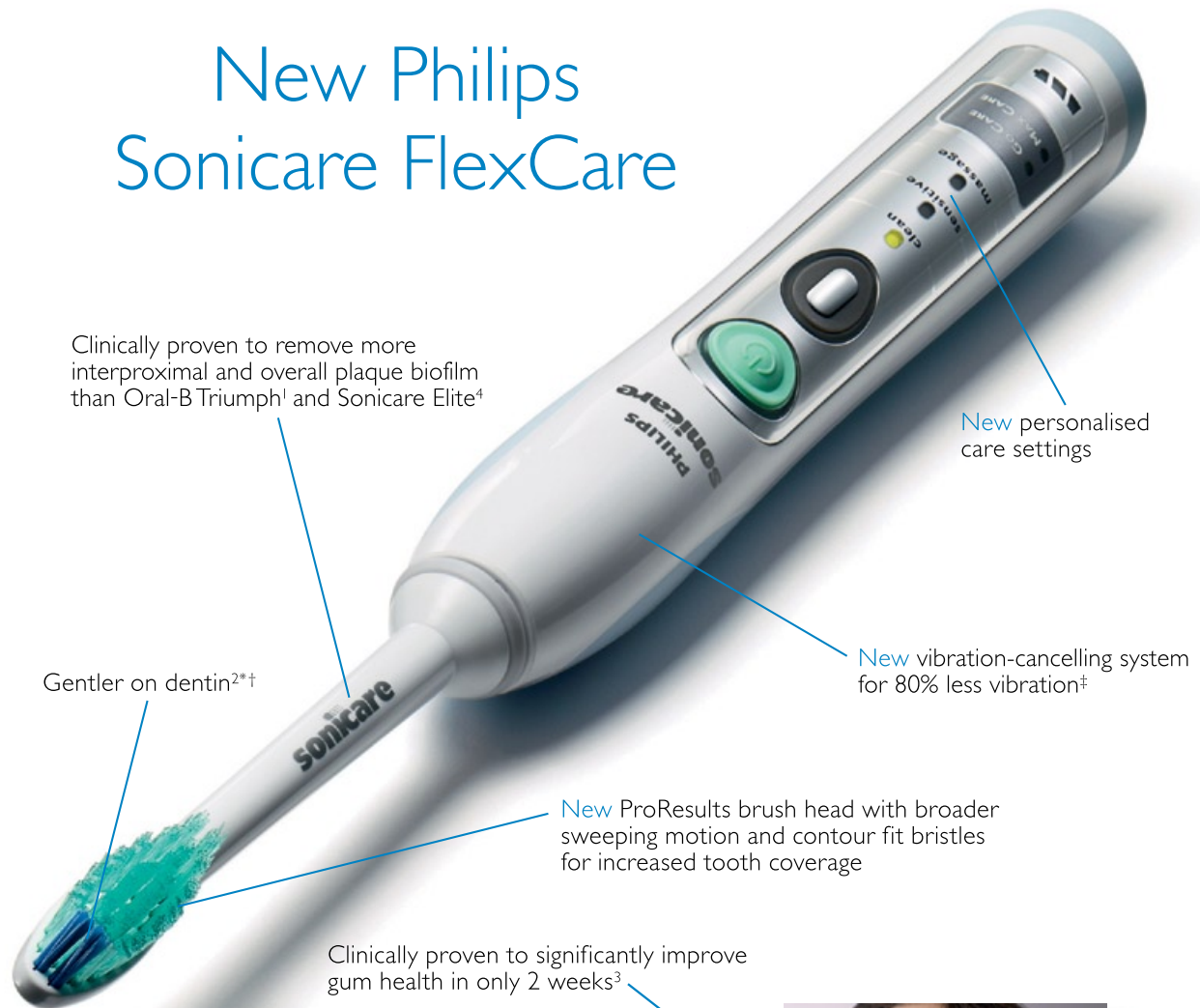As reported in DCF's 2007 Annual Report, under the **Endowment Fund** category there are 26 Education Endowment Funds totalling \$1,150,922: 6 Research/Lecture Funds (\$321,809), 10 Public Outreach Funds (\$480,406), 6 Developing Funds (\$30,941), 9 Non-specific Funds (\$165,361) and the Oral Health Good For Life Fund (\$1,118,429). Also in the Endowment Fund category is the historic Helen Langstaff Library Endowment Fund (\$2,132,487). Within the **Externally Restricted Fund** there are 6 Public Outreach Projects, totalling \$160,810; \$93,693 is set aside for Special Projects.

Of course, all the activity and resources required to raise, enhance and manage almost 70 separate funds and then disperse them among 122 worthy grant recipients within one year is no simple task for a voluntary board and staff of only 3 dedicated people. It is to their credit that they are able to achieve as much as they do with absolute minimal operating costs. And it is because all those involved with DCF, the profession's oral health charity, share the responsibility to the profession, that donors, recipients, the public — everyone — is fully and completely aware of **where all the money goes.**

**For more details about this transformational campaign, please contact Stephanie MacWhirter, Campaign Director, toll-free at 1.877.363.0326**

*\*Trademark of the Canadian Dental Association; used with permission.*

# New Philips Sonicare FlexCare



Clinically proven to remove more interproximal and overall plaque biofilm than Oral-B Triumph<sup>1</sup> and Sonicare Elite<sup>4</sup>

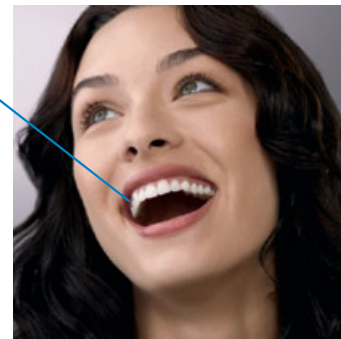New personalised care settings

Gentler on dentin<sup>2\*†</sup>

New vibration-cancelling system for 80% less vibration<sup>‡</sup>

New ProResults brush head with broader sweeping motion and contour fit bristles for increased tooth coverage

Clinically proven to significantly improve gum health in only 2 weeks<sup>3</sup>



## Simplicity is more than a brush, it's superior oral health.

**Introducing FlexCare.** Our most advanced sonic technology combined with the new ProResults brush head makes brushing even more effective for you and your patients.

To order your new FlexCare trial unit contact your Sonicare representative on 1-800-676-SONIC (7664).

[www.sonicare.com](http://www.sonicare.com)

**PHILIPS**  
**sonicare**  
the sonic toothbrush

<sup>\*</sup>In vitro study

<sup>†</sup>Compared with Oral-B Triumph <sup>‡</sup>Compared with Sonicare Elite

**References:** 1. Schaeken M, Sturm D, Master A, Jenkins W, Schmitt P. Data on file, 2007. 2. De Jager M, Nelson R, Schmitt P, Moore M, Putt MS, Kunzelmann KH, Nyamaa I, Garcia-Godoy F, Garcia-Godoy C. Data on file, 2007. 3. Holt J, Sturm D, Master A, Jenkins W, Schmitt P, Hefti AF. Data on file, 2007. 4. Milleman J, Pitt MS, Strum M, Master A, Jenkins W, Schmitt P, Hefti AF. Data on file, 2007.

**PHILIPS**  
sense and simplicity

## Resources for the Dental Office

*CDA's Resource Centre offers a full range of services to meet members' clinical, practice management and oral health research needs. This article is part of an occasional series to help better inform readers on topics of interest by providing answers to actual questions posed to the Resource Centre. If you have a topic you would like the CDA Resource Centre to address, email your question to [library@cda-adc.ca](mailto:library@cda-adc.ca).*

In the online age, it is tempting to assume that all knowledge can be found on the Internet. While there are many very useful dental and medical resources online, print books still prevail as an easily accessible way to answer some of the various questions encountered in a dental practice. The CDA Resource Centre has put together a bibliography of some must-have resources on topics that would apply to any dental office. Most dental practitioners probably have some old, dusty textbooks lying around, but keep in mind these resources may be outdated or there may be some gaps in your collection. Having an up-to-date reference collection at your clinic will provide resources for you and your staff to help you deal with any question or situation that may arise.

### **Anatomy**

- Brand RW, Isselhard DE. *Anatomy of orofacial structures*. 7th ed. St. Louis: Mosby; 2003.

Standard anatomy textbook used in most dental schools. Features workbook questions and line-drawn illustrations. Provides a solid overview of dental anatomy, oral histology, embryology, and head and neck anatomy.

- Liebgott B. *The anatomical basis of dentistry*. 2nd ed. St. Louis: Mosby; 2001.

General anatomy textbook with line-colour illustrations and photographs. While the text covers full body anatomy, it also includes extensive chapters devoted to the neck, skull and regions of the head. Provides clinical notes throughout the text regarding common ailments and problems.

### **Anesthesiology**

- Clark MS, Brunick AL. *Handbook of nitrous oxide and oxygen sedation*. 2nd ed. St. Louis: Mosby; 2003.

An excellent resource for any health care practitioner treating patients under sedation. Provides practice guidelines for the use of nitrous oxide and oxygen sedation, scientific principles, clinical indications and practical techniques in administration of nitrous oxide and oxygen sedation. Also provides details on the use of nitrous oxide and oxygen sedation when treating children.

- Malamed SF. *Sedation: a guide to patient management*. 4th ed. St. Louis: Mosby; 2003.

A classic and well-rounded textbook that looks at the various elements of sedation within a dental practice. Examines fear and anxiety surrounding dental visits, as well as the various options for pain and anxiety control, including non-drug treatment. Provides details on the different means of administration, including pharmacosedation, general anesthesia, inhalation and intravenous sedation.

### **Infection Control**

- Petty TL, Canadian Dental Association. *Infection prevention and control in the dental office: an opportunity to improve safety and compliance*. Ottawa: Canadian Dental Association; 2006.

The official CDA guidelines for infection control and prevention. This exhaustive guide covers topics including personnel health, sterilization and disinfection of patient care items and environmental infection control. Available to CDA members and non-members. Order your copy at: [www.cda-adc.ca/en/dental\\_profession/practising/resources/infection\\_control.asp](http://www.cda-adc.ca/en/dental_profession/practising/resources/infection_control.asp)

### **Critical Care and Emergencies**

- Malamed SF. *Medical emergencies in the dental office*. 6th ed. St. Louis: Mosby; 2007.

Well-written and thorough book regarding emergency situations in the dental office. Suitable for all staff. Examines prevention of emergencies, unconsciousness, respiratory distress, altered consciousness, seizures, drug-related emergencies, chest pain and cardiac arrest.

**Dictionaries and Handbooks**

- Mosby's dental dictionary. 2nd ed. St. Louis: Mosby; 2008.

A medical dictionary is an essential resource for any collection and this one focuses on dentistry. Mosby's recently updated non-illustrated dental dictionary provides a good basis for dental terminology.

- Da Silva JD, Mitchell DA, Mitchell L. Oxford American handbook of clinical dentistry. New York: Oxford University Press; 2008.

Concise, comprehensive and affordable, this handbook is designed as an ultra-quick reference

book for clinical dentistry. Suitable for dental students, trainees, researchers and for more experienced generalists who wish to keep up-to-date. Includes chapters on practice management, medicine relevant to dentistry and pediatric dentistry.

**Drug guides**

- LEXI-COMP® Online™, CDA Edition (<http://www.cda-adc.ca/lexi>)

While there are many different print drug guides, we recommend LEXI-COMP® Online™, CDA Edition, available to CDA members. Users have access to 2 Lexi-Comp databases, Lexi-Drugs® and Lexi-Natural Products™ — all updated daily. Also includes customizable patient advisory leaflets for adult and pediatric patients. Print documentation simply doesn't compare to this online service's ease of use, comprehensiveness and accuracy. ➤

*Danielle Waytowich is acting information specialist at the Canadian Dental Association.*

Enjoy Continuing Dental Education While on Vacation on Celebrity's Newest Ship!  
**THE CELEBRITY SOLSTICE**

Prepare to be dazzled as the maiden ship of the Solstice Class unveils a vacation experience unparalleled at sea or elsewhere. Discover a refined level of elegance – an unrivaled experience making a distinctive statement of style and design.

REGISTRATION FEES \$350.00 per person. Early bird registration before November 20, 2008 save 25%.

**SEMINARS INCLUDE:**

- Hiring for Success and Keeping the Good Ones  
Human Resources Management Workshop
- Recession Proof Your Practice  
Financial Benchmarks for a Successful Practice
- Strategic Business Systems for Increased Case Acceptance

Sandie Baillargeon is a leading authority on how to increase the effectiveness of medical and dental business systems. Ms. Baillargeon is author of two text books, Dental Office Administration and The Canadian Dental Office Administrator, published by ITP Nelson Canada. Sandie is the owner and operator of Dental Office Consulting Services, which specializes in dental business planning, staff development, consulting and continuing education seminars. Visit her website at [www.dentalofficeconsulting.com](http://www.dentalofficeconsulting.com).

**DATES: February 15 – 22, 2009**

**CRUISE PORTS**  
Fort Lauderdale Florida  
San Juan, Puerto Rico  
Philipsburg, St. Maarten  
Tortola, B.V.I.  
Labadee, Haiti  
Fort Lauderdale, Florida



Registration for courses, visit my website at [www.dentalofficeconsulting.com](http://www.dentalofficeconsulting.com) or EMAIL [tim@dentalofficeconsulting.com](mailto:tim@dentalofficeconsulting.com) or CALL 905.336.7624.

For travel and accommodations contact [pramsbottom@cruseshipcenters.com](mailto:pramsbottom@cruseshipcenters.com).



Sandie Baillargeon, Dental Office Consulting Services has been designated an approved Program Provider of the Academy of General Dentistry. All formal CDE programs are accepted by the AGD for membership maintenance, Fellowship and Mastership credits.





## It Could Happen to You

A disabling illness or injury can strike anyone at any time. That's why it's important to protect yourself and your family with adequate disability insurance for your income — and to choose a disability plan that offers specialized coverage.

The **Long Term Disability (LTD) Insurance** plan sponsored by the CDA provides back-to-work assistance and features you won't always find in other plans, including HIV and Hepatitis B and C coverage — *at no extra cost*. You may also qualify for more LTD coverage even if your income is unchanged.

To get coverage that's right for you, speak to an insurance advisor who understands dentists best.

**1-877-293-9455 ext. 5002**

*to reach a licensed advisor at CDSPI Advisory Services Inc.*

**CDSPI**

D E N T I S T S F I R S T

*The Long Term Disability Insurance plan is a member benefit of the CDA and co-sponsoring provincial dental associations and is administered by CDSPI. The plan is underwritten by The Manufacturers Life Insurance Company (Manulife Financial).*

# A Customized Portfolio Offers a Wealth of Advantages

By **Ron Haik**, MBA, CFP, FMA

**W**hen your financial situation becomes more complex, you need higher-level tax and financial planning advice. In fact, if you have assets over \$1 million and multiple investment portfolios, including non-registered, registered and in-trust accounts, or an incorporated dental practice, it may no longer be desirable or feasible for you to manage your portfolios on your own.

As a dentist and CDA member, you can now gain access to new private wealth management services offering distinct advantages such as custom-built portfolios of individual securities and investments that are tailored to your specific risk tolerance and tax situation. What may surprise you is that these personalized, portfolio-management services are available at a lower average percentage cost than you would typically pay for fee-based trading programs and non-customized, pooled investments such as mutual funds. It's a huge advantage that allows more of your investment returns to remain in your portfolio.

Do you want the opportunity to deduct your investment counselling fees against the returns earned on your non-registered portfolio? Are you planning to realize a capital gain on your business assets and would therefore like to minimize the gains realized on your other investment assets? Do you want portfolio reporting that uses a year-end other than December 31st? Would you like to invest in real estate or equity investments that aren't traded publicly? All of this and much more is possible with the private wealth management service.

Unlike a mutual fund portfolio where the portfolio manager is not aware of your individual financial objectives, with a customized portfolio, the manager knows your risk tolerance, investment goals and preferred tax situation, and buys and sells investments with these objectives in mind.

Through the service, your designated portfolio manager will advise you about the investments that are appropriate for your stated financial and tax objectives, select the investments, handle all the portfolio decision-making and provide updates through transaction confirmations, monthly account statements, quarterly portfolio valuations and regular meetings. Your portfolio will be monitored and rebalanced regularly so it stays in line with

your predetermined asset allocation and your investment policy statement — a blueprint detailing your financial situation and objectives. Portfolio management fees are very competitively priced, based on a percentage of the asset value of your portfolio.

With a customized portfolio, you'll obtain the peace of mind that comes from knowing that your investments are being selected and managed by highly qualified professionals according to your specific objectives. You'll also gain time to focus on your other life goals such as travel, pastimes, new business ventures or simply spending more time with your family. To learn more about the new private wealth management service, contact a certified financial planner at CDSPI Advisory Services Inc. at **1-877-293-9455, extension 5023**. (Restrictions may apply to advisory services in certain jurisdictions.)

## THE AUTHOR



*Mr. Haik is a senior investment planning advisor at CDSPI Advisory Services Inc.*

## Your Company, Your Choice

CDSPI truly is *your* company.

The Canadian Dental Association is one of our members. And the insurance and investment programs we administer as CDA member benefits are designed specifically with dentists in mind.

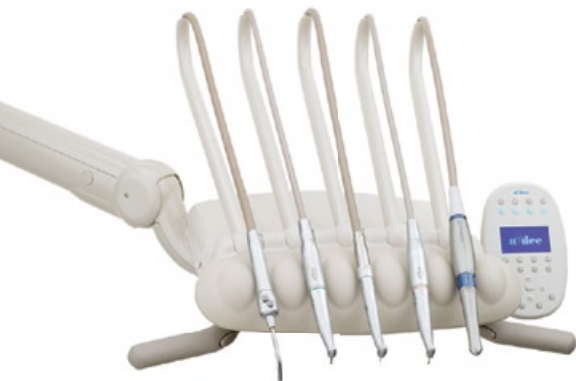**1-800-561-9401**    **www.cdspi.com**



08-326 01/08



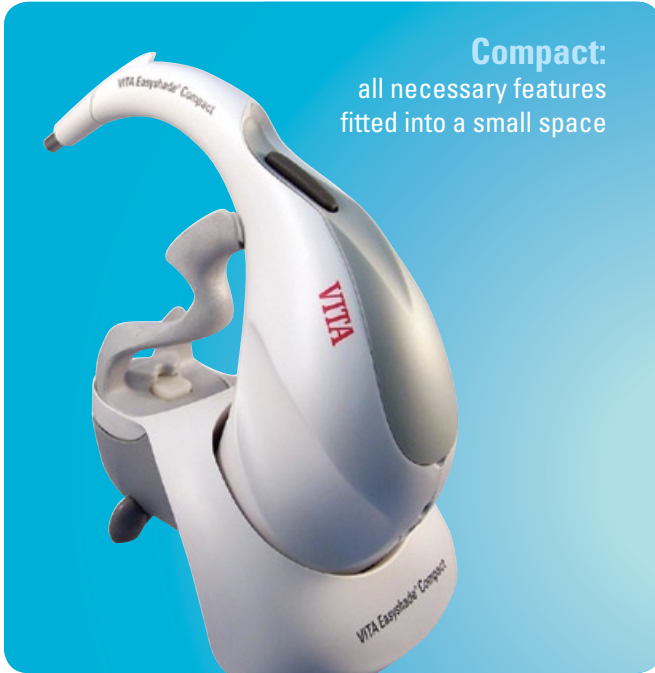# Indulge Your Senses



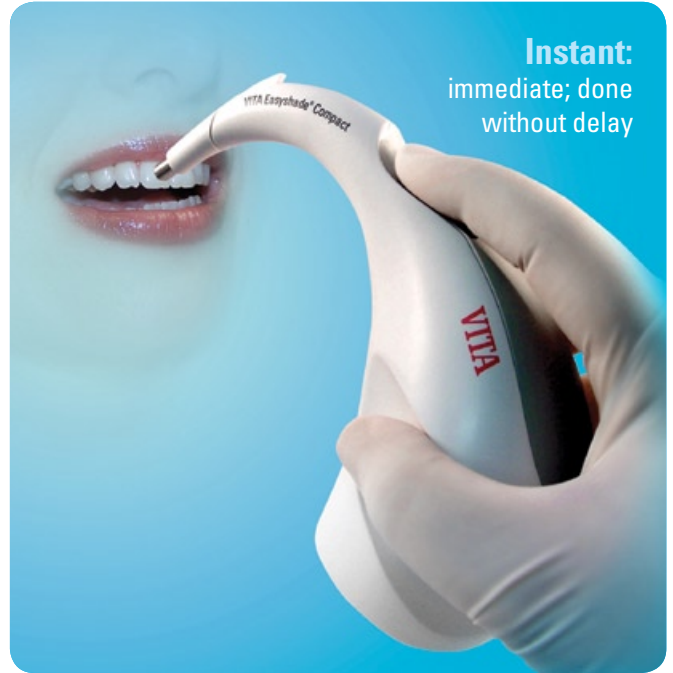The moment you pick up the new Synea highspeed handpiece, your senses are in for a treat. You feel it in your hand—wonderfully lightweight and balanced. Then there's the light. Synea is the first highspeed handpiece to feature LED technology, which offers daylight quality illumination and a superior light pattern. Add the innovative Penta Spray system and incredibly small head, and you'll marvel at all you can see.

To find out how much your senses will love Synea, contact your local authorized A-dec dealer, call 1.800.547.1883 or visit us online at [www.a-dec.com](http://www.a-dec.com).

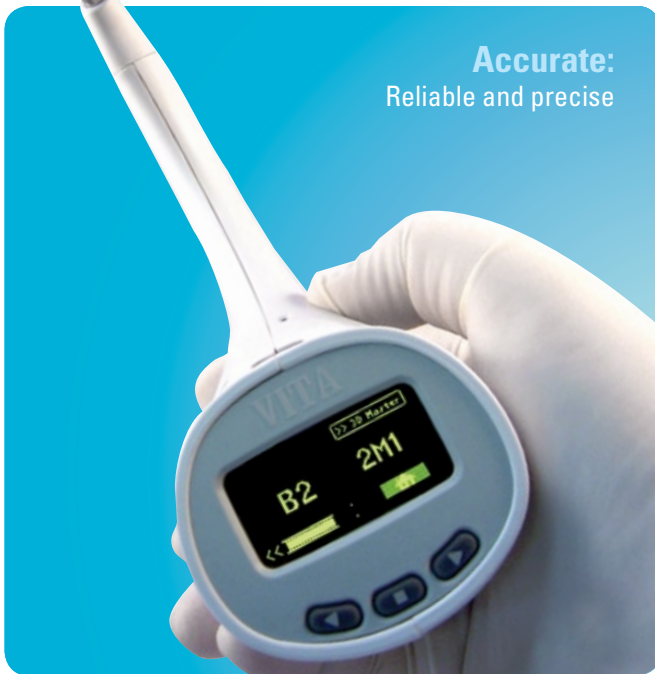# Instant Shade Control in the Palm of Your Hand



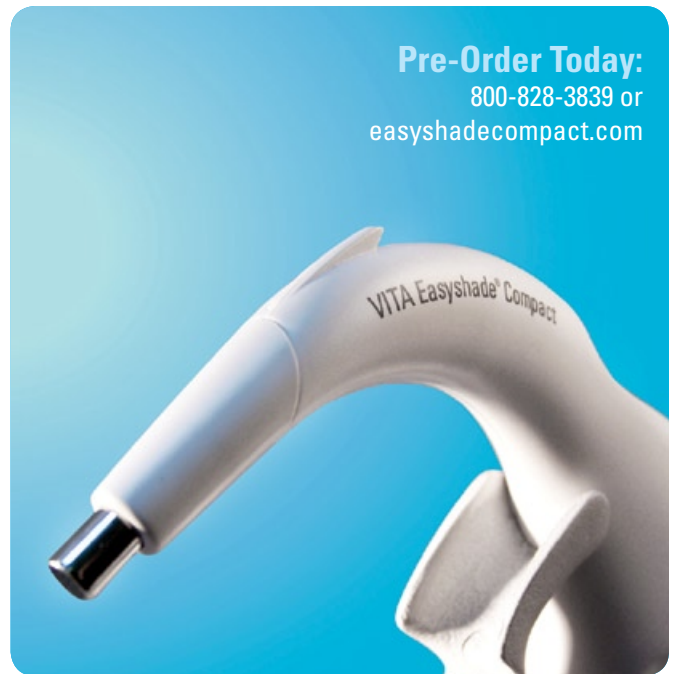**Compact:**  
all necessary features  
fitted into a small space



**Instant:**  
immediate; done  
without delay



**Accurate:**  
Reliable and precise



**Pre-Order Today:**  
800-828-3839 or  
[easysshadecompact.com](http://easysshadecompact.com)

## VITA Easyshade® Compact



# VITA®

Cordless, sleek and incredibly fast. The all-new VITA Easyshade Compact delivers the fastest, easiest way to measure tooth shades under any lighting condition. Easyshade Compact gives you the ability to conquer the trickiest shade challenges all

day, every day, instantly and accurately. Now you can measure natural teeth, check restoration shades and track bleaching progress with the push of a button. Order today and instantly prescribe over 97 VITA 3D-Master® and Classical shades.

[www.easysshadecompact.com](http://www.easysshadecompact.com)

©Vident 2008. 3D-Master and Easyshade are registered trademarks of VITA Zahnfabrik.

800-263-4778



JCDA is collaborating with the Canadian Cochrane Network and Centre to reprint abstracts from selected Cochrane Reviews. In this instalment, JCDA has chosen 2 systematic reviews from the Cochrane Oral Health Group. The abstracts are printed without modification.

The Cochrane Library is considered the best single source of the highest quality research studies and current evidence on clinical treatments. CDA purchased a licence in 2007 that grants all CDA members full access to the complete Cochrane Library (see [www.cda-adc.ca/cochrane](http://www.cda-adc.ca/cochrane)).

Cochrane Reviews are regularly updated as new evidence emerges. The Cochrane Library should be consulted for the most recent version of reviews. The current status of all oral health-related reviews can be found on the Cochrane Oral Health Group's website at [www.ohg.cochrane.org/reviews.html](http://www.ohg.cochrane.org/reviews.html).

## ABSTRACT

### Interventions for replacing missing teeth: bone augmentation techniques for dental implant treatment

#### Background

Dental implants require sufficient bone to be adequately stabilized. For some patients implant treatment would not be an option without bone augmentation. A variety of materials and surgical techniques are available for bone augmentation.

#### Objectives

General objectives: To test the null hypothesis of no difference in the success, function, morbidity and patient satisfaction between different bone augmentation techniques for dental implant treatment. Specific objectives: (A) to test whether and when augmentation procedures are necessary; (B) to test which is the most effective augmentation technique for specific clinical indications. Trials were divided into three broad categories according to different indications for the bone augmentation techniques: (1) major vertical or horizontal bone augmentation or both; (2) implants placed in extraction sockets; (3) fenestrated implants.

#### Search strategy

The Cochrane Oral Health Group's Trials Register, the Cochrane Central Register of Controlled Trials (CENTRAL), MEDLINE and EMBASE were searched. Several dental journals were hand-searched. The bibliographies of review articles were checked, and personal references were searched. More than 55 implant manufacturing companies were also contacted. Last electronic search was conducted on 9th January 2008.

#### Selection criteria

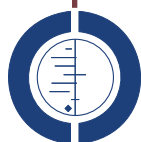
Randomized controlled trials (RCTs) of different techniques and materials for augmenting bone for implant treatment reporting the outcome of implant therapy at least to abutment connection.

#### Data collection and analysis

Screening of eligible studies, assessment of the methodological quality of the trials and data extraction were conducted independently and in duplicate. Authors were contacted for any missing information. Results were expressed as random-effects models using mean differences for continuous outcomes and odd ratios for dichotomous outcomes with 95% confidence intervals. The statistical unit of the analysis was the patient.

#### Main results

Seventeen RCTs out of 40 potentially eligible trials reporting the outcome of 455 patients were suitable for inclusion. Since different techniques were evaluated in different trials, no meta-analysis could be performed. Ten trials evaluated different techniques for vertical or horizontal bone augmentation or both. Four trials evaluated different techniques of bone grafting for implants placed in extraction sockets and three trials evaluated different techniques to treat bone dehiscence or fenestrations around implants.



### Authors' conclusions

Major bone grafting procedures of resorbed mandibles may not be justified. Bone substitutes (Bio-Oss or Cerasorb) may replace autogenous bone for sinus lift procedures of atrophic maxillary sinuses. Various techniques can augment bone horizontally and vertically, but it is unclear which is the most efficient. It is unclear whether augmentation procedures at immediate single implants placed in fresh extraction sockets are needed, and which is the most effective augmentation procedure, however, sites treated with barrier plus Bio-Oss showed a higher position of the gingival margin when compared to sites treated with barriers alone. Non-resorbable barriers at fenestrated implants regenerated more bone than no barriers, however it remains unclear whether such bone is of benefit to the patient. It is unclear which is the most effective technique for augmenting bone around fenestrated implants. Bone morphogenetic proteins may enhance bone formation around implants grafted with Bio-Oss. Titanium may be preferable to resorbable screws to fixate onlay bone grafts. The use of particulate autogenous bone from intraoral locations, also taken with dedicated aspirators, might be associated with an increased risk of infective complications. These findings are based on few trials including few patients, sometimes having short follow up, and often being judged to be at high risk of bias.

---

### Plain language summary

Some patients have insufficient bone to place dental implants but there are many surgical techniques to increase the bone volume making implant treatment possible.

Short implants are more effective and cause less complications than conventional implants placed in thin lower jaws (mandibles) augmented with bone from the hip. Bone substitutes (Bio-Oss or Cerasorb) might be used instead of self generated (autogenous) bone graft to fill large upper jaw (maxillary) sinuses. Bone can be regenerated in a vertical direction using various techniques, but it is unclear which technique is preferable. There is not enough evidence supporting or refusing the need of augmentation procedures when single extracted teeth are immediately replaced with dental implants, nor is it known whether any augmentation procedure is better than the others. There is not enough evidence to demonstrate superiority of any particular technique for regenerating bone around exposed implants, however the use of bone morphogenetic proteins may enhance bone formation.

---

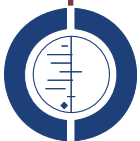
Esposito M, Grusovin MG, Kwan S, Worthington HV, Coulthard P. Interventions for replacing missing teeth: bone augmentation techniques for dental implant treatment. *Cochrane Database of Systematic Reviews* 2008, Issue 2. Art. No.: CD003607. DOI: 10.1002/14651858.CD003607.pub3

## ABSTRACT

### Interventions for replacing missing teeth: antibiotics at dental implant placement to prevent complications

#### Background

Some dental implant failures may be due to bacterial contamination at implant insertion. Infections around biomaterials are difficult to treat and almost all infected implants have to be removed. In general, antibiotic prophylaxis in surgery is only indicated for patients at risk of infectious endocarditis, for patients with reduced host-response, when surgery is performed in infected sites, in cases of extensive and prolonged surgical interventions and when large foreign materials are implanted. To minimize infections after dental implant placement various prophylactic systemic antibiotic regimens have been suggested. More recent protocols recommended short term prophylaxis, if antibiotics have to be used. With the administration of antibiotics adverse events may occur, ranging from diarrhoea to life-threatening allergic reactions. Another major concern associated with the widespread use of antibiotics is the selection of antibiotic-resistant bacteria. The use of prophylactic antibiotics in implant dentistry is controversial.



## Objectives

To assess the beneficial or harmful effects of systemic prophylactic antibiotics at dental implant placement versus no antibiotic/placebo administration and, if antibiotics are of benefit, to find which type, dosage and duration is the most effective.

## Search strategy

The Cochrane Oral Health Group's Trials Register, the Cochrane Central Register of Controlled Trials (CENTRAL), MEDLINE and EMBASE were searched up to 9th January 2008. Several dental journals were handsearched. There were no language restrictions.

## Selection criteria

Randomized controlled clinical trials (RCTs) with a follow up of at least 3 months comparing the administration of various prophylactic antibiotic regimens versus no antibiotics to patients undergoing dental implant placement. Outcome measures were prosthesis failures, implant failures, post-operative infections and adverse events (gastrointestinal, hypersensitivity, etc.).

## Data collection and analysis

Screening of eligible studies, assessment of the methodological quality of the trials and data extraction were conducted in duplicate and independently by two review authors. Results were expressed as random-effects models using risk ratios (RRs) for dichotomous outcomes with 95% confidence intervals (CIs). Heterogeneity was to be investigated including both clinical and methodological factors.

## Main results

Two RCTs were identified: one comparing 2 g of preoperative amoxicillin versus placebo (316 patients) and the other comparing 2 g of preoperative amoxicillin plus 500 mg 4 times a day for 2 days versus no antibiotics (80 patients). The meta-analyses of the two trials showed a statistically significant higher number of patients experiencing implant failures in the group not receiving antibiotics: RR = 0.22 (95% CI 0.06 to 0.86). The number needed to treat (NNT) to prevent one patient having an implant failure is 25 (95% CI 13 to 100), based on a patient implant failure rate of 6% in patients not receiving antibiotics. The other outcomes were not statistically significant, and only two minor adverse events were recorded, one of which in the placebo group.

## Authors' conclusions

There is some evidence suggesting that 2 g of amoxicillin given orally 1 hour preoperatively significantly reduce failures of dental implants placed in ordinary conditions. It remains unclear whether postoperative antibiotics are beneficial, and which is the most effective antibiotic. It might be recommendable to suggest the use of one dose of prophylactic antibiotics prior to dental implant placement.

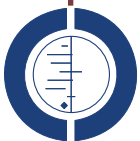
---

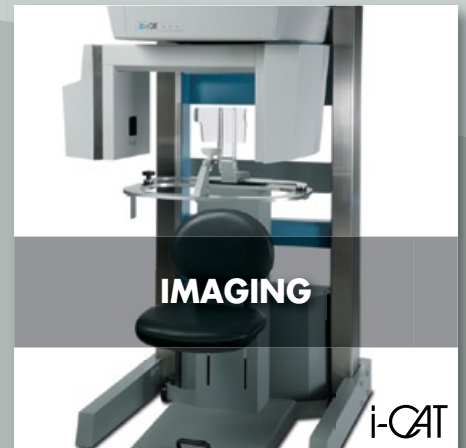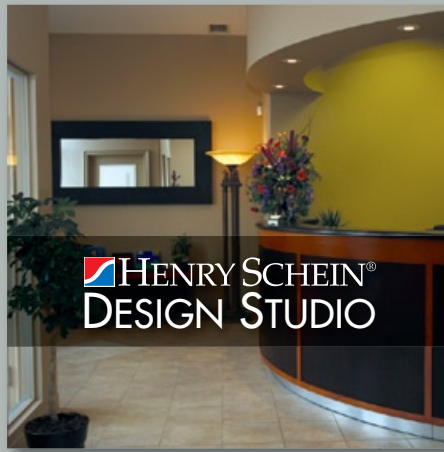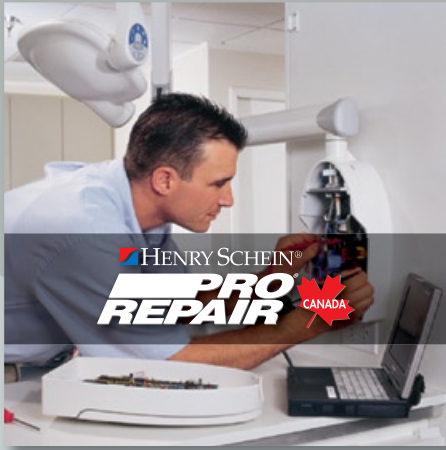## Plain language summary

Missing teeth can sometimes be replaced with dental implants to which a crown, bridge or denture can be attached. Bacteria introduced during placement of implants can lead to infection and sometimes implant failure. It appears that the oral administration of 2 grams of amoxicillin 1 hour before placement of dental implants is effective in reducing implant failures. More specifically, giving antibiotics to 25 patients will avoid one patient experiencing early implant losses. It is still unclear whether postoperative antibiotics are of any additional benefits.

---

Esposito M, Grusovin MG, Talati M, Coulthard P, Oliver R, Worthington HV. Interventions for replacing missing teeth: antibiotics at dental implant placement to prevent complications. *Cochrane Database of Systematic Reviews* 2008, Issue 2. Art. No.: CD004152. DOI: 10.1002/14651858.CD004152.pub2





**HENRY SCHEIN®** 

Your Total Solution Provider

1-800-668-5558 | [www.henryschein.ca](http://www.henryschein.ca)



# Use of Porcelain Veneers, Crowns and an Implant to Resolve an Esthetic Problem

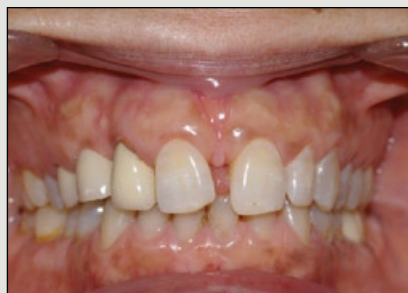Omar El-Mowafy, BDS, PhD, FADM

*“Clinical Showcase” is a series of pictorial essays that focus on the technical art of clinical dentistry. The section features step-by-step case demonstrations of clinical problems encountered in dental practice. If you would like to propose a case or recommend a clinician who could contribute to this section, contact editor-in-chief Dr. John O’Keefe at [jokeefe@cda-adc.ca](mailto:jokeefe@cda-adc.ca).*

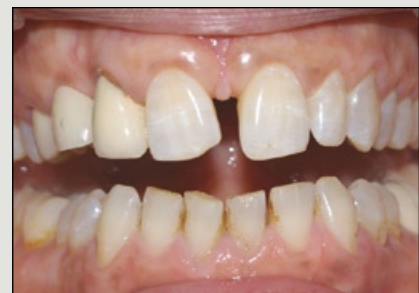A 51-year-old woman who worked as a company sales representative was concerned about the deteriorating condition of her anterior teeth. On presentation, the appearance of her anterior teeth was less than ideal, and she requested treatment to improve the situation. Her medical history was non-contributory, but intraoral examination revealed excessive diastema between the maxillary central incisors (Fig. 1). The maxillary right central incisor had an incisal edge fracture at the mesial side and appeared mesially tilted. The maxillary right lateral incisor was acting as an abutment for a fixed partial denture (FPD). The retainer on this tooth was out of ideal positioning, and its colour did not match that of the adjacent teeth, perhaps because of opacity of the underlying metallic core (Fig. 2). The maxillary

right canine was missing, and the pontic component of the 3-unit FPD that replaced it looked shorter than the lateral incisor and had a flattened incisal edge (Fig. 3). Further examination of the maxillary left anterior side revealed that the 3 anterior teeth were discoloured and the incisal edge of the central incisor was worn down at a slant (Fig. 4).

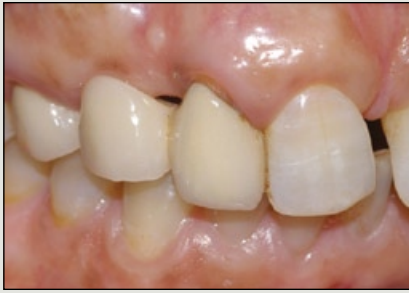Lingual examination revealed the unsightly appearance of the metallic framework of the 3-unit porcelain-fused-to-metal FPD (Fig. 5). Prior endodontic treatment of the maxillary lateral incisor had been performed through the FPD retainer and the access opening had been sealed with resin composite. Part of the veneering porcelain on the distal aspect of the premolar retainer had fractured, and the remaining anterior teeth had dark extrinsic staining.



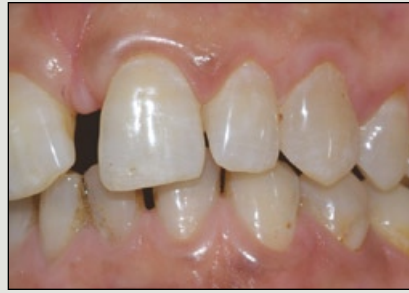**Figure 1:** Intraoral view of a 51-year-old woman shows excessive diastema between the maxillary central incisors. The maxillary right central incisor has an incisal fracture at the mesial side and appears mesially tilted. The maxillary right lateral incisor is acting as an abutment for a fixed partial denture (FPD).



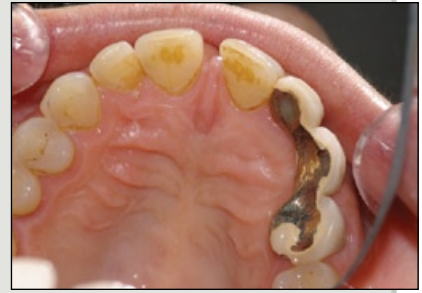**Figure 2:** The retainer on the maxillary right lateral incisor is out of ideal positioning, and the colour of the tooth does not match that of adjacent teeth. In the open position, the fracture on the incisal edge of the maxillary central incisor is more obvious. Staining of the lower incisors adds to the esthetic problem.



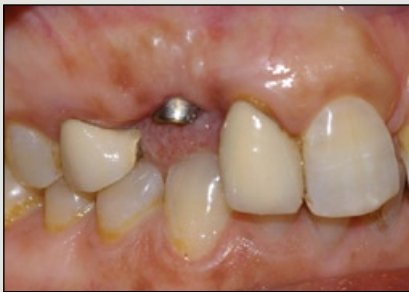**Figure 3:** Close-up view of the maxillary right side. The canine, which is the pontic part of a 3-unit FPD, appears significantly shorter than the lateral incisor and has a flattened incisal edge.



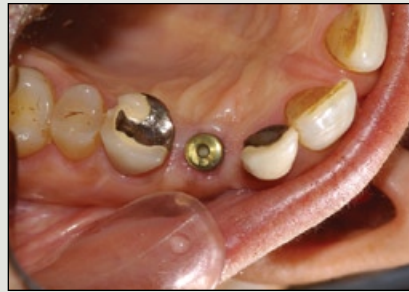**Figure 4:** Close-up view of the maxillary left anterior side. The teeth are discoloured, and the incisal edge of the central incisor is worn down at a slant.



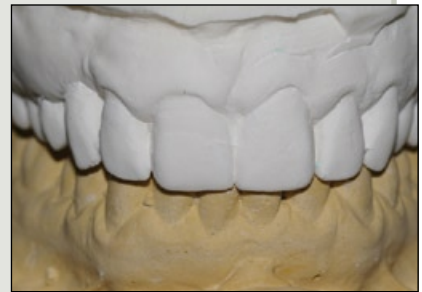**Figure 5:** Lingual view of the maxillary anterior area. The lingual aspect of the 3-unit FPD shows the unsightly appearance of the metallic framework. Prior endodontic treatment of the maxillary lateral incisor had been performed through the FPD retainer, and the access opening had been sealed with resin composite. In addition, part of the veneering porcelain on the distal aspect of the retainer on the first premolar had fractured.



**Figure 6:** The pontic of the FPD was severed, and an implant was inserted into the space. This view shows the healing cap.



**Figure 7:** The retainers of the FPD were left in place on the maxillary lateral incisor and the first premolar throughout the healing period for the inserted implant.



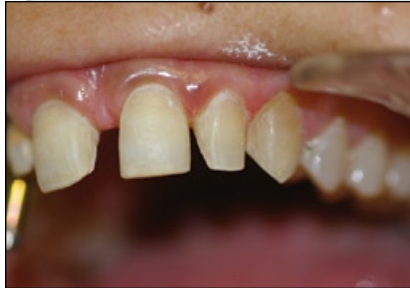**Figure 8:** A diagnostic wax-up was made and duplicated in stone. The duplicate stone model was used for fabrication of a clear matrix with a vacuum moulding machine.

The patient reported dissatisfaction with the FPD, both in terms of its appearance and because she was unable to properly floss between the teeth. Although the diastema between the 2 maxillary central incisors had been present for many years, she had noticed that her teeth were drifting, the diastema was increasing in size and the colour of the teeth was becoming darker.

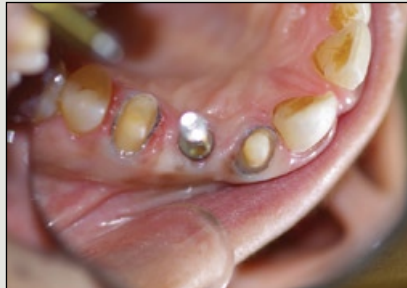Because the patient had full posterior support without edentulous spaces in the posterior region, the drifting of the anterior teeth was most likely due to the congenital absence of tooth 13, the large diastema between the 2 central incisors and the patient's age.

### Treatment Plan

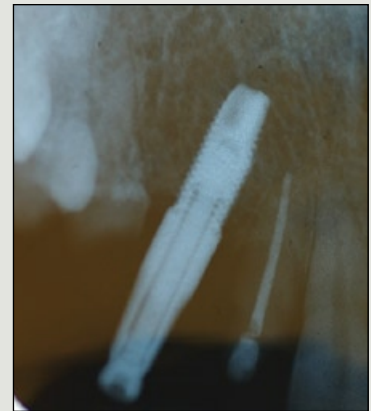After study models had been prepared and radiographic images of the anterior teeth and digital intraoral photographs had been examined, a treatment plan was designed to address the patient's concerns. Various treatment approaches were considered, including one that would have involved orthodontic movement of the anterior teeth with a fixed appliance; however, the patient was more interested in alternative approaches that would be less time-consuming. The one she selected involved removal of the existing 3-unit FPD and replacement with an implant-supported porcelain crown in the maxillary right canine location. The current



**Figure 9:** Four maxillary anterior teeth were prepared to receive porcelain veneers.



**Figure 10:** At the impression-taking stage, the implant healing cap was removed and the transfer coping secured in place. A retraction cord was placed in the sulci of the other prepared teeth.



**Figure 11:** A periapical radiograph was obtained to ensure that the transfer coping had been properly seated onto the implant before the impression was taken.

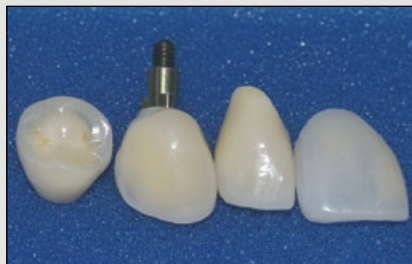high success rate of implants warrants their use for routine clinical conditions, such as this one.<sup>1</sup> Under the treatment plan, both the maxillary right lateral incisor and the maxillary first premolar, which had originally acted as abutments for the FPD with porcelain-fused-to-metal retainers, were to receive all-porcelain crowns. Reported success rates for this type of crown in the anterior region of the mouth have been high.<sup>2-4</sup> The remaining anterior teeth were to receive porcelain veneers to close the diastema between the 2 central incisors, to correct the alignment and shape of the 2 central incisors, and to ensure uniform colour for all of the anterior teeth. The technique for applying porcelain veneer was originally introduced by Dr. John Calamia in 1985 and has yielded reliable and long-lasting results.<sup>5</sup>

The periodontal health of the involved teeth was within normal limits, except for the maxillary right lateral incisor, which had suffered some bone loss and had increased periodontal pocket depth. However, the results of previous endodontic treatment of this tooth were satisfactory and stable. The patient was informed of the periodontal condition of this tooth and was told that if its condition deteriorated to the point that extraction was warranted, the implant-supported crown that was to be made for the tooth 13 location could later be replaced with a cantilevered FPD supported on the same implant and replacing both teeth 12 and 13.

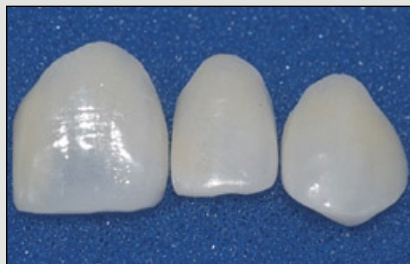### Treatment Phase

The FPD pontic was severed, and an implant (NobelReplace Straight Groovy, Nobel Biocare, Gothenburg, Sweden) was inserted into the maxillary right canine location (Figs. 6 and 7). After healing was complete, a new maxillary stone model was made and a diagnostic wax-up constructed. The diagnostic wax-up was then duplicated in stone (Fig. 8). This stone model was used to show the patient the expected final shape of the teeth. It was also used for fabrication of a matrix to be used for making provisional restorations.

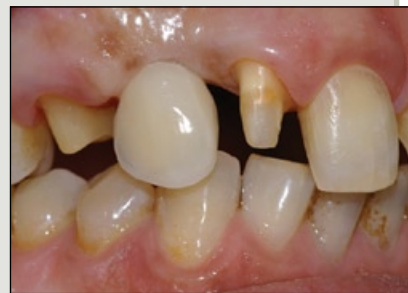Following successful osseointegration of the implant, the FPD retainers on the maxillary right lateral incisor and the first premolar were removed. These 2 teeth were re-prepared to receive porcelain crowns, and the maxillary left central and lateral incisors and the maxillary left canine were prepared to receive porcelain veneers (Fig. 9). The healing cap was removed from the implant and a matching transfer coping was placed. A retraction cord was placed into the gingival sulci of the other prepared teeth to expose the preparation margins for accurate impression-taking (Fig. 10). A radiograph was obtained to ensure proper seating of the transfer coping onto the implant (Fig. 11). An impression was taken in a silicon material using the closed-tray technique, after which ceramic crowns with zirconium oxide cores and matching veneering porcelain were made for the lateral incisor



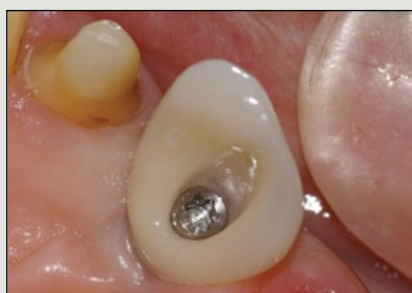**Figure 12:** Two ceramic crowns and an implant-supported crown and porcelain veneer for the right maxillary central and lateral incisors, canine and first premolar. The difference in colour between the veneer and the crowns relates to the minimal thickness of the veneer.



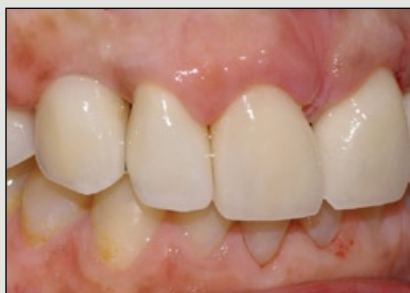**Figure 13:** Porcelain veneers for the maxillary left central and lateral incisors and the left maxillary canine.



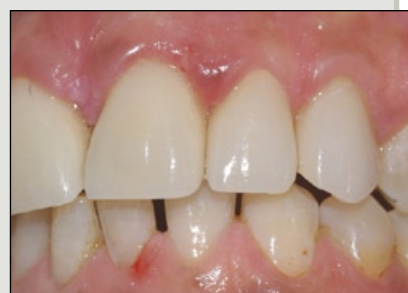**Figure 14:** The implant-supported crown was the first to be inserted.



**Figure 15:** The implant screw was torqued with a manual torque wrench before the opening was closed with a composite resin.



**Figure 16:** The ceramic crowns of the maxillary lateral incisor and first premolar were cemented with a resin cement. Restoration of the anatomic features of the teeth, as shown here, is key to achieving a natural, pleasing smile.

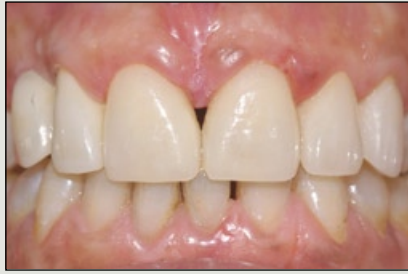

**Figure 17:** An appropriate shade of resin cement was selected and used to secure the 4 porcelain veneers.

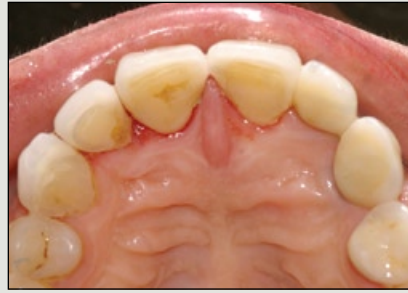and the first premolar (Procera Crown Zirconia, Nobel Biocare) (Fig. 12). An implant abutment made of zirconium oxide and matching the size of the inserted implant was veneered with matching porcelain (Procera Abutments, Nobel Biocare). For the remaining 4 prepared teeth, porcelain veneers were fabricated using matching feldspathic porcelain (Fig. 13).

The implant-supported crown was the first restoration to be inserted (Fig. 14). After the crown was secured with a manual wrench, a radiograph was taken to ensure proper seating. The screw was then torqued to 35 N with a manual torque wrench (Nobel Biocare) (Fig. 15). The access hole was then sealed with a composite resin. The remaining 2 ceramic crowns were cemented with a dual-cured self-adhesive resin cement (Breeze, Pentron, Wallingford, Conn.) (Fig. 16), the ce-

ment of choice for ceramic restorations.<sup>6,7</sup> It was important to insert the 3 crowns first so that the final colour of all restorations could be established. The colour of the porcelain veneers could then be matched to the colour of the crowns by choosing an appropriate shade of resin cement (Fig. 17). A postoperative facial view (Fig. 18) shows how the colour of the veneers blends nicely with the colour of the crowns. The dimensional relation between the right central and lateral incisors is now ideal, the lateral tooth being shorter by 2 mm than the central incisor, unlike the preoperative situation (see Fig. 1), in which the 2 teeth were at the same level. However, it was impossible to completely close the diastema because of the excessive space between the 2 central incisors. Attempting to completely close the space would have made these 2 teeth appear wide, short and artificial. A lingual



**Figure 18:** Immediate postoperative view. The colour of the veneers blends nicely with that of the crowns. This match was achieved by selecting the most appropriate shade of resin cement.



**Figure 19:** Lingual view of the maxillary anterior region. The appearance of the right side has been improved dramatically by using 3 crowns to replace the porcelain-fused-to-metal FPD.

postoperative view (**Fig. 19**) shows a dramatic improvement in the appearance of the teeth on the right side after replacement of the conventional porcelain-fused-to-metal FPD with 3 crowns.

### Conclusion

An esthetic problem created by several clinical conditions (namely, excessive diastema, tooth drifting, rotation, discoloration and failure of an FPD) was resolved by strategic use of esthetic non-metallic porcelain-and-ceramic restorations and one implant-supported crown. ✦

### THE AUTHOR



*Dr. El-Mowafy is a professor in restorative dentistry in the department of clinical dental sciences, faculty of dentistry, University of Toronto, Ontario.*

**Correspondence to:** Dr. Omar El-Mowafy, Department of clinical dental sciences, Faculty of dentistry, University of Toronto, 124 Edward St., Toronto, ON M5G 1G6. Email: oel.mowafy@utoronto.ca

*The author has no declared financial interests in any company manufacturing the types of products mentioned in this article.*

### References

1. Callan DP, Hahn J, Hebel K, Kwong-Hing A, Smiler D, Vassos DM, and others. Retrospective multicenter study of an anodized, tapered, diminishing thread implant: success rate at exposure. *Implant Dent* 2000; 9(4):329–36.
2. Odén A, Andersson M, Krystek-Ondracek I, Magnusson D. Five-year clinical evaluation of Procera AllCeram crowns. *J Prosthet Dent* 1998; 80(4):450–6.
3. Fradeani M, D’Amelio M, Redemagni M, Corrado M. Five-year follow-up with Procera all-ceramic crowns. *Quintessence Int* 2005; 36(2):105–13.
4. Zitzmann NU, Galindo ML, Hagmann E, Marinello CP. Clinical evaluation of Procera AllCeram crowns in the anterior and posterior regions. *Int J Prosthodont* 2007; 20(3):239–41.
5. Calamia JR. Etched porcelain veneers: the current state of the art. *Quintessence Int* 1985; 16(1):5–12.
6. El-Mowafy OM. The use of both porcelain veneers and all-porcelain crowns in restoring anterior teeth. [Clinical Showcase] *J Can Dent Assoc* 2006; 72(9):803–6.
7. El-Mowafy OM, Rubo MH, El-Badrawy WA. Hardening of new resin cements cured through ceramic inlay. *Oper Dent* 1999; 24(1):38–44.



## We're all smiles. **Join our team.**

Annual revenues approaching one billion dollars, along with our superior technological platform, power to innovate, and the quality of our rapidly growing staff, have put us in a strong position to sustain future growth. Our clients are extremely valued, and we are committed to achieving excellence by exceeding their expectations. We believe that Straumann will be a long-term, trusted partner for dental specialists, general practitioners and lab technicians and we look forward to helping these businesses grow to their fullest potential. If you'd like to work with or for a company that is committed to putting a smile on everyone's face, we invite you to consider a career with Straumann Canada. [Learn more at www.straumann.ca](http://www.straumann.ca)

COMMITTED TO  
**SIMPLY DOING MORE**  
FOR DENTAL PROFESSIONALS

# The Role of the Dentist in Recognizing Elder Abuse

*Michael Wiseman, DDS, FASGD, MRCSEd*

## Contact Author

*Dr. Wiseman*  
*Email: michael.wiseman@mcgill.ca*



## ABSTRACT

Recognizing abuse is paramount to protecting the increasing proportion of seniors in the Canadian population. Dentists are in an ideal position to identify and signal suspected abuse, as they perform a thorough examination of the head and neck region and generally see their patients twice a year. Good communication skills are necessary to improve dialogue with the patient. This article is intended to provide the dentist with tools to identify abuse and a decision tree to manage and monitor the suspected abused elder. With increased awareness, dentists will play an important role in helping protect seniors from abuse.

For citation purposes, the electronic version is the definitive version of this article: [www.cda-adc.ca/jcda/vol-74/issue-8/715.html](http://www.cda-adc.ca/jcda/vol-74/issue-8/715.html)

Seniors comprise the fastest growing segment of the Canadian population. In 2006, seniors represented 13.2% of Canada's total population or 4.2 million people; by 2036, the proportion is expected to increase to 24.5% or 9.8 million seniors. The increase is attributed to a decreasing birth rate, increased life expectancy and the impact of the aging "baby boom" generation. The fastest growing group will be seniors over the age of 80 years, who are expected to increase from 2.1% of the total population to 5.8% between 2021 and 2056.<sup>1</sup> The number of elderly seeking dental care is also expected to increase, not only because of this shift in demographics, but also because of such factors as decreased edentulism, increased disposable income and increased awareness of oral care and its potential link to systemic illnesses.<sup>2</sup>

Elder abuse has been defined as single or multiple hurtful acts of commission or omission inflicted on an elderly person by a person in a position of trust.<sup>3</sup> The hurtful act is considered to be one that is intentional, wilful or non-accidental. Elder abuse is becoming a

public issue, with the frequency of such acts increasing as the population ages. The concept of oral care providers recognizing and reporting child abuse is recognized as obligatory; however, extension of this practice to the elderly is not often considered. Bomba<sup>4</sup> has developed a validated template to help physicians recognize elder abuse and counsel seniors at risk. With permission, I have modified this template for use by dentists (Figs. 1 and 2). In this article, I review the topic of elder abuse and present a modified geriatric medical template to help dentists recognize elder abuse and counsel at-risk seniors.

## Prevalence

Elder abuse affects every social stratum and shows no regard for race, creed or colour. The frequency of elder abuse is difficult to quantify as many abused elderly people are afraid to report their abusers to the appropriate authorities. In 1981, a United States Congress Select Committee on Aging estimated that 5% of the American elderly or 1.5 million seniors were victims of abuse.<sup>5</sup>

<b>Signs that raise suspicion of elder abuse, neglect, financial exploitation</b>	<b>Management and monitoring</b>
<p><b>General</b></p> <ul style="list-style-type: none"> <li>• Delays between dental injury or disease and assessment</li> <li>• History from victim and perpetrator differs</li> <li>• Implausible or vague explanations</li> <li>• Functionally impaired patient presents without caregiver</li> <li>• Cognitively impaired patient presents without caregiver</li> <li>• Radiographic results inconsistent with history</li> <li>• “Physician/dentist hopping”</li> </ul> <p><b>Physical abuse</b></p> <ul style="list-style-type: none"> <li>• Bruises, welts, cuts, wounds, cigarette/rope burn marks</li> <li>• Blood on person, clothes</li> <li>• Injuries: fractures of teeth or jaws and related structures</li> <li>• Painful body movements unrelated to illness</li> <li>• Avulsed or loose teeth</li> </ul> <p><b>Psychological abuse</b></p> <ul style="list-style-type: none"> <li>• Sense of resignation or hopelessness</li> <li>• Passive, helpless, withdrawn behaviour</li> <li>• Fearful, tearful, anxious, clinging</li> <li>• Self-blame for life situation or caregiver behaviour</li> </ul> <p><b>Neglect</b></p> <ul style="list-style-type: none"> <li>• Unclean appearance, excessive plaque</li> <li>• Untreated caries</li> <li>• Underweight, frail, dehydrated</li> <li>• Inappropriate use of medications or failure to purchase medications</li> <li>• Long-term use of fractured dentures</li> </ul> <p><b>Financial exploitation</b></p> <ul style="list-style-type: none"> <li>• Unexplained change in power of attorney, will, legal documents</li> <li>• Missing cheques, money</li> <li>• Unexplained decrease in bank account, bounced cheques</li> <li>• Missing belongings</li> </ul> <p><b>Sexual abuse</b></p> <ul style="list-style-type: none"> <li>• Laceration of labial frenum, palatal petechiae</li> </ul> <p><i>Modified Ohio A &amp; DVLL Screening Tool, NEAN 13(2) 2001:35</i></p>	<p><b>Assess for safety:</b> <b>Is there immediate danger?</b></p> <p>Yes → <span style="border: 1px solid black; padding: 2px;">Immediate referral to police</span>      No ↓</p> <p><b>Does the patient accept intervention?</b></p> <p>Yes ↓ <span style="border: 1px solid black; padding: 5px;"> <ul style="list-style-type: none"> <li>• Provide emergency information</li> <li>• Educate the patient</li> <li>• Develop goals of care</li> <li>• Alleviate causes of abuse</li> <li>• Refer patient and family for services e.g., community health centre</li> <li>• Arrange follow-up</li> </ul> </span>      No ↓</p> <p><b>Does the patient have the capacity to refuse treatment?</b></p> <p>Yes ↓ <span style="border: 1px solid black; padding: 5px;"> <ul style="list-style-type: none"> <li>• Provide emergency information</li> <li>• Educate the patient</li> <li>• Develop goals of care</li> <li>• “Gentle persuasion”</li> <li>• Arrange follow-up</li> </ul> </span>      No ↓</p> <p><span style="border: 1px solid black; padding: 5px; display: inline-block; width: 100%;"> <ul style="list-style-type: none"> <li>• Refer to hospital geriatric team</li> </ul>                     Possible actions:                     <ul style="list-style-type: none"> <li>- financial management</li> <li>- guardianship</li> <li>- court proceedings</li> </ul> <ul style="list-style-type: none"> <li>• Arrange follow-up</li> </ul> </span></p> <p><i>Modified AMA Diagnostic and Treatment Guideline on Elder Abuse and Neglect, 1992</i></p>

**Figure 1:** Template for dentists to use in assessing and managing elder abuse (adapted from Bomba<sup>4</sup>)

Some international studies have estimated the rate of abuse at 2%–10%<sup>6</sup>; however, 1 Israeli study indicates that it can be as high as 20%.<sup>7</sup> In 2003, in Canada there were 4,000 incidents of violence against seniors, 29% of them committed by a family member. Most physical abuse inci-

dents took place in the home.<sup>1</sup> In the United States, it has been estimated that the rate of abuse increased 150% in the 10-year period between 1986 and 1996.<sup>8</sup> Although not well reported, this trend is probably occurring in Canada as well.



**As health care professionals, our challenge is to balance**

1. Duty to protect the safety of the vulnerable elder
2. Elder's right to self-determination

**Values**

- Treat elders with honesty, compassion, respect
- Goals of care should focus on improving quality of life and reducing suffering

**Principles: Rights of older adults**

- To be safe
- To retain civil and constitutional rights, unless restricted by courts
- To make decisions that do not conform to social norms if they cause no harm to others
- To have decision-making capacity unless courts decide otherwise
- To accept or refuse services

**Best practice guidelines**

- First **DO NO HARM**
- Interest of the senior is the priority
- Avoid imposing your personal values
- Respect diversity
- Involve the senior in the plan of care
- Recognize the senior's right to make choices
- Use family and informal support
- Recommend community-based services before institutional-based services, whenever possible
- In the absence of known wishes, act in the best interests of the patient and use substituted judgment

*Adapted and modified from A National Association of Adult Protective Services Administrators (NAAPSA) consensus statement.*

**Screening questions**

- Are you afraid of anyone in your family?
- Has anyone close to you tried to hurt or harm you recently?
- Has anyone close to you called you names or put you down or made you feel bad recently?
- Does someone in your family make you stay in bed or tell you you're sick when you know you aren't?
- Has anyone forced you to do things you didn't want to do?
- Has anyone taken things that belong to you without your OK? Are you often hungry?

**Figure 2:** Principles of dental assessment and management of elder abuse (adapted from Bomba<sup>4</sup>)

**Forms of Abuse**

Abuse can take a variety of forms: physical, emotional, sexual or financial abuse or neglect (**Table 1**).<sup>9</sup> Elder abuse can frequently involve 2 or more of these forms. Physical abuse is an injury or harm that causes pain, suffering, impairment or disease.<sup>10</sup> This may be caused by hitting

with hands or objects, burning or unjustified physical or pharmacologic restraint.<sup>11</sup> Scarring or bruising of wrists may indicate physical restraint. Hand- or knuckle-shaped bruises and fracture of facial bones and teeth may indicate physical abuse. Unexplained loss of hair may indicate hair pulling.

Emotional abuse involves intimidation, humiliation, belittling and threats of abandonment.<sup>12</sup> As this form of abuse may be displayed in both the dental operatory and waiting room, it is important for the office personnel to recognize and report it to the dentist. Victims of emotional abuse may often appear withdrawn, especially in the presence of their care providers.

Sexual abuse has been defined as nonconsensual sexual contact of any kind.<sup>13</sup> Intraoral palatal petechiae or torn labial frenum may be associated with forced oral sex.<sup>14</sup>

Neglect has been defined as the failure to provide goods or services necessary for a dependent person to function or to avoid harm.<sup>10</sup> It includes the failure to provide food, shelter, clothing and medical or dental care. Neglect can be active or passive. Active neglect is defined as the intentional withholding of the basic necessities of life. Passive neglect refers to the failure to provide these basic measures, not out of malice but as a result of lack of experience or ability.<sup>15</sup> The dentist should include neglect as part of a differential diagnosis when the dependent patient's mouth has abundant amounts of plaque or food debris. The patient may have numerous untreated caries, broken restorations, ill-fitting dentures and prolonged untreated soft-tissue pathologies.

Financial abuse is the financial exploitation of the elderly victim. The perpetrators may limit the amount of money available for food, housing, medicine and dental care. There are 3 types of perpetrators. The first is usually a person of trust, such as an accountant, lawyer, caregiver or clergy, who preys on the elderly because of greed and lack of ethics. The second is a family member who does not want to see any dilution of the future estate; this person may feel that he or she is entitled to the funds. The third is the scam artist, who may deceive seniors with false promises of lottery winnings or bogus home repairs.<sup>16</sup>

**Identification of Potential Abusers**

In 1 study,<sup>17</sup> abusers were interviewed to determine what characteristics increased their abuse potential. The investigators interviewed 2 distinct groups: 1 that physically abused and the another that neglected their elderly dependents. The abusers shared the following characteristics:

- they cared for an elderly person over 75 years of age
- they lived with their dependent
- they were inexperienced or unwilling caregivers

**Table 1** Forms of elder abuse and their manifestations

Form of abuse	General manifestations	Dental manifestations
Punching or slapping	Multiple bruises at varying stages of healing	Hand print on face, swollen lips, facial contusions, fractured or avulsed teeth, muscle trismus
Pulling of hair	Unexplained alopecia	Unusual loss of hair in the head and neck areas
Physical restraints	Rope burns or loss of hair on arms from tape	Periorbital facial lacerations from tape over lips
Psychological abuse	Unexplained fear, withdrawn behaviour, crying	No pathological source of discomfort, patient may blame themselves for their current dental condition
Neglect	Unclean appearance, underweight	Abundant plaque and food debris in mouth, broken dentures or restorations
Financial exploitation	Patient may have unexplained power of attorney, will or other legal documents	Caregiver refuses to pay for basic dental care, unusual returned cheques
Sexual exploitation	Inappropriate touching	Palatal bruising or petechiae, torn labial frenum

- they had high expectations of their elderly patient
- they had personal relationship conflicts and exhibited hostile, aggressive behaviour
- they had other caring demands, such as a spouse or children
- they were under stress due to lack of finances or poor housing
- they felt isolated and lacked community and personal support
- they may have been suffering from poor health
- they may have had a history of mental health problems including depression, anxiety, alcohol or drug abuse
- they may have been neglected or abused as a child or have had a family history of violence.

The study concluded that the probability of elder abuse or neglect increased with the number of these characteristics caregivers displayed.<sup>17</sup>

### Identification of the Abused

The identification of abused patients is difficult, as many of them will deny being abused. This is characteristically due to:

- a fear of retaliation or abandonment by their caregiver
- the feeling that they deserve the abuse
- a sense of helplessness — that nothing can be done
- shame in admitting that they are abused by their own family.<sup>18</sup>

A dentist who suspects abuse or neglect must empower the patient to speak freely. He or she should try to interview the patient without the suspected abuser present. **Figure 2** lists some screening questions that may

help the dentist question a patient. The patient should be seated upright and the dentist should use eye contact to improve communication. The dentist should note the form of abuse, duration and possible triggers of the behaviour. The dentist must understand the dynamics of the family unit, i.e., which member is in charge of medical and financial issues, whether there is a possibility of more than 1 abuser, etc.

The following characteristics are commonly seen in the abused elderly:

- physical or mental dependence on the caregiver
- poor communication between the abused and the caregiver
- “accident prone,” suffering many unexplained falls
- submissive or withdrawn behaviour in the presence of their caregiver.

Obvious signs of neglect or abuse to the head and neck region that are readily apparent to the dentist are listed in **Table 1**. As with any patient, identification of these clues begins with a good head and neck examination.

### Rationale for the Dentist as a Screener

Dentists may evaluate their patients on entry into the office by observing gait, appearance, communication skills and, of course, the head and neck region.<sup>19</sup> Many patients visit their dentist every 6 months, whereas they visit their physician only yearly. Dentists are among the most trusted professionals, and patients feel comfortable communicating with them. This trust increases as dentists communicate with compassion and empathy.<sup>20</sup>

Conversations with a suspected victim should be in a private area without any of the patient’s significant others present, and they should be witnessed by another

staff member. The dentist may decide to use some of the screening questions provided in **Figure 2**. Any physical evidence should be photographed and measured and its exact location documented. The patient must be constantly reassured, and all plausible explanations for any signs of abuse should be evaluated for consistency and probability. Many abused patients feel ashamed, experience self-denial and de-emphasize the abuse.<sup>21</sup>

The dentist may then interview the caregiver(s) and document the explanations given. The dentist must always be aware of natural changes associated with aging such as thinning of the skin, increased potential for bruising due to systemic illnesses or medications such as blood thinners. The latter 2 etiologies can be easily discerned from potential abuse by reviewing a comprehensive medical history.

### **Obligation to Report Suspected Abuse**

Barriers that may affect a dentist's willingness to report signs of elder abuse include lack of knowledge regarding legal responsibility, uncertainty about the diagnosis and fear that identification of the abused and abuser(s) might worsen the patient's situation.<sup>22</sup>

The confusion over legal responsibility stems from the Canadian legal structure, where federal, provincial and territorial governments have jurisdiction in specific areas of law designated by the Canadian constitution. Although criminal law is under federal jurisdiction, property rights, family law, human rights, consent and adult protection are provincial or territorial responsibilities. The Canadian Charter of Rights and Freedoms guarantees certain rights and liberties across Canada, and each province or territory adopts its own concepts into its laws. This has led to different responsibilities for dentists depending on the location of their practice.<sup>23</sup>

**Figures 1** and **2** are the modified validated templates<sup>4</sup> for the recognition and assessment of elder abuse by dentists. The well-being of the patient is of prime importance. If the patient is deemed to be in immediate danger, the police should be notified at once. However, if the dentist recognizes an abusive relationship in a fully cognitive patient and the patient refuses intervention, this creates an ethical quandary. Is the dentist correct in breaching patient confidentiality and disclosing the suspected abuse to the authorities? The answer seems to depend on the province in which the dentist practises. In Nova Scotia, reporting of abuse and neglect is mandatory.<sup>24</sup> Newfoundland and Labrador have mandatory reporting of neglect but not abuse,<sup>25</sup> and Prince Edward Island, New Brunswick and British Columbia have legislated voluntary reporting.<sup>26</sup> The Ontario Long-Term Care Homes Act<sup>27</sup> passed in 2006 establishes mandatory reporting of abuse only in long-term care centres. In Quebec, the cognitive senior has the right to choose how he or she wants to live; the rationale is that these patients are al-

ready protected by laws against assault or fraud within the criminal code.<sup>28</sup>

In my opinion, patients have the right to choose how they are going to live; however, if the dentist suspects a life-threatening situation, then authorities should be contacted immediately. The dentist should suggest to the patient that he or she may benefit from the social services provided by community-based clinics. This should be done with a persuasive, empathetic tone, and not in the presence of the alleged abuser. The dentist may wish to contact a social worker at such an agency. The dentist should employ a team approach involving the patient's physician and community health centre to allow for coordinated action. For patients who do not have the capacity to manage their own affairs, the local community health centre will refer the matter to the police and the courts. This will probably result in curatorship and possible criminal charges.

### **Management and Monitoring of Abuse in Canada**

Elder abuse is estimated to be as prevalent as child abuse, with only half of cases reported.<sup>26</sup> Most dentists would acknowledge their legal obligation to report child abuse, but many would not consider reporting elder abuse an obligation as well. This may be due to the fact that reporting child abuse is obligatory across Canada whereas the legal requirement to report elder abuse depends on the province in which one practises.

The question of mandatory reporting has been rejected by some organizations such as the Elder Abuse Prevention Unit in Queensland, Australia.<sup>29</sup> They believe that mandatory reporting will not improve or will have a negligible impact on the safety of older people and will divert resources away from addressing this issue. Further, the introduction of mandatory reporting denies the rights of seniors to make their own decisions, thereby reinforcing ageist stereotypes.<sup>28</sup> However, the Queensland group states that this policy does not extend to those with diminished capacity.

The Canadian Network for Prevention of Elder Abuse has adopted a position similar to that of the Queensland group.<sup>30</sup> They state that, unlike children, adults have the ability to make decisions about their own well-being and safety. They further state that seniors have the right to live their lives the way they want as long as they are mentally capable of doing so. Mandating reporting of abuse would be a violation of the mentally capable person's autonomy. There are already criminal, substitute-decision-making, guardianship and mental health laws available for the protection of people who are not mentally capable of protecting themselves.<sup>29-31</sup> This approach has been followed by the Quebec government, where there are no specific laws in connection with elder abuse, but individuals are covered by the Canadian criminal

code for acts such as assault and fraud. The Quebec Human Rights Commission states that suspected abuse cases should be referred to local community health units and, if the threat appears imminent, to the local police.

## Conclusion

Elder abuse is becoming more frequent as the population ages, and recognizing abuse is paramount in the protection of seniors. Dentists are in an ideal position to identify and signal suspected abuse, as they perform a thorough examination of the head and neck region and generally see their patients twice a year. Suspected abuse can be identified by approaching the patient with empathy and compassion. The dentist must use his or her clinical knowledge to distinguish abuse from normal fragility of the tissues. With the aid of the modified template (Figs. 1 and 2) dentists should play an important role in helping protect seniors from abuse. ♦

## THE AUTHOR



**Dr. Wiseman** is an assistant professor in the faculty of dentistry, McGill University, Montreal, Quebec; chief of dentistry at Mount Sinai Hospital, Côte Saint-Luc, Quebec; and has active status at St. Mary's Hospital, Montreal. He also maintains a private practice in Côte Saint-Luc.

**Correspondence to:** Dr. Michael Wiseman, 102-5555 Westminster Ave., Côte Saint-Luc, QC H4W 2J2.

The views expressed are those of the author and do not necessarily reflect the opinions or official policies of the Canadian Dental Association.

This article has been peer reviewed.

## References

- Turcotte M, Schellenberg G. A portrait of seniors in Canada. Ottawa: Statistics Canada; 2006. Available at: [www.statcan.ca/english/freepub/89-519-XIE/89-519-XIE2006001.pdf](http://www.statcan.ca/english/freepub/89-519-XIE/89-519-XIE2006001.pdf) (accessed 2008 May 20).
- Wilson AA, Bolden AJ, Bailit HL. Oral health services for the elderly population in a nation with mainly self-financed health care. In: Holm-Pederson P, Løe H, editors. Textbook of geriatric dentistry. Munksgaard, Copenhagen; 1996. p. 528–35.
- Hamp LF. Analysis of elder abuse and neglect definitions under the law. In: Bonnie RJ, Wallace RB, editors. Elder mistreatment: abuse, neglect, and exploitation in an aging America. National Research Council Panel to Review Risk and Prevalence of Elder Abuse and Neglect. Committee on National Statistics and Law. Division of Behavioral and Social Sciences and Education. Washington: National Academy Press; 2003. p. 35–8.
- Bomba PA. Use of a single page elder abuse assessment and management tool: a practical clinician's approach to identifying elder mistreatment. *J Gerontol Soc Work* 2006; 46(3-4):103–22.
- Subcommittee on Health Long-Term Care. Elder abuse: a decade of shame and inaction. Select Committee on Aging, House of Representatives, 101st Congress, 2nd Session; 1990.
- Lachs MS, Pillemer K. Elder abuse. *Lancet* 2004; 364(9441):1263–72.
- Siegel-Itzkovich J. A fifth of elderly people in Israel are abused. *BMJ* 2005; 330(7490):498.
- Trends in elder abuse in domestic settings. Elder abuse information series no. 2. Washington: National Center on Elder Abuse; 1997. Available: [www.ncea.aoa.gov/ncearoot/Main\\_Site/pdf/basics/fact2.pdf](http://www.ncea.aoa.gov/ncearoot/Main_Site/pdf/basics/fact2.pdf) (accessed 2008 May 20).
- Jorgensen JE. A dentist's social responsibility to diagnose elder abuse. *Spec Care Dentist* 1992; 12(3):112–5.
- American Medical Association. Diagnostic and treatment guidelines on elder abuse and neglect. Chicago: AMA; 1996. AA25:96-937:4M 12/96 ed).
- Lachs MS, Pillemer K. Abuse and neglect of elderly persons. *N Engl J Med* 1995; 332(7):437–43.
- Clarke ME, Pierson W. Management of elder abuse in the emergency department. *Emerg Med Clin North Am* 1999; 17(3):631–44.
- Major types of elder abuse. Washington: National Center on Elder Abuse; 2007. Available: [www.ncea.aoa.gov/ncearoot/Main\\_Site/FAQ/Basics/Types\\_Of\\_Abuse.aspx](http://www.ncea.aoa.gov/ncearoot/Main_Site/FAQ/Basics/Types_Of_Abuse.aspx) (accessed 2008 May 20).
- Terezhalmay GT, Riley CK, Moore WS. Oral lesions secondary to fellatio. *Quintessence Int* 2000; 31(5):361.
- Spencer C, Soden A. A softly greying nation: law ageing and policy in Canada. Montreal: Elder Law Canada; 2007. Available: [www.elderlawcanada.ca/pdf/greying\\_nation.pdf](http://www.elderlawcanada.ca/pdf/greying_nation.pdf) (accessed 2008 May 20).
- Kemp B, Liao S. Elder financial abuse: tips for the medical director. *J Am Med Dir Assoc* 2006; 7(9):591–3. Epub 2006 Oct 4.
- Campbell Reay AM, Browne KD. Risk factor characteristics in carers who physically abuse or neglect their elderly dependents. *Ageing Ment Health* 2001; 5(1):56–62.
- Kosberg JI. Preventing elder abuse: identification of high risk factors prior to placement decisions. *Gerontologist* 1988; 28(1):43–50.
- Ochs HA, Neuenschwander MC, Dodson TB. Are head, neck and facial injuries markers of domestic violence? *J Am Dent Assoc* 1996; 127(6):757–61.
- Epstein RM. Virtual physicians, health systems, and the healing relationship. *J Gen Intern Med* 2003; 18(5):404–6.
- McDowell JD, Kassebaum DK, Stromboe SE. Recognizing and reporting victims of domestic violence. *J Am Dent Assoc* 1992; 123(9):44–50.
- Wong C, Marr S. Factors influencing health-care professionals in identifying and managing elder abuse: a preliminary report. *Geriatrics Today* 2002; 5:34–7. Available: [www.canadiangeriatrics.com/pubs/GTFeb2002/gtfFeb2002\\_A9.pdf](http://www.canadiangeriatrics.com/pubs/GTFeb2002/gtfFeb2002_A9.pdf) (accessed 2008 May 20).
- Beaulieu M, Gordon RM, Spencer C. The abuse and neglect of older Canadians: key legal and related issues. In: Soden A, editor. Advising the older client. Markham, Ont.: LexisNexis Butterworths; 2005. p. 197–246.
- Adult Protection Act. Halifax: Government of Nova Scotia; 1989. Available: [www.gov.ns.ca/legislature/legc/statutes/adulpro.htm](http://www.gov.ns.ca/legislature/legc/statutes/adulpro.htm) (accessed 2008 May 20).
- Neglected Adults Welfare Act, R.S.N.L. 1990. c. N-3. Saint John's: Government of Newfoundland and Labrador; 1990. Available: [www.canlii.org/nl/laws/sta/n-3/20080215/whole.html](http://www.canlii.org/nl/laws/sta/n-3/20080215/whole.html) (accessed 2008 May 20).
- Kenney JP. Domestic violence: a complex health care issue for dentistry today. *Forensic Sci Int* 2006; 159 Suppl 1:S121–5. Epub 2006 Mar 20.
- Ontario Ministry of Health and Long-Term Care. Long-Term Care Homes Act, 2006. Available: [www.health.gov.on.ca/english/public/legislation/ltc\\_homes/ltc\\_homes.html](http://www.health.gov.on.ca/english/public/legislation/ltc_homes/ltc_homes.html) (accessed 2008 May 20).
- Commission des droits de la personne et des droits de la jeunesse. The exploitation of the elderly: report on the implementation of the recommendations made in the report Towards a tightened safety net. Montreal: CDPDJ; 2005. Available: [www.cdpedj.qc.ca/en/publications/docs/exploitation\\_recommandations\\_implementation.pdf](http://www.cdpedj.qc.ca/en/publications/docs/exploitation_recommandations_implementation.pdf) (accessed 2008 May 20).
- Elder Abuse Prevention Unit. Position statement on mandatory reporting of elder abuse. Brisbane, Australia: EAPU; 2006. Available: [www.eapu.com.au/LinkClick.aspx?fileticket=QIm6T5TYUrl%3D&tabid=80&mid=398](http://www.eapu.com.au/LinkClick.aspx?fileticket=QIm6T5TYUrl%3D&tabid=80&mid=398) (accessed 2008 May 20).
- Canadian Network for the Prevention of Elder Abuse. Mandatory reporting. Available: [www.cnpea.ca/mandatory%20reporting\\_1.pdf](http://www.cnpea.ca/mandatory%20reporting_1.pdf) (accessed 2008 May 20).
- National Clearinghouse on Family Violence. Abuse and neglect of older adults: a discussion paper. Ottawa: Public Health Agency of Canada; 2005. Available: [www.phac-aspc.gc.ca/ncfv-cnivf/familyviolence/html/agediscussion\\_e.html](http://www.phac-aspc.gc.ca/ncfv-cnivf/familyviolence/html/agediscussion_e.html) (accessed 2008 May 20).

# Efficacy of 3 Techniques in Removing Root Canal Filling Material

Emre Bodrumlu, DDS, PhD; Özgür Uzun, DDS, PhD;  
Özgür Topuz, DDS, PhD; Mustafa Semiz, PhD

## Abridged Version

The complete article is published in the electronic JCDA at [www.cda-adc.ca/jcda/vol-74/issue-8/721.html](http://www.cda-adc.ca/jcda/vol-74/issue-8/721.html)

For citation purposes, the electronic version is the definitive version of this article.

Root canal treated teeth may require retreatment in case of a persistent infection or after reinfection of the root canal. Retreatment requires complete removal of the root canal filling material, followed by further shaping, cleaning and reobturation.

**Objective:** This study evaluated the efficacy of 3 techniques in removing laterally compacted Resilon/Epiphany (Pentron Clinical Technologies, Wallingford, Conn.) and gutta-percha/AH Plus (Dentsply, GmbH, Konstanz, Germany) from straight and curved canals during retreatment.

**Materials and Methods:** Extracted human teeth (90 maxillary anterior teeth with single, straight root canals and 90 mandibular molars with mesial canal root curvatures of 20° to 35°) were used in this study. The crowns of the teeth were sectioned at the cemento-enamel junction using water-cooled diamond discs. All 180 roots were divided into 6 groups, each consisting of 15 straight and 15 curved canals. Groups 1, 3 and 5 were obturated using gutta-percha/AH Plus; groups 2, 4 and 6 were obturated with Resilon/Epiphany.

After the filling process, the quality of obturation was assessed radiographically, the root canal en-

trances were sealed with temporary filling material (Cavit, ESPE Dental, Medizin, Germany) and specimens were stored at 37°C in 100% humidity for 3 weeks. All roots were then mounted on plastic tubes with acrylic resin and temporary fillings were removed with round burs. The root

canal fillings in both obturation groups were removed using 1 of the following 3 techniques: Gates Glidden drill, Gates Glidden drill plus chloroform or System B device.

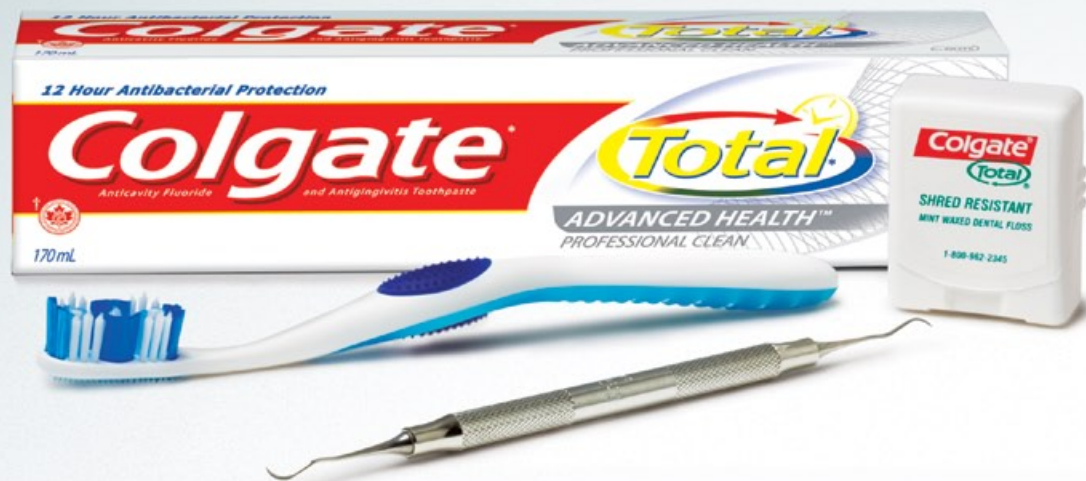**Results:** All removal techniques left more remnants of filling material in curved canals than in straight canals. For all removal techniques, specimens obturated with gutta-percha/AH Plus showed significantly more remaining obturation material than specimens filled with Resilon/Epiphany in both straight and curved canals ( $p < 0.05$ ). Removal time for Resilon/Epiphany material was shorter than for gutta-percha/AH Plus for all techniques and for both curved and straight canals. The Gates Glidden drill with or without chloroform was significantly faster than the System B technique in removing filling material from both straight and curved canals ( $p < 0.05$ ). The Gates Glidden technique worked best for straight canals, whereas the Gates Glidden technique with chloroform worked best for curved canals. However, there appears to be no statistical difference in degree of removal among all tested techniques ( $p > 0.05$ ). The degree of removal for the 2 obturation groups using the System B technique was lower than the other 2 techniques in straight and curved canals and in both gutta-percha/AH Plus and the Resilon/Epiphany groups.

**Conclusions:** The removal of Resilon/Epiphany filling material was faster and resulted in fewer remnants than removal of gutta-percha/AH Plus material using a Gates Glidden drill and a Gates Glidden drill plus chloroform in both straight and curved canals. ✦

THE REMOVAL OF RESILON/EPIPHANY FILLING MATERIAL WAS FASTER AND RESULTED IN FEWER REMNANTS THAN REMOVAL OF GUTTA-PERCHA/AH PLUS MATERIAL USING A GATES GLIDDEN TECHNIQUE.



## Protection Against Plaque, Gingivitis, and Caries



**Only Colgate Total\*** has a unique Triclosan *plus* Copolymer formula delivering 12-hour antibacterial protection

**Colgate\***

YOUR PARTNER IN ORAL HEALTH

# Unusual Ectopic Eruption of a Permanent Central Incisor Following an Intrusion Injury to the Primary Tooth

*Ebru Canoglu, DDS; Cenk Ahmet Akcan, DDS, PhD; Erdinç Baharoglu, DDS; H. Cem Gungor, DDS, PhD; Zafer C. Cehreli, DDS, PhD*

## Contact Author

*Dr. Cehreli*  
Email: [zcehreli@hacettepe.edu.tr](mailto:zcehreli@hacettepe.edu.tr)



## ABSTRACT

Intrusive luxation of primary teeth carries a high risk of damage to underlying permanent tooth germs. Ectopic eruption of permanent incisors is an unusual outcome of traumatic injury to their predecessors. In this case report, we describe the multidisciplinary management of the consequences of a primary tooth intrusion that led to severe ectopic eruption of the permanent left central incisor in a horizontal position at the level of the labial sulcus.

For citation purposes, the electronic version is the definitive version of this article: [www.cda-adc.ca/jcda/vol-74/issue-8/723.html](http://www.cda-adc.ca/jcda/vol-74/issue-8/723.html)

Preschool-age children lack the psychomotor skills needed to perform precise and safe movements and, as a result, they are susceptible to falls and other injuries.<sup>1,2</sup> According to the literature, 15%–30% of children suffer traumatic injuries to primary teeth.<sup>3–5</sup> In contrast to the hard-tissue injuries that are more commonly seen in permanent dentition, luxation injuries predominate in the primary dentition.<sup>6,7</sup> The larger bone marrow space resulting in high elasticity of alveolar bone surrounding the primary teeth has been cited as the reason for this.<sup>1</sup>

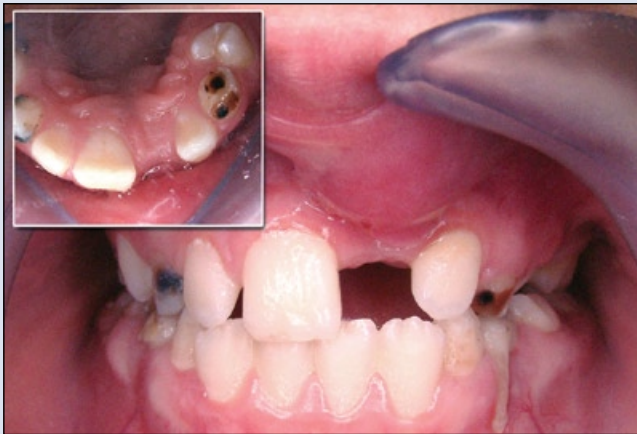Intrusive luxations constitute 4.4%–22% of traumatic injuries in primary dentition.<sup>1,5,8–10</sup> In the case of an intruded primary tooth, developmental disturbances of the successor permanent tooth can occur as a result of the close proximity of the developing permanent tooth germ to the primary root apex.<sup>6</sup> With an overall prevalence of 41%,<sup>11</sup> these developmental disturbances include white or yellow-

brown enamel discoloration with or without enamel hypoplasia, crown–root dilaceration, odontoma, root duplication or angulation, arrest of root development, germ sequestration and eruption disturbances.<sup>12–14</sup>

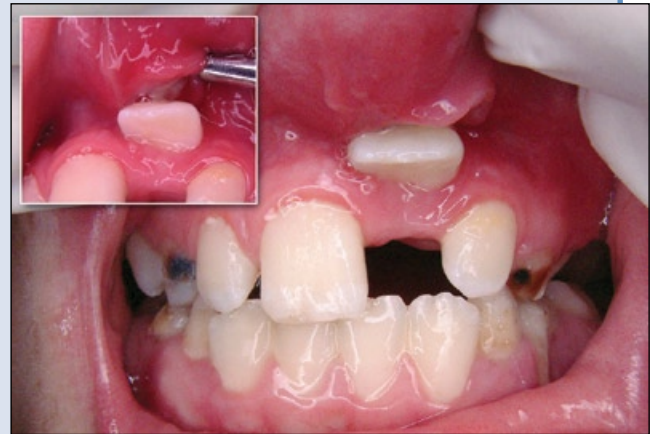
Ectopic eruption of a permanent incisor may result from traumatic injury to its predecessor.<sup>15</sup> The condition is caused by the physical displacement of the permanent germ, the lack of eruption guidance by the prematurely lost primary incisor or both.<sup>15</sup> In this case report, we describe the management of a permanent central incisor that was erupting ectopically because of prior intrusive luxation of the corresponding primary tooth.

## Case Report

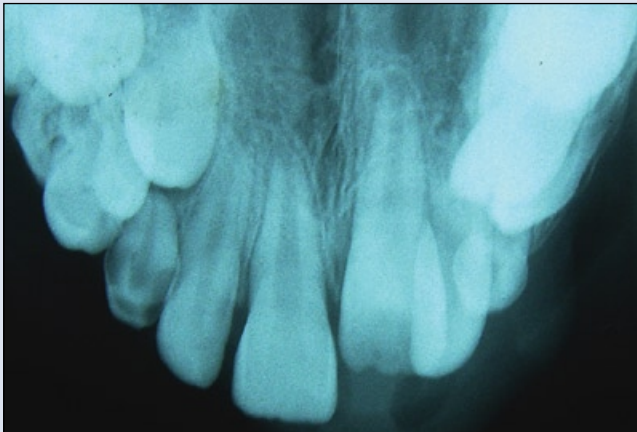
A healthy 9-year-old boy was referred to the pediatric dentistry clinic with the chief complaint of ectopic eruption of the maxillary left central incisor. Reportedly, at 4 or 5 years of age he had experienced a fall that caused



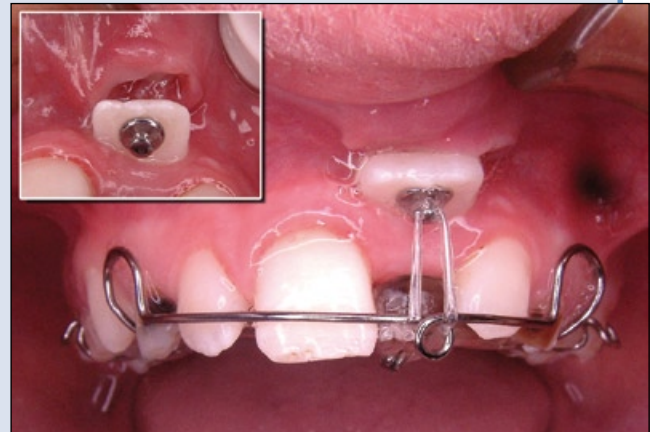
**Figure 1:** Frontal view of the anterior maxillary arch at the patient's first visit. Despite retraction of the lips, the ectopically erupted incisor is not visible. Inset: Occlusal view of the anterior maxillary arch.



**Figure 2:** The ectopically erupted incisor was exposed by stretching the upper lip forward and up. Inset: view of the "pseudo pouch" with edematous borders and a purulent exudation.



**Figure 3:** Radiographic view of the left central incisor revealing no root dilaceration.



**Figure 4:** Orthodontic extrusion and respacing was initiated using a modified fan-type appliance. Inset: an orthodontic button, bonded to the palatal aspect of the incisor.

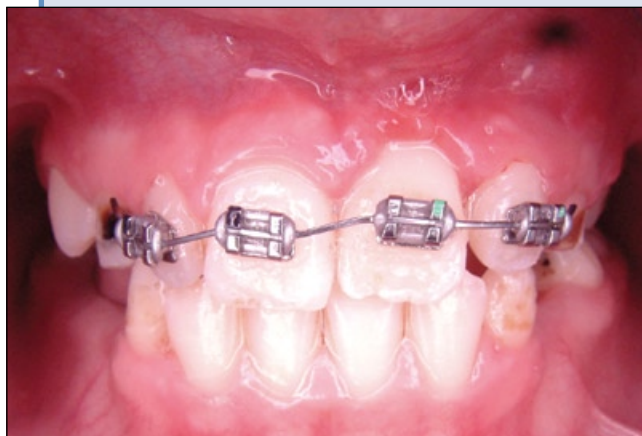severe intrusion of his primary left central incisor and premature loss of the tooth 1 month later.

Intraoral examination revealed the absence of the maxillary left central incisor within the dental arch, along with slight closure of the eruption space caused by displacement of the neighbouring incisors (**Fig. 1**). The central incisor could only be visualized when the patient's upper lip was stretched up and outward as much as possible (**Fig. 2**). Trauma had caused displacement of the tooth to an almost horizontal position at the level of the labial sulcus, forcing the incisor to erupt toward the inner labial mucosa. Over time, chronic soft-tissue irritation caused by the tooth's incisal aspect had caused formation of a "pseudo-pouch" with a swollen, elevated border that overlapped the crown in the resting position of the lip (**Fig. 2, inset**). Stretching of the upper lip

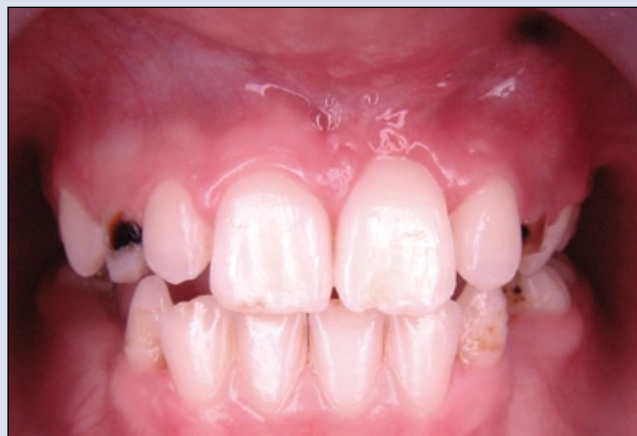also revealed a purulent exudation that had accumulated within the pouch. An occlusal radiograph showed no root dilaceration (**Fig. 3**).

Following orthodontic consultation, an initial treatment plan was formulated to regain the approximately 2 mm of space lost as a result of displacement of the neighbouring incisors and to move the left central incisor to a normal position. An impression of the maxillary arch was taken to permit fabrication of a fan-type expansion appliance, containing a modified vestibular arch and a palatal hook (**Fig. 4**). The patient was prescribed antibiotics and anti-inflammatory drugs. A chlorhexidine mouth rinse was recommended, oral hygiene motivation was provided and another visit was scheduled. At the next appointment, an orthodontic button was bonded to the palatal surface of the incisor (**Fig. 4, inset**). After





**Figure 5:** Fixed orthodontic therapy was needed for further extrusion of the left central incisor. Note the extent of healing of the inner labial mucosa.



**Figure 6:** Post-treatment view showing correct alignment of the left central incisor, an acceptable gingival contour and excellent healing of the inner labial mucosa.

fitting the fan-type appliance, extrusive orthodontic movement of the left incisor was initiated by securing an elastic ligature between the button and the palatal hook of the appliance. The patient was instructed in the use of the appliance and how to change the ligatures and was scheduled for weekly follow-up visits.

Two months later, the lost space had been completely recovered. During that time, the labial mucosa healed dramatically as the irritating incisal edge was moved gradually in the occlusal direction. Because of the extent of extrusion achieved, the palatal button was relocated to the labial surface of the tooth to achieve sufficient orthodontic force in the proper direction. During the third month, fixed orthodontic therapy was initiated to further extrude the tooth and to ensure its correct alignment within the maxillary arch (Fig. 5).

After a further 2 months, orthodontic extrusion of the left central incisor was completed, and the gingival margin of the tooth was brought to the approximate level of that of the neighbouring teeth (Fig. 6). In addition to complete healing of the inner labial mucosa, the tooth and supporting tissues appeared to be in good condition radiographically. The tooth was temporarily secured to the neighbouring incisors with an acid-etch composite resin to prevent relapse. Regular follow-up visits over the subsequent 12 months were uneventful.

## Discussion

Intrusion injuries to primary teeth present the highest risk of damage to permanent tooth germs.<sup>16</sup> Many factors influence the sequelae of intrusion injuries: age, direction and severity of intrusion and type of treatment.<sup>17</sup> Intrusive-type injuries to primary incisors most commonly take place between 1 and 3 years of age.<sup>5,6</sup> Several

reports have shown that the younger the child at the time of the intrusion injury, the more severe the induced sequelae to the successor tooth.<sup>11,18</sup> Despite the occurrence of severe ectopic eruption in the present case, developmental disturbances such as discoloration, hypoplasia, crown or root dilaceration or root angulation were not observed in the affected permanent incisor. Because the trauma had occurred at a relatively later age, the effect on the permanent successor tooth may have been limited to alteration of the eruption pathway.

Many studies have reported intrusive luxation to be the most frequent cause of developmental disturbances in permanent teeth.<sup>17,19,20</sup> The intimate relation between the primary incisors and their successors explains the disruptive effect of intrusion injuries on permanent teeth,<sup>6</sup> one of which is the disturbance of eruption. Children with a history of trauma experience a higher percentage of malpositioned incisors compared with those without trauma.<sup>15</sup> This case presents a similar outcome, except that the severity of impact caused the successor to erupt in a highly unusual pattern without any crown-root or root dilaceration. To our knowledge, no such disturbance has been reported in the dental literature previously.

Considering the position of the ectopically erupted incisor and the insufficient arch length, it seemed difficult to bring the maxillary central incisor into the dental arch. However, regaining sufficient space and ensuring sufficient traction in the right direction allowed us to move the ectopically erupted tooth into the correct position. Although we initially expected to correct this problem with removable appliances, fixed orthodontic therapy was necessary to achieve proper levelling and angulation. Eventually, functional and esthetic problems were solved when the central incisor was positioned in the arch.

When abnormally positioned ectopically erupted incisors are moved into the arch, discrepancies are often observed between the gingival levels of the affected and neighbouring teeth. Clinical experience has shown that light forces are more effective than strong ones in moving ectopically erupted teeth and achieving a good gingival position.<sup>21</sup> Following fixed orthodontic therapy, the gingiva of the central incisor was brought close to the level of that of the adjacent central incisor, thus eliminating the need for gingival plastic surgery. ❖

## THE AUTHORS



**Dr. Canoglu** is a research assistant in the department of pediatric dentistry, faculty of dentistry, Hacettepe University, Ankara, Turkey.



**Dr. Akcan** is a research associate in the department of orthodontics, faculty of dentistry, Hacettepe University, Ankara, Turkey.



**Dr. Baharoğlu** is a research assistant in the department of orthodontics, faculty of dentistry, Hacettepe University, Ankara, Turkey.



**Dr. Gungor** is an associate professor in the department of pediatric dentistry, faculty of dentistry, Hacettepe University, Ankara, Turkey.



**Dr. Cehreli** is an associate professor in the department of pediatric dentistry, faculty of dentistry, Hacettepe University, Ankara, Turkey.


**Correspondence to:** Dr. Zafer C. Cehreli, Department of pediatric dentistry, Faculty of dentistry, Hacettepe University, Sıhhiye 06100, Ankara, Turkey.

The authors have no declared financial interests.

This article has been peer reviewed.

## References

- Andreasen JO. Etiology and pathogenesis of traumatic dental injuries. A clinical study of 1,298 cases. *Scand J Dent Res* 1970; 78(4):329–42.
- Harrington MS, Eberhart AB, Knapp JF. Dentofacial trauma in children. *ASDC J Dent Child* 1988; 55(5):334–8.
- Flores MT. Traumatic injuries in the primary dentition. *Dent Traumatol* 2002; 18(6):287–98.
- García-Godoy F, Morbán-Laucer F, Corominas LR, Franjul RA, Noyola M. Traumatic dental injuries in preschool children from Santo Domingo. *Community Dent Oral Epidemiol* 1983; 11(2):127–30.
- Skaare AB, Jacobsen I. Primary tooth injuries in Norwegian children (1–8 years). *Dent Traumatol* 2005; 21(6):315–9.
- Andreasen JO. Injuries to the developing teeth. In: Andreasen JO, Andreasen FM, editors. Textbook and color atlas of traumatic injuries to the teeth. Copenhagen: Munksgaard; 1994. p. 457–94.
- Altay N, Güngör HC. A retrospective study of dento-alveolar injuries of children in Ankara, Turkey. *Dent Traumatol* 2001; 17(5):201–4.
- García-Godoy F, García-Godoy F, García-Godoy FM. Primary teeth traumatic injuries at a private pediatric dental center. *Endod Dent Traumatol* 1987; 3(3):126–9.
- Sennhenn-Kirchner S, Jacobs HG. Traumatic injuries to the primary dentition and effects on the permanent successors — a clinical follow-up study. *Dent Traumatol* 2006; 22(5):237–41.
- Rodriguez JG. Traumatic anterior dental injuries in Cuban preschool children. *Dent Traumatol* 2007; 23(4):241–2.
- Andreasen JO, Ravn JJ. The effect of traumatic injuries to primary teeth on their permanent successors. II. A clinical and radiographic follow-up study of 213 teeth. *Scand J Dent Res* 1971; 79(4):284–94.
- Turgut MD, Tekçiçek M, Canoglu H. An unusual developmental disturbance of an unerupted permanent incisor due to trauma to its predecessor — a case report. *Dent Traumatol* 2006; 22(5):283–6.
- Lenzi AR, Medeiros PJ. Severe sequelae of acute dental trauma in the primary dentition — a case report. *Dent Traumatol* 2006; 22(6):334–6.
- Kuvvetli SS, Seymen F, Gencay K. Management of an unerupted dilacerated maxillary central incisor: a case report. *Dent Traumatol* 2007; 23(4):257–61.
- Brin I, Ben-Bassat Y, Zilberman Y, Fuks A. Effect of trauma to the primary incisors on the alignment of their permanent successors in Israelis. *Community Dent Oral Epidemiol* 1988; 16(2):104–8.
- von Arx T. Developmental disturbances of permanent teeth following trauma to the primary dentition. *Aust Dent J* 1993; 38(1):1–10.
- Diab M, el Badrawy HE. Intrusion injuries of primary incisors. Part III: Effects on the permanent successors. *Quintessence Int* 2000; 31(6):377–84.
- Ravn JJ. Developmental disturbances in permanent teeth after intrusion of their primary predecessors. *Scand J Dent Res* 1976; 84(3):137–41.
- Kramer PF, Zembruksi C, Ferreira SH, Feldens CA. Traumatic dental injuries in Brazilian preschool children. *Dent Traumatol* 2003; 19(6):299–303.
- Bassiouny MA, Giannini P, Deem L. Permanent incisors traumatized through predecessors: sequelae and possible management. *J Clin Pediatr Dent* 2003; 27(3):223–8.
- Cozza P, Mucedero M, Ballanti F, De Toffoli L. A case of an unerupted maxillary central incisor for indirect trauma localized horizontally on the anterior nasal spine. *J Clin Pediatr Dent* 2005; 29(3):201–3.




**PHILIPS**

## Be prepared!

Cardiac Arrest can happen to anyone at anytime. Philips AED's are safe, voice prompted and simple to use. With the world's fastest "CPR to Shock" sequence, we offer best possible survival. Choose Philips... lives are worth it!

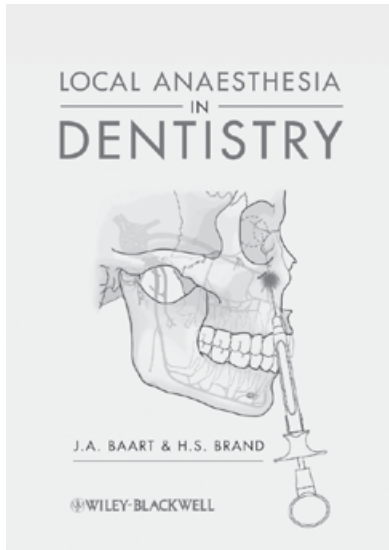
**The current survival rate for out of hospital cardiac arrest is between 3-5% with EMS responding. Locations with AED's (Automatic External Defibrillator) can have survival rates as high as 70%+.**



**First Edition**  
First Aid Training Authorized Philips Distributor

**Jan Kirkpatrick** Phone/Fax: (403) 243-2644 Email: h2hcpr@telusplanet.net  
**www.firsteditionfirstaid.ca**

# Finally, a Painless Reference for Dental Anaesthesia.



Highly illustrated in full colour throughout, *Local Anaesthesia in Dentistry* provides clear and practical guidance to the administration of local anaesthesia. The book begins with an introduction to nerve conduction and pain, and the anatomy of the trigeminal nerve. Further chapters cover such key areas of practice as regional anaesthesia, local anaesthesia in children, pharmacology, local and systemic complications, general practical aspects, the prevention of side effects and legal aspects.

ISBN: 978-1-4051-8436-6 • Softcover • 192 pp.  
\$70.00 • November 2008

For more information and other titles, please visit [www.wiley.ca](http://www.wiley.ca)

 **WILEY-BLACKWELL**



FACULTÉ DE MÉDECINE DENTAIRE

## Professeurs recherchés

La Faculté de médecine dentaire de l'Université Laval recherche présentement des professeures et professeurs dans les domaines de la **prosthodontie**, la **parodontie** et l'**endodontie**.

### Qualifications générales requises :

- Détenir un permis de pratique de l'Ordre des dentistes du Québec ou s'engager à l'obtenir.
- Détenir une maîtrise en sciences dentaires et un certificat dans la discipline concernée ou s'engager à l'obtenir.
- Démontrer des aptitudes pédagogiques; pouvoir enseigner en français ou prendre les dispositions nécessaires à cet effet dans un délai raisonnable.

**Date de clôture des concours :** 1<sup>er</sup> décembre 2008

**Pour information :** 418 656-7532 • [doyen@fmd.ulaval.ca](mailto:doyen@fmd.ulaval.ca)

Les descriptions complètes et les critères de sélection de chacun des concours sont disponibles sur le site web de la Faculté au **[www.fmd.ulaval.ca](http://www.fmd.ulaval.ca)** sous l'onglet «Emplois disponibles».

# Professional solutions, customized advice.



CIBC Professional Edge® combines professional solutions with customized advice exclusively to meet the needs of professionals like you.

You'll benefit from the experience of a dedicated CIBC business advisor who is supported by a team of business solutions experts. Together they will work with you to provide objective advice that meets the unique needs of your practice and helps you to achieve your personal financial goals.

**Contact a CIBC business advisor today or visit [cibc.com/professional](http://cibc.com/professional).**



**For what matters.**

®Registered trademark of CIBC.  
"CIBC For what matters." is a TM of CIBC.

# Repair of Furcal Perforation with Mineral Trioxide Aggregate: Long-Term Follow-Up of 2 Cases

**Camila M.M. Silveira**, DDS, MSc; **Alfonso Sánchez-Ayala**, DDS, MSc;  
**Manuel O. Lagravère**, DDS, MSc; **Gibson L. Pilatti**, DDS, MSc, PhD;  
**Osnara M.M. Gomes**, DDS, MSc, PhD

## Contact Author

**Dr. Sánchez-Ayala**  
Email: [snzcd@fop.unicamp.br](mailto:snzcd@fop.unicamp.br)



## ABSTRACT

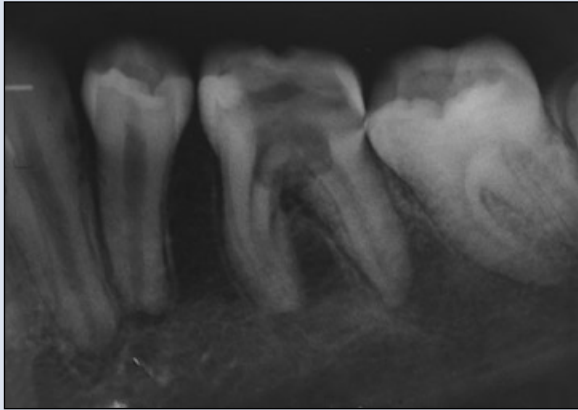
Previous studies have demonstrated the efficacy of mineral trioxide aggregate (MTA) in repair of furcal perforation. In this article, the use of MTA in treating 2 cases of furcal perforation (accidental and caries-related) and subsequent long-term follow-up are described.

For citation purposes, the electronic version is the definitive version of this article: [www.cda-adc.ca/jcda/vol-74/issue-8/729.html](http://www.cda-adc.ca/jcda/vol-74/issue-8/729.html)

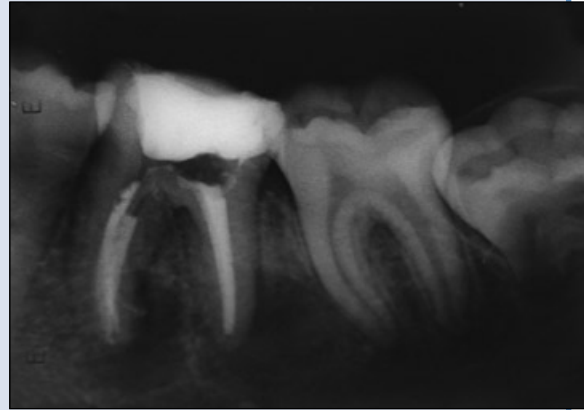A major complication of endodontic and restorative treatments is accidental perforation of the roots or the pulp chamber floor. Such perforation may occur during nonsurgical root canal treatment or during preparation for a variety of restorative procedures.<sup>1</sup> The result is a chronic inflammatory reaction of the periodontium (characterized by the formation of granulation tissue) that can lead to irreversible loss of attachment or loss of the tooth.<sup>2</sup> Such perforations are managed surgically or nonsurgically, depending on the particular characteristics of the case.<sup>3</sup> The prognosis may be questionable if treatment involves a lesion occurring at the level of the radicular furcation, but the prognosis is usually good if the problem is diagnosed correctly and treated with a material having suitable sealing ability and biocompatibility.<sup>1</sup> The prognosis also depends on the location, size and time of contamination of the lesion.<sup>4</sup>

Various materials have been used in managing perforations, including zinc oxide–eugenol, amalgam, calcium hydroxide,

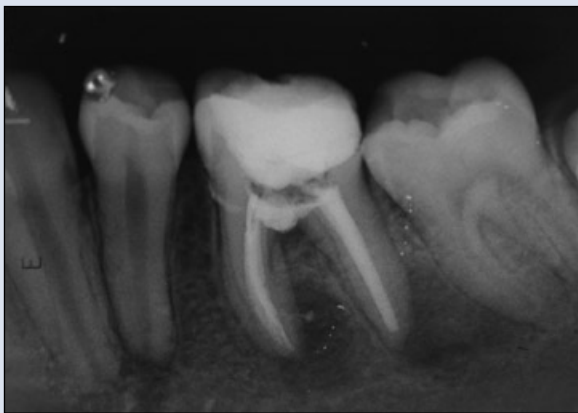composite resin, glass ionomer and resin-modified glass ionomer.<sup>1,4</sup> The ideal material for treating radicular perforations should be nontoxic, nonabsorbable, radiopaque, and bacteriostatic or bactericidal; it should also provide a seal against microleakage from the perforation.<sup>5</sup> Mineral trioxide aggregate (MTA) has all of these characteristics and has been applied with good outcomes in root-end surgery, direct pulpal coverage, apexification, radicular resorption, and repair of lateral radicular and furcal perforation.<sup>6</sup> Its suitability for managing all of these problems can be attributed to its biocompatibility, its low induction of inflammation, its solubility, its capacity for creating a seal between the pulpal chamber and periodontal tissues and its repair capacity. The last of these features can in turn be attributed to the antimicrobial properties and high pH (12.5) of MTA, which promote growth of the cementum and formation of bone, which in turn allow regeneration of the periodontal ligament around the site of injury.<sup>7</sup>



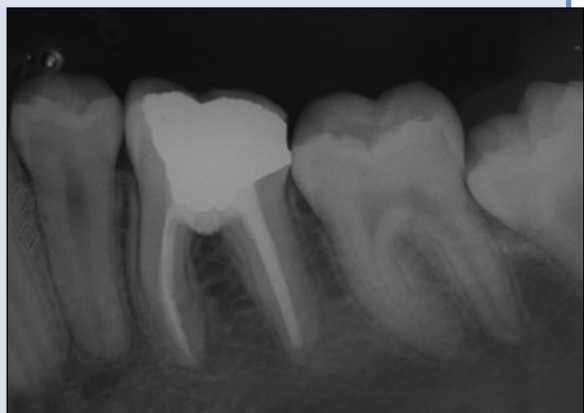**Figure 1a:** Case 1. Periapical image of tooth 36 showing caries-related furcal perforation.



**Figure 1b:** Mineral trioxide aggregate (MTA) placed with temporary restoration.



**Figure 1c:** MTA seal and new root canal treatment at 3-month follow-up.



**Figure 1d:** At 2-year follow-up, there is complete osseous healing at the apex and the furcation.

In this article, 2 cases are described in which MTA was used to repair furcation perforation. These cases illustrate the potential benefits of MTA and its relative ease of use for management of perforation at easily accessed sites.

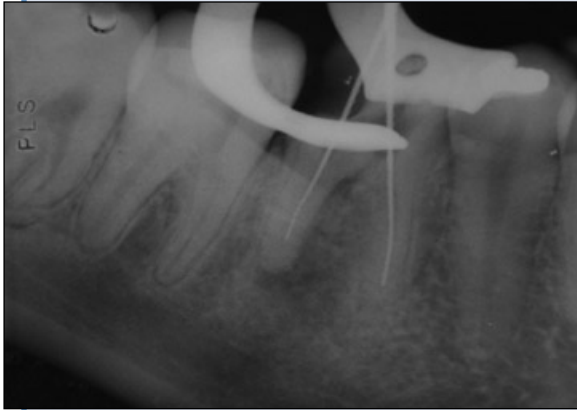
### Case 1

A 27-year-old woman presented with buccal radicular caries, a sinus tract, suppuration, pain on palpation and periodontal breakdown in the furcal region of tooth 36 (Fig. 1a). The patient did not recall when the problem first appeared and stated that the pain had started unexpectedly. The diagnosis was pulpal necrosis with acute periradicular periodontitis and furcation perforation due to dental caries. Treatment options included extraction, bicuspidization and nonsurgical repair of the perforation with MTA. After discussion with the patient, MTA treatment was chosen. A rubber dam was used for isolation, the caries was removed, and the perforation site was irrigated with 1% sodium hypochloride to control hemorrhage and allow visualization of the perforation. Cotton

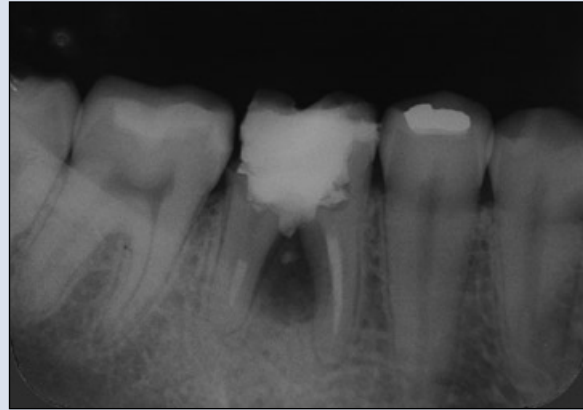
pellets moistened in saline were placed in the root canals, and the perforation was sealed with grey MTA (Angelus, Londrina, Brazil) mixed with sterile saline, as suggested by the manufacturer. The MTA was covered with a cotton pellet moistened with distilled water and Cavit temporary restoration material (3M ESPE, St. Paul, Minn.) (Fig. 1b). Two days after repair of the perforation, the patient underwent nonsurgical root canal treatment without complications. At the 15-day follow-up, the patient was asymptomatic. Three months after the treatment, there was radiographic evidence of bone formation adjacent to the MTA; there was slight extrusion of the material along with the seal of the defect (Fig. 1c). At the last check-up, 2 years after treatment, radiography showed complete osseous healing at the apex and the furcation (Fig. 1d).

### Case 2

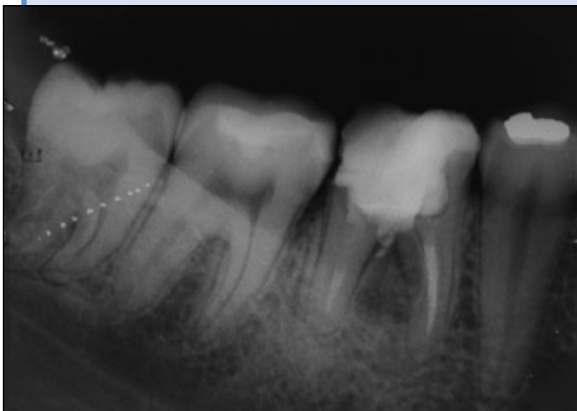A 30-year-old woman presented with accidental furcal perforation, which had occurred during access preparation for root canal treatment of tooth 46. Several treatment options were discussed with the patient, who opted



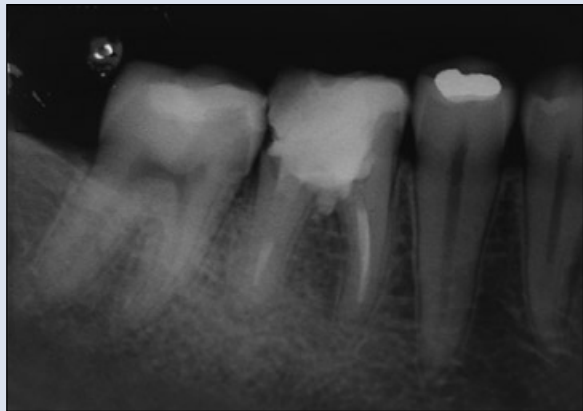
**Figure 2a:** Case 2. Periapical image of tooth 46 showing inadvertent furcal perforation, caused by drilling during access preparation for root canal treatment.



**Figure 2b:** MTA placed with temporary restoration.



**Figure 2c:** Bone formation is visible at 6-month follow-up.



**Figure 2d:** Osseous repair can still be seen at the 5-year follow-up.

for root canal treatment along with repair of the perforation with MTA. The furcal perforation was confirmed by periapical radiography of tooth 46, which revealed osseous breakdown at the furcation (**Fig. 2a**). The root canal treatment was completed, and the pulpal chamber was then irrigated with 1% sodium hypochloride to control hemorrhage and to allow visualization of the perforation. White MTA-Angelus was applied in a manner similar to that described for case 1. The final radiograph obtained at the time of treatment showed evidence that the perforation had been sealed (**Fig. 2b**). Ten days later, the patient was asymptomatic. At the 6-month follow-up, bone formation was evident on radiography (**Fig. 2c**). A radiograph obtained 5 years after treatment showed that the osseous repair had persisted (**Fig. 2d**).

### Discussion

Furcal perforation is an undesirable problem that may occur during root canal treatment or post preparation. Similarly, a risk of perforation may arise during removal of affected tissue in a patient with caries involving

the pulpal chamber. In either case, the situation can be quickly addressed, which is important, as immediate treatment will help ensure a positive prognosis.<sup>4</sup> In the 2 cases presented here, the problem was resolved promptly by application of MTA.

Two major brands of MTA are available on the market: MTA-Angelus (used in the cases described here) and Pro-Root MTA (Maillefer, Dentsply, Switzerland). Both products are available in grey or white. According to the manufacturer's material safety data sheet, Pro-Root MTA is composed of 75% Portland cement, 20% bismuth oxide and 5% dehydrated calcium sulfate. MTA-Angelus is composed of 80% Portland cement and 20% bismuth oxide, with no calcium sulfate.<sup>8</sup> The dominant compounds in both types of Pro-Root MTA are calcium oxide, silica and bismuth. However, the grey version has greater concentrations of aluminum oxide (122% higher), magnesium (130% higher) and iron (1000% increase).<sup>9</sup> Although both the grey and the white versions of Pro-Root MTA perform similarly in terms of furcal sealing<sup>10</sup>

and antimicrobial effectiveness,<sup>11</sup> the grey version has a more favourable behaviour in vitro in terms of development of odontoblasts,<sup>12</sup> whereas the white version is associated with development of cementoblasts and keratinocytes.<sup>13</sup> The white version gives a better final appearance than the original grey MTA, which can create a shadow under thin tissue.<sup>10</sup> Both the grey and the white versions of MTA-Angelus and Pro-Root MTA have numerous similarities: pH 9 after 168 hours,<sup>14</sup> success in dog pulpotomy,<sup>15</sup> minimal concentration of arsenic (0.0002 ppm),<sup>16</sup> overall composition,<sup>8</sup> biocompatibility,<sup>17</sup> inflammatory response,<sup>18</sup> sealant ability,<sup>5</sup> in vitro fibroblastic stimulation<sup>19</sup> and antimicrobial activity.<sup>20</sup> However, MTA-Angelus has greater release of calcium in the first 24 hours of activation<sup>14</sup> and a lower concentration of bismuth (grey version only).<sup>21</sup> In the current report, white MTA-Angelus was used in one case and grey in the other, with similar results.

MTA is difficult to manipulate because of its granular consistency, slow setting time and looseness.<sup>22</sup> Pro-Root MTA contains fewer large particles and fewer small particles than MTA-Angelus. Generally speaking, white MTA contains smaller particles than grey MTA, with a narrower distribution of sizes. MTA-Angelus particles have relatively low sphericity and a wide size distribution, and they are less homogeneous than Pro-Root MTA.<sup>23</sup> The main disadvantage of Pro-Root MTA may be its long setting time. MTA-Angelus contains no calcium sulphate, which reduces its setting time to 10 minutes.<sup>8</sup>

Contamination of the blood should be avoided when using this type of material, as such contamination can reduce the retention capacity of the MTA.<sup>24</sup> Previous authors have stated that contact with adjacent tissues may increase the sealant capacity of MTA, since an acidic environment (such as tissue) may increase this property.<sup>25</sup> In the cases presented here, sealing of the lesions could be observed, with some extrusion of the material. To prevent overfilling or underfilling, a resorbable collagen matrix can be applied before placing the MTA,<sup>24</sup> but use of a matrix depends on the size of the lesion. Success has been reported both with<sup>26</sup> and without<sup>27</sup> the matrix. At present, there is no size classification for furcal lesions to determine appropriate treatment and prognosis; therefore, all options are considered to have a guarded prognosis.<sup>17</sup> In the 2 cases presented here, the lesions were of different sizes. In case 1, the lesion was larger, with irregular limits, characteristic of a V-shaped caries. As shown in **Fig. 1a**, the lesion affected almost the complete dimension of the furcal region, but did not affect the internal walls of the roots; this limited the lesion overall and indicated a lateral boundary against which to place the material. If the lesion had been larger, it would have been necessary to apply a matrix base before placing the MTA. **Figure 1d** shows mild extrusion of the MTA adjacent to the newly formed osseous crest. In case 2,

the lesion was more circumscribed and had a vertical entrance, characteristic of accidental perforation with a diamond bur (**Fig. 2a**); osseous destruction was also greater (**Fig. 2b**). Nevertheless, the use of white MTA in case 2 yielded results similar to those achieved with grey MTA in case 1.

Although use of MTA has been reported for several different endodontic treatments, the literature on its success in cases of furcal perforation is limited. Two common clinical presentations of furcal perforation (related to caries and to accidental drilling) have been described here. Although the prognosis is typically better for smaller lesions (as in case 2), and although the location of these perforations at the level of the epithelial attachment and crestal bone suggested a guarded prognosis,<sup>14</sup> MTA treatment was successful, as indicated by imaging at 2 and 5 years, respectively. ✦

## THE AUTHORS



*Dr. Silveira is a professor in the endodontic specialization program, the University of Ponta Grossa, Ponta Grossa, Brazil.*



*Dr. Sánchez-Ayala is a PhD student in the prosthodontic postgraduate program, faculty of dentistry, University of Campinas, Campinas, Brazil.*



*Dr. Lagravère is a PhD resident in the orthodontic graduate program, faculty of medicine and dentistry, University of Alberta, Edmonton, Alberta.*



*Dr. Pilatti is an associate professor in the integrated clinic postgraduate program, department of dentistry, University State of Ponta Grossa, Ponta Grossa, Brazil.*



*Dr. Gomes is an associate professor in the dentistry postgraduate program, department of dentistry, University State of Ponta Grossa, Ponta Grossa, Brazil.*

**Correspondence to:** Dr. Alfonso Sánchez-Ayala, Limeira 901, Areao, Box 52, CEP: 13414903, Piracicaba – Sao Paulo, Brazil.

*The authors have no declared financial interests in any company manufacturing the types of products mentioned in this article.*

*This article has been peer reviewed.*

## References

1. Tsesis I, Fuss Z. Diagnosis and treatment of accidental root perforations. *Endod Top* 2006; 13:95–107.
2. Al-Daafas A, Al-Nazhan S. Histological evaluation of contaminated furcal perforation in dogs' teeth repaired by MTA with or without internal matrix. *Oral Surg Oral Med Oral Pathol Oral Radiol Endod* 2007; 103(3):e92–9.
3. Roda RS. Root perforation repair: surgical and nonsurgical management. *Pract Proced Aesthet Dent* 2001; 13(6):467–72.



4. Fuss Z, Trope M. Root perforations: classification and treatment choices based on prognostic factors. *Endod Dent Traumatol* 1996; 12(6):255–64.
5. De-Deus G, Reis C, Brandão C, Fidel S, Fidel RA. The ability of Portland cement, MTA, and MTA Bio to prevent through-and-through fluid movement in repaired furcal perforations. *J Endod* 2007; 33(11):1374–7.
6. Torabinejad M, Chivian N. Clinical application of mineral trioxide aggregate. *J Endod* 1999; 25(3):197–205.
7. Roberts HW, Toth JM, Berzins DW, Charlton DG. Mineral trioxide aggregate material use in endodontic treatment: a review of the literature. *Dent Mater* 2008; 24(2):149–64.
8. Oliveira MG, Xavier CB, Demarco FF, Pinheiro AL, Costa AT, Pozza DH. Comparative chemical study of MTA and Portland cements. *Braz Dent J* 2007; 18(1):3–7.
9. Asgary S, Parirokh M, Eghbal MJ, Brink F. Chemical differences between white and gray mineral trioxide aggregate. *J Endod* 2005; 31(2):101–3.
10. Hamad HA, Tordik PA, McClanahan SB. Furcation perforation repair comparing gray and white MTA: a dye extraction study. *J Endod* 2006; 32(4):337–40.
11. Ribeiro CS, Kuteken FA, Hirata Junior R, Scelza MFZ. Comparative evaluation of antimicrobial action of MTA, calcium hydroxide and portland cement. *J Appl Oral Sci* 2006; 14(5):330–3.
12. Perez AL, Spears R, Gutmann JL, Opperman LA. Osteoblasts and MG-63 osteosarcoma cells behave differently when in contact with ProRoot MTA and White MTA. *Int Endod J* 2003; 36(8):564–70.
13. Oviir T, Pagoria D, Ibarra G, Geurtsen W. Effects of gray and white mineral trioxide aggregate on the proliferation of oral keratinocytes and cementoblasts. *J Endod* 2006; 32(3):210–3.
14. Duarte MA, Demarchi AC, Yamashita JC, Kuga MC, Fraga Sde C. pH and calcium ion release of 2 root-end filling materials. *Oral Surg Oral Med Oral Pathol Oral Radiol Endod* 2003; 95(3):345–7.
15. Menezes R, Bramante CM, Letra A, Carvalho VG, Garcia RB. Histologic evaluation of pulpotomies in dog using two types of mineral trioxide aggregate and regular and white Portland cements as wound dressings. *Oral Surg Oral Med Oral Pathol Oral Radiol Endod* 2004; 98(3):376–9.
16. Duarte MA, De Oliveira Demarchi AC, Yamashita JC, Kuga MC, De Campos Fraga S. Arsenic release provided by MTA and Portland cement. *Oral Surg Oral Med Oral Pathol Oral Radiol Endod* 2005; 99(5):648–50.
17. De Deus G, Ximenes R, Gurgel-Filho ED, Plotkowski MC, Coutinho-Filho T. Cytotoxicity of MTA and Portland cement on human ECV 304 endothelial cells. *Int Endod J* 2005; 38(9):604–9.
18. Rezende TM, Vargas DL, Cardoso FP, Sobrinho AP, Vieira LQ. Effect of mineral trioxide aggregate on cytokine production by peritoneal macrophages. *Int Endod J* 2005; 38(12):896–903.
19. Guven G, Cehreli ZC, Ural A, Serdar MA, Basak F. Effect of mineral trioxide aggregate cements on transforming growth factor beta1 and bone morphogenetic protein production by human fibroblasts in vitro. *J Endod* 2007; 33(4):447–50.
20. Tanomaru-Filho M, Tanomaru JM, Barros DB, Watanabe E, Ito IY. In vitro antimicrobial activity of endodontic sealers, MTA-based cements and Portland cement. *J Oral Sci* 2007; 49(1):41–5.
21. Song JS, Mante FK, Romanow WJ, Kim S. Chemical analysis of powder and set forms of Portland cement, gray ProRoot MTA, white ProRoot MTA, and gray MTA-Angelus. *Oral Surg Oral Med Oral Pathol Oral Radiol Endod* 2006; 102(6):809–15.
22. Ber BS, Hatton JF, Stewart GP. Chemical modification of ProRoot MTA to improve handling characteristics and decrease setting time. *J Endod* 2007; 33(10):1231–4.
23. Komabayashi T, Spångberg LS. Comparative analysis of the particle size and shape of commercially available mineral trioxide aggregates and Portland cement: a study with a flow particle image analyzer. *J Endod* 2008; 34(1):94–8.
24. Vanderweele RA, Schwartz SA, Beeson TJ. Effect of blood contamination on retention characteristics of MTA when mixed with different liquids. *J Endod* 2006; 32(5):421–4.
25. Roy CO, Jeansonne BG, Gerrets TF. Effect of an acid environment on leakage of root-end filling materials. *J Endod* 2001; 27(1):7–8.
26. Bargholz C. Perforation repair with mineral trioxide aggregate: a modified matrix concept. *Int Endod J* 2005; 38(1):59–69.
27. Schwartz RS, Mauger M, Clement DJ, Walker WA 3rd. Mineral trioxide aggregate: a new material for endodontics. *J Am Dent Assoc* 1999; 130(7):967–75.

**THE tri hawk<sup>®</sup> Talon™ BUR**

**You just can't beat it for performance!**

- cuts vertically, horizontally, amalgam, crown & bridge
- single use eliminates cleaning, disinfecting



**FOR YOUR FREE SAMPLE, CALL 1.866.TRI HAWK (874.4295)**  
**www.trihawk.com email:TALON@trihawk.com**



## Empowering Your Success

To prepare confidently for the future you've always wanted, turn to CDSPI.

Your CDSPI advisors will lead you through a comprehensive discovery process to understand your most important goals. Then develop financial solutions tailored for your specific needs through the CDA insurance and investment programs.

Like dental practice overhead insurance offering a valuable maternity leave benefit at no additional cost. And the right investment strategies to help you build and manage your wealth.

To learn how to get ahead — and stay there — call CDSPI today.

**1-877-293-9455**    **[www.cdspi.com](http://www.cdspi.com)**

*Restrictions may apply to advisory services in certain jurisdictions.*

**CDSPI**

D E N T I S T S   F I R S T

# Oral Submucous Fibrosis, a Clinically Benign but Potentially Malignant Disease: Report of 3 Cases and Review of the Literature

Ajit Auluck, MDS; Miriam P. Rosin, PhD; Lewei Zhang, BDS, PhD, FRCD(C);  
Sumanth KN, MDS

## Contact Author

Dr. Auluck  
Email: drajitauluck@gmail.com



## ABSTRACT

Oral submucous fibrosis (OSF) is a premalignant condition mainly associated with the practice of chewing betel quid containing areca nut, a habit common among South Asian people. It is characterized by inflammation, increased deposition of submucosal collagen and formation of fibrotic bands in the oral and paraoral tissues, which increasingly limit mouth opening. Recently, OSF has been reported among South Asian immigrants in Canada, the United Kingdom and Germany. Dentists in western countries should enhance their knowledge of this disease as it seems to be increasing with population migration. In this paper, we review the literature on OSF and present 3 cases representing different stages of the disease to help dentists make an early diagnosis and reduce the morbidity and mortality associated with this condition.

For citation purposes, the electronic version is the definitive version of this article: [www.cda-adc.ca/jcda/vol-74/issue-8/735.html](http://www.cda-adc.ca/jcda/vol-74/issue-8/735.html)

Oral submucous fibrosis (OSF) is a disease mainly associated with the chewing of areca nut, an ingredient of betel quid, and is prevalent in South Asian populations. It causes significant morbidity (in terms of loss of mouth function as tissues become rigid and mouth opening becomes difficult) and mortality (when transformation into squamous cell carcinoma occurs). The introduction of chewing tobacco containing areca nut into the market has been associated with a sharp increase in the frequency of OSF.<sup>1</sup> According to Statistics Canada,<sup>2</sup> in 2006 about 1.26 million people in Canada identified themselves as South Asians. With an increase in immigration from South Asia, there will likely be an increase in the frequency of OSF in western

countries (Table 1) including Canada.<sup>3-15</sup> In this article, we review the literature on OSF and present 3 cases to increase awareness of this condition among Canadian dentists.

## Literature Review

### Etiology

The strongest risk factor for OSF is the chewing of betel quid containing areca nut. The amount of areca nut in betel quid and the frequency and duration of chewing betel quid are clearly related to the development of OSF.<sup>16</sup> The direct contact of the quid mixture with oral tissues results in their continuous irritation by various components, including biologically active alkaloids (arecoline,

**Table 1** Summary of oral submucous fibrosis cases reported in western countries

Country	Ethnic origin of patient	Number of cases reported
Canada <sup>3</sup>	India	2
Canada <sup>4</sup>	India	1
Canada <sup>5</sup>	India	3
United Kingdom <sup>6</sup>	Bangladesh	1
United Kingdom <sup>7</sup>	Bangladesh	1
United Kingdom <sup>8</sup>	India (2) Pakistan (1)	3
France <sup>9</sup>	India	1
Germany <sup>10</sup>	India	1
Russia <sup>11</sup>	Greece	1
Melbourne, Australia <sup>12</sup>	India	1
South Africa <sup>13</sup>	India	14
Durban, South Africa <sup>14</sup>	Not mentioned	6
Not available <sup>15</sup>	Saudi Arabia	1

arecaidine, arecolidine, guvacoline, guvacine, flavonoids (tannins and catechins) and copper.

Other factors, such as genetic and immunologic predisposition, probably also play a role as OSF has been reported in families (both children and adults) whose members are not in the habit of chewing betel quid or areca nut.<sup>17</sup>

**Pathogenesis**

The pathogenesis of OSF is not well established, although a number of possible mechanisms have been suggested (Fig. 1). Pathogenesis is believed to involve juxta-epithelial inflammatory reaction and fibrosis in the oral mucosa, probably due to increased cross-linking of collagen through up-regulation of lysyl oxidase activity.<sup>18</sup>

Fibrosis, or the build up of collagen, results from the effects of areca nut, which increases collagen production (e.g., stimulated by arecoline, an alkaloid) and decreases collagen degradation.<sup>19,20</sup> Thus, OSF is now considered a collagen metabolic disorder.<sup>16</sup>

**Clinical Features**

The period between initiation of the chewing habit and the development of clinical symptoms of OSF varies tremendously, ranging from a few months to several decades depending on the type of areca nut consumed, duration and practice of the habit, individual susceptibility and other factors. The symptoms and signs of OSF are due to inflammation and, primarily, fibrosis.

The most common initial symptoms and signs are a burning sensation, dry mouth, blanching oral mucosa and ulceration. The burning sensation usually occurs

while chewing spicy food. Blanching of the oral mucosa is caused by impairment of local vascularity because of increasing fibrosis and results in a marble-like appearance. Blanching may be localized, diffuse or reticular. In some cases, blanching may be associated with small vesicles that rupture to form erosions. Patients complain that these vesicles form after they eat spicy food, suggesting the possibility of an allergic reaction to capsaicin. These features can be observed at all stages of OSF.

In the more advanced stage of the disease, the essential feature is a fibrous band restricting mouth opening and causing difficulty in mastication, speech, swallowing and maintaining oral hygiene. Development of fibrous bands in the lip makes the lip thick, rubbery and difficult to retract or evert; a band around the lips gives the mouth opening an elliptical shape. Fibrosis makes cheeks thick and rigid. When a patient blows a whistle or tries to inflate a balloon, the usual puffed-out appearance of the cheeks is missing. In the tongue, depapillation of mucosa around the tip and lateral margins may occur with blanching or fibrosis of the ventral mucosa. Fibrosis of the tongue and the floor of the mouth interfere with tongue movement. Hard palate involvement includes extensively blanched mucosa.

Fibrosis may extend posteriorly to involve the soft palate and uvula. The latter may appear shrunken and, in extreme cases, budlike. Gingival involvement is relatively uncommon and is characterized by fibrosis, blanching and loss of normal stippling. In rare cases of extensive involvement, there may be loss of hearing due to blockage of Eustachian tubes and difficulty swallowing because of esophageal fibrosis.

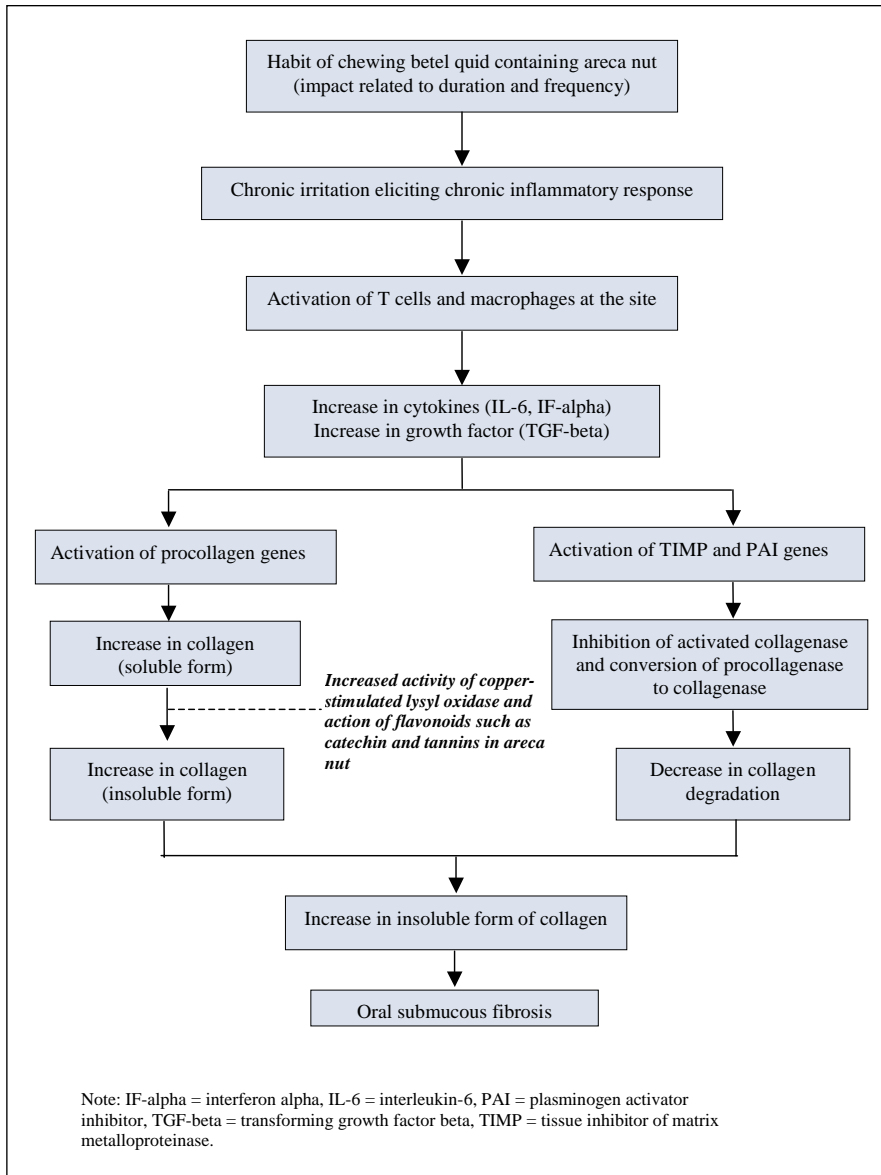
**Pathology**

The initial pathology of OSF is characterized by juxta-epithelial inflammation including edema, large fibroblasts and an inflammatory infiltrate, consisting primarily of neutrophils and eosinophils.<sup>21</sup> Later, collagen bundles with early hyalinization are seen and the acute inflammatory infiltrate contains more chronic cell types, such as lymphocytes and plasma cells, occasionally resembling lichenoid mucositis.

In more advanced stages, OSF is characterized by formation of thick bands of collagen and hyalinization extending into the submucosal tissues and decreased vascularity. The epithelium lining frequently becomes thin and loses melanin or becomes hyperkeratotic. Occasionally dysplastic changes occur in the epithelium. Inflammation and fibrosis of minor salivary glands can also be seen. Muscle degeneration will occur in advanced stages of OSF.

**Treatment**

No known treatment for OSF is effective, although some conservative and surgical interventions may result



**Figure 1:** Etiopathogenesis of oral submucous fibrosis.

in improvement.<sup>7,22</sup> Currently, intralesional steroids are the main treatment modality. These are injected into the fibrotic bands weekly for 6–8 weeks with regular monitoring of mouth opening. Patients are advised to do mouth-opening exercises, for example, by placing ice cream sticks in their mouth and gradually increasing the number. Hyaluronidase,<sup>23</sup> which facilitates the breakdown of connective tissue, can be combined with the steroids for injection.

The list of other treatment modalities (Table 2)<sup>23–31</sup> is extensive and includes use of micronutrients and minerals, carbon dioxide laser, pentoxifylline, lycopene, immunized milk, interferon gamma, turmeric, hyalase, chymotrypsin and collagenase. As fibrosis cannot be reversed, when mouth opening is severely limited surgical

interventions, such as myotomy, coronoidectomy<sup>32</sup> and excision of fibrotic bands, are required. Reconstruction using such techniques as buccal pad flap, superficial temporal flap and forearm flap, can also be performed.<sup>22,33,34</sup> Alternative procedures, such as insertion of an oral stent, physiotherapy, local heat therapy, mouth exercises using acrylic carrots and ice cream sticks, have been tried with variable rates of success.

In most cases, depending on the stage of disease and extent of oral involvement, therapy consisting of a combination of the above-mentioned drugs and surgery might be useful.

### Outcome

Outcomes of OSF are characterized by 2 features: the persistence of the disease and its potential to become malignant.

OSF does not regress spontaneously or on cessation of areca nut chewing. Once the disease is present, it either persists or becomes more severe with involvement of additional areas of the oral mucosa.<sup>35</sup>

OSF is strongly associated with a risk of oral cancer, although the biology underlying this association is still unresolved.<sup>36</sup> OSF may cause atrophy in the epithelium, increasing carcinogen penetration. Studies suggest that dysplasia is seen in about 25% of biopsied OSF

cases and the rate of transformation to malignancy varies from 3% to 19%.<sup>37</sup>

### Case Reports

#### Case 1

A 23-year-old man presented with a complaint of a burning sensation in the buccal mucosa while chewing spicy food, but no other systemic or dermatologic problem. The patient reported a habit of chewing dried areca nut powder 3–4 times a day for the past 2–3 years. He occasionally mixed calcium oxide with the areca nut powder and drank alcohol (approximately 750 mL of local undistilled alcohol) on weekends for the previous 5 years. His mouth opening was normal. Intraoral examination revealed that his entire oral mucosa was pale,

**Table 2** Treatment modalities for oral submucous fibrosis

Treatment	Treatment details
Micronutrients and minerals <sup>24</sup>	Vitamin A, B complex, C, D and E, iron, copper, calcium, zinc, magnesium, selenium and others
Milk from immunized cows <sup>25</sup>	45 g milk powder twice a day for 3 months
Lycopene <sup>26</sup>	8 mg twice a day for 2 months
Pentoxifylline <sup>27</sup>	400 mg 3 times a day for 7 months
Interferon gamma <sup>28</sup>	Intralesional injection of interferon gamma (0.01–10.0 U/mL) 3 times a day for 6 months
Steroids <sup>29</sup>	Submucosal injections twice a week in multiple sites for 3 months
Steroids <sup>29</sup>	Topical for 3 months
Hyalase + dexamethasone <sup>23</sup>	—
Placental extracts <sup>23</sup>	—
Turmeric <sup>30</sup>	Alcoholic extracts of turmeric (3 g), turmeric oil (600 mg), turmeric oleoresin (600 mg) daily for 3 months
Chymotripsin, hyaluronidase and dexamethasone <sup>31</sup>	Chymotripsin (5000 IU), hyaluronidase (1500 IU) and dexamethasone (4 mg), twice weekly submucosal injections for 10 weeks

especially the buccal mucosa, which showed areas of erosion (**Fig. 2**), and the hard palate, which was completely blanched. His tongue, uvula and soft palate were normal. No fibrotic bands were palpable in the oral cavity.

A biopsy of the buccal mucosa showed nonspecific ulcer and mucositis consisting of prominent fibroblasts, increased vascularity, edema and an inflammatory infiltrate that included numerous neutrophils and eosinophils. Although histologic evidence alone was not specific, it was highly consistent with OSF when considered in combination with the patient's chewing habit and clinical presentation. A diagnosis of early OSF was made. This patient was advised to stop chewing areca nut and return for follow-up in 1 month. He did not return until 8 months later, when he had developed difficulty in mouth opening. He had not stopped chewing areca nut although he reported a reduction in frequency of use.

### Case 2

A 43-year-old woman presented with a complaint of progressive difficulty in opening her mouth over the past 2 years. She had a longstanding habit of chewing fresh areca nut (4–5 pouches a day for 20–25 years). Examination revealed that her lips were thin and her mouth opening was limited to about 26 mm (average normal opening is 40 mm). There was erosion at the corners of her mouth (**Fig. 3**). The entire oral mucosa was pale, with focal blanched areas (**Fig. 4**). The tongue was devoid of papillae and extensive fibrosis had occurred on its ventral surface and the floor of the mouth (**Figs. 3 and 5**). The patient could not stick out her tongue or touch the hard palate with the tip of her tongue.

Thick fibrotic bands were palpable bilaterally on the buccal mucosa. Intraoral examination was problematic as it was difficult to retract the patient's fibrotic cheeks. During examination the mirror often stuck to the oral mucosa, suggesting dry mouth. When the patient was asked to blow out air with closed lips, the usual puffed-cheek appearance was not seen, suggesting loss of cheek elasticity. General examination was normal.

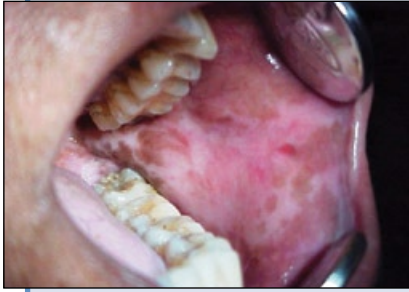A diagnosis of OSF at a moderately advanced stage was made based on the characteristic oral features: generalized blanching of mucosa, extensive fibrosis and limited mouth opening.

### Case 3

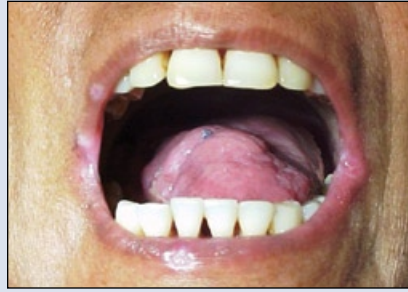A 60-year-old man, with diagnosed OSF of 10 years duration, reported to our clinic for evaluation of a swelling in his cheek and on the floor of the mouth apparent for the past 6 months. The patient had begun treatment with intralesional steroids 10 years earlier on diagnosis of OSF. However, after a few visits, he ceased treatment and continued to chew areca nut over subsequent years.

His mouth opening was restricted to about 16 mm. His oral cavity was fully blanched and the buccal mucosa completely fibrotic. The uvula was fibrotic and deformed (**Fig. 6**). The tongue was completely devoid of papillae. A diagnosis of OSF at an advanced stage was made based on the habit and the classical clinical presentation.

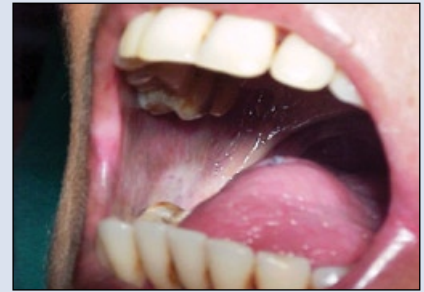In addition to the above changes, 2 masses were noted. One mass (about 3 × 2 cm) with an irregular margin was located on the right buccal mucosa extending from the corner of his mouth to the molar area. It was firm on palpation and fixed to the underlying tissues. The mucosa surrounding the mass was indurated. The other mass, about 1 cm in diameter, was on the floor of the mouth, in the lingual sulcus of the right mandibular premolar region. Its surface had numerous small finger-like projections (**Fig. 7**). On palpation, the swelling was firm and fixed to the underlying structures; however, a panoramic radiograph revealed no bony involvement. Biopsies of both masses revealed squamous cell carcinoma.



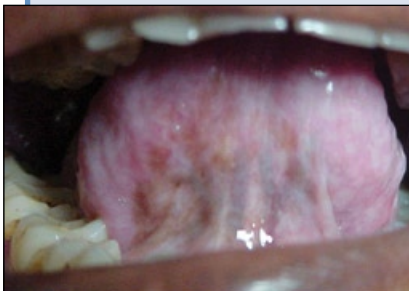**Figure 2:** Case 1. Intraoral photograph of the buccal mucosa showing blanching oral mucosa with erosions in the initial stages of oral submucous fibrosis.



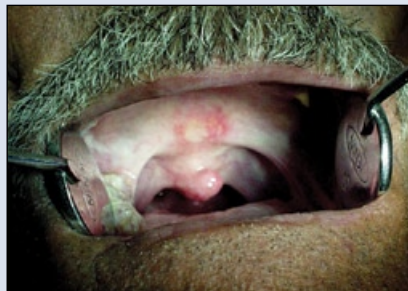**Figure 3:** Case 2. Extraoral photograph showing reduced mouth opening with atrophied lips and erosions at the corners of the mouth.



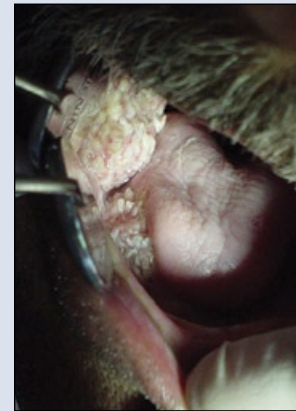**Figure 4:** Case 2. Intraoral photograph showing blanching fibrosed oral mucosa and restricted mouth opening.



**Figure 5:** Case 2. Intraoral photograph showing extensive blanching and fibrosis of the ventral surface of the tongue.



**Figure 6:** Case 3. Intraoral photograph showing fibrosed and deformed uvula and a small ulcer in the palate.



**Figure 7:** Case 3. Intraoral photograph showing 2 proliferative growths in the buccal mucosa and sulcus (because of restricted mouth opening, it was impossible to obtain a high-quality image).

## Discussion

The 3 cases reported here represent different stages of OSF. In the first case, the disease was at a very early stage and the patient showed the classical clinical presentation of burning sensation, ulceration, localized areas of pale and blanching mucosa and a habit of chewing areca nut. This case illustrates the importance of clinical information, as a diagnosis of early-stage OSF cannot be based on histology alone but rather on a combination of histology, chewing habit and clinical information. It is critical to provide the pathologist with clinical information. In the second case, the disease was at a more advanced stage, and the patient showed diffuse blanching and fibrosis of the oral mucosa. In the third case, an advanced stage of OSF, the patient had diffuse oral fibrosis and severely limited ability to open his mouth. In addition, 2 late-stage squamous cell carcinomas were found, a disease associated with a poor survival rate in the late stages.

The rate of development of OSF varied among the 3 patients. The first patient developed early OSF after only 2–3 years of chewing areca nut, whereas the second developed the disease only after more than 20 years of using areca nut. The first patient went on to experience difficulty in mouth opening in a short time (8 months) despite a reduction in areca nut use.

The cases illustrate the relentless progression of OSF and its significant morbidity and mortality; they also emphasize the importance of close follow-up of such cases. Because of the significant cancer risk among these patients, periodic biopsies of suspicious regions of the oral mucosa are essential for early detection and management of high-risk oral premalignant lesions and prevention of cancer. Dentists can play an important role in both the education of patients about the perils of chewing betel quid and in the early diagnosis of high-risk premalignant lesions and cancer. ♦

## THE AUTHORS



**Dr. Auluck** is a PhD student in the British Columbia Oral Cancer Prevention Program, oral medicine and pathology, faculty of dentistry, University of British Columbia, Vancouver, British Columbia.



**Dr. Rosin** is a professor and director, Cancer Control Research, British Columbia Cancer Agency, Vancouver, British Columbia.



**Dr. Zhang** is professor and chair of oral medicine and pathology, faculty of dentistry, University of British Columbia, Vancouver, British Columbia.



**Dr. KN** is an associate professor of oral medicine and radiology, Manipal College of Dental Sciences, Mangalore, India.

**Correspondence to:** Dr. Ajit Auluck, British Columbia Oral Cancer Prevention Program and Faculty of Dentistry, University of British Columbia, Room No. 2-119, 675 West 10th Avenue, Vancouver BC V5Z 1L3.

The authors have no declared financial interests.

This article has been peer reviewed.

## References

- Nair U, Bartsch H, Nair J. Alert for an epidemic of oral cancer due to use of the betel quid substitutes gutkha and pan masala: a review of agents and causative mechanisms. *Mutagenesis* 2004; 19(4):251–62.
- Statistics Canada. 2006 census: Ethnic origin, visible minorities, place of work and mode of transportation. *The Daily* 2008; April 2. Available: [www.statcan.ca/Daily/English/080402/d080402a.htm](http://www.statcan.ca/Daily/English/080402/d080402a.htm) (accessed 2008 July 20).
- Morawetz G, Katsikeris N, Weinberg S, Listrom R. Oral submucous fibrosis. *Int J Oral Maxillofac Surg* 1987; 16(5):609–14.
- Hayes PA. Oral submucous fibrosis in a 4-year-old girl. *Oral Surg Oral Med Oral Pathol* 1985; 59(5):475–8.
- Hardie J. Oral submucous fibrosis. A review with case reports. *J Can Dent Assoc* 1987; 53(5):389–93.
- Shah B, Lewis MA, Bedi R. Oral submucous fibrosis in a 11-year-old Bangladeshi girl living in the United Kingdom. *Br Dent J* 2001; 191(3):130–2.
- Yusuf H, Yong SL. Oral submucous fibrosis in a 12-year-old Bangladeshi boy: a case report and review of literature. *Int J Paediatr Dent* 2002; 12(4):271–6.
- McGurk M, Craig GT. Oral submucous fibrosis: two cases of malignant transformation in Asian immigrants to the United Kingdom. *Br J Oral Maxillofac Surg* 1984; 22(1):56–64.
- Vilmer C, Civatte J. [Oral submucous fibrosis. Review of the literature apropos of a case]. *Ann Dermatol Venereol* 1986; 113(2):107–12. French.
- Reichart PA, Philipsen HP. [Oral submucous fibrosis in a 31-year-old Indian women: first case report from Germany]. *Mund Kiefer Gesichtschir* 2006; 10(3):192–6. German.
- Laskaris G, Bovopoulou O, Nicolis G. Oral submucous fibrosis in a Greek female. *Br J Oral Surg* 1981; 19(3):197–201.
- Oliver AJ, Radden BG. Oral submucous fibrosis. Case report and review of the literature. *Aust Dent J* 1992; 37(1):31–4.
- Seedat HA, van Wyk CW. Submucous fibrosis (SF) in ex-betel nut chewers: a report of 14 cases. *J Oral Pathol* 1988; 17(5):226–9.
- Seedat HA, van Wyk CW. Submucous fibrosis in non-betel nut chewing subjects. *J Biol Buccale* 1988; 16(1):3–6.
- Mani NJ, Kim HW, Sastry KA. Oral submucous fibrosis in a Saudi female. *Ann Dent* 1985; 44(2):12–3.
- Rajalalitha P, Vali S. Molecular pathogenesis of oral submucous fibrosis — a collagen metabolic disorder. *J Oral Pathol Med* 2005; 34(6):321–8.
- Rajendran R, Vidyarani. Familial occurrence of oral submucous fibrosis: report of eight families from northern Kerala, south India. *Indian J Dent Res* 2004; 15(4):139–44.
- Trivedy CR, Warnakulasuriya KA, Peters TJ, Senkus R, Hazarey VK, Johnson NW. Raised tissue copper levels in oral submucous fibrosis. *J Oral Pathol Med* 2000; 29(6):241–8.
- Shieh TY, Yang JF. Collagenase activity in oral submucous fibrosis. *Proc Natl Sci Counc Repub China B* 1992; 16(2):106–10.
- Yang SF, Hsieh YS, Tsai CH, Chen YJ, Chang YC. Increased plasminogen activator inhibitor-1/tissue type plasminogen activator ratio in oral submucous fibrosis. *Oral Dis* 2007; 13(2):234–8.
- Chiang CP, Hsieh RP, Chen TH, Chang YF, Liu BY, Wang JT, and others. High incidence of autoantibodies in Taiwanese patients with oral submucous fibrosis. *J Oral Pathol Med* 2002; 31(7):402–9.
- Lai DR, Chen HR, Lin LM, Huang YL, Tsai CC. Clinical evaluation of different treatment methods for oral submucous fibrosis. A 10-year experience with 150 cases. *J Oral Pathol Med* 1995; 24(9):402–6.
- Kakar PK, Puri RK, Venkatachalam VP. Oral submucous fibrosis — treatment with hyalase. *J Laryngol Otol* 1985; 99(1):57–9.
- Maher R, Aga P, Johnson NW, Sankaranarayanan R, Warnakulasuriya S. Evaluation of multiple micronutrient supplementation in the management of oral submucous fibrosis in Karachi, Pakistan. *Nutr Cancer* 1997; 27(1):41–7.
- Tai YS, Liu BY, Wang JT, Sun A, Kwan HW, Chiang CP. Oral administration of milk from cows immunized with human intestinal bacteria leads to significant improvements of symptoms and signs in patients with oral submucous fibrosis. *J Oral Pathol Med* 2001; 30(10):618–25.
- Kumar A, Bagewadi A, Keluskar V, Singh M. Efficacy of lycopene in the management of oral submucous fibrosis. *Oral Surg Oral Med Oral Pathol Oral Radiol Endod* 2007; 103(2):207–13. Epub 2006 Oct 24.
- Rajendran R, Rani V, Shaikh S. Pentoxifylline therapy: a new adjunct in the treatment of oral submucous fibrosis. *Indian J Dent Res* 2006; 17(4):190–8.
- Haque MF, Meghji S, Nazir R, Harris M. Interferon gamma (IFN-gamma) may reverse oral submucous fibrosis. *J Oral Pathol Med* 2001; 30(1):12–21.
- Borle RM, Borle SR. Management of oral submucous fibrosis: a conservative approach. *J Oral Maxillofac Surg* 1991; 49(8):788–91.
- Hastak K, Lubri N, Jakhi SD, More C, John A, Ghaisas SD, and other. Effect of turmeric oil and turmeric oleoresin on cytogenetic damage in patients suffering from oral submucous fibrosis. *Cancer Lett* 1997; 116(2):265–9.
- Gupta D, Sharma SC. Oral submucous fibrosis — a new treatment regimen. *J Oral Maxillofac Surg* 1988; 46(10):830–3.
- Chang YM, Tsai CY, Kildal M, Wei FC. Importance of coronoidotomy and masticatory muscle myotomy in surgical release of trismus caused by submucous fibrosis. *Plast Reconstr Surg* 2004; 113(7):1949–54.
- Mokal NJ, Raje RS, Ranade SV, Prasad JS, Thatte RL. Release of oral submucous fibrosis and reconstruction using superficial temporal fascia flap and split skin graft — a new technique. *Br J Plast Surg* 2005; 58(8):1055–60. Epub 2005 Aug 1.
- Lee JT, Cheng LF, Chen PR, Wang CH, Hsu H, Chien SH, and other. Bipaddled radial forearm flap for the reconstruction of bilateral buccal defects in oral submucous fibrosis. *Int J Oral Maxillofac Surg* 2007; 36(7):615–9. Epub 2007 May 11.
- Hammer JE, Mehta FS, editors. Tobacco related oral mucosal lesions and conditions in India. Mumbai: Basic Dental Research Unit, Tata Institute of Fundamental Research; 1993. p. 67.
- Mithani SK, Mydlarz WK, Grumbine FL, Smith IM, Califano JA. Molecular genetics of premalignant oral lesions. *Oral Dis* 2007; 13(2):126–33.
- Murti PR, Bhonsle RB, Pindborg JJ, Daftary DK, Gupta PC, Mehta FS. Malignant transformation rate in oral submucous fibrosis over a 17-year period. *Community Dent Oral Epidemiol* 1985; 13(6):340–1.



### Guaranteed access to Canada's largest audience of dentists

Direct orders and enquiries to:

**John Reid**, ext. 23  
jreid@keithhealthcare.com

**c/o Keith Communications Inc.**  
104-1599 Hurontario St.  
Mississauga, ON L5G 4S1  
Tel.: 1-800-661-5004  
(905) 278-6700  
Fax: (905) 278-4850

Placement of ads by telephone  
not accepted.

#### DEADLINE DATES

Issue	Closing Date
November	October 10
December/January	November 10

#### Send all box number replies to:

Box ... JCDA  
104-1599 Hurontario St.  
Mississauga, ON L5G 4S1

The names and addresses of advertisers using box numbers are held in strict confidence.

#### DISPLAY ADVERTISING

**RATES** (Regional rates available upon request)

1 page.....2665	1/3 page ..970
2/3 page ....1890	1/4 page ..840
1/2 page ....1420	1/8 page...455

#### REGULAR CLASSIFIED RATES

\$145 for the first 50 words or fewer, each additional word \$1.15. Reply box numbers \$27 (first insertion only).

Special Display (2 1/8" x 2 1/8") \$295.

All advertisements must be prepaid.

**10% DISCOUNT TO CDA MEMBERS.**

The classified ads are published in the language of submission.

#### Offices and Practices

**ALBERTA - Edmonton:** Established family-oriented dental practice for sale; west central location. Low overhead office with 4 operatories (another plumbed), Panorex. Owner can stay on for smooth transition. Reply in confidence to: (780) 299-2958 to leave message. D4709

**ALBERTA - Edmonton:** Well-established family practice for sale in West Edmonton area in a very pleasant community. Three operatories, low rent and highly profitable. Great opportunity for dentist who wants to start with low investment and great new patient flow. Available immediately. Please call Ephraim Baragona: (780) 487-1010 or (780) 904-2619. Email: egbar@telus.net. D4732

**ALBERTA - Lac La Biche:** Busy, established general practice in Northern Alberta lake-land area with 3 operatories and plumbed for a fourth. Practice has excellent long-term staff and is dental hygienist supported. Dentist retiring. Contact Dr. Ronald Gee at: (780) 623-4910 or email at: rgeellb@gmail.com. D4691

**BRITISH COLUMBIA - Abbotsford:** Established Abbotsford endodontist has office space to share or transfer to a general dentist or specialist. Central location with ground level access and parking. Phone: (604) 504-7668 or fax: (604) 504-7669. D4770

**BRITISH COLUMBIA - Clearwater:** Established low overhead, high profit and stress free dental practice for sale, lease, or associate position ASAP. Surrounded by beautiful lakes, rivers, mountains and gorgeous Wells Gray Park, this is the only practice in

a radius of 120km. 1-1/4 hour drive to Kamloops plus 1 hour flight to Vancouver is excellent opportunity to make tons of money while able to live 2-3 days a week in big cities. Real estate available to purchase if desired. Vendor is relocating out of country for other opportunities. Very reasonably priced. Email: toma2@telus.net. D4842

**BRITISH COLUMBIA - Delta:** Professional building. Cost-sharing arrangement, total 2890 sq. ft., 3 large operatories with state-of-the-art equipment, long est., exc. clientele, good gross approximately \$750K with room to grow as seller only working part time. Wonderful staff. Owner retiring but will assist in transition if necessary. Phone Dr. Robert J. Holditch: (604) 599-5600 or email: robertholditch@hotmail.com. D4831

**BRITISH COLUMBIA - Okanagan:** Enjoy living in the beautiful Okanagan Valley where you will anxiously await all four seasons. Excellent opportunity to be part of a well-established practice with untapped potential for exceptional growth. Existing dentist would like an associate/partner (cost sharing) to service the increasing demand for dental care in the area. Enjoy life working daytime weekdays and have a partner to share costs and management responsibilities with while making more money at the end of the day. Successful candidate must associate first with agreement to buy in. Associateship without purchase agreement is also an option. Email: daisey09@telus.net. D4779

**BRITISH COLUMBIA - Prince George:** State of the art 6 operatory clinic with ceramic lab on site, 3 full-time hygienists and 2400+ ACTIVE

recall patients awaits you here in the heart of beautiful BC. General practice in accessible downtown location, long term lease, modern top of the line finishes and even a Koi pond! PG is a university town that attracts professionals from across the country! Vendor offers flexible transition terms. Contact Nadean Burkett via email: burkett@dentalbusiness.ca or phone: (604) 939-5009. D4809

**BRITISH COLUMBIA - Shuswap/North Okanagan:** Enjoy the outdoors and amenities of Shuswap Lake in this turn-key 3+ operatory, well managed and nicely equipped, productive family practice in Salmon Arm, B.C. Strong dental team willing to transition to new owner/operator. Vendor is retiring - flexible on terms and price to your benefit. Building ownership is also offered - be your own landlord! Contact Nadean Burkett confidentially via email: burkett@dentalbusiness.ca or phone her at: (604) 939-5009 to get all the details of how you can work and play in the beautiful and popular Shuswap Lake area. D4808

**BRITISH COLUMBIA - South Vancouver Island:** Live the island lifestyle! Four operatory, recently extensively remodelled and upgraded clinic with full time hygiene. This busy, productive general practice is located in a popular, upscale residential neighbourhood and serves an highly retentive adult-oriented patient base. Vendor is retiring and offers flexible transition terms. Fully documented practice valuation. Contact Nadean Burkett via email: burkett@dentalbusiness.ca or phone: (604) 939-5009. D4810

**BRITISH COLUMBIA - Vancouver:** Endodontic specialty practice. Full-time endodontic practice for sale. Large referral base. High income, low overhead. Four operatories. Owner retiring but will transition to suit. Contact: mackenz@telus.net. Phone: (604) 685-9227. D3805

**NOVA SCOTIA - Halifax:** 35 minutes from Halifax. "Goldmine for sale" - 36 year old dental practice (28 years in same location). High gross, low overhead, low stress. Dental practice and building (free standing). Transition period very flexible. Golf courses (3) within 10 minutes; skiing, universities (9) within easy commute. This practice has given me a lifestyle that I could only dream about. Contact: Cameronlove@aol.com or phone: (902) 228-2795. D4735

**NUNAVUT - Iqaluit:** \$1 Million clinic for sale in Iqaluit, Nunavut. Very productive and successful, 7 year old, 3 operatory clinic for sale for \$225,000. Gross productivity for 2007 exceeded \$1 million. For details email: drg@stillwatersdental.com. D4797

**ONTARIO - GTA:** Practices Wanted! Altima Dental Canada seeks to purchase 5 additional practices within 1 hour of the Greater Toronto Area, to complement our existing 20 locations. Thinking about selling? Contact us about our exciting purchase incentives. Call Dr. George Christodoulou at: (416) 785-1828, ext. 201, or email: drgeorge@altima.ca. Website: www.altima.ca. D2915

**ONTARIO - Ottawa:** Dental office for sale in Ottawa (Orleans). Four fully equipped operatories. Satellite office opened 6 months ago, superb location and modern construction. French speaking clientele with 100% insurance coverage. Region in vast development. Dentist occupied with his main office. Please contact Dr. Rizk or Roseanne: (613) 232-9282. D3595

**SASKATCHEWAN - Rocanville:** Growing, family-oriented community in rural S.E. Saskatchewan, population 1,000, requires a dentist to open a practice. Local employer, Potash Corp., is expanding, creating 280 permanent jobs after 2.8 billion dollar expansion. Residents must currently travel out of town for dental services. Please call Traci Burke B.S.P.: (306) 645-2633 day,

(306) 645-2890 evening, (306) 645-2175 fax, or send email to: tracib@superthrifty.com. D4841

## Positions Available

**ALBERTA - Calgary/Edmonton:** Experienced associate required for our well-established, busy practices in Calgary. For more information visit our website at: www.ihp.ca or contact Dr. George Christodoulou, tel.: 1 (888) 81SMILE ext. 201, or via email: drgeorge@ihp.ca. D2691

**ALBERTA - Calgary:** Great downtown Calgary location, offering no weekend or evening hours, seeking a full-time associate. Newly renovated office with digital radiographs, hygienist, and wonderful staff. Have autonomy in a remarkable environment. Email: info@dentalchoice.ca or fax Candice at: (780) 444-9411. D4678

**ALBERTA - Calgary:** Pediatric dentist is required for a caring, preventive-oriented, idealistic private pediatric practice. Hospital affiliation is necessary. This position is as an associate leading to role reversal through practice purchase. For further information please contact: (403) 248-5015. or email: narveyipc@telus.net D4663

**ALBERTA - Calgary:** Excellent opportunity for part-time/full-time associateship in a busy solo family-oriented practice in SW Calgary. Associate position available for immediate start. Right individual must be able to work some evenings and/or Saturdays. Please fax your resume to: (403) 201-6964 or email resume to: drmaiga@telus.net. New grads welcome. D4739

**ALBERTA - Calgary:** High-end practice searching for an experienced associate. Our current associate is relocating and an opportunity has now opened in our well-established dental practice with a large, regular patient base and strong hygiene and recare program. Our non-assignment

practice offers extended hours to patients where fees are consistently 30% greater than the fee schedule. We look forward to hearing from enthusiastic, skilled applicants who wish to participate on a friendly and supportive team. Please reply to: dentalprofessionalcalgary@gmail.com. D3827

**ALBERTA - Calgary:** Full-time associate required for progressive, busy, well established SE family practice. Digital radiography, computerized operatories, Cerec, neuromuscular, implants, and orthodontics. Tons of potential for the right candidate, excellent patients and long-term staff. Come join our team! Please email resume in confidence to: drcpatton@shaw.ca. D4756

**ALBERTA - Calgary:** Full-time associate required for a busy, well-established family practice in NW Calgary. Healthy new patient base with excellent growth potential. Great opportunity for a motivated, team-oriented individual with good communication skills. Must be flexible to work some evenings and weekends. Please forward resume to: careteeth@gmail.com. D4791

**ALBERTA - Didsbury:** Associate required for a busy, well-established family dental practice located 45 minutes north of Calgary. We offer all aspects of general dentistry, modern equipment, an excellent hygiene program and a terrific team to work with. Please fax your resume to: (403) 335-8625 or email resume to: drmcracken@shaw.ca. New grads welcome. D2919

**ALBERTA - Drumheller:** Full-time associate position(s) available. Very lucrative, well-established, low stress family practice located in Drumheller, AB, 80 minutes east of Calgary. One position available immediately, however a two-dentist team would be ideal. Transition from associate to future owner is offered with very agreeable terms. Hospital privileges available. Email resume Attn: Dr. Poznikoff to: rdc@magtech.ca or fax: (403) 823-3844. D4696

**ALBERTA - Edmonton:** Experienced associate required for great opportunity in a busy, well-established practice close to downtown for 4-5 days/week. No evenings or weekend hours. All applications kept strictly confidential. Fax Candice at: (780) 444-9411 or email: candice@dentalchoice.ca. D4705

**ALBERTA - Edmonton:** Experienced associate required for great opportunity in a busy, well-established practice close to downtown for 4-5 days/week. No evenings or weekend hours. All applications kept strictly confidential. Fax Candice at: (780) 444-9411 or email: candice@dentalchoice.ca. D4705

**ALBERTA - Edmonton:** Excellent opportunity available immediately. Full-time associate needed for busy, well-established practice in SW Edmonton. This is a family-oriented practice located in a rapidly growing community with great new patient flow. Potential for future buy-in. Please fax resume to: (780) 988-8795 or email to: c-chow@shaw.ca. D3417

**ALBERTA - Cold Lake:** The perfect opportunity awaits an ambitious associate to join our friendly and dedicated team at Alberta's best kept secret. We offer patients all areas of general dentistry including implants, Invisalign, orthodontics and sedation dentistry. Please contact Bettina at: (780) 594-5056 fax: (780) 594-5965 email: drtlowry@shawcable.com. D4760

**ALBERTA - Fort McMurray:** Be a part of the action! Excellent full-time GP associate opportunity immediately available in the fastest growing place in Canada. Need 1 or 2 highly motivated, energetic individuals who want to make a ton of money! Rapidly expanding family practice in Fort McMurray, Alta., has an excellent team already established but can't keep up. Rotary endo and Cerec already in place. Don't miss out on making more money than you ever dreamed possible. Please phone: (780) 743-3570 or fax to: (780) 790-0809. D1817

**ALBERTA - Grande Prairie:** Rewarding associateship in busy, growing Grande Prairie. Vibrant, well established, high grossing, family dental practice. Excellent, motivated staff. Please call: (780) 539-6769, fax: (780) 538-2387, or email: wpiepgrass@msn.com. D4847

**ALBERTA - Grande Prairie:** Associate required for a busy, well-established family dental practice. We offer all aspects of general dentistry, an excellent hygiene program and a terrific team to work with. Please fax your resume to: (403) 335-8625 or email resume to: drmcracken@shaw.ca. New grads welcome. D2571

**ALBERTA - Provost:** Busy full-time practice seeking positive and motivated associate to join our team. Potential for buy in and mentorship available, flexible hours and pay. Possible accommodation and vehicle expense. New grads welcome, position available ASAP. Phone: (778) 688-7526, email: somakk@hotmail.com. D4804

**ALBERTA - Red Deer:** Progressive cosmetic/family practice searching for long-term mutual visionary (associate/partner) ready to excel along with us and the rapid growth of Red Deer. Located exactly between Calgary and Edmonton at the foothills of the Rocky Mountains, Red Deer has the smaller city lifestyle with the big city opportunities. Computerized, laser, Cerec 3-D and digital ready are available for expanded options of patient care. New grads welcome with easy ownership program available. Feel free to call: (403) 309-4600 or fax your resume to: (403) 340-0078. Confidence with confidentiality can be assured by emailing: appleway@telus.net. D2938

**ALBERTA - Red Deer:** Associate wanted for well established, newly renovated 8 operatory office. Excellent patient flow, computerized operatories, digital radiography, Cerec 3D. New grads welcome. To further discuss this

opportunity, contact Dr. Ryan Fleming: ryan@ocudent.ca or Dr. Tony Odenbach: tony@ocudent.ca. Call: (403) 347-7467. D4782

**ALBERTA - Stony Plain:** Twenty minutes to Edmonton. Full-time associate required to take over existing client base in group practice with good hygiene program. Experience an asset due to heavy patient load, but will consider a recent grad. We need an enthusiastic, people-friendly individual to join us. Future buy-in possible. Dr. Ron Turner. Fax: (780) 963-2904 email: rgtturner@telus.net. D4598

**ALBERTA - Valleyview:** Associate position available immediately. Existing patient base, high percentage paid, choose your lifestyle. No evenings or weekends. Full or part time. Fast growing region with a balanced economy. Local government in planning stages of new Health Care Centre where practice will be relocating. Be in on ground floor with affordable ownership

option possible. Apply to Dr. Darryl R. Smith: (780) 957-0442 (home) or: fishdoc@telusplanet.net. D4816


**BRITISH COLUMBIA - Chilliwack:** Full time associate position available to dentist committed to continuing education/excellence in patient care. Area offers year-round recreation including skiing, boating, hiking, etc. 100 km east of Vancouver. There is potential for partnership. Reply to: Dr. Michael Thomas, Ste. 102-45625 Hodgins Ave., Chilliwack, BC, V2P 1P2; phone: (604) 795-9818 (res), (604) 792-0021 (bus), fax: (604)792-1318 or email: drthomasoffice@telus.net. D4534

**BRITISH COLUMBIA - Delta:** Part time leading to full time associate required for practice with wonderful patient base. Eventual opportunity for buy in. All aspects of dentistry practiced, with emphasis on crowns & bridges. Please submit resumes to email: robertholditch@hotmail.com. D4830

**BRITISH COLUMBIA - Fort St. John:** Full-time associate needed for busy and profitable practice in North East B.C. Fort St. John is a thriving and growing community which offers small town atmosphere with larger centre amenities. For more information please email: fsjdc@telus.net or call: (250) 785-1867. D4814

**BRITISH COLUMBIA - Maple Ridge:** Full and part time associate position available in a busy family practice. Must be productive and have at least two years experience. Highly lucrative, job satisfaction guaranteed. Modern, state-of-the-art office. Email resume to: kgbrar@hotmail.com. D4815

**BRITISH COLUMBIA - Penticton:** Interesting associate position available. Taking over an existing patient load equals full schedule. Practice the way you want with great team support in a collegial group practice in a new facility. Partnership on the table for future consideration, plus you get to live in Penticton! Contact:


D4593

*Find out why our doctors say that joining a group practice was the best choice they made since choosing dentistry as a profession.*

Our multi-specialty growing group practices are seeking General Dentists and Specialists – full or part-time.

Join our affiliated groups nationwide where flexible work hours are readily available and encouraged. As a valued dentist in our group, you will be eligible for a generous compensation and benefit package, including malpractice, medical, life and disability benefits, and participation in a 401K with employer match.

Please call Anna Robinson at (781) 213-0209  
Email: arobinson@amdpi.com Fax: (781) 224-4216  
For more information, please visit our website at: [www.amdpi.com](http://www.amdpi.com)

**Imagine!**

A balanced lifestyle, outdoor wonders and appealing dental practice.

**Employment Opportunity for Permanent Dentist**

A practice of two Dentists, with clinic operated by United Church Health Services in the beautiful Northern community of **Hazelton BC**. With two assistants, reception and billing provided by United Church Health Services, this is a fantastic opportunity to walk in and begin your practice. Remuneration is based on % of daily production. Housing provided.

For more information Please contact Diane Matheson, Corporate Office Manager, United Church Health Services, Wrinch Memorial Hospital, Bag 999 Hazelton, BC V0J 1Y0  
Ph: 250-842-5556 Fax: 250-842-4621  
E- Diane.Matheson@northernhealth.ca  
Visit our website at [www.uchealth.ca](http://www.uchealth.ca) D3879

**We post your ad online**

FREE

**Place a classified ad in the JCDA and not only is your ad posted to the Internet at no extra cost, it's posted in 2 days or less!**

**Check us out at:**  
[www.cda-adc.ca/jcda](http://www.cda-adc.ca/jcda)

**To place your CDA Classified ad, contact:**

John Reid  
1 800-661.5004 / (905) 278-6700 ext. 23  
Fax: (905) 278.4850  
E-mail: [jreid@keithhealthcare.com](mailto:jreid@keithhealthcare.com)

pentictodontal@shawcable.com if interested. D4752

**BRITISH COLUMBIA - Kelowna:**  
Great opportunity in Kelowna, B.C. Our exceptional practice is experiencing huge growth in our brand new facility with all digital equipment (x-ray, Panorex, Cerec 3D, Casey, Adstra Imaging) and paperless management. This well-managed extremely profitable practice will welcome an ambitious, skilled & caring practitioner. Buy-in offered to the associate with strong leadership and clinical skills. Call: (250) 469-3455. D3740

**BRITISH COLUMBIA - Kelowna:**  
Associate required for new practice in a beautiful location. All operatories are computerized and paperless with digital x-rays. Facility is state of the art with a great staff. Young dentist graduated in 2003. We welcome new grads. Contact Lisa for more information: (250) 868-2221. D4850

**BRITISH COLUMBIA - Revelstoke:**  
Full-time associate required for very busy, well-established general practice in beautiful Revelstoke. Future partnership opportunity for the right candidate. We are Canada's most talked about mountain resort town boasting a booming economy and world class skiing. Check out this mountain paradise online: [www.seerevelstoke.com](http://www.seerevelstoke.com). Please call: (250) 837-9431 evenings or email us at: [schwenck@telus.net](mailto:schwenck@telus.net). D4467

**BRITISH COLUMBIA - Squamish:**  
Like to ski, mountain bike, wind-surf, hike? Busy well-established family practice requires an associate in the fast growing "outdoor recreation capital of Canada". Situated between Vancouver and Whistler, this is an excellent opportunity to establish yourself in the corridor prior to the 2010 Winter Olympics. Please apply to: [applications@parksidedentalgroup.ca](mailto:applications@parksidedentalgroup.ca). D4724

## Head, Department of Dental Diagnostic and Surgical Sciences

Director, Graduate Oral and Maxillofacial Surgery Program

Located in the thriving, multicultural city of Winnipeg, the University of Manitoba offers students and faculty a vibrant learning community, exceptional facilities and the chance to explore ideas, challenge assumptions and turn theory into reality. Our researchers are among the best in the world, finding new ways to protect the environment, improve human health, advance technology and strengthen communities in Canada and beyond. With over 30,000 students, faculty, and staff, and offering 82 degree programs, the University of Manitoba plays a key role in the social, cultural, and economic well-being of our community and our world.



Applications are invited for a full-time, tenure track appointment as an oral and maxillofacial surgeon at the rank of Associate Professor/Professor in the Department of Dental Diagnostic and Surgical Sciences. The position will also include the headship of the department as well as the directorship of the Graduate Oral and Maxillofacial Surgery Program. The headship and directorship appointments are normally for a five-year term, and are renewable. The position start date is January 1, 2009 or as soon thereafter as possible.

The successful candidate must have demonstrated expertise in teaching, research and university or hospital-based specialty training in Oral and Maxillofacial Surgery, which will enable him/her to register as an Oral and Maxillofacial Surgery specialist with the Manitoba Dental Association. Additionally, he/she must possess the Fellowship in Oral and Maxillofacial Surgery from the Royal College of Dentists of Canada within two years of his/her appointment. An MD or PhD in a related area is preferred. Salary will be commensurate with qualifications and experience.

The Department of Dental Diagnostic and Surgical Sciences is responsible for undergraduate teaching in the disciplines of Hospital Dentistry, Oral Diagnosis, Oral and Maxillofacial Surgery, Oral Pathology, Oral Radiology and Periodontology, and for graduate programs in Oral and Maxillofacial Surgery and Periodontology and includes 9 FTE Academic and 4.5 FTE Support Staff. The Division of Oral and Maxillofacial Surgery teach and co-ordinates undergraduate courses in Oral and Maxillofacial Surgery, Pain and Anxiety Control, Medicine, and Hospital Dentistry. The Division also directs the Oral and Maxillofacial Surgical Residency/Graduate Program where the full scope of Oral and Maxillofacial Surgery is practiced and the Graduate Program's faculty and residents are involved in the treatment of high patient volumes in maxillofacial trauma and orthognathic surgery. Excellent relationships exist with other departments and disciplines within the Faculties of Dentistry and Medicine which provide opportunities for collaboration in clinical research and patient care teams, including craniofacial and cleft palate care, head and neck surgical oncology, oral implantology and combined orthognathic treatment with graduate Orthodontics.

The Faculty of Dentistry offers a dental degree program (DMD), a dental hygiene diploma (Dip. Dental Hygiene), a bachelor of dentistry (BSc Dent) and five graduate programs; M.Sc. (Orthodontics), M.Sc. (Oral Biology), Ph.D. (Oral Biology), M.Dent (Oral and Maxillofacial Surgery), and M.Dent (Periodontics).

Considered an area of strength within the University of Manitoba, the Faculty of Dentistry is dedicated to educating dental, dental hygiene and graduate students in a progressive learning environment, conducting research in oral health, and serving the oral health professions and community as a source of knowledge and expertise. Details about the Faculty appear at [www.umanitoba.ca/dentistry](http://www.umanitoba.ca/dentistry). Winnipeg is the largest city in the Province of Manitoba. Learn more about Winnipeg at <http://www.city.winnipeg.mb.ca>.

The University of Manitoba encourages applications from qualified women and men, including members of visible minorities, Aboriginal peoples, and persons with disabilities. All qualified candidates are encouraged to apply, however Canadians and permanent residents will be given priority.

Applications and nominations should be forwarded with curriculum vitae, and the names and addresses of three references, to:

**Dr. Anthony M. Iacopino, Dean**  
Faculty of Dentistry, University of Manitoba  
D113-780 Bannatyne Avenue  
Winnipeg, Manitoba R3E 0W2  
Canada  
Phone: (204) 789-3249  
Fax: (204) 789-3912



**FACULTY OF DENTISTRY**  
SCHOOL OF DENTAL HYGIENE

*Traditions of Excellence, Horizons of Change*

The closing date for applications is **November 1, 2008**. Review of applications will be considered until the position is filled. Please refer to the noted Position # BF722 in all correspondence.

Application materials, including letters of reference, will be handled in accordance with *The Freedom of Information and Protection of Privacy Act* (Manitoba).

**One university.  
Many futures.**



**UNIVERSITY OF MANITOBA**

**BRITISH COLUMBIA - Terrace:** What's your passion? Are you seeking opportunities to learn new skills, or looking to enjoy a lower stress lifestyle? We need another dentist and our well-organized family practice may be the perfect fit for you. Consideration will be given to full-time, part-time, or locum arrangements. Buy-in is possible. This is a great opportunity to be part of a fun and highly successful practice. Apply to: Dr. Dennis Fisher/Dr. Rick Tabata, Attn.: Office Manager, 201-4619 Park Avenue, Terrace, BC, V8G 1V5. Telephone: (250) 638-0841 or fax: (250) 635-4537. D4701

**BRITISH COLUMBIA - Vancouver:** Do you want to be fully booked? Great lifestyle and above average income. Busy suburban expanding group practices. Friendly team, latest equipment, mentorship. Opportunity for F/T experienced GP's, F/T new grads, P/T specialists. www.joinmetro.towndental.com. Call Dr. Joban: (604) 439-0999 ext. 233 or fax: (604) 435-0299.

or visit us online at: www.metro.towndental.com. D4719

**BRITISH COLUMBIA - Vancouver and Surrounding Area:** Certified periodontist, licensed as dentist in British Columbia, available to perform periodontal services, biopsies and train hygienists in your office on a part-time basis. Please email response to: mtp35@hotmail.com. D4755

**BRITISH COLUMBIA - Victoria:** Associate position. Associate to join our diverse and busy treatment centre. Dr. Luckhurst has many years of experience and has taught internationally and has built a well-established practice offering patients family-centred dentistry, restorative, cosmetics, implants, and full mouth rehabilitations. Dr. Luckhurst is looking for a hard working, ethical, professional individual to join our progressive team. Replies to: Dr. A. Luckhurst, phone: (250) 386-3044, fax: (250) 386-3064, email: crluck2@shaw.ca. D3801

**BRITISH COLUMBIA - Victoria:** Associate wanted for progressive, prevention-based, established practice in Victoria, B.C. Flexible working conditions in an office with 10 newly renovated operatories and 4 existing doctors. Suitable for a new grad. Fax resume to: (250) 477-3722 or email: csoul@shaw.ca. D4776

**BRITISH COLUMBIA - White Rock:** Associate F/T Mon-Thurs required for busy, well established group practice. Email: odewatson@hotmail.com or fax: (778) 294-1832. D4823

**MANITOBA - North Central:** Want to be busier and earn what you are worth? We offer a unique practice setting for an eager associate. Do all the forms of dentistry you are comfortable doing a good job with! Earn a high minimum plus a percentage based bonus. Accommodations and travel are completely paid for the right candidate. Please phone: (204) 620-1585 or email: saursriv@yahoo.ca. D3675



**Faculty Position (5 year term)  
Community Dentistry/Public Health  
College of Dentistry**

The College of Dentistry invites applications from qualified individuals for a faculty position (5 year term) in Community Dentistry/Public Health. Responsibilities will include teaching and coordination of the undergraduate academic program in Community Dentistry/Public Health in all its aspects. A significant part of this position will be devoted to the development of community outreach programs (delivery of clinical care, health promotion, community development) to address oral health disparities across Saskatchewan on behalf of the College and its partners as well as providing students with meaningful clinical and social experiences in the community. There will be ample scope within this appointment to engage in and initiate an active research program within the Colleges and the interdisciplinary health sciences. Opportunities exist to participate in the School of Public Health's graduate programming. The candidate should have significant experience in developing and implementing community health/dental public health programming and research and bring to the College an enthusiasm for furthering and enhancing the role and profile of the College in the community. The candidate should have significant experience in community and stakeholder development. The candidate should have an advanced degree in dental public health, epidemiology, preventive dentistry or equivalent at the Masters or PhD level. Completion of an accredited specialty training program in dental public health is highly desirable as is Royal College/American Board certification and eligibility for licensure in Saskatchewan. Rank and salary will be commensurate with experience and qualifications. The University is committed to Employment Equity. Members of designated groups (women, Aboriginal people, people with disabilities and visible minorities) are encouraged to self-identify on their applications. All qualified candidates are encouraged to apply; however, Canadians and permanent residents will be given priority. Further information about our College and its programs are available at [www.usask.ca/dentistry](http://www.usask.ca/dentistry)

A letter of application, curriculum vitae, copies of professional credentials, a statement of teaching and research interests, and three (3) reference letters should be sent to:

**Dr. Gerry Uswak  
Dean, College of Dentistry  
Room 331 Dental Clinic Building  
University of Saskatchewan  
105 Wiggins Road  
Saskatoon, SK, S7N 5E4, Canada  
Telephone: (306) 966-5122  
Facsimile: (306) 966-5132  
e-mail: [gerry.uswak@usask.ca](mailto:gerry.uswak@usask.ca)**

Applications with completed documentation will be accepted until December 31, 2008 or until a suitable candidate is found.

D4837

**MANITOBA - Winnipeg:** Seeking associates to join our very progressive practice. Currently with 4 locations in and around Winnipeg. Potential opportunity to make over 20K a month net for the right candidate. New graduates encouraged to apply. We feature an onsite lab and a part-time orthodontist. Expect a fully booked schedule. Impeccable management is the foundation to the success and progression of this practice. Contact D.K. Mittal: cell: (204) 297-5344 res.: (204) 633-8280 off.: (204) 774-7774 email: dmittal@shaw.ca. D4765

**NEWFOUNDLAND - Mount Pearl:** Full-time associate required for progressive family dental practice in Mount Pearl, Newfoundland. Our friendly, state-of-the-art 8-operator practice has an exceptional opportunity for a dentist to join our professional, well-trained dental team. Full schedule available immediately with outstanding income potential and competitive benefits. Enjoy working a wide range of general dentistry services in an office equipped with the latest in technology including digital radiography and chair-side multimedia. For further information, please email: drwalsh@mountpearldental.nf.net or fax your resume to: (709) 895-8857.

Visit us online at: [www.mountpearldental.nf.net](http://www.mountpearldental.nf.net). D4823

**NUNAVUT - Iqaluit:** Associate position(s) available for immediate start. Established clinic offers generous package and full appointment book to associates. All round clinical skills are your ticket to a wide range of recreational activities! No travel required and housing available in Canada's newest and fastest growing capital city. Please apply to: Administration, PO Box 1118, Yellowknife, NT X1A 2N8 or tel: (867) 873-6940, fax: (867) 873-6941. D1497

**ONTARIO - 20 Locations:** Experienced associate required for our well-established, busy practice. Enjoy a small town or a large city atmosphere. For more information visit our website at: [www.altima.ca](http://www.altima.ca) or contact: Dr. George Christodoulou, Altima Dental Canada, Tel: (416) 785-1828 ext 201 or via email: drgeorge@altima.ca. D2690

**ONTARIO - Brampton:** Busy family practice in Brampton, Ontario requires an associate. Approximately 35 hours/week. Likely leading to full time. New grads welcome. Fax resume to: (905) 791-1887. D4807

**ONTARIO/QUEBEC - Cornwall & Hawkesbury:** Choose the location you want, very busy practices. In Quebec, only 30 minutes southwest of Montreal. Full schedule (crown bridge, endodontics etc.). Possible sale. Outstanding growth income. Stability, flexibility and respect assured! For further information call Luc at: (450) 370-7765 or send email to: luc.leboeuf291@hotmail.com. D1674

**ONTARIO - Kingston:** Improve your quality of life in our wonderful lakeside city. Great restaurants, festivals, historic downtown, and a white-collar economy combine to make your home life and work life dynamic. Visit: [www.kingstoncanada.com](http://www.kingstoncanada.com). Work in a custom designed office, 8-4 M-F, excellent staff, great patients and make \$300K+ per year. [www.smilemdc.com](http://www.smilemdc.com). Email inquiries to: scott@smilemdc.com. D4747


**ONTARIO - London:** Full-time (4 days a week) associate required immediately for large, busy, well established family-oriented general dental practice. Present associate is relocating to a new city. Great opportunity to practise all aspects of general dentistry, while living in beautiful London, ON. Fax resume to: (519) 672-8557 or email: drmsmith@bellnet.ca. D4820

**ONTARIO - Niagara:** Periodontist. Excellent associateship opportunity in a traditional periodontal specialist office, with a large maintenance base and an expanding implant practice. We are looking for a potential future partner or owner, with a high level of integrity, professionalism and commitment. Email: niagara.periodontics@gmail.com. D4749

**ONTARIO - Orillia:** An excellent associate opportunity for an experienced dentist to join a modern, productive and comprehensive practice. You are mature, friendly and strive to provide health and happiness for our patients. You enjoy learning and welcome the challenge of integrating your personality and skills as a valued member of our highly-motivated team. Fax your resume to: (705) 329-0706 or email to: kevshort@sympatico.ca. D4802

**PRINCE EDWARD ISLAND - Charlottetown:** Oral surgeon. Well-established 30+ year practice in Prince Edward Island where you can also enjoy world famous golfing and a peaceful lifestyle. Seeking associate for all aspects of busy OMS, with opportunity to assume leadership. Hospital privileges available. Please email to: habbi@islandtelecom.com. Phone: (902) 892-2970 office, (902) 892-8337 home. D1548

**PRINCE EDWARD ISLAND - Summerside:** Seeking quality oriented associate with excellent people skills. We are a multi dentist family practice operating in a state of the art facility complemented by an experienced friendly support staff and a strong recare program. New grads welcome. Please forward any enquiries to: Attn:



**Bedford, Nova Scotia**

Full time position (3 or 4 days per week) in one of the most modern dental clinics in Eastern Canada. You will be practising with 4 hygienists and a well trained, friendly staff servicing over 3,000 active patients. Your operatory is equipped with an intraoral camera, digital imaging, chartless, satellite flat-screen TV's, rotary endo, electric/air hand pieces, CEREC, soft tissue laser etc. We are looking for a progressive, outgoing individual with a commitment to excellence. Reply in confidence to [drmike@summitdentistry.net](mailto:drmike@summitdentistry.net) D4836

Practice Manager, Water Street Dental Clinic, 645 Water Street, Summerside, PE, C1N 4H9. Phone: (902) 436-2737, fax: (902) 436-0331 or email: rmillar@wsdc.ca. D4787

**SASKATCHEWAN - Moose Jaw:** Seeking associate for multi-dentist practice. Located in thriving but peaceful Moose Jaw, Saskatchewan. Modern, computerized office offering an opportunity to set own work hours. New associate will take over an established patient pool with experienced staff. Contact Mike at phone: (306) 693-0755 or email: beesley.prestie@sasktel.net. D4308

**SASKATCHEWAN - Saskatoon:** Exceptional opportunity to work full time in our beautiful community. We are an established growing family practice and want to shorten our lengthy patient wait times to serve our patients better. We need another dentist to provide quality dental care along with our friendly team. We have been in our new location less than 2 years with incredible new patient flow and more than 7000 active charts. Our office has 7 operatories and room for expansion. The opportunity also exists for practice ownership in the future. Please send resume to: lawsondental@sasktel.net, fax: (306) 931-7861, or call Dr. Redden: (306) 933-3233. D4838

**SASKATCHEWAN - Swift Current:** An excellent opportunity for an associate to join our well-established family-oriented practice. Recently renovated office, equipped with the latest technology and with wonderful highly-motivated staff. We presently have one full-time hygienist and one part-time hygienist, and have 5 operatories with room to grow. We are looking for a friendly, team-oriented person. New grads are welcome. Phone: (306) 773-9355 or fax CV to: (306) 773-5326. D4429

**UNITED STATES - Illinois, Texas, and Massachusetts:** A unique and exciting opportunity is available for general dentists in the U.S. Earn

between 250-350k per year with paid malpractice and health insurance while working in a great environment. The group is owned and operated by Canadians and will look after all immigration needs. Must have started or be prepared to complete US boards. Email: dwolle@gmail.com, fax: (312) 274-0760. D2456

**YUKON - Whitehorse:** Land of the midnight sun. Come for the adventure. Associate required. As well, specialists, are you looking for a Northern Exposure? Check out our website: www.klondike-dental.com. Phone Dr. Pearson at home: (867) 668-4618, fax: (867) 667-4944 or Berni at work: (867) 668-3152. D1828

**Conferences**

**LEARN VIRTUALLY ANYTIME ANYWHERE:** With NEI Conferences. Technologically advanced CDE courses are all presented in a vacation environment and are all tax-deductible. The flexible year-round open registration allows you to choose travel destinations and dates that are convenient for you, ANYTIME - ANYWHERE. Have travel plans or planning to travel? Looking for a conference-to-go? Visit us at: www.neiconferences.com. D3429

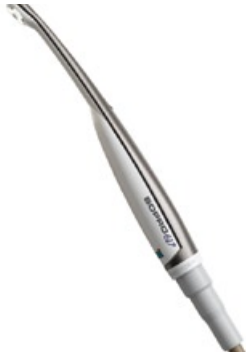**Equipment Sales & Service**

**FOR SALE:** Vacuum VacStar 50H (Air Techniques) used for 6 years. X-ray film processor Philips 810XL. Both in excellent condition. For info, please email: drfrancoisbedard@bellnet.ca. D4812

**Advertisers' Index**

3M ESPE . . . . . 672  
 A-dec . . . . . 703  
 CDA Funds . . . . . 750  
 CDSPI . . . . . 680, 701, 734  
 CIBC . . . . . 728  
 Colgate-Palmolive . . . . . 722  
 Dental Office Consulting . . . . . 700  
 Dentsply . . . . . 670  
 First Edition . . . . . 726  
 GlaxoSmithKline . . . . . 678  
 Henry Schein . . . . . 708  
 Ivoclar Vivadent . . . . . 752  
 P&G Professional Oral Health . . . . . 673, 676  
 Pacific Dental Conference . . . . . 696  
 Philips Oral Healthcare . . . . . 698  
 Quantum Health . . . . . 683  
 Straumann . . . . . 714  
 Sunstar Americas . . . . . 674  
 Tri Hawk . . . . . 733  
 Université Laval . . . . . 727  
 Vident . . . . . 704  
 VOCO . . . . . 684  
 Wiley-Blackwell . . . . . 727

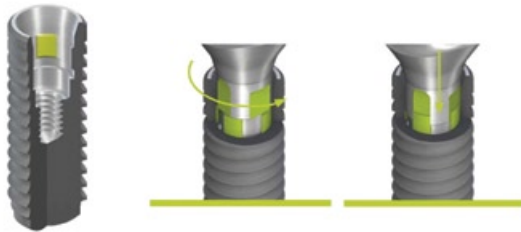



A-dec announces the release of the new **Sopro 617 intraoral camera**. A-dec claims that the camera combines LED lighting technology and superior optics to provide incredibly sharp images. The camera has a wide 105° angle of view for exceptional visibility and features an aspheric lens which effectively eliminates “fish-eye” distortion. The Sopro 617 allows full integration into A-dec systems and operates directly from the delivery system while fully connected to the treatment room computer. Other features include analog and digital imaging capability, a quick-disconnect design for easy sharing between treatment rooms and easy-handling with a balanced weight of only 55 g.

**A-dec, 1-800-547-1883, [www.a-dec.com](http://www.a-dec.com)**

Straumann has launched the new **CrossFit Connection bone level dental implant system**. According to the manufacturer, the new system features an internal cone angled at 15° for long-term mechanical stability and a tight fit.



It also has 4 flat surfaces which safeguard against rotation and offers 4 different positioning options. According to the manufacturer, these surfaces act as a key-way for the abutment, offering a ‘self-guiding’ connection that enables prosthodontists to ‘feel the fit’ and gives confidence that the abutment has seated exactly. Straumann claims that the connection guarantees a highly precise interface between implant and abutment and facilitates handling.

**Straumann, 1-800-363-4024, [www.straumann.ca](http://www.straumann.ca)**



Dentsply introduces the **Midwest Stylus ATC high-speed handpiece system**. Dentsply claims that it provides the power and efficiency of electric handpieces without sacrificing the superior access, lighter weight and familiar comfort of an air handpiece. Dentsply also claims that ATC technology uses cutting-edge sensors to continually monitor bur speed and automatically adjusts performance to maintain peak power and a constant speed even under load. According to the manufacturer, Stylus ATC intelligently adapts to the force applied to deliver the most powerful cutting ideal for fast, efficient crown removal and tooth reduction, as well as smooth precision control for decay removal and margin refinement.

**Dentsply, 1-800-263-1437, [www.dentsply.ca](http://www.dentsply.ca)**

*The “New Products” section provides readers with brief descriptions of recent innovations in dentistry. Publication of this information, which is condensed from news releases provided by manufacturers, does not imply endorsement by the JCDA or the Canadian Dental Association. Please send news releases and photographs to Rachel Galipeau, coordinator of publications, at [rgalipeau@cda-adc.ca](mailto:rgalipeau@cda-adc.ca). Material submitted in both English and French will be given priority.*



# CDA Funds

CHECK OUT OUR PERFORMANCE

**Leading Fund Managers Low Fees**

CDA Funds can be used in your CDA RSP, CDA RIF, CDA Investment Account, CDA RESP and CDA IPP.

**CDA Fund Performance (for period ending August 31, 2008)**

	MER	1 year	3 years	5 years	10 years
<b>CDA Canadian Growth Funds</b>					
Aggressive Equity Fund (Altamira)	1.00%	-25.0%	-2.3%	3.5%	7.1%
Common Stock Fund (Altamira)	0.99%	6.9%	12.3%	14.3%	11.0%
Canadian Equity Fund (Trimark)	1.50%	-8.1%	2.1%	6.1%	7.6%
Dividend Fund (PH&N) <sup>†</sup>	1.20%	-8.9%	3.8%	8.7%	12.2%
High Income Fund (Sceptre) <sup>†</sup>	1.45%	3.7%	4.6%	13.9%	n/a
Special Equity Fund (KBSSH)	1.45%	-2.1%	4.5%	9.2%	8.6%
TSX Composite Index Fund (BGI) <sup>††</sup>	0.67%	4.7%	11.4%	14.7%	n/a
<b>CDA International Growth Funds</b>					
Emerging Markets Fund (Brandes)	1.77%	-14.0%	9.5%	10.5%	10.4%
European Fund (Trimark) <sup>†</sup>	1.45%	-17.1%	4.0%	3.9%	-1.4%
International Equity Fund (CC&L)	1.30%	-13.0%	1.3%	1.2%	0.2%
Pacific Basin Fund (CI)	1.77%	-12.7%	4.2%	3.0%	1.0%
US Large Cap Fund (Capital Intl) <sup>†</sup>	1.46%	-18.8%	-5.7%	-2.5%	n/a
US Small Cap Fund (Trimark)	1.25%	-23.9%	1.8%	3.9%	n/a
Global Fund (Trimark)	1.50%	-14.1%	3.3%	3.8%	6.5%
Global Growth Fund (Capital Intl) <sup>†</sup>	1.77%	-11.5%	3.0%	6.3%	n/a
S&P 500 Index Fund (BGI) <sup>††</sup>	0.67%	-11.6%	-1.2%	0.2%	-0.2%
<b>CDA Income Funds</b>					
Bond and Mortgage Fund (Fiera)	0.99%	5.4%	2.8%	3.5%	4.6%
Bond Fund (PH&N)	0.65%	5.8%	3.2%	5.1%	6.0%
Fixed Income Fund (McLean Budden) <sup>†</sup>	0.97%	5.6%	2.5%	4.4%	5.2%
<b>CDA Cash and Equivalent Fund</b>					
Money Market Fund (Fiera)	0.67%	3.3%	3.3%	2.7%	3.2%
<b>CDA Growth and Income Funds</b>					
Balanced Fund (PH&N)	1.20%	-2.8%	3.6%	5.6%	5.3%
Balanced Value Fund (McLean Budden) <sup>†</sup>	0.95%	-3.3%	3.5%	6.2%	6.1%
<b>CDA Managed Risk Portfolios (Wrap Funds)</b>					
<b>Index Fund Portfolios</b>					
CDA Conservative Index Portfolio (BGI) <sup>†</sup>	0.85%	1.4%	3.8%	5.6%	4.8%
CDA Moderate Index Portfolio (BGI) <sup>†</sup>	0.85%	-1.0%	4.7%	7.4%	6.3%
CDA Aggressive Index Portfolio (BGI) <sup>†</sup>	0.85%	-2.9%	5.6%	8.9%	7.0%
<b>Income/Equity Fund Portfolios</b>					
CDA Income Portfolio (CI) <sup>†</sup>	1.65%	1.9%	3.0%	5.7%	5.4%
CDA Income Plus Portfolio (CI) <sup>†</sup>	1.65%	0.0%	3.8%	7.1%	6.4%
CDA Balanced Portfolio (CI) <sup>†</sup>	1.65%	-2.3%	4.3%	8.0%	7.0%
CDA Conservative Growth Portfolio (CI) <sup>†</sup>	1.65%	-4.1%	n/a	n/a	n/a
CDA Moderate Growth Portfolio (CI) <sup>†</sup>	1.65%	-4.9%	3.8%	7.1%	n/a
CDA Aggressive Growth Portfolio (CI) <sup>†</sup>	1.65%	-6.0%	n/a	n/a	n/a

Figures indicate annual compound rate of return. All fees have been deducted. As a result, performance results may differ from those published by the fund managers. CDA figures are historical rates based on past performance and are not necessarily indicative of future performance.

<sup>†</sup> Returns shown are for the underlying funds in which CDA funds invest.

<sup>††</sup> Returns shown are the total returns for the indices tracked by these funds.

For current unit values and GIC rates visit [www.cdspi.com/values-rates](http://www.cdspi.com/values-rates).

To speak with a representative, call CDSPI toll-free at 1-800-561-9401, ext. 5020.

# WE SELL PRACTICES!

roicorp.com

Canada's #1 dental practice appraisal & sales group - from coast-to-coast.



*Dr. Marcia Boyd, Dr. John Wilson, Dr. Wayne Raborn, Mr. Tom Schramm, Ms. Sandy Evans, Mr. Roy Brown, Mr. Timothy A. Brown, Mr. Robert MacDonald, Dr. Roger Ellis, Ms. Ann Wright, Dr. John Badger, Dr. Jeff Williams.*

Visit our website for the most comprehensive and up-to-date listings in the country. Our experienced and qualified ROI Corporation Associates are available to assist you in your region. Check our website for their contact information and benefit from our expertise.

**roicorp.com**

ROI Corporation

Phone: (905) 278-4145

Toll free: 1-888-764-4145

Email: [roi@roicorp.com](mailto:roi@roicorp.com)

ROI Corporation is a Licensed Real Estate and Business Brokerage.

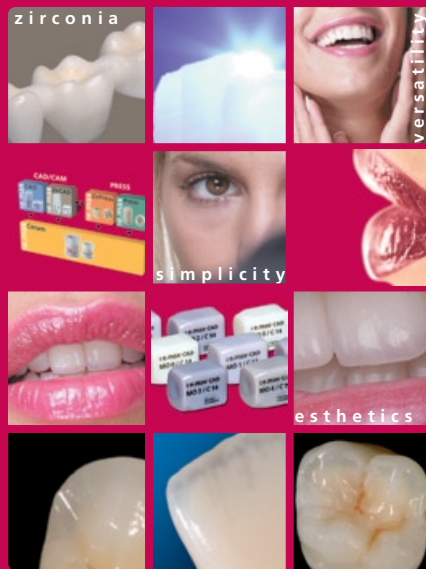
**ROI**  
**CORPORATION**  
Canada's Appraiser & Broker

# IPS e.max<sup>®</sup>

IPS e.max<sup>®</sup>

**all** ceramic

**all** you need



IPS e.max delivers the ultimate in metal free esthetics and strength utilizing both pressable and CAD/CAM technologies.

**IPS e.max offers:**

- Outstanding esthetics and strength
- Conventional cementation
- Choice of zirconia or lithium disilicate ceramic
- Press and CAD/CAM fabrication techniques optimizing both strength and fit

100% CUSTOMER SATISFACTION  
GUARANTEED!

[www.ivoclarvivadent.com](http://www.ivoclarvivadent.com)

Call us toll free at 1-800-263-8182 in Canada, 1-800-533-6825 in the U.S.  
©2008 Ivoclar Vivadent, Inc. IPS e.max is a registered trademark of Ivoclar Vivadent.

ivoclar  
vivadent<sup>®</sup>  
passion vision innovation