

# Taste Change Associated with a Dental Procedure: Case Report and Review of the Literature

Gary D. Klasser, DMD; Robert Utsman, DDS; Joel B. Epstein, DMD, MSD, FRCD(C)

## Contact Author

Dr. Klasser  
Email: [gklasser@uic.edu](mailto:gklasser@uic.edu)



## ABSTRACT

Loss or alteration of taste is a rare phenomenon that may be idiopathic or may be caused by head trauma, medication use or systemic and local factors including various invasive dental procedures resulting in nerve damage. We present an unusual case of generalized taste change following an oral surgical procedure. The case is presented to enhance understanding of taste disorders and their relation to a localized traumatic event. Causative factors and management strategies are also reviewed.

For citation purposes, the electronic version is the definitive version of this article: [www.cda-adc.ca/jcda/vol-74/issue-5/455.html](http://www.cda-adc.ca/jcda/vol-74/issue-5/455.html)

Taste change, encompassing loss (ageusia) or alteration (dysgeusia) of taste, is a rare phenomenon that may be idiopathic or may result from head trauma; endocrine, metabolic, sinus, autoimmune and salivary gland disorders; medication use; cancer treatment (radiation or chemotherapy); viral, bacterial and fungal infections; certain oral conditions; or peripheral nerve damage due to invasive procedures including dental interventions.<sup>1-4</sup> Some factors thought to be responsible for nerve injuries associated with dental procedures are proximity of the chorda tympani nerve to the surgical site, retraction of the lingual flap, extraction of unerupted teeth, especially third mandibular molars, and experience of the operator.<sup>5-9</sup> Nerve damage may also be a result of local anesthetic injection due to direct needle trauma causing hemorrhage within the epineurium or a neurotoxic effect of the anesthetic.<sup>10,11</sup>

The sensation of taste is mediated by 3 cranial nerves: facial (VII), glossopharyngeal (IX) and vagus (X).<sup>12</sup> The trigeminal nerve (V) provides general sensory innervation to a region

that overlaps the areas served by these other cranial nerves<sup>12</sup> (Table 1). Because of their anatomic proximity, the possibility exists for iatrogenic injury to the chorda tympani, lingual nerve or both during surgical procedures in the posterior mandible. This may result in irreversible gustatory deficits and somatosensory dysfunction.<sup>13,14</sup>

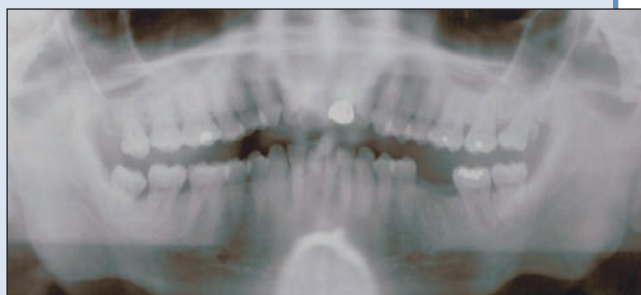The purpose of this article is to review the possible causes and management of taste disorders. An unusual case of generalized taste change following an oral surgical procedure is presented to enhance understanding of taste disorders and their possible relation to a localized traumatic event.

## Case Report

In October 2006, a 66-year-old man presented to the oral medicine clinic with the chief complaint of taste change. In addition, he reported a sensation of oral dryness despite frequent hydration with water, poor appetite and malaise. He had lost approximately 10 pounds since the onset of his poor appetite in July 2005. His taste loss had occurred several

**Table 1** Cranial nerves and branches involved in taste

Cranial nerve	Location of exit from skull	Branches	Innervated area related to taste function
Mandibular (V3), a branch of the trigeminal nerve	Foramen ovale	Lingual nerve	General sensation on the anterior two thirds of tongue
Facial (VII)	Internal auditory meatus	Chorda tympani nerve Greater superficial petrosal nerve	Sensation of taste on the anterior two thirds of tongue Sensation of taste on the palate
Glossopharyngeal (IX)	Jugular foramen	Lingual branch	Sensation of taste on the posterior third of tongue General sensation on the posterior third of tongue, oropharynx and pharyngeal mucosa
Vagus (X)	Jugular foramen	Palatopharyngeal branch	Sensation of taste on the base of tongue and epiglottis General sensation on the soft palate and upper larynx



**Figure 1:** Preoperative panoramic radiograph showing advanced periodontal bone loss.

weeks after a combined periodontal and oral surgery procedure.

The procedure had been recommended by his periodontist due to advanced periodontal bone loss and associated tooth mobility (**Fig. 1**). Performed by an oral surgeon in July 2005 under intravenous sedation, the procedure involved the extraction of his maxillary and mandibular third molars. Surgical incisions involving the sulcular, buccal, lingual and palatal tissues in both the maxillary and mandibular posterior regions were carried out to allow access for thorough debridement and recontouring of the residual osseous defects in these areas. The patient was prescribed analgesics that are used routinely during postsurgical recovery.

Between August and December 2005, the patient returned several times to the oral surgeon to report his symptoms. The surgeon noted his complaint of taste

change, but did not provide any treatment. In October 2005, the patient sought treatment from his primary care physician. At that time, he stated that food “tasted like cardboard” since the dental procedures. The physician conducted provocation taste tests, placing sugar, salt and mustard on the patient’s tongue. The patient did not detect salt or mustard, resulting in a diagnosis of ageusia/dysgeusia and subsequent referral to a neurologist.

The patient returned to his physician many times with his complaint of taste change; however, he did not complete the neurology consult. In June 2006, the physician ordered magnetic resonance imaging (MRI), but no central nervous system lesions or extra-axial abnormalities were detected.

At his initial examination at the oral medicine clinic in October 2006, the patient reported that he was able to discern different tastes, although at reduced intensities (hypogeusia), and he often experienced loss of taste during mastication. The patient self-medicated with zinc supplements (50 mg 4 times a day) but had not noticed any improvement in taste intensity or alteration in frequency of ageusic episodes.

In December 2005, the patient had been diagnosed with hypothyroidism and prescribed thyroid supplementation. He also reported osteoarthritic knees and had taken an over-the-counter joint supplement, but discontinued its use following our initial appointment. He was taking multivitamins and minerals and reported an allergy to sulfa drugs.

An extraoral examination revealed intact cranial nerves, facial symmetry, no lymphadenopathy, normal range of mandibular movements and no tenderness or

**Table 2** Conditions and mechanisms resulting in taste changes<sup>1–7,10,11,14–17</sup>

Condition	Mechanism	Taste alteration
Head trauma	Damage to central or peripheral nerves	Dysgeusia Ageusia
Systemic conditions (diabetes, hypothyroidism, systemic lupus erythematosus and nasal polyps)	Alteration in taste receptor function or signal transduction Decreased salivary flow rate	Dysgeusia Elevated bitter taste
Various medications, including ACE inhibitors, calcium-antagonist, diuretics, antiarrhythmics, antibiotics, antivirals, antiprotozoals, antirheumatics, antithyroid, antidiabetic, antihistamines, antidepressants, antipsychotics, local anesthetics, antineoplastic treatment, chelating agents	Interference with chemical composition or flow of saliva Secretion of the medication in saliva Alteration in taste receptor function or signal transduction	Hypogeusia (decreased sensitivity to taste) Dysgeusia Ageusia
Radiation or chemotherapy to treat cancer of the head and neck	Changes in salivary composition Drug secretion in oral fluids Decreased salivary flow rate Alteration in normal oral flora Decreased rate of turnover of taste buds	Dysgeusia Ageusia
Viral infections (upper respiratory tract and middle ear, herpes zoster, HIV)	Damage to central or peripheral nerves	Dysgeusia Ageusia
Oral bacterial and fungal infections	Damage to central or peripheral nerves Decreased salivary flow rate	Elevated bitter and/or metallic taste Dysgeusia
Oral conditions (lichen planus, burning mouth syndrome and dry mouth)	Damage to central or peripheral nerves Decreased salivary flow rate	Hypogeusia Dysgeusia
Local anesthetics (articaine, procaine, tetracaine, bupivacaine or lidocaine)	Direct needle trauma to nerve Hemorrhage inside the epineurium Neurotoxicity	Hypogeusia Dysgeusia Ageusia
Surgical procedures	Partial or complete nerve transaction	Dysgeusia Ageusia

Note: ACE = angiotensin converting enzyme.

pain on palpation of the masticatory musculature and lateral aspect of the temporomandibular joints. Intraoral examination revealed intact dentition with well-healed mucosa at the surgical sites and no clinical signs of infection or inflammation. The oral mucosa and gingivae were within normal limits: pink, without lesions, masses or swellings. The tongue was normally papillated and was without lesions or masses. Salivary flow rates were determined measuring total saliva (unstimulated and stimulated) expectorated for 3 minutes. The results indicated a slightly reduced unstimulated flow rate (0.2 g/min) and a normal stimulated whole salivary flow rate.

The working diagnosis was taste change as a result of injury to chorda tympani nerves at the time of the

surgery, probably caused by inflammatory, infectious or fibrotic changes within the nerves. There was also the possibility of an underlying pathosis, leading to taste hypogeusia and mild hyposalivation at rest.

Zinc dosage was increased from 200 mg/day to 450 mg/day and the patient was prescribed 30 mg cevimeline 3 times a day to increase saliva production. This medication produced subjective improvement and comfort with eating. Objective salivary flow rates (0.5 g/min unstimulated and 1.9 g/min stimulated) indicated an increase in salivary flow. In November 2006, a technetium-99m bone scan was performed to assess and rule out nonclinically evident pathology in the bone; no significant findings were identified. Further

imaging of the head (computed tomography and MRI) was unremarkable and ruled out central nervous system pathology.

Although the patient was satisfied with the increase in intraoral moisture and continues to use sialogogues, normal taste sensation has not returned. He was advised to discontinue zinc supplements and to modify his diet by increasing the texture of foods and using stronger seasonings. At this point, he is satisfied with the recommendations and will be recalled periodically for follow-up.

## Discussion

Many reported cases of taste change are idiopathic.<sup>2</sup> However, many identifiable causes are also associated with chemosensory (taste or olfactory) deficits (Table 2). In the case presented, the lack of history of these conditions and the unremarkable clinical examination, bone scan and neuroimaging enabled us to rule out potential underlying tumour or other disease entities. At the onset of the initial complaint, there was no history of medication use or diagnosis of any systemic condition.

Several months after the patient reported taste changes, he was diagnosed with hypothyroidism and treated with thyroid supplementation. Several studies<sup>18-20</sup> have cited hypothyroidism as a factor that may affect taste because of the role of thyroid hormones in the maturation and specialization of taste buds. However, the timing of this diagnosis well after presentation of the initial complaint and the fact that the patient's hypothyroidism is well controlled makes this an unlikely cause of the taste change.

Although gustatory disorders after oral surgical procedures have frequently been reported, much of the literature is based on case studies resulting from damage to the chorda tympani after middle ear surgery.<sup>21-24</sup> However, several articles report unilateral taste change, sensory (anesthesia, dysesthesia or paresthesia) changes and nerve damage after surgical procedures involving the removal of third molars.<sup>14,15</sup> Shafer and others<sup>16</sup> showed that perceived taste intensity on discrete areas of the tongue was significantly reduced after third molar surgery, and patients with the most severely impacted molars gave the lowest taste intensity ratings to whole-mouth test solutions. They also found that removal of severely impacted molars could cause partial or complete transection of nerves resulting in gustatory deficits. Surgical procedures requiring lingual flaps, tooth sectioning or the insertion of a periosteal elevator can all be linked to taste dysfunction following third molar extraction.<sup>5,6</sup> In our case, although a surgical procedure to remove the third molars was not conducted, surgery and manipulation of the underlying tissues was performed for periodontal reasons and may have resulted in neural injury and led to the patient's complaints.

Nerve damage has also been linked to the experience of the operator and procedures performed under various

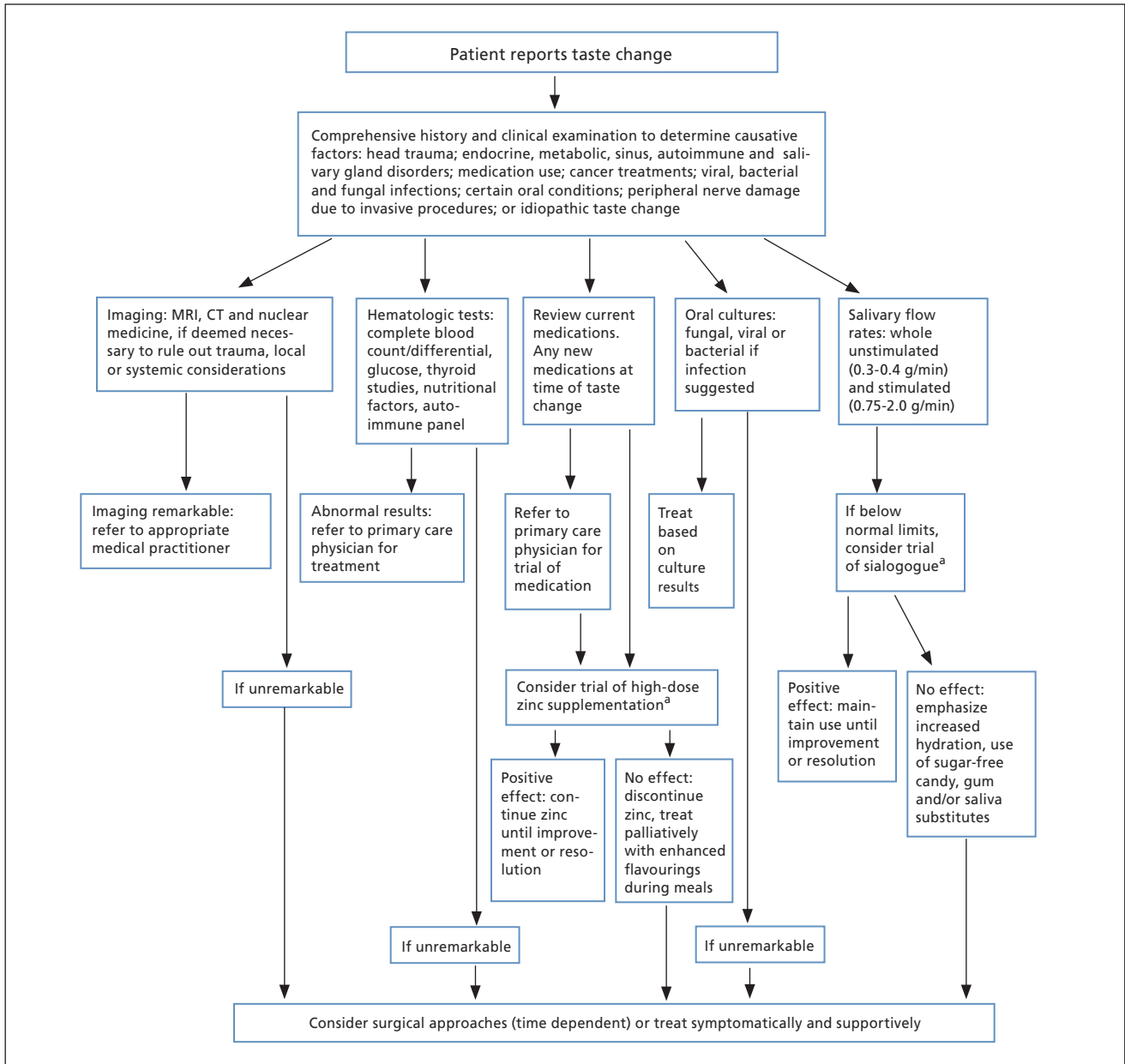
forms of sedation. Complications, including a higher frequency of nerve damage, are more likely with less-experienced oral surgeons than with more experienced oral surgeons.<sup>7</sup> In addition, the degree of force used to remove impacted teeth is greater when the patient is under sedation than in a conscious patient and this additional aggressiveness is a risk for nerve damage.<sup>17</sup> Although in our case it seems unlikely that a high degree of force would be needed to remove his erupted and periodontally compromised teeth, it is possible that nerve injury may have been caused during that procedure.

Another possible mechanism for nerve damage is the use of local anesthetic. Direct contact with the needle used to inject anesthetic traumatizes the nerve and produces a prolonged change in sensation. However, paresis caused by shearing of the nerve as a result of direct trauma is unlikely because of the small diameter of the needle (0.45 mm in a 25-gauge needle) compared with the 2-3 mm diameter of the lingual and inferior alveolar nerves.<sup>11,25</sup> Intra-neural hematoma caused by the needle striking one of the smaller intra-neural blood vessels is a possible cause of nerve damage. If the needle contacted one of the small blood vessels inside the nerve, the release of blood and blood products inside the epineurium could cause compression, fibrosis and scar formation.<sup>10,11</sup> Compression of the nerve could result in damage and inhibit or alter the natural healing process.<sup>10,11</sup>

Chemical damage to the nerve due to neurotoxicity of the local anesthetic is another possibility if the anesthetic is injected intrafascicularly or becomes deposited within the nerve as the needle is withdrawn.<sup>25</sup> Local anesthetics (articaine, procaine, tetracaine, bupivacaine or lidocaine) can all be neurotoxic when injected directly into the nerve.<sup>26</sup> Chemical trauma as a result of these has been shown to cause demyelination, axonal degeneration and inflammation of the surrounding nerve fibres within fascicles, which results in a breakdown of the nerve-blood barrier and endoneurial edema.<sup>25</sup>

The case presented above is unusual as it represents generalized taste change following an oral surgical procedure. There is no curative therapy for trauma-induced taste change, although studies have shown that zinc supplementation, sialogogues and surgical procedures have been useful in treating taste disorders.<sup>27-31</sup> Our treatment strategies were based on prior studies. An algorithm for the diagnosis and management of taste change is shown in Fig. 2.

Several studies indicate that zinc (gluconate or sulfate) may be helpful in the treatment of idiopathic dysgeusia, as it is an important factor in gustation. Zinc has been shown to play a significant role in the regeneration of taste bud cells.<sup>32</sup> Contrary to these findings, a trial involving head and neck cancer patients found no significant effect of zinc sulfate on the interval before taste alteration, the incidence of taste alteration or the interval



**Figure 2:** Algorithm for diagnosis and management of taste change.

Note: CT = computed tomography, MRI = magnetic resonance imaging.

<sup>a</sup>Trials of zinc supplementation and sialogogue use may be tried concomitantly.

to taste recovery.<sup>33</sup> Clearly, the role that zinc plays in gustation is not fully understood and larger studies are needed to investigate its efficacy.

The amount of saliva in the oral cavity is an important factor in taste function. Saliva has been linked to taste sensitivity, as it is the principal component in the external environment of taste receptor cells. Salivary constituents dissolve substances that diffuse to the taste receptor sites. Matsuo and Yamamoto<sup>34</sup> demonstrated an association between saliva and taste; whole saliva affected taste response of the chorda tympani nerve to the

4 standard chemical stimuli (sucrose, NaCl, HCl, quinine hydrochloride). Thus, low saliva flow may alter taste, which would warrant the use of a sialogogue.

Surgical procedures to repair nerve damage are another means to manage taste disturbances. In a review, Ziccardi and Steinberg<sup>35</sup> found that trigeminal nerve microsurgery was an option for treatment of patients with nerve injury. However, timing is critical in determining whether the procedure is warranted. The articles reviewed suggested that injuries should be repaired within the first 90 days to increase the chances of improvement.



Injuries not clinically observed at the time of a procedure that are accompanied by nerve conduction deficits are recommended for surgical repair up to one year from the time of the injury. In our case, because of the time that had elapsed since the initial taste disturbance, a surgical procedure was not recommended.

## Conclusion

This case report is unique in that the patient reported a generalized taste change shortly after an oral surgical procedure. The presentation and clinical features differ from those of previous cases reported in the literature in that the symptoms and reporting thereof were somewhat delayed. The reasons for this delay may have been the patient's altered diet following normal wound healing from the oral surgical procedure, inflammation as a result of the surgery, masking of tastes by medications taken after surgery, unmasking of a preexisting condition by the oral surgery, heightening the patient's perception of altered taste or revealing an underlying and possibly undiagnosed preexisting hypothyroid condition. A management approach based on available scientific evidence was adopted.

Unfortunately, the outcome has not been very positive to date. Unlike most other patients in this situation, normal taste has not returned and will most likely remain unchanged, making this a rather distressing situation. To avoid similar situations, oral health practitioners must be able to recognize this phenomenon. This can only be accomplished if they are aware of and understand the potential causes and management of taste disorders. Hopefully, this will increase patients' chances of recovery through timely diagnosis and appropriate care. ❖

## THE AUTHORS



**Dr. Klasser** is an assistant professor in the department of oral medicine and diagnostic sciences, University of Illinois at Chicago College of Dentistry, Chicago, Illinois.



**Dr. Utsman** is a fellow in the department of oral medicine and diagnostic sciences, University of Illinois at Chicago College of Dentistry, Chicago, Illinois.



**Dr. Epstein** is a professor and head of the department of oral medicine and diagnostic sciences, University of Illinois at Chicago College of Dentistry; and director of the Interdisciplinary Program in Oral Cancer, College of Medicine, Chicago Cancer Center, Chicago, Illinois.

**Correspondence to:** Dr. Gary Klasser, University of Illinois at Chicago College of Dentistry, Department of oral medicine and diagnostic sciences, 801 South Paulina Street, Room 569B (M/C 838), Chicago, IL 60612-7213.

The authors have no declared financial interests.

This article has been peer reviewed.

## References

- Ackerman BH, Kasbekar N. Disturbances of taste and smell induced by drugs. *Pharmacotherapy* 1997; 17(3):482–96.
- Deems DA, Doty RL, Settle RG, Moore-Gillon V, Shaman P, Mester AF, and others. Smell and taste disorders, a study of 750 patients from the University of Pennsylvania Smell and Taste Center. *Arch Otolaryngol Head Neck Surg* 1991; 117(5):519–28.
- Scully C, Bagan JV. Adverse drug reactions in the orofacial region. *Crit Rev Oral Biol Med* 2004; 15(4):221–39.
- Spielman AI. Chemosensory function and dysfunction. *Crit Rev Oral Biol Med* 1998; 9(3):267–91.
- Queral-Godoy E, Figueiredo R, Valmaseda-Castellón E, Berini-Aytés L, Gay-Escoda C. Frequency and evolution of lingual nerve lesions following lower third molar extraction. *J Oral Maxillofac Surg* 2006; 64(3):402–7.
- Gülicher D, Gerlach KL. Sensory impairment of the lingual and inferior alveolar nerves following removal of impacted mandibular third molars. *Int J Oral Maxillofac Surg* 2001; 30(4):306–12.
- Valmaseda-Castellón E, Berini-Aytés L, Gay-Escoda C. Lingual nerve damage after third lower molar surgical extraction. *Oral Surg Oral Med Oral Pathol Oral Radiol Endod* 2000; 90(5):567–73.
- Rehman K, Webster K, Dover MS. Links between anaesthetic modality and nerve damage during lower third molar surgery. *Br Dent J* 2002; 193(1):43–5.
- Pogrel MA, Schmidt BL, Sambajon V, Jordan RC. Lingual nerve damage due to inferior alveolar nerve blocks: a possible explanation. *J Am Dent Assoc* 2003; 134(2):195–9.
- Pogrel MA, Thamby S. Permanent nerve involvement resulting from inferior alveolar nerve blocks. *J Am Dent Assoc* 2000; 131(7):901–7.
- Pogrel MA, Bryan J, Regezi J. Nerve damage associated with inferior alveolar nerve blocks. *J Am Dent Assoc* 1995; 126(8):1150–5.
- Netter FH. Atlas of human anatomy, professional edition. 4 ed. Philadelphia: WB Saunders; 2006.
- Yanagisawa K, Bartoshuk LM, Catalanotto FA, Karrer TA, Kveton JF. Anesthesia of the chorda tympani nerve and taste phantoms. *Physiol Behav* 1998; 63(3):329–35.
- Fielding AF, Rachiele DP, Frazier G. Lingual nerve paresthesia following third molar surgery: a retrospective clinical study. *Oral Surg Oral Med Oral Pathol Oral Radiol Endod* 1997; 84(4):345–8.
- Paxton MC, Hadley JN, Hadley MN, Edwards RC, Harrison SJ. Chorda tympani nerve injury following inferior alveolar injection: a review of two cases. *J Am Dent Assoc* 1994; 125(7):1003–6.
- Shafer DM, Frank ME, Gent JF, Fischer ME. Gustatory function after third molar extraction. *Oral Surg Oral Med Oral Pathol Oral Radiol Endod* 1999; 87(4):419–28.
- Brann CR, Brickley MR, Shepherd JP. Factors influencing nerve damage during lower third molar surgery. *Br Dent J* 1999; 186(10):514–6.
- Femiano F, Gombos F, Esposito V, Nunziata M, Scully C. Burning mouth syndrome (BMS): evaluation of thyroid and taste. *Med Oral Patol Oral Cir Bucal* 2006; 11(1):E22–5.
- Doty RL, Bromley SM. Effects of drugs on olfaction and taste. *Otolaryngol Clin North Am* 2004; 37(6):1229–54.
- McConnell RJ, Menendez CE, Smith FR, Henkin RI, Rivlin RS. Defects of taste and smell in patients with hypothyroidism. *Am J Med* 1975; 59(3):354–64.
- Akal UK, Küçükyavuz Z, Nalçacı R, Yılmaz T. Evaluation of gustatory function after third molar removal. *Int J Oral Maxillofac Surg* 2004; 33(6):564–8.
- Blackburn CW, Bramley PA. Lingual nerve damage associated with the removal of lower third molars. *Br Dent J* 1989; 167(3):103–7.
- Landis BN, Lacroix JS. Postoperative/posttraumatic gustatory dysfunction. *Adv Otorhinolaryngol* 2006; 63:242–54.
- Hotta M, Endo S, Tomita H. Taste disturbance in two patients after dental anesthesia by inferior alveolar nerve block. *Acta Otolaryngol Suppl* 2002; (546):94–8.
- Smith MH, Lung KE. Nerve injuries after dental injection: a review of the literature. *J Can Dent Assoc* 2006; 72(6):559–64.
- Schwankhaus JD. Bilateral anterior lingual hypogeusia hypesthesia. *Neurology* 1993; 43(10):2146.
- Robinson PP, Loeschner AR, Yates JM, Smith KG. Current management of damage to the inferior alveolar and lingual nerves as a result of removal of third molars. *Br J Oral Maxillofac Surg* 2004; 42(4):285–92.
- Hershkovich O, Nagler RM. Biochemical analysis of saliva and taste acuity evaluation in patients with burning mouth syndrome, xerostomia and/or gustatory disturbances. *Arch Oral Biol* 2004; 49(7):515–22.
- Deems DA, Yen DM, Kreshak A, Doty RL. Spontaneous resolution of dysgeusia. *Arch Otolaryngol Head Neck Surg* 1996; 122(9):961–3.

30. Heckmann SM, Hujoel P, Habiger S, Friess W, Wichmann M, Heckmann JG, and other. Zinc gluconate in the treatment of dysgeusia — a randomized clinical trial [published erratum in *J Dent Res* 2005; 84(4):382]. *J Dent Res* 2005; 84(1):35–8.
31. Heckmann JG, Lang CJ. Neurological causes of taste disorders. *Adv Otorhinolaryngol* 2006; 63:255–64.
32. Henkin RI, Martin BM, Agarwal RP. Efficacy of exogenous oral zinc in treatment of patients with carbonic anhydrase VI deficiency. *Am J Med Sci* 1999; 318(6):392–405.
33. Halyard MY, Jatoi A, Sloan JA, Bearden JD 3rd, Vora SA, Atherton PJ, and others. Does zinc sulfate prevent therapy-induced taste alterations in head and neck cancer patients? Results of phase III double-blind, placebo-controlled trial from the North Central Cancer Treatment Group (N01C4). *Int J Radiat Oncol Biol Phys* 2007; 67(5):1318–22.
34. Matsuo R, Yamamoto T. Effects of inorganic constituents of saliva on taste responses of the rat chorda tympani nerve. *Brain Res* 1992; 583(1-2):71–80.
35. Ziccardi VB, Steinberg MJ. Timing of trigeminal nerve microsurgery: a review of the literature. *J Oral Maxillofac Surg* 2007; 65(7):1341–5.