

# In-Office Iliac Crest Bone Harvesting for Peri-Implant Jaw Reconstruction

Marshall M. Freilich, BSc, DDS, MSc, FRCD(C);  
George K.B. Sándor, MD, DDS, PhD, FRCD(C), FRCSC, FACS

## Contact Author

Dr. Freilich  
Email:  
[drfreilich@rogers.com](mailto:drfreilich@rogers.com)



## ABSTRACT

We describe 2 minimally invasive techniques for in-office iliac crest bone harvesting. The increasingly limited access to hospital operating rooms and the increased need for bone grafting to facilitate dental implant-related reconstructions have been the major impetuses behind relocating some of these surgeries to the out-of-hospital, in-office setting.

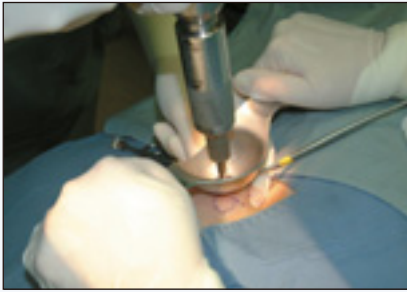**MeSH Key Words:** bone transplantation/methods; jaw/surgery; oral surgical procedures/methods

© J Can Dent Assoc 2006; 72(6):543-7  
This article has been peer reviewed.

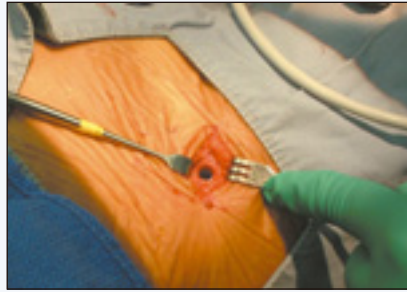
Dental implant treatment has become widely accepted by patients, resulting in an increased demand for bone reconstructive techniques that allow for ideal placement of implant fixtures. Successful implant surgery is not simply the achievement of successful osseointegration, but rather the establishment of an ideal foundation for implant-supported prosthetic restorations. This objective requires the diagnosis and surgical management of deficiencies in both hard and soft tissue foundations. Some ridge-preservation techniques are expensive for the patient, are performed in sites that are often chronically inflamed and do not necessarily obviate the need for future osseous reconstruction. Autologous bone graft remains the gold standard approach for all forms of maxillofacial peri-implant reconstruction.<sup>1</sup> It is preferable to perform these procedures secondary to extracting teeth, allowing for soft tissue healing to optimize conditions for bone-graft coverage and consolidation.

The reconstruction of small osseous defects may be possible using autogenous bone

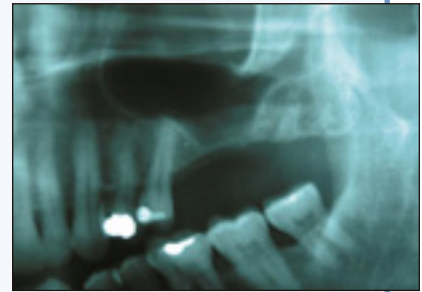harvested from intraoral sources.<sup>2</sup> The mandibular ramus and symphysis provide small amounts of cortical and cancellous bone, suitable for single-tooth segments. However, harvesting bone from these sites carries a risk of paresthesia in the distribution of the inferior alveolar, mental and incisive nerves.<sup>2</sup> Thus, restoring large hard-tissue defects to facilitate implant placement usually requires the harvesting of bone from extraoral sites.<sup>3</sup> The anterior ilium is easily accessible and provides large quantities of bone. It is well suited as a donor site for many types of reconstructive surgery.<sup>4</sup> Although bone harvest surgery has traditionally been performed in hospital, recent advances in minimally invasive surgical techniques<sup>5-7</sup> have allowed this procedure to be performed safely in the oral and maxillofacial surgery office on a routine basis. These techniques allow the surgeon to perform unilateral or bilateral maxillary sinus augmentation, buccal onlay grafting, cleft alveolar repair and revisional peri-implant grafting with significant amounts of autogenous bone.



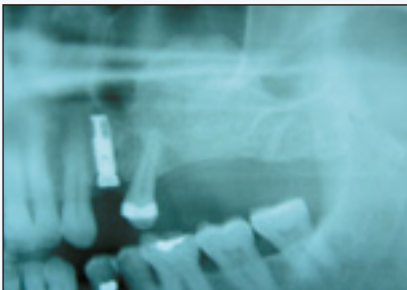**Figure 1:** A Straumann Osteocore (Straumann AG, Waldenburg, Switzerland) motorized trephine is introduced to the anterior iliac crest, with guiding trocar retractor protecting the surrounding soft tissues.



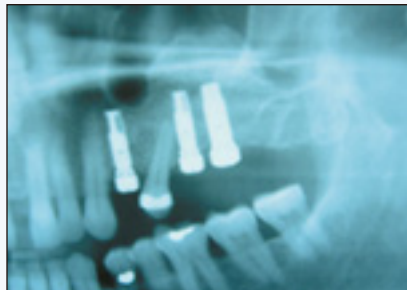**Figure 2:** Minimal defect in right anterior iliac crest following trephination of a cancellous core.



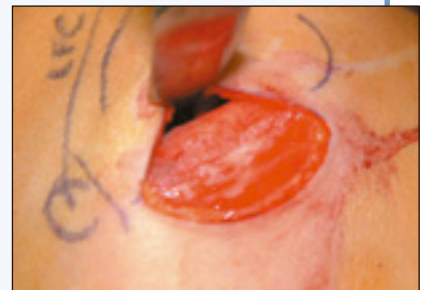**Figure 3:** The left maxillary sinus before surgical elevation and autologous bone augmentation.



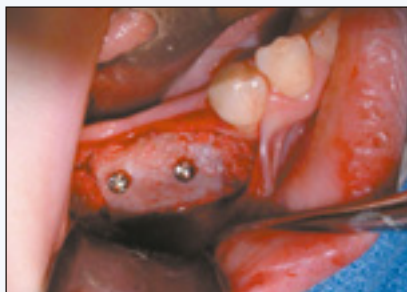**Figure 4:** Postoperative view of left maxillary sinus immediately following sinus elevation and autologous bone augmentation using the Osteocore trephine technique.



**Figure 5:** Implant placement following 4-month period of graft incorporation.



**Figure 6:** Right anterior iliac crest with exposure of medial cortex before harvesting a block corticocancellous graft.



**Figure 7:** Block bone graft harvested from the iliac crest is rigidly fixed to the alveolar ridge with transosseous screws as an onlay graft to augment ridge width.

### In-Office Bone Harvesting for Reconstructive Surgery

Bone harvesting from the anterior iliac crest originally involved hospital admission, as it was a far more invasive procedure than it is today. The development of less invasive harvesting techniques, limited access to hospital services for procedures deemed elective and increasing waiting times for procedures<sup>8</sup> have resulted in more surgeries being performed in private clinics.<sup>9,10</sup> The safety and complications associated with these techniques have been recently documented.<sup>11</sup>

As in all clinical procedures, case selection is paramount; not every case is suitable for treatment in the office setting. Patients undergo a preoperative medical assessment that includes complete blood count, platelet count, international normalized ratio and electrocardiogram studies. Patients are assigned a classification according to the American Society of Anesthesiologists' (ASA) system.<sup>12</sup> ASA I and II patients are considered for in-office surgery, which can be performed using 1 of the following 2 techniques.

#### *Harvesting Iliac Crest Bone by Trephination*

Trephination, using a variety of approaches and instruments, has been reported to be a generally safe surgical technique and has been used with minimal morbidity in harvesting bone from the anterior ilium.<sup>5-7,13-22</sup> The use of a power-driven trephine for this purpose has also been established as a safe technique to provide ample bone for many maxillofacial reconstructive procedures, including maxillary sinus elevation and cleft alveolar osseous reconstruction, with minimal morbidity.<sup>5,7,23</sup>

Surgery is performed under intubated general anesthesia provided by an anesthesiologist. This allows the operating surgeon to concentrate on maintaining strict sterility of the surgical site, unencumbered by the

necessity of maintaining the patient's airway or administering anesthetic.

Long-acting local anesthetic consisting of 0.5% bupivacaine with epinephrine (1:200 000) is administered to the iliac crest site to ensure postoperative comfort. The incision, which ranges in length from 1 to 2 cm, depending on the amount of bone required, is made 1 cm posterior to the anterior superior iliac spine (ASIS) and 1 cm lateral to the height of the crest. Dissection is performed through Scarpa's fascia, avoiding both the iliopsoas and gluteal musculature. Following identification of the iliac crest, a mid-crest periosteal incision is made 1 cm posterior to the ASIS, and the bony crest is identified. A guiding trocar (Straumann AG, Waldenburg, Switzerland) is introduced onto the surface of the iliac crest, which then aids the surgeon in the placement of the trephine (Fig. 1).

Once the required number of cancellous bone cores have been obtained (Fig. 2), the edges of the bone are smoothed, the site is cleansed thoroughly with saline and Gelfoam (Pharmacia, Bergenfield, N.J.) is placed in the bony wound to control bleeding. The wound is closed in layers using a layered plastic surgical closure, with interrupted or continuous sutures, and dressed with a pressure dressing. Surgical drains are not required if dissection, wound closure and dressing procedures are performed appropriately.

Following harvesting of bone, attention is turned to the oral cavity, where grafting procedures are completed as required (Figs. 3 and 4). Local anesthesia is administered at the graft recipient site before incision, and the graft surgery, such as sinus floor elevation and augmentation, is performed using the autogenous bone graft. The patient is moved to the office recovery room and standard protocols for doctor and nursing supervision and criteria for discharge are followed. Jensen and Sennerby<sup>24</sup> have shown at a histologic level that implant placement can occur 4 to 6 months following bone grafting (Fig. 5).

#### **Harvesting Block Bone from the Anterior Ilium**

Although particulate cancellous bone has suitable handling properties for applications such as sinus augmentation and cleft alveolar reconstruction, block corticocancellous bone is ideal for reconstructing severe deficiencies in buccolingual ridge width. The use of segments of block bone allows for rigid fixation of the graft, which facilitates its undisturbed vascularization and subsequent incorporation. Harvesting of bone from the medial aspect of the anterior ilium has been demonstrated to have several advantages over lateral crest harvesting,<sup>25</sup> and this technique is preferred by the authors. The length of the iliac incision ranges from 2 to 6 cm, depending on the amount of bone required, and dissection to the iliac crest is identical to that described for the trephination technique.

#### **Box 1** Possible complications from anterior iliac crest harvesting<sup>5-7,11,23</sup>

- Postoperative pain at donor site
- Lateral femoral cutaneous nerve paresthesia or dysesthesia
- Hematoma
- Seroma
- Gait disturbance
- Contour deformity of donor site
- Infection
- Abdominal herniation
- Adynamic ileus
- Stress fracture
- Keloid scar

The medial aspect of the iliac crest is exposed and the medial soft tissues are protected throughout the remainder of surgery (Fig. 6). An osteotomy outlining the size of the required graft is performed at the iliac crest using a combination of saws, drills and chisels. Once the bony block has been obtained, the site is cleansed and Gelfoam (Pharmacia) is applied to the bony wounds of the iliac crest. The incision is closed and pressure dressings are applied as described in the trephination procedure. The intraoral recipient site is exposed, and the harvested piece of block bone is customized to fit the site passively. The corticocancellous bone graft is then fixed to the recipient site using 2.0-mm bone screws (Fig. 7). Cancellous bone is used to graft the gaps around the perimeter of the graft. The soft tissue flap is undermined and expanded to facilitate passive, tension-free closure over the graft. As with the trephined cancellous cores, implant placement can generally take place 4–6 months after graft surgery, at which time the bone fixation screws are removed (if nonresorbable metal screws were used) and the dental implants are placed.

#### **Discussion**

Several recent advances in minimally invasive bone-harvesting techniques<sup>26–28</sup> have allowed a greater range of reconstructive surgeries to be performed in the ambulatory care setting. Motorized trephination for harvesting bone from the anterior ilium has been supported in the literature,<sup>5,7,23</sup> and the safety of this technique has been documented as it has evolved over 7 years.<sup>6,7,11</sup>

The technique described in this report was initially investigated in a cadaver study.<sup>23</sup> Once deemed to be anatomically safe, the procedure was then used in hospital until its safety record was established for ambulatory care.<sup>5,6,23</sup> The technique was then further developed into

a routine outpatient procedure without the need for a postoperative hospital stay.<sup>7</sup> More recently, the techniques described in this report were studied in 40 iliac crest bone-graft harvests performed entirely in the office setting.<sup>11</sup> Medial iliac crest block harvesting is also well established,<sup>4,25,29–31</sup> and the complications associated with this procedure<sup>6,24,32–38</sup> can be minimized by good surgical technique and proper case selection. As with any surgical procedure, there are possible complications (Box 1), many of which occur rarely. The 40 harvested sites resulted in complications limited to 2 seromas and 1 hematoma for an incidence of 7.5%. One patient sustained partial paresthesia in the distribution of the lateral femoral cutaneous nerve and 1 patient complained of hip pain and difficulty ambulating (2% incidence for each). None of these complications would have been prevented by hospital admission. All patients in that study were discharged directly home from the in-office setting as planned with no admissions to hospital.<sup>11</sup> Similar results have been obtained by harvesting bone from other extraoral sites such as the tibia.<sup>39</sup>

Iliac crest harvesting in the office setting allows patients to receive a wide range of reconstructive procedures on a timely basis, expediting their reconstructive care. Surgery and anesthesia provided in the office setting are not covered by provincial health plans, and the financial responsibility for these procedures is assumed by the patient. At present, limited coverage for these procedures may be extended by private insurance carriers.

It is the responsibility of surgeons performing iliac crest graft surgery to ensure that they are adequately trained to perform such procedures in an out-of-hospital setting and to maintain the highest standards of safety and excellence so that the frontiers of hospital-based surgery are not being moved without due care and attention to the safety of the patient. Patients are generally very satisfied with the provision of their surgery in the office setting.<sup>11</sup> The advantages of performing iliac crest harvesting in the private practice setting include patient convenience, increased predictability in the scheduling of surgery and the prompt delivery of elective reconstructive care. ♦

## THE AUTHORS



*Dr. Freilich is staff pediatric oral and maxillofacial surgeon, The Hospital for Sick Children and Bloorview Kids' Rehab; and associate in dentistry at the faculty of dentistry, University of Toronto, Ontario. He maintains a private practice in North Toronto.*



*Dr. Sándor is clinical director of the graduate program in oral and maxillofacial surgery and anesthesia, Mount Sinai Hospital; coordinator of pediatric oral and maxillofacial surgery, Hospital for Sick Children and Bloorview Kids' Rehab; professor of oral and maxillofacial surgery, University of Toronto, Ontario; and docent, University of Oulu, Finland.*

*Correspondence to: Dr. Marshall M. Freilich, The Hospital for Sick Children, Department of Dentistry, S-525, 555 University Ave., Toronto, ON M5G 1X8.*

*The authors have no declared financial interests in any company manufacturing the types of products mentioned in this article.*

## References

- Marx RE. Philosophy and particulars of autogenous bone grafting. *Oral Maxillofac Surg Clin North Am* 1993; 5:599–612.
- Kainulainen VT, Sandor GK, Clokie CM, Oikarinen KS. Intraoral bone harvesting in oral and maxillofacial surgery. *Suomen Hammaslääkärilehti* (Finnish Dental Journal) 2002; 5:216–22.
- Kainulainen VT, Sandor GK, Caminiti MF, Clokie CM, Oikarinen KS. Extraoral bone harvesting sites for oral and maxillofacial surgery. *Suomen Hammaslääkärilehti* (Finnish Dental Journal) 2002; 10–11:570–6.
- Mrazik J, Amato C, Leban S, Mashberg A. The ilium as a source of autogenous bone for grafting: clinical considerations. *J Oral Surg* 1980; 38(1):29–32.
- Sandor GK, Nish IA, Carmichael RP. Comparison of conventional surgery with motorized trephine in bone harvest from the anterior iliac crest. *Oral Surg Oral Med Oral Pathol Oral Radiol Endod* 2003; 95(2):150–5.
- Sandor GK. The minimization of morbidity in craniomaxillofacial osseous reconstruction: bone graft harvesting and coral-derived granules as a bone graft substitute. Doctoral thesis. *Acta Universitatis Ouluensis* 2003; D-715:76–8.
- Sandor GK, Rittenberg BN, Clokie CM, Caminiti MF. Clinical success in harvesting autologous bone using a minimally invasive trephine. *J Oral Maxillofac Surg* 2003; 61(2):164–8.
- Hatch WV, Trope GE. Waiting times for eye surgery at a Toronto teaching hospital. *Can J Ophthalmol* 2004; 39(1):31–7.
- McPherson K, Coulter A, Stratton I. Increasing use of private practice by patients in Oxford requiring common elective surgical operations. *Br Med J (Clin Res Ed)* 1985; 291(6498):797–9.
- Cheng LH, Newman L. Overnight-stay patients in a day surgery unit to overcome shortage of inpatient beds. *Br J Oral Maxillofacial Surg* 2005; 43(2):169–72.
- Freilich MM, Sandor GK. Ambulatory in-office anterior iliac crest bone harvesting. *Oral Surg Oral Med Oral Pathol Oral Radiol Endod* 2006; 101(3):291–8.
- American Society of Anesthesiologists. ASA physical status classification system. Available from: URL: <http://www.asahq.org/clinical/physicalstatus.htm>.
- Abubaker AO, Sotereanos GC. Modified technique for harvesting bone from the ilium for grafting alveolar clefts. *J Oral Maxillofac Surg* 1989; 47(11):1230–1.
- Schwartz HC, Leake DL. Use of a craniotome for obtaining cancellous bone and marrow from the ilium. *Ann Plast Surg* 1979; 3(6):576–7.
- Wagner JD, Moore DL. The use of cylindrical osteotomes for harvesting cancellous bone from the ilium. *J Oral Maxillofac Surg* 1991; 49(4):433–4.
- Altman K, Blenkinsopp PT. Use of the bone biopsy trephine to obtain iliac crest cancellous bone. *J Oral Maxillofac Surg* 1994; 52(5):522–3.
- McGurk M, Barker G, Grime PD. The trephining of bone from the iliac crest: an anterior approach. *Int J Oral Maxillofac Surg* 1993; 22(2):87–90.
- Billmire DA, Rotatori S. Use of the CORB needle biopsy for the harvesting of iliac crest bone graft. *Plast Reconstr Surg* 1994; 93(2):416–8.
- Tilley MG, Davis LF. Trephine technique to obtain cancellous bone. *J Oral Maxillofac Surg* 1984; 42(1):64–5.
- teVelde J, den Ottolander GJ, Haak HL, van't Veer M, Hartgrink-Groeneveld CA, Spaander PJ, and others. Iliac bone marrow trephine biopsy: some remarks on the technique. *Neth J Med* 1978; 21(5):221–7.
- Smirnov AN, Baranov AE. Trephine for iliac-crest biopsy. *Lancet* 1971; 1(7713):1353–4.
- Schuyt C, Meulemans A, van Eek WH. A bone-fixing trephine for large-diameter iliac biopsies in dogs. *Calcif Tissue Int* 1979; 29(1):71–3.
- Caminiti MF, Sandor GK, Carmichael RP. Quantification of bone harvested from the iliac crest using a power-driven trephine. *J Oral Maxillofac Surg* 1999; 57(7):801–5.
- Jensen OT, Sennerby L. Histologic analysis of clinically retrieved titanium microimplants placed in conjunction with maxillary sinus floor augmentation. *Int J Oral Maxillofac Implants* 1998; 13(4):513–21.
- Marx RE, Morales MJ. Morbidity from bone harvest in major jaw reconstruction: a randomized trial comparing the lateral anterior and posterior approaches to the ilium. *J Oral Maxillofac Surg* 1988; 46(3):196–203.
- Kainulainen VT, Sandor GK, Oikarinen KS, Clokie CM. Zygomatic bone: an additional donor site for alveolar bone reconstruction. *Int J Oral Maxillofac Implants* 2002; 17(5):723–8.

27. Ilankovan V, Stronczek M, Telfer M, Peterson LJ, Stassen LFA, Ward-Booth P. A prospective study of trephined bone grafts of the tibial shaft and iliac crest. *Br J Oral Maxillofac Surg* 1998; 36(6):434-9.
28. Oikarinen K, Kainulainen V, Kainulainen T. A method of harvesting cortico-cancellous bone chips for reconstructive maxillofacial surgery. *Int J Oral Maxillofac Surg* 1997; 26(2):103-5.
29. Keller EE, Triplett WW. Iliac bone grafting: review of 160 consecutive cases. *J Oral Maxillofac Surg* 1987; 45(1):11-4.
30. van der Wal KG, de Visscher JG, Stoelinga PJ. The autogenous inner table iliac bone graft: a review of 100 patients. *J Maxillofac Surg* 1986; 14(1):22-5.
31. Hall MB, Smith RG. The medial approach for obtaining iliac bone. *J Oral Surg* 1981; 39(6):462-5.
32. Laurie SW, Kaban LB, Mulliken JB, Murray JE. Donor site morbidity after harvesting rib and iliac bone. *Plast Recon Surg* 1984; 73(6):933-8.
33. Joshi A, Kostakis GC. An investigation of post-operative morbidity following iliac crest graft harvesting. *Br Dent J* 2004; 196(3):167-71.
34. Tayapongsak P, Wimsatt JA, LaBanc JP, Dolwick MF. Morbidity from anterior ilium bone harvest. A comparative study of lateral versus medial surgical approach. *Oral Surg Oral Med Oral Pathol* 1994; 78(3):296-300.
35. Arrington ED, Smith WJ, Chambers HG, Bucknell AL, Davina NA. Complications of iliac crest bone graft harvesting. *Clin Orthop Relat Res* 1996; 329:300-9.
36. Kalk WW, Raghoebar GM, Jansma J, Boering G. Morbidity from iliac crest bone harvesting. *J Oral Maxillofac Surg* 1996; 54(12):1424-9.
37. Ziccardi VB, Lalikos JF, Sotereanos GC, Patterson GT. Retroperitoneal hematomas as a complication of anterior iliac crest harvest: report of a case. *J Oral Maxillofac Surg* 1992; 50(10):1113-6.
38. Swan MC, Goodacre TE. Morbidity at the iliac crest donor site following bone grafting of the cleft alveolus. *Br J Oral Maxillofac Surg* 2006; 44(2):129-33.
39. Marchena JM, Block MS, Stover JD. Tibial bone harvesting under intravenous sedation: morbidity and patient experiences. *J Oral Maxillofac Surg* 2002; 60(10):1151-4.

## Expand Your Practice with Orthodontics!

- Enhance Patient Care
- Increase your satisfaction
- Grow your income

### CSW & Functional Orthodontic Program

- Most comprehensive Fixed and Interceptive orthodontic course available today! Ten sessions spread over two years.
- Designed for those new to orthodontics and for experienced doctors who want to upgrade their skills.
- Covers full spectrum from diagnosis and treatment planning to effective application of Functional Appliance and Straight Wire therapy.
- Personal case study at each session! Attendance limited!
- For a complete description of the course compendium please call 1-877-20-ORTHO or email [info@cswfop.com](mailto:info@cswfop.com)

#### First Sessions Starting In:

Halifax Nov. 3 & 4                      Toronto Nov. 5 & 6  
Winnipeg Nov. 17 & 18                  Vancouver Nov. 19 & 20

All dates and locations will be confirmed 30 days before commencement of course.



Dr. Bond



Dr. Macdonald

### The Clinicians

- Senior certified Academy of Orthodontics instructors.
- Have lectured for more than 20 years to general and paediatric dentists across Canada, the U.S. and Mexico.
- References available on request at **1-877-20-ORTHO**.



ADAC • E • R • P  
CONTINUING EDUCATION RECOGNITION PROGRAM

The Academy of General Dentistry recognizes the ADA CERP approval and therefore FAGD/MAGD credit will be awarded.

To reserve your place,  
call TOLL FREE 1-877-20-ORTHO or  
visit our website at [www.cswfop.com](http://www.cswfop.com).