

Esthetic Option for the Implant-Supported Single-Tooth Restoration — Treatment Sequence With a Ceramic Abutment

- Pierre Boudrias, DMD, MSD •
- Élise Shoghikian, DMD, MSD •
- Éric Morin, DMD, MSD •
- Paul Hutnik, Td. •

A b s t r a c t

A single implant-supported restoration is one treatment alternative to consider for the replacement of a missing tooth. Technological advances in materials and machining have led to the development of a densely sintered aluminum oxide ceramic abutment, designed and machined using CAD/CAM technology. This manufacturing method improves management of the subgingival depth of the crown/abutment interface and enhances the esthetic qualities of the restoration. However, since this ceramic abutment has less mechanical resistance than metal abutments, its use should be confined to the restoration of incisors and premolars not subjected to excessive occlusal forces.

MeSH Key Words: dental abutments; dental implants, single-tooth; dental porcelain; dental prosthesis, implant-supported

© J Can Dent Assoc 2001; 67:(9)508-14
This article has been peer reviewed.

There are several restorative alternatives for replacing a missing anterior tooth. The single implant-supported restoration is among the prosthetic options under certain biological (sufficient bone mass, condition and morphology of the periodontium, integrity of natural and restored teeth) and biomechanical conditions (occlusal forces).¹⁻⁶

In order to meet growing esthetic demands, aluminum oxide ceramic abutments⁷ (CerAdapt: Nobel Biocare AB, Göteborg, Sweden) and zirconium abutments (ZiReal Post: 3i Implant Innovations Inc., Palm Beach Gardens, United States) have been developed to improve light transmission and to imitate the optical properties of a healthy natural tooth.^{8,9}

A recent application of Computer Assisted Design/Computer Assisted Machining (CAD/CAM) technology consists of machining an abutment adapted to each clinical situation. This method was first applied to titanium abutments. The initial technique used the Procera 3D CAD (3 Dimensions Computer Assisted Design) (Nobel Biocare AB, Göteborg, Sweden), a computer program that

reproduced the position of the implant and allowed for the design of an abutment of ideal shape and tilt. This information was then transmitted to a device that machined the final abutment in a titanium cylinder. Another technique consists of first waxing an abutment on the master model. The surface of the wax-up is then digitalized and the final abutment is machined identically in titanium.¹⁰

With advances in dental materials and biomechanics, it is now possible to apply CAD/CAM technology to ceramic.¹¹ This type of abutment is composed of a densely sintered high-purity aluminum oxide. Because of its colour, similar to that of natural teeth (~A3 Vitapan: Vita Zahnfabrik, Bad Säckingen, Germany) and its light transmission properties, the reduced luminosity of the gingiva or greyish gingival discolouration sometimes observed with metal abutments is avoided.^{6,12}

Today, the technique to design a ceramic abutment uses only the Procera 3D CAD computer program. The shape of the abutment is transmitted to a machining device that shapes the aluminum oxide ceramic at the green (immature) stage to prevent hairline fractures. The completed

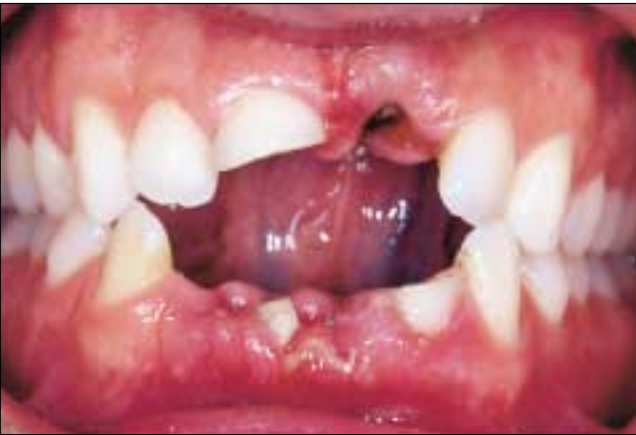

Figure 1: Clinical view 6 days after the trauma.

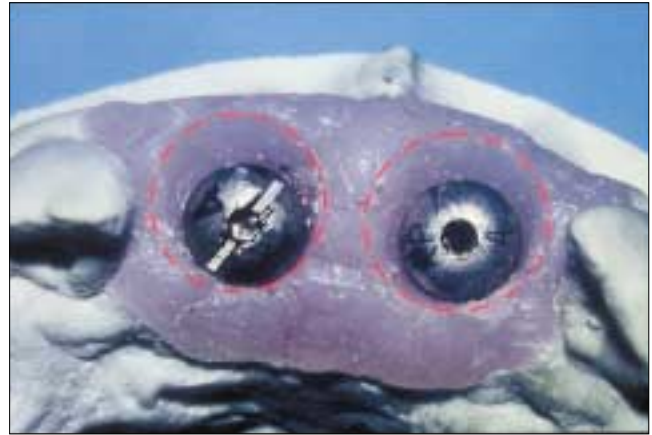


Figure 2: The implants are more than 4 mm below the gingival level. The gingival emergence profile is increased slightly on the master model. This facilitates the fabrication of temporary restorations with a more harmonious sub- to supra-gingival coronal transition and more suitable dimensions at the gingival 1/3 of crowns 11 and 21.

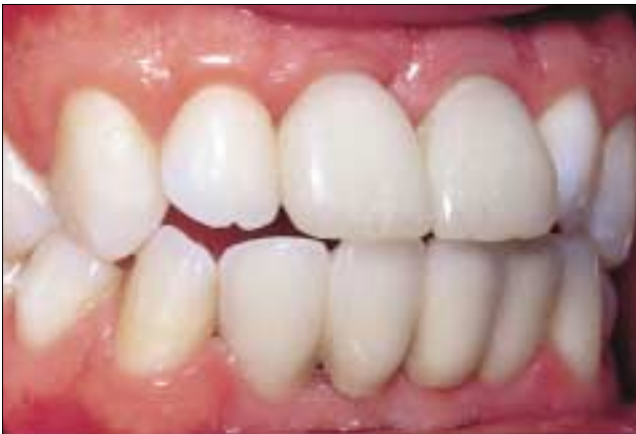

Figure 3: After minor gingivoplasty, temporary restorations 11 and 21 are fixed to the implants. They maintain the emergence profile and guide the gingival healing. A porcelain-fused-to-metal restoration 32-X-X-42 is fixed to the implants (Laboratoire dentaire Artech).

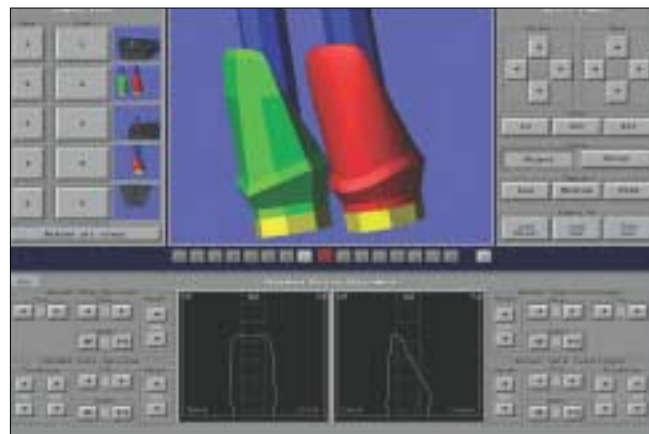


Figure 4: The final shape of abutments 11 and 21 is produced using a ProCera CAD 3D program. Each abutment is designed and adjusted labially and interproximally (photo: Mr. Gunnar Bagge, Nobel Biocare, North York, Ontario).

high-density ceramic abutment is obtained after the final sintering.

The crown restoration may be done 2 ways.⁴ When the longitudinal axis of the implant passes through the centre of the lingual surface of the final crown, a screw-retained crown is produced by curing the porcelain directly onto the abutment. When the longitudinal axis of the implant traverses the incisal edge of the final crown, the abutment is shaped to receive a cemented crown.

Knöde and Sørensen showed that the aluminum oxide abutment had 40% less fracture resistance when compared to a prefabricated titanium (CeraOne: Nobel Biocare AB, Göteborg, Sweden).¹³ This component has been designed primarily for a single-unit restoration and a short-span bridge in an esthetic zone where occlusal loads are moderate.^{4,5}

This article presents the advantages and limitations of the aluminum oxide ceramic abutment and illustrates its possibilities with 2 clinical cases.

Clinical Case No. 1

Teeth 11 and 21 were fractured following a trauma (fig. 1). These teeth were cut down below the gingival level. One month after, they were extracted and 2 implants of 3.75 mm x 13 mm were inserted at the same appointment (technique described by Langer¹⁴).

The implants were exposed during a second surgical phase, 6 months after insertion. The healing abutments were removed 2 weeks later, and the impression was taken with screw-retained fixture level transfers.

The gingival emergence profile was widened slightly (coronal 1/2 of the gingival height) on the master model around the implants 11 and 21 areas to create a more

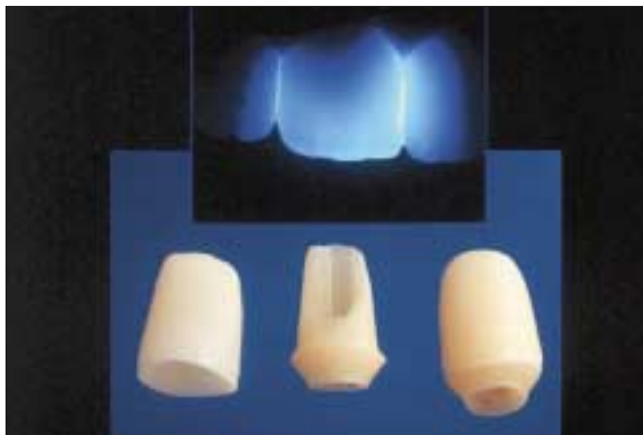


Figure 5: Procera aluminum oxide ceramic abutments and crown copings (Mr. Paul Hutnik, Quantum Dental Laboratory). The joint use of a ceramic abutment and a ceramic crown improve light transmission.

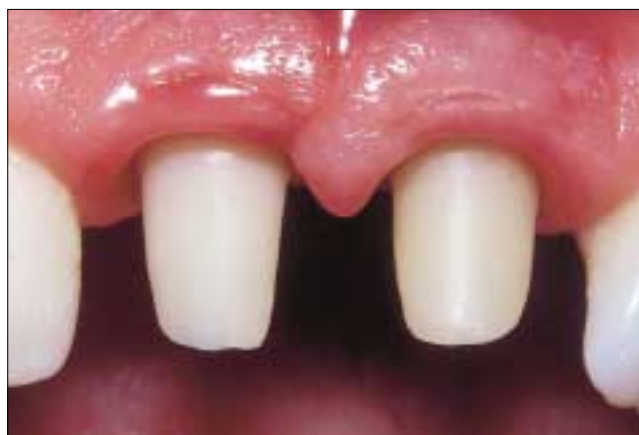

Figure 6: Ceramic abutments. The shoulder of the abutment is 1 to 2 mm below the gingival level.

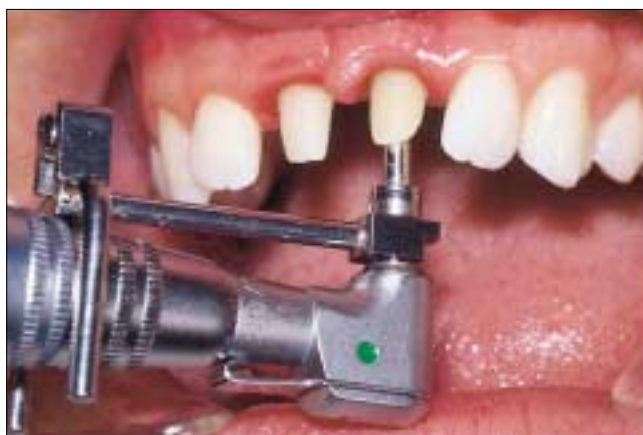

Figure 7: Tightening of the abutment screw at 32 Ncm with counter-torque.

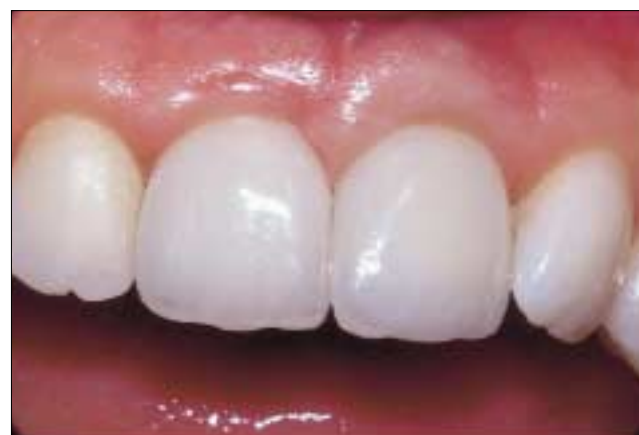

Figure 8: Procera crowns cemented with an adhesive composite resin cement (porcelain: Mr. Roger Picard, dental technician).

harmonious prosthetic transition between the subgingival and supragingival portion of the restorations. This minor modification of the gingival profile allows for better esthetics at the cervical 1/3 of centrals 11 and 21 (**fig. 2**).

Two individual screw-retained provisional restorations were then prepared directly on the master model using temporary abutments (hexagonal base) and autopolymerizing acrylic resin.

The healing abutments were removed at the next appointment and a minor gingivoplasty was performed with a diamond bur to recreate the gingival emergence profile produced on the master model. Screw-retained temporary restorations 11 and 21 were placed onto the implants and served as a gingival healing matrix (**fig. 3**).

In the laboratory, a T-bar with a hexagonal base was fixed to the hex of the implant replica in the master model. The position of this T-bar makes it possible to produce a virtual image on the computer screen that copies the position of the implant on the master model using the Procera

3D CAD program. The tilt and shape of the abutment were determined and designed with the computer according to the longitudinal axis of the implant, guided by the surfaces of the adjacent teeth (**fig. 4**).

These abutments were designed to receive 2 ceramic crowns. The abutment shoulder was approximately 2 mm below the gingival level and followed the shape of the gingival scallop.

The computer drawing of the shape of the abutments was transmitted to a Procera workstation. The ceramic was pressed and machined at an immature (green) stage by following the contours produced with the Procera 3D CAD program. Final sintering of the ceramic abutments 11 and 21 was then completed. In the laboratory, the dental technician digitalized the surface of the ceramic abutments to fabricate 2 ceramic crowns¹⁵ (**fig. 5**).

The temporary restorations were removed and ceramic abutments 11 and 21 were placed in position on their

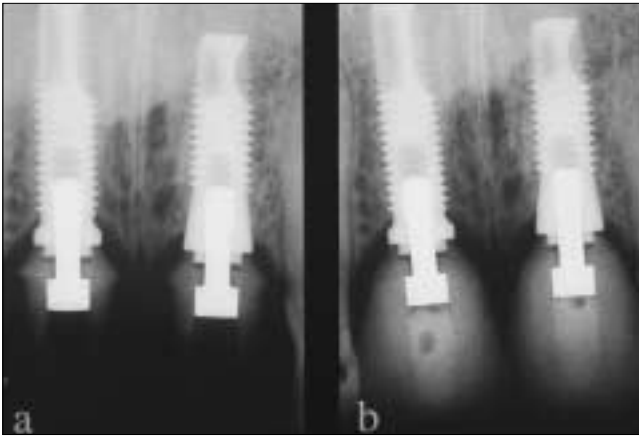


Figure 9: Periapical radiographs: a) 11 and 21: implants/posts, b) 11 and 21: implants/abutments ceramic crowns cemented.

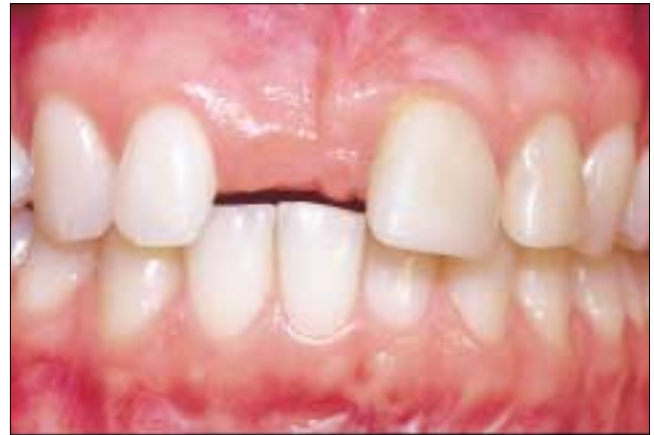

Figure 10: Clinical view 4 years after the trauma to the anterior teeth.

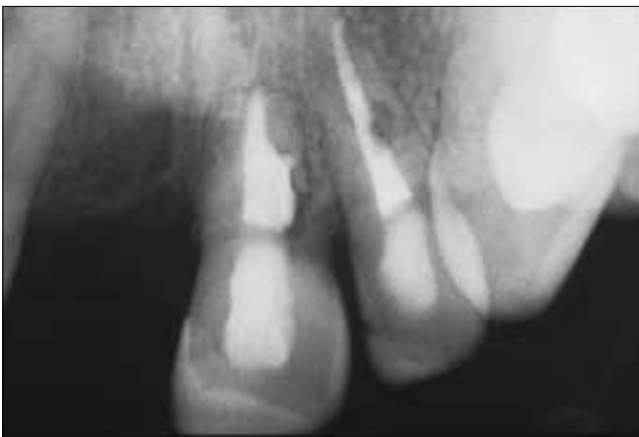

Figure 11: Root resorption at the level of teeth 21 and 22.

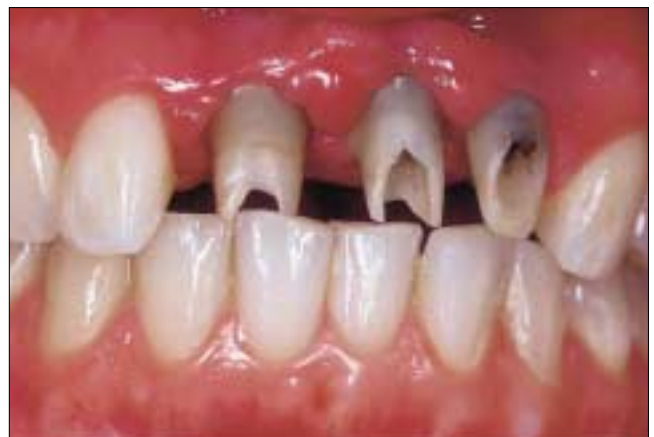

Figure 12: Aluminum oxide ceramic abutments fixed onto the implants. The shoulder of abutment 21 is at gingival level.

respective implants (**fig. 6**). Each gold screw was tightened at 32 Ncm with the aid of a torque driver (**fig. 7**).

After occlusal and proximal adjustments, the ceramic crowns were cemented with an adhesive cement (**figs. 8 and 9**).

Clinical Case No. 2

A young woman suffered a trauma to the upper incisors at age 13. Tooth 11 was extirpated under the impact, and teeth 21 and 22 were treated endodontically and restored with composite resin (**fig. 10**).

During a recall examination 4 years after the trauma, a periapical radiograph revealed advanced intra- and extraradicular resorption in teeth 21 and 22 (**fig. 11**).

One month after “cutting down” teeth 21 and 22 subgingivally, the roots of these teeth were extracted and 2 implants were inserted during the same appointment (technique described by Langer).¹⁴ A partial acrylic prosthesis was used as a temporary restoration.

Six months after insertion of the implants, the second surgical phase (exposure of the implants and healing abutments) was performed. It is preferable to wait a mini-

mum of 1 to 2 weeks before taking the final impression to allow the soft tissue to heal. If the impression is taken too soon after the second surgical phase, the master model will reproduce a swollen gingiva and there is a risk of incorrectly establishing the subgingival depth of the abutment shoulder.

The impression was made with screw-retained fixture level transfers (hexagonal base) and the master model was delivered to the dental laboratory for preparation of the ceramic abutments.

As the longitudinal axis of the implants intersected the incisal edge of the future crowns (slight labial tilt), a “cemented-crown-onto-abutment” prosthetic approach was chosen. This restorative technique is often used in the anterior region of the maxilla because of the labial profile of the bone and the rectilinear shape of the implants.

The ceramic abutments were completed and the outer surface of each was digitalized to fabricate 3 Procera all-ceramic crowns (Nobel Biocare AB, Göteborg, Sweden).¹⁵

Each abutment was carefully oriented and positioned on its respective implant (**fig. 12**). A periapical radiograph taken perpendicular to the longitudinal axis of the implant

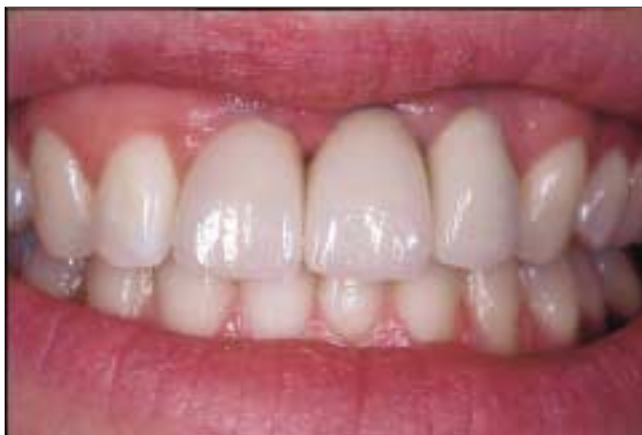

Figure 13: Procera ceramic crowns cemented (abutments and copings: Mr. Paul Hutnik; porcelain: Laboratoire dentaire Denta-Design).

ensured the correct placement of the abutment hex over the implant hexagon and the fit at the abutment/implant interface.

The gold alloy screw (Unigrip: Nobel Biocare AB, Göteborg, Sweden) of each abutment was tightened to 32 Ncm (implant diameter: 3.75 mm) with the aid of a torque driver.

Interproximal contacts and occlusion were adjusted on crowns 11, 21 and 22. A thin layer of a temporary filling material (Fermit: Ivoclar Vivadent, Schaan, Liechtenstein) or condensed white gutta percha was used to isolate the gold screw and the rest of the access cavity was filled with composite resin. The ceramic crowns were then cemented with an adhesive cement onto their respective abutments (figs. 13 and 14). The excess cement is removed before final polymerization. This cement cleaning procedure is easier since the CAD/CAM technology enables the dental technician to determine the subgingival depth of the abutment shoulder and the ceramic abutment/crown interface is accessible at less than 2 mm subgingivally.

Discussion

The ceramic abutment used in conjunction with an all-ceramic crown contributes to the enhanced esthetic result. The favourable optical properties (light transmission) coupled with a colour that is close to that of natural teeth promotes high esthetic performance in the case of single-tooth restorations.^{4-6,11}

When the gingiva is thin and translucent, the subgingival intrusion of this ceramic abutment eliminates the greyish discolouration of the marginal gingiva observed with metal posts.^{4,11}

However, the visibility of the collar (supragingival) of the aluminum oxide ceramic abutment may be unesthetic. This caution applies to the "crown-cemented-onto-abutment" technique. The rather saturated colour (A3 Vitapan) of the ceramic abutment may result in a demarca-

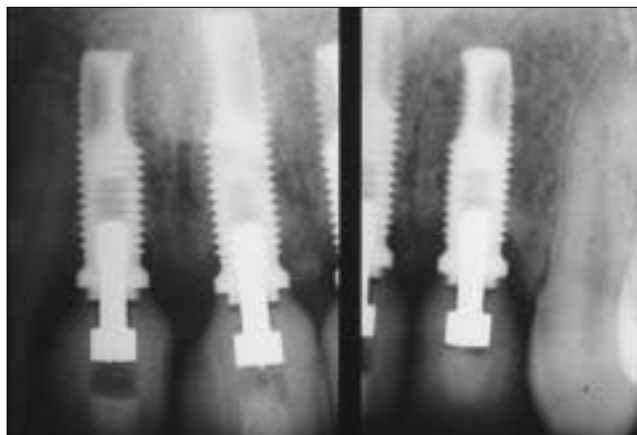


Figure 14: Periapical radiographs: Implants 11, 21, 22, screw-retained ceramic abutments (32 Ncm), Procera ceramic crowns.

tion with the colour of the crown. If the collar of the abutment cannot be placed subgingivally due to an inadequate apical placement of the implant, its saturated tint will clearly stand out from a pale-coloured crown (i.e. B1, A1 Vitapan). If, however, the final crown is more saturated in colour (i.e. A3, B3 Vitapan), the abutment will blend in with the colour of the restoration and the supragingival abutment/crown junction will go unnoticed.

Knöde and Sørensen compared the mechanical resistance of 3 abutments: a prefabricated titanium abutment (CeraOne: Nobel Biocare AB, Göteborg, Sweden), a cast abutment in gold alloy, and the aluminum oxide ceramic abutment (CerAdapt: Nobel Biocare AB, Göteborg, Sweden). The ceramic abutment fractured with the application of a lesser load (117 N) than the titanium and the cast abutments (198 N).¹³ To ensure adequate fracture resistance, the densely sintered aluminum oxide ceramic abutment requires a minimum height of 7 mm and an axial wall thickness of more than 0.7 mm.

The use of this ceramic abutment is limited to incisor and premolar restorations. Its mechanical resistance is inadequate for molar, canine or incisor replacement when there is an overbite superior to 50%. However, when the occlusal forces are light to moderate (minor vertical overlap, little or no lateral or protrusive guidance), a single-tooth restoration built with a ceramic abutment is acceptable, especially in the anterior maxillary zone where the occlusal loads are less significant and the esthetics more important.

It is possible to machine a ceramic abutment to correct a slight labial tilt of the implant. However, a distinctly labial longitudinal axis of the implant (through the labial middle 1/3) leads to a severe thinning or elimination of the buccal wall of the access cavity. Furthermore, the labial reduction of the abutment to correct its angulation causes a marked weakening of its axial walls and of its labio-gingival collar. The angle created between the longitudinal axis of

the implant and the labial surface of the abutment should be well under 30° to avoid excessive thinning of the labial surface of the ceramic abutment that may result in a cohesive fracture.

The 2 clinical cases illustrated in this article, which have been restored with individual single-tooth restorations, are examples of restorations with single-unit crowns. As discussed earlier, both of these patients presented with no exaggerated centric occlusion or protrusive occlusal forces. In clinical case no. 2, there was no protrusive guidance on these implant-supported single-tooth restorations and the same occlusal situation prevailed before implant placement. When there are greater occlusal loads, oblique and horizontal forces caused by more pronounced protrusive guidance, we need to splint units in order to distribute the occlusal stresses over several implants rather than risk overloading the individual implants.

These ceramic abutments benefit from CAD/CAM technology. With the "crown-cemented-onto-abutment" approach, the shoulder is prepared following the contour of the gingival scallop to a subgingival depth of no more than 2 mm. The regular and uniform placement of the abutment/crown interface facilitates the removal of excess cement. Conversely, prefabricated machined abutments have a circumferential collar and a shoulder at a predetermined height, and the subgingival depth interproximally is often greater than that found at the level of the buccal or lingual surface.

Papavasiliou and others¹⁶ compared the stress produced with the 2 restorative methods (crown cemented onto a ceramic abutment and screw-retained crown) using 2-dimensional finite-element analysis. The crown cemented onto a ceramic abutment generated a better distribution of occlusal loads and reduced the stress on the thinner portions of the abutment.

Prestipino and Ingber recommend a type of cement based on the desired degree of reversibility.⁴ Temp-Bond type temporary cements (Kerr Manufacturing Company, Romulus, United States) offer reversibility. However, these cements offer poor retention and are too opaque.

Awliya and others¹⁷ obtained adequate retention using an aluminum oxide ceramic sandblasted with particles of aluminum oxide 50 µm and cemented with different adhesive bonding resins. Dwan and others¹⁸ compared the fracture resistance of Procera crowns with 3 types of cement. The values of the loads causing the crowns to fracture are distinctly superior with the adhesive cement (225 kg) and with the hybrid glass ionomer (214 kg) compared to the values obtained with zinc phosphate (153 kg). However, these 3 categories of cement cannot be considered reversible.

Adhesive composite resin cements have superior physical properties and do not interfere with light transmission.¹⁹

Conclusion

The use of a ceramic abutment may be considered when an implant-supported single-tooth restoration is fabricated in an esthetic zone where the occlusal forces are slight to moderate.

It is preferable to take the impression and prepare a ceramic post after the gingiva heals so that the shoulder of the abutment is designed at the correct subgingival height (crown cemented onto ceramic post approach).

The aluminum oxide ceramic abutment is contraindicated when its height is less than 7 mm and the thickness of the axial walls is less than 0.7 mm. The angle formed between the labial surface of the abutment and the longitudinal axis of the implant must be less than 30°. With the "ceramic-crown-cemented-onto-abutment" approach, a visible supragingival collar of the aluminum oxide ceramic abutment blends better with a crown that presents a gingival 1/3 with saturated colours.

The ceramic post is especially advantageous when the mucogingival complex is thin and translucent. The risk of decreased luminosity and greyish gingiva shadowing is thus eliminated. ♦

Acknowledgments: Mr. Gunnar Bagge (Nobel Biocare) for his expertise; Mr. Bruno Berlatie, dental technician, Université de Montréal, and Mr. Roger Picard, dental technician, Laboratoire dentaire Roger Picard, for their technical support; and Dr. Jean-François Brunet, for his comments.

Dr. Boudrias is a prosthodontist, full professor, department of restorative dentistry, Université de Montréal.

Dr. Shoghikian is a periodontist in private practice, and senior clinical lecturer in periodontics, Université de Montréal.

Dr. Morin is an oral and maxillofacial surgeon in private practice, and senior clinical lecturer in oral surgery, Université de Montréal.

Mr. Hutnik is a dental technical, Quantum Dental Laboratory.

Correspondence to: Dr. Pierre Boudrias, Université de Montréal, Faculty of Dentistry, P.O. Box 6128, Centre-ville Station, Montreal, QC H3C 3J7. E-mail: boudriap@medent.umontreal.ca.

Dr. Boudrias has lectured and provided consulting services for Nobel Biocare and other companies manufacturing implants and related components.

References

- Henry PJ, Laney WR, Jemt T, Harris D, Krogh PH, Polizzi G, and others. Osseointegrated implants for single-tooth replacement: a prospective 5-year multicenter study. *Int J Oral Maxillofac Implants* 1996; 11(4):450-5.
- Schmitt A, Zarb GA. The longitudinal clinical effectiveness of osseointegrated dental implants for single-tooth replacement. *Int J Prosthodont* 1993; 6(2):197-202.
- Scheller H, Urgell JP, Kultje C, Klineberg I, Goldberg PV, Stevenson-Moore P, and others. A 5-year multicenter study on implant supported single crown restorations. *Int J Oral Maxillofac Implants* 1998; 13(2):212-8.
- Prestipino V, Ingber A. Esthetic high-strength abutments. Part I. *J Esthet Dent* 1993; 5(1):29-36.
- Prestipino V, Ingber A. Esthetic high-strength abutments. Part II. *J Esthet Dent* 1993; 5(2):63-8.
- Prestipino V, Ingber A. All-ceramic implant abutments: esthetic indications. *J Esthet Dent* 1996; 8(6):255-62.

7. Andersson B, Schärer P, Simion M, Bergström C. Ceramic implant abutments used for short-span fixed partial dentures: a prospective 2-year multicenter study. *Int J Prosthodont* 1999; 12(4):318-24.
8. Geller W, Kwiatkowski SJ. The Willi's glass crown: a new solution in the dark and shadowed zones of esthetic porcelain restorations. *Quintessence Dent Technol* 1987; 11(4):233-42.
9. O'Boyle KH, Norling BK, Cagna DR, Phoenix RD. An investigation of new metal framework design for metal ceramic restorations. *J Prosthet Dent* 1997; 78(3):295-301.
10. Marchack CB, Yamashita T. Fabrication of a digitally scanned, custom-shaped abutment: a clinical report. *J Prosthet Dent* 2001; 85(2):113-5.
11. Hegenbarth E. Use of the Procera CAD/CAM System for metal-free crowns on single-tooth implants. *Quintessence Dent Tech* 1998; 1:27-37.
12. Yildirim M, Edelhoff D, Hanish O, Spiekermann H. Ceramic abutments — A new era in achieving optimal esthetics in implant dentistry. *Int J Periodontics Restorative Dent* 2000; 20(1):81-91.
13. Knode H, Sorensen JA. Fracture strength of ceramic single tooth implant restoration. *J Dent Res* 1992; 71(abstr 1137):248.
14. Langer B. Spontaneous in situ gingival augmentation. *Int J Periodontics Restorative Dent* 1994; 14(6):524-35.
15. Andersson M, Razzoog ME, Oden A, Hegenbarth EA, Lang BR. Procera: a new way to achieve an all-ceramic crown. *Quintessence Int* 1998; 29(5):285-96.
16. Papavasiliou G, Tripodakis AP, Kamposiora P, Strub JR, Bayne SC. Finite element analysis of ceramic abutment-restoration combinations for osseointegrated implants. *Int J Prosthodont* 1996; 9(3):254-60.
17. Awliya WA, Yaman P, Dennison JB, Razzoog ME. High energy abrasion and resin cement bond to alumina core. *J Dent Res* 1996; 75(abstr 2884):378.
18. Dwan A, Yaman P, Razzoog ME, Wang RF. Effect of cement on fracture resistance of all-ceramic crowns. *J Dent Res* 1996; 75(abstr 2136):284.
19. Diaz-Arnold AM, Vargas MA, Haselton DR. Current status of luting agents for fixed prosthodontics. *J Prosthet Dent* 1999; 81(2):135-41.

C D A R E S O U R C E C E N T R E

CDA members can borrow a copy of *Esthetic dentistry and ceramic restorations*, by Bernard Touati, Paul Miara and Dan Nathanson, by contacting the Resource Centre at tel.: 1-800-267-6354 or (613) 523-1770, ext. 2223; fax: (613) 523-6574; e-mail: info@cda-adc.ca. (Shipping charges and taxes apply on all loans.)

C D A R E S O U R C E C E N T R E

Information Package, October 2001

This month's package contains a selection of reading material on **dental impression techniques** and is available to CDA members for \$10.00 plus applicable tax.

A complete list of information packages is available upon request by calling 1-800-267-6354 or can be easily accessed on CDA's Web site at www.cda-adc.ca. Once on the site, please log into the "CDA Members" area and click on "Resource Centre" to view the list of packages. Each information package contains the most up-to-date articles on any given subject.

New Acquisitions: Textbooks

Brånemark, Per-Ingvar, *Osseointegration and autogenous onlay bone grafts*, Quintessence, 2001.

Cohen, Stephen & Burns, Richard C., *Pathways of the pulp*, 8th ed., Mosby, 2002.

Dimitroulis, George, *Handbook of third molar surgery*, Wright, 2001.

Francischone, Carlos Eduardo, Vasconcelos, Laércio Wonhrath & Brånemark, Per-Ingvar, *Osseointegration and esthetics in single tooth rehabilitation*, Quintessence, 2001.

Kim, Syngcuk, *Color atlas of microsurgery in endodontics*, W.B.Saunders, 2001.

Kjaer, Inger, Keeling, Jean W. & Hansen, Birgit Fischer, *The prenatal human cranium: normal and pathological development*, Munksgaard, 1999.

Malamed, Stanley F., *Medical emergencies in the dental office*, 5th ed., Mosby, 2000.

McMahon, R.F.T. & Sloan, P., *Essentials of pathology for dentistry*, Churchill Livingstone, 2000.

Mcnamara, James A., Brudon, William L. & Kokich, Vicent G., *Orthodontics and dentofacial orthopedics*, Needham Press, 2001.

Newman, Michael G. & vanWinkelhoff, Arie J., *Antibiotic and antimicrobial use in dental practice*, 2nd ed., Quintessence, 2001.

New Acquisitions: Subscription

The Journal of Evidence-Based Dentistry, Mosby, 2001.