

# Unusual Maxillary First Molar with 2 Palatal Canals Within a Single Root: A Case Report

• Stephen Johal, DMD •

## A b s t r a c t

*A case report is presented regarding a maxillary first molar with 5 canals. The morphology is atypical because it is characterized by a single palatal root with 2 canals with separate orifices joining in the apical third. A literature review pertaining to the morphology of maxillary first molars is discussed. Modifications to the normal access opening and examination of the pulpal floor for additional canals are stressed.*

**MeSH Key Words:** molar/abnormalities; root canal therapy; tooth root/abnormalities

© J Can Dent Assoc 2001; 67:211-4  
This article has been peer reviewed.

The complexity of the root canal system of maxillary molars presents a constant challenge, as the dentist must have a thorough knowledge of root canal morphology to provide successful endodontic treatment.

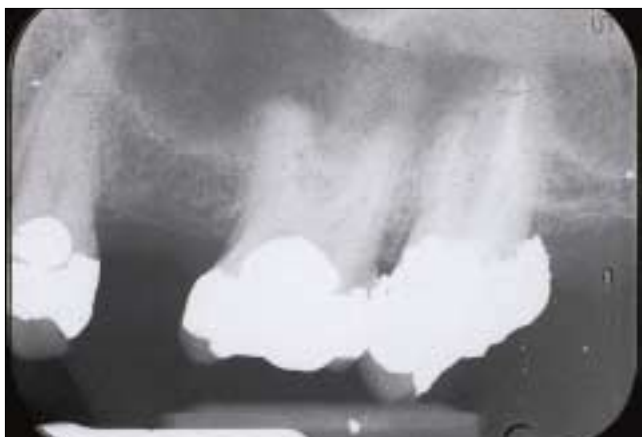The form, configuration, and number of root canals present in maxillary first molars have been discussed for more than half a century.<sup>1-12</sup> Differences between studies may be attributed to variations in the technique used to study the morphology.

- 1925: In a study of 513 maxillary molars, Hess<sup>1</sup> found that 53% had 4 canals.
- 1927: Okumara<sup>2</sup> found that 53% of 299 extracted teeth had 2 canals in the mesiobuccal (MB) root, 2.9% had 2 in the distobuccal (DB) root, and 0.3% had 2 in the palatal root.
- 1969: Weine and others<sup>3</sup> studied 208 extracted first molars, and found that 51.5% had 2 canals in the MB root.
- 1972: Pineda and Kuttler<sup>4</sup> found that, in 262 maxillary first molars, 60.7% had 2 canals in the MB root, 3.6% had 2 in the DB root, and 100% had one canal in the palatal root.
- 1973: Seidberg and others<sup>5</sup> found that 62% of 100 extracted first maxillary molars studied in vitro had 2 canals in the MB root, but only 33% of 201 maxillary

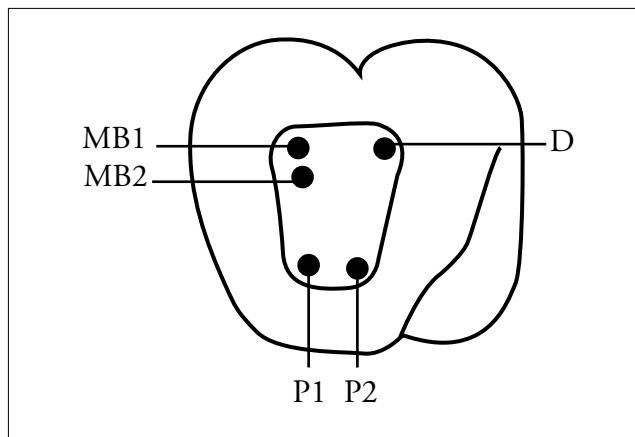
molars treated with endodontic therapy and studied in vivo showed 2 canals.

- 1974: Slowey<sup>6</sup> reported that of 103 endodontically treated molars 50.4% had 2 MB canals and 49.6% had only one.
- 1974: In a study of 100 decalcified maxillary first molars, Vertucci<sup>7</sup> found that a fourth canal occurred in 55%.
- 1974: Pomeranz and Fishelberg<sup>8</sup> examined 100 extracted maxillary first molars and found 69% had 4 canals, with 2 located in the MB root.
- 1978: Acosta Vigouroux and Trugeda Bosaans<sup>9</sup> showed that 72% of the 134 maxillary first molars studied had more than 3 root canals.
- 1983: Gray<sup>10</sup> found a fourth canal in 56% of teeth examined.
- 1993: Thomas and others<sup>11</sup> found that 74% of MB roots showed a double canal system and over 95% of palatal and DB roots contained a single canal.
- 1994: Fogel and others<sup>12</sup> reported a double canal system in the maxillary first molar of 72% of teeth.

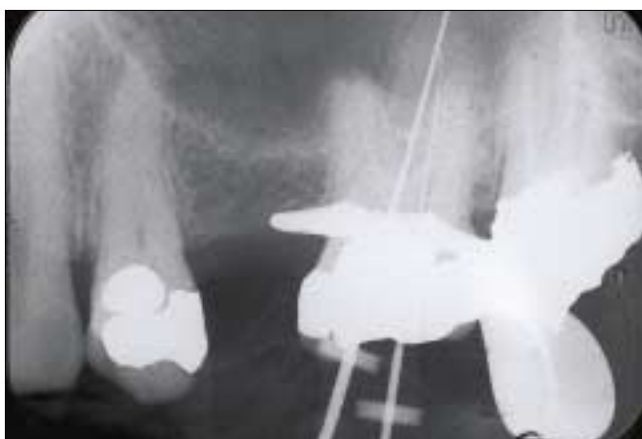What is not generally understood, however, is that there may be more than 4 canals. Acosta Vigouroux and Trugeda Bosaans<sup>9</sup> reported 5 root canals in 2.25% of maxillary first molars. Gray<sup>10</sup> reported 5 canals in 2.4% of the teeth he studied, with the following distribution: 2 MB, 2 DB, and one palatal canal. Beatty<sup>13</sup> reported a case of 5 canals, with 3 in the MB area. Harris<sup>14</sup> documented a case where the



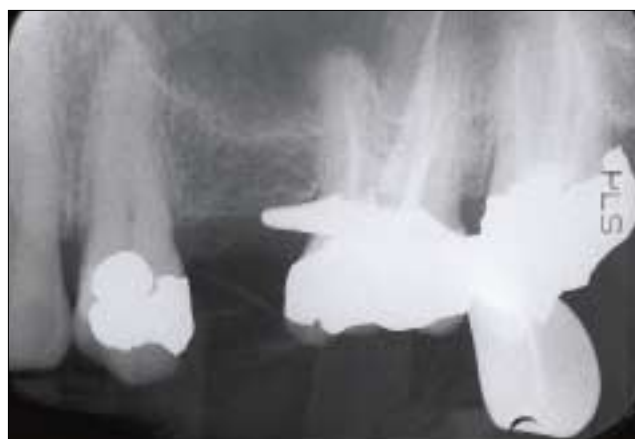**Figure 1:** Preoperative radiograph of left maxillary first molar.



**Figure 2:** Diagrammatic representation of the location of the orifices of the 5 canals in the maxillary left molar.



**Figure 3:** K-type files present in the 2 palatal canals.



**Figure 4:** Immediate post-treatment radiograph displaying the unique palatal morphology.

palatal root of a maxillary first molar had 2 separate root canals. Cecic and others<sup>15</sup> reported a case with 5 canals (2 MB, 1 DB, and 2 palatal), in which the palatal canals bifurcated at midroot into 2 distinct canals. Martinez-Berna and Ruiz-Badanelli<sup>16</sup> described 3 cases of maxillary first molars with 6 canals (3 MB, 2 DB, and 1 palatal). Bond and others<sup>17</sup> also presented a 6-canal first molar (2 MB, 2 DB, and 2 palatal).

This case report describes a permanent maxillary first molar with 5 root canals (2 MB, 1 DB, and 2 palatal), with unusual palatal canal morphology in that 2 canals with separate orifices join in the apical third.

**Case Report**

A 42-year-old male patient presented with signs of irreversible acute pulpitis. He complained of pain, both spontaneous and temperature related, on the left side of the face for several days prior to his appointment. The patient’s medical history was noncontributory. After extensive clinical and radiographic examination, the maxillary left first molar was prepared for nonsurgical endodontic therapy. A preoperative radiograph was obtained (**Fig. 1**). The patient received local anesthesia of 2% lidocaine with 1:100,000

epinephrine. A rubber dam was placed, and a conventional endodontic access opening was made.

In the pulp chamber floor, the 3 principal root canal systems were identified: MB, DB, and palatal. K-type files were used for gross removal of pulp tissue in the 3 main canals. The pulp chamber floor was then explored to find the fourth canal in the MB root. After probing with a Hu-Friedy DG 16 endodontic explorer and scraping calcifications with a spoon excavator, a small hemorrhagic point was noted in a groove approximately 2 mm from the MB orifice in a palatal direction. At the same time a similar hemorrhagic point was noted near the orifice of the main palatal canal. A small amount of dentin that was occluding the orifice of the second palatal canal was removed. The conventional triangular access was modified to a trapezoidal shape to improve access to the additional canals. In both areas there was a “stick” with the endodontic explorer.

Examination of the chamber floor with the explorer revealed 5 canal orifices (**Fig. 2**). The palatal (**Fig. 3**) and mesial root had 2 orifices, fairly well separated, exiting from the floor of the pulp chamber. K-type files were used to clean and shape the canal system. Gates Glidden burs #2 and #3

were used to flare the coronal portion of the canals to improve straight-line access. Frequent irrigation with 5.25% sodium hypochlorite was also carried out. All canals were stepped back in 1-mm increments for 3 file sizes larger than the master apical file. The tooth was dried with paper points, and a cotton pellet was sealed into the pulp chamber with a temporary restorative filling material.

At the next appointment, the root canals were irrigated with 5.25% sodium hypochlorite and dried with paper points. The canals were obturated using zinc oxide-eugenol sealer and laterally condensed gutta-percha. A temporary restoration was placed and a postoperative radiograph was taken (Fig. 4). The immediate post-treatment radiograph shows the unique palatal morphology. The tooth has been asymptomatic thereafter.

### Access Opening and the Pulpal Floor

This case report emphasizes the importance of looking for canals and of ensuring adequate access to improve the likelihood that additional canals will be located. The conservation of tooth structure must be kept in mind when establishing an endodontic access to allow for successful restoration of the tooth after root canal therapy. Endodontic access should be designed to provide direct access to the apical third of the root canal system, not merely to locate the canal orifice. The dentist should be able to visualize all aspects of the coronal third of the root canal system, and all tooth structure or restorative material that interferes with straight-line access should be removed. It is important for the access cavity to have smooth externally diverging walls to improve visibility and prevent debris from migrating into the canal system.

The traditional triangular access opening — the MB, DB, and palatal root representing the apex of each point of the triangle — is often too constricted to allow straight-line access in maxillary molars. Thomas and others<sup>11</sup> showed that 81% of the teeth they studied had a trapezoidal pulp chamber and that the use of a trapezoidal access cavity was warranted. Christie and Thompson<sup>18</sup> have recommended modifying the outline to an ovoid shape, so that the roof of the chamber when opened up is more parallel to the mesial marginal ridge. They believe that this outline provides better access for searching for additional canals, therefore improving endodontic success.

To investigate properly the possibility of additional canals, the dentist should:

- understand the complexity of the morphology of the tooth involved
- take additional off-angle radiographs
- ensure adequate “straight-line” access to improve visibility
- examine the pulpal floor for “lines” to areas where additional canals may be located

- remove a small amount of tooth structure that often may occlude a canal orifice.

The dentist should be suspicious of additional canals if endodontic files are not well centred in the canal on the radiograph or if endodontic files are not well centred in the canal clinically.

It must be assumed that most maxillary first molars will have 4 canals. The second MB canal is usually found 0.5-5 mm palatal to the main MB canal, often hidden under a cervical ledge.<sup>19</sup> Cutting around the first orifice, cutting a trough in a straight line toward the palatal canal, or both, will usually allow the dentist to find it.

### Conclusion

This case report contributes to our understanding of the complexity of the root canal morphology found in maxillary first molars. Although such cases occur infrequently, dentists should be aware of them when considering endodontic treatment of a maxillary first molar. ♦

---

*Dr. Jobal is in full-time private practice in Surrey, B.C., and is a part-time clinical pediatric instructor at the University of British Columbia.*

*Correspondence to: Dr. Stephen Jobal, 6642 123A St., Surrey BC V3W 0Z1. E-mail: njobal@sprint.ca.*

*The author has no declared financial interest.*

---

### References

1. Hess W. The anatomy of the root canals of the teeth of the permanent dentition. London: John Bale Sons and Danielsen, 1925.
2. Okumara T. Anatomy of the root canals. *J Am Dent Assoc* 1927; 632-6.
3. Weine FS, Healey HJ, Gerstein H, Evanson L. Canal configuration in the mesiobuccal root of the maxillary first molar and its endodontic significance. *Oral Surg Oral Med Oral Pathol* 1969; 28(3):419-25
4. Pineda F, Kuttler Y. Mesiodistal and buccolingual roentgenographic investigation of 7,275 root canals. *Oral Surg Oral Med Oral Pathol* 1972; 33(1):101-10.
5. Seidberg BH, Altman M, Guttuso J, Suson M. Frequency of two mesiobuccal root canals in maxillary permanent first molars. *J Am Dent Assoc* 1973; 87(4):852-6.
6. Slowley RR. Radiographic aids in the detection of extra root canals. *Oral Surg Oral Med Oral Pathol* 1974; 37(5):762-72.
7. Vertucci FJ. The endodontic significance of the mesiobuccal root of the maxillary first molar. *US Navy Med* 1974; 63(5):29-31.
8. Pomeranz HH, Fishelberg G. The second mesiobuccal canal of maxillary molars. *J Am Dent Assoc* 1974; 88(1):119-24.
9. Acosta Vigouroux SA, Trugeda Bosaans SA. Anatomy of the pulp chamber floor of the permanent maxillary first molars. *J Endod* 1978; 4(7):214-9.
10. Gray R. The maxillary first molar. In: Bjorndal A, Skidmore E, editors. Anatomy and morphology of the human teeth. Iowa City: University of Iowa College of Dentistry; 1983. p. 31-40.
11. Thomas RP, Moule AJ, Bryant R. Root canal morphology of maxillary permanent first molar teeth at various ages. *Int J Endod* 1993; 26(5):257-67.
12. Fogel HM, Peikoff MD, Christie WH. Canal configuration in the mesiobuccal root of the maxillary first molar: a clinical study. *J Endod* 1994; 20(3):135-7.
13. Beatty RG. A five-canal maxillary first molar. *J Endod* 1984; 10(4):156-7.

14. Harris WE. Unusual root canal anatomy in a maxillary molar. *J Endod* 1980; 6(5):573-5.
15. Cecic P, Hartwell G, Bellizzi R. The multiple root canal system in the maxillary first molar: a case report. *J Endod* 1982; 8(3):113-5.
16. Martinez-Berna A, Ruiz-Badanelli P. Maxillary first molars with six canals. *J Endod* 1983; 9(9):375-81.
17. Bond JL, Hartwell G, Portell FR. Maxillary first molar with six canals. *J Endod* 1988; 14(5):258-60.
18. Christie WH, Thompson GK. The importance of endodontic access in locating maxillary and mandibular molar canals. *J Can Dent Assoc* 1994; 60(6):527-32, 535-6.
19. Lovdahl PE, Gutmann JL, Dumsha TC, Hovland EJ. CH 4: Problems in locating and negotiating fine and calcified canals. Problem solving in endodontics. 2nd ed. St. Louis (MO): Mosby; 1992. p. 50-69.