

Pathologic Fracture of the Mandible Caused by Metastatic Follicular Thyroid Carcinoma

Mohammed AlGahtani, MD; Mansour Alqudah, BDS, MSc, FDSRCS;
Saad AlShehri, MD, FRCSC, FACS; Abdulaziz Binahmed, BDS, MDent, FRCD(C), MSc;
George K.B. Sándor, MD, DDS, PhD, FRCD(C), FRCSC, FACS

Auteur-ressource

Dr Sándor
 Courriel : george.sandor@utoronto.ca



SOMMAIRE

Les fractures pathologiques peuvent être une manifestation aiguë ou un problème chronique mal défini, et leurs causes sont nombreuses. Le dentiste peut être le premier professionnel de la santé à examiner un patient qui présente une fracture pathologique de la mâchoire. Cette étude de cas vise à informer les dentistes sur les fractures pathologiques et sur l'importance de diriger rapidement le patient vers les ressources compétentes pour réduire au minimum ses souffrances.

Pour les citations, la version définitive de cet article est la version électronique : www.cda-adc.ca/jcda/vol-75/issue-6/457.html

A pathologic fracture may occur when a bone has been weakened by an underlying pathologic process, even when it is subjected to otherwise normally tolerated loading forces.¹ Although such fractures may occur in any bone, their most common location in the orofacial skeleton is the mandible.¹

Weakening of the jaw may be congenital (e.g., hypodevelopment) or acquired (e.g., extreme alveolar atrophy accompanying long-standing edentulism²) (**Box 1**). Pathologic fractures may result from severely impacted or ectopic teeth and may also be associated with their removal.³ They may also follow placement of a dental implant in atrophic jaws. Osteoradionecrosis of the jaws,⁴ osteomyelitis⁴ and more recently bisphosphonate-related osteonecrosis of the jaws^{5,6} have been observed to cause pathologic fractures. Destructive neoplasms, both benign and malignant, may also lead to pathologic fractures as might metastatic tumours of the jaws.⁷⁻¹⁰

The purpose of this case report is to describe the presentation of a pathologic fracture of the

mandible and review the features and management of pathologic fractures that dentists may encounter.

Case Report

A 66-year-old woman presented to her dentist with a 4-month history of swelling in her left cheek. The patient had noticed a clicking in her left mandible when she moved her jaw and a deviation of the chin to the right side. She also reported numbness of the lower lip and difficulty chewing.

Clinical examination revealed a hard, tender, fixed swelling of the left mandible extending from the ramus to the submandibular area and completely obliterating the mandibular anatomy. Intraoral examination showed significant expansion of the left mandible in the buccolingual direction and unusual mobility of the mandible when pressure was applied to the ramus. A palpable left thyroid nodule was present, but no lymphadenopathy was found.

Radiologic investigation included an orthopantomogram, which showed a destructive

Box 1 Causes of pathologic fractures of the mandible

Congenital

Hypodevelopment of portions of the jaws or entire jaws
Osteogenesis imperfecta

Acquired

Osteoporosis
Extreme maxillary and mandibular atrophy
Long-standing edentulism
Presence or removal of severely impacted or ectopic teeth
Placement of dental implant in severely atrophic jaws
Osteoradionecrosis of the jaws
Osteomyelitis
Bisphosphonate-related osteonecrosis of the jaws

Destructive lesions

Large cystic lesions
Benign tumours
Malignant tumours
Metastatic tumours

radiolucent lesion on the mandible (**Fig. 1**) extending from the left first premolar anteriorly to the ramus and a pathologic fracture of the mandible.

An incisional biopsy was performed under local anesthesia. Tissue from the left mandible contained thyroid follicles lined with cuboidal cells with round to oval nuclei and moderate amounts of cytoplasm. Most of the follicles contained intraluminal colloid, which was thyroglobulin (DAK-Tg6) positive.

A metastatic work-up included computed tomography of the head and neck, which showed a large destructive lesion in the left mandible associated with a large soft tissue mass measuring $4.6 \times 4.2 \times 4$ cm. Injection of contrast dye greatly enhanced the image and indicated a hypervascular lesion. Multiple small lymph nodes were present in the neck. A large heterogeneous mass (3.4×4.7 cm) involving the left lobe of the thyroid gland had caused displacement of the trachea.

The case was reviewed by the head and neck tumour board, which recommended total thyroidectomy, lateral neck dissection and resection of the mandibular lesion. This treatment was carried out (**Fig. 2**). A segmental mandibulectomy was performed and a 2.7-mm reconstruction plate was used to span the gap after resection and provide the rigidity needed to allow the patient mandibular mobility and function without pain (**Fig. 3**).

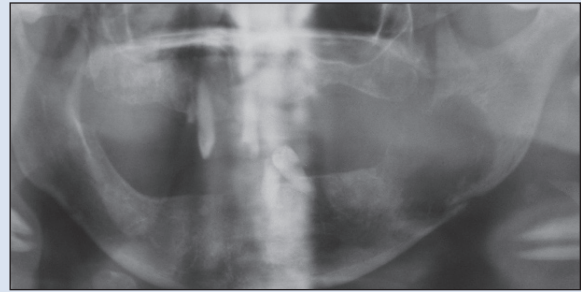


Figure 1: Preoperative orthopantomogram showing large lytic lesion of the left mandibular body and ramus with pathologic fracture through the inferior border. Note overlapping of the edges of the inferior border of the mandible.

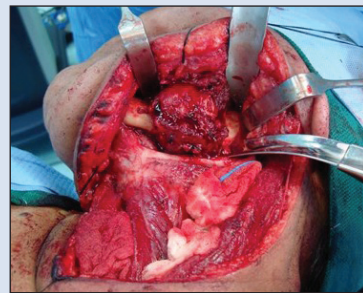


Figure 2: Intraoperative photograph of large metastatic tumour of left mandible at the time of resection.

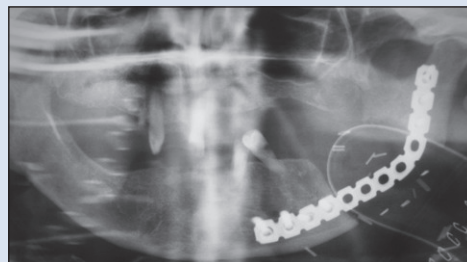


Figure 3: Postoperative orthopantomogram following resection of the left mandibular tumour. A reconstruction plate has been applied to restore jaw rigidity necessary for pain-free movement and mastication.

Discussion

Pathologic fractures of the jaw may lead to severe pain and suffering, inability to eat and difficulty in swallowing. Symptomatic pathologic fractures require active treatment to re-establish the rigidity of the jaw and permit pain-free movement and mastication. Patients with suspected pathologic fractures of the jaw should be examined clinically and radiographically, then referred for prompt evaluation by specialists, such as oral and maxillofacial surgeons. Some pathologic fractures occur in patients with underlying malignancy. The treatment of such fractures may be

essential to maintain the patient's quality of life, as in the case presented above.

Follicular carcinoma of the thyroid accounts for 17% of all thyroid malignancies. It is most common in women between the ages of 22 and 50 years.⁷ The presenting symptom is a long-lasting neck lump that may be noted by the dental practitioner during head and neck examination. Follicular thyroid carcinoma metastasizes through the hematologic route to the lungs, bone, liver and brain.^{7,10,11} Lymphatic spread occurs rarely.⁸ In this case, a metastatic follicular carcinoma of the thyroid was an unusual cause of a pathologic fracture of the mandible.

The true incidence of metastatic tumours in the bones of the jaw is unknown,⁸ as jaws are not always included in radiographic skeletal surveys for metastasis and they may not be examined during autopsies.⁹

Involvement of the jaw in metastasis appears to be less common than that of other bones, as the amount of red bone marrow and blood vessels in the jaw bones tends to decrease with age.⁸ This is due to the gradual replacement of red marrow with yellow or fatty marrow. Most (60%–80%) metastasis involving jaw bones occurs in the mandible, mainly in the molar and premolar areas, when compared to other bones of the facial skeleton.⁸ This is thought to be due to the greater presence of hematopoietic tissue in the mandible. Because the mode of metastasis is hematogenous, the neoplastic cells become deposited in areas where there is vascular tissue.⁹

Metastatic tumours are most common in the fifth to seventh decades of life.⁸ The most common origins of metastasis vary with gender: breast, ovary and thyroid in female patients and lung, prostate, kidney and liver in men.¹¹ The lung is the most common origin of metastasis into oral soft tissues, whereas the breast is the most common origin of metastatic tumours in the jaw bones.¹²

Metastatic tumours in the jaw present with pain, swelling, mobility of teeth, delay in healing of extraction sockets, pathologic fractures or paresthesia.^{13,14} Radiographically, metastatic lesions are most often ill-defined and are usually osteolytic or radiolucent, although they may be osteoblastic, radiopaque mixed lesions.^{11,12}

The lack of large numbers of patients with mandibular metastasis prevents accurate determination of the prognosis associated with the treatment described above. Some evidence indicates that resection of solitary bony metastasis, along with total thyroidectomy, may increase survival among those with follicular thyroid carcinoma.¹⁵ Treatment of the pathologic fracture in the case described in this report rendered the patient symptom-free and restored her quality of life to the prefracture level. Dental practitioners may take the first essential step in initiating such treatments by promptly referring patients with suspected pathologic fractures. ♦

THE AUTHORS



Dr. Al Gahtani is a resident in plastic surgery, King Abdulaziz Medical Centre, Riyadh, Saudi Arabia.



Dr. Alqudah is an oral and maxillofacial surgeon, King Abdulaziz Medical Centre, Riyadh, Saudi Arabia.



Dr. Al Shehri is a general, oncology and endocrine surgeon, King Abdulaziz Medical Centre, Riyadh, Saudi Arabia.



Dr. Binhamed is fellow, pediatric oral and maxillofacial surgery, The Hospital for Sick Children and University of Toronto, Toronto, Ontario, and oral and maxillofacial surgeon, King Abdulaziz Medical Centre, Riyadh, Saudi Arabia.



Dr. Sándor is professor and head of oral and maxillofacial surgery, University of Toronto, coordinator of pediatric oral and maxillofacial surgery, The Hospital for Sick Children and Bloorview Kids Rehab, Toronto, Ontario; professor, Regea Institute for Regenerative Medicine, University of Tampere, Tampere, Finland, and docent, University of Oulu, Oulu, Finland.

Correspondence to: Professor George K.B. Sándor, The Hospital for Sick Children, S-525, 555 University Ave., Toronto ON M5G 1X8.

The authors have no declared financial interests.

This article has been peer reviewed

References

- Coletti D, Ord RA. Treatment rationale for pathologic fractures of the mandible: a series of 44 fractures. *Int J Oral Maxillofac Surg.* 2008;37(3):215-22. Epub 2007 Nov 26.
- Kainulainen VT, Lindholm TC, Sándor GK. Reconstruction of an extremely resorbed mandible by the "tent pole" procedure. *Suomen Hammaslääkärilehti* [Finnish Dental Journal]. 2003;12(12):591-7.
- Meisami T, Sojat A, Sándor GK, Lawrence H, Clokie CM. Impacted third molars and risks of angle fracture. *Int J Oral Maxillofac Surg.* 2002;31(2):140-4.
- Brown DA, Evans AW, Sándor GK. Hyperbaric oxygen therapy in the management of osteoradionecrosis of the mandible. *Adv Otorhinolaryngol.* 1998;54(2):14-32.
- Lam DK, Sándor GK, Holmes HI, Evans AW, Clokie CM. A review of bisphosphonate-associated osteonecrosis of the jaws and its management. *J Can Dent Assoc.* 2007;73(5):417-22.
- Khan AA, Sándor GK, Dore E, Morrison AD, Alsahlhi M, Amin F, and others. Canadian consensus practice guidelines for bisphosphonate associated osteonecrosis of the jaw. *J Rheumatol.* 2008;35(7):1391-7. Epub 2008 Jun 1. Erratum in: *J Rheumatol.* 2008;35(8):1688. Erratum in: *J Rheumatol.* 2008;35(10):2084.
- Saunders CM, Baum M. The thyroid gland and the thyroglossal tract. In: Russell RC, Williams NS, Bulstrode CJ, editors. *Bailey and Love's short practice of surgery.* 24th ed. London: Arnold Publishers; 2004. p. 797-801.
- Hirshberg A, Leibovich P, Buchner A. Metastatic tumors to the jaw bones: analysis of 390 cases. *J Oral Pathol Med.* 1994;23(8):337-41.
- Zachariades N, Koumoura F, Vairaktaris E, Mezitis M. Metastatic tumors to the jaws: a report of seven cases. *J Oral Maxillofac Surg.* 1989;47(9):991-6.

10. Draper BW, Precious DS, Priddy RW, Byrd DL. Clinicopathological conference. Case 29, part 2. Follicular thyroid carcinoma metastatic to the mandible. *J Oral Surg.* 1979;37(10):736-9.
11. Anil S, Lal PM, Gill DS, Beena VT. Metastasis of thyroid carcinoma to the mandible. Case report. *Aust Dent J.* 1999;44(1):56-7.
12. D'Silva NJ, Summerlin DJ, Cordell KG, Abdelsayed RA, Tomich CE, Hanks CT, and others. Metastatic tumors in the jaws: a retrospective study of 114 cases. *J Am Dent Assoc.* 2006;137(12):1667-72.
13. Bodner L, Sion-Vardy N, Geffen DB, Nash M. Metastatic tumor to the jaws: a report of eight new cases. *Med Oral Pathol Oral Cir Bucal.* 2006;11(2):E132-5.
14. Kaveri H, Punnya VA, Tayaar Amsavardani S. Metastatic thyroid carcinoma to the mandible. *J Oral Maxillofacial Pathol.* 2007;11(1):32-4.
15. Ostrosky A, Mareso EA, Klurfan FJ, Gonzalez MJ. Mandibular metastasis of follicular thyroid carcinoma. Case report. *Med Oral.* 2003;8(3):224-7.
16. Vural E, Hanna E. Metastatic follicular thyroid carcinoma to the mandible: a case report and review of the literature. *Am J Otolaryngol.* 1998;19(3):198-202.