

Some Current Legal Issues that May Affect Oral and Maxillofacial Radiology. Part 2: Digital Monitors and Cone-Beam Computed Tomography

David S. MacDonald-Jankowski, BDS, BSc (Hons), LLB (Hons), MSc, FDSRCPS, DRRRCR;
Elaine C. Orpe, DMD, BSc, MSc, Dip Oral Maxillofac Radiol

Auteur-ressource

Dr MacDonald-Jankowski
Courriel : dmacdon@interchange.ubc.ca



SOMMAIRE

Dans ce deuxième d'une série de 2 articles sur les progrès technologiques en radiologie dentaire, nous examinons les répercussions juridiques de l'utilisation des moniteurs numériques et de la tomодensitométrie à faisceau conique sur l'exercice de la dentisterie. Bien que certaines technologies nouvelles, comme les dispositifs à transfert de charge et les phosphores photostimulables, soient couramment utilisées en dentisterie, d'autres (p. ex., les moniteurs en niveaux de gris) sont mieux connues en médecine où elles constituent la norme de diligence en matière de diagnostic primaire. Cette question complexe a été examinée. Ainsi, l'introduction récente de la tomодensitométrie à faisceau conique a soulevé un certain nombre de dilemmes sur le plan juridique, notamment quant à la responsabilité inhérente à la lecture et à l'interprétation, durant la planification préalable à la pose d'implant, des images produites par cette nouvelle technologie qui, par sa technique d'imagerie différente, offre de larges champs de vision qui incluent les zones extragnathiques, lesquelles ne sont habituellement pas du ressort du dentiste.

Pour les citations, la version définitive de cet article est la version électronique : www.cda-adc.ca/jcda/vol-73/issue-6/507.html

Careful reading of diagnostic radiographs and other images to prevent misdiagnosis is the responsibility of all dental professionals.¹ They must optimize their viewing conditions, regardless of whether they use film, the gold standard for image quality, particularly for spatial resolution,² with a standard illuminated viewer under reduced ambient lighting, or a digital monitor. Making the transition to digital technology requires similar viewing conditions. To ensure that digital radiographs viewed on a monitor are of diagnostic quality, monitor specifications must be compatible with the optimal display of the image captured by the detector.³

According to McCarthy and Brennan,⁴ the viewing conditions for film established by the World Health Organization are a light-box luminance of 1500–3000 cd/m² (cd/m² is the measure of the luminous intensity of a point source also known as meter-lamberts, lumens or nits) and ambient lighting at 100 or less lux (lx, which is a measure of how many rays fall on a 1-m² card).

In the first of 2 papers about technological developments in dental radiology, we discussed the legal impact of the basic developments in digital dental radiology.⁵ In this second paper, we discuss the legal impact of using digital monitors and cone-beam computed tomography (CBCT) on dental practice.

Digital Monitors

Monitors used by medical radiologists for making primary diagnoses from conventional digital radiographic images are usually greyscale (monochromatic), have a high resolution and very high brightness, and are largely self-calibrating to digital imaging and communications in medicine (DICOM) standards. These medical-grade, diagnostic or primary-read monitors are technologically complex. For example, the greyscale standard-display function is based on a phenomenon called human-contrast sensitivity, which takes the human eye's nonlinear perception into account; the human eye easily sees relatively small changes in brighter areas than in darker areas. The greyscale standard-display function adjusts the brightness so that all areas have the same level of perceptibility.⁶

The standard of care for the use of diagnostic monitors has long been set by medicine. Krupinski and others⁷ found that searches done with the higher luminance of mammographic displays (which are closer in spatial resolution to those of dentistry) are more efficient. The total viewing and decision-dwell times were shorter with higher-luminance displays. Luminance, measured in cd/m^2 , is synonymous with brightness; illuminance, measured in lx, describes the amount of ambient lighting.⁸

Because each practising dentist is his or her own radiologist, he or she should use the same luminance levels as medical radiologists. The monitors used by other medical doctors need not be of this quality because these monitors are used for therapeutic purposes and need only be adequate for reminding them of the results of their radiologists' reports. Further, it is very unlikely that many monitors currently found in Canadian dental offices display a full panoramic image at the recommended 1-to-1 pixel (detector image to displayed image) ratio. Therefore, information contained within the detector image may not be displayed on the monitor. Haak and others⁹ reported that ratios of 1:1 and 2:1 were significantly better for detection of proximal caries than a ratio of 7:1. (If the monitor has the capacity to display only 1:1 in the normal mode, this ratio would be exceeded in the high-resolution mode.) In their comparison of a standard desktop with a dedicated medical monitor, Gutierrez and others¹⁰ found that the standard desktop display was clearly inadequate for diagnostic radiology.

Importance of the Monitor's Brightness and Reduced Ambient Lighting

Since the monitor is the digital equivalent of the viewing box, the monitor's brightness is a crucial factor in primary diagnosis and works with reduced ambient lighting.¹¹ Together, these permit optimal visualization of low-contrast high spatial resolution lesions such as caries. The visualization of caries is markedly reduced when viewed on a monitor in bright ambient lighting. Research on digital chest radiography¹² presents clear and unequivocal evidence that bright ambient light significantly decreases detection

of small low-contrast resolution structures. Further, Nair and others¹³ reported that better signal detection and performance, comparable with those of film, resulted from digital images with enhanced contrast and brightness. The brightness of even high-end commercial monitors reaches just above $200 \text{ cd}/\text{m}^2$, in contrast to that of a similar-sized medical greyscale monitor, which can reach up to $900 \text{ cd}/\text{m}^2$. Although the American College of Radiologists' recommended luminance of 50 foot-lamberts converts to $171.3 \text{ cd}/\text{m}^2$,¹⁴ most digital medical images (not all of those for computed tomography [CT] or magnetic resonance imaging) are viewed on greyscale monitors that luminate to $500 \text{ cd}/\text{m}^2$ or more, as is obvious from Wade and Brennan's recent report.¹⁵ Recommendations for reduced ambient lighting in diagnostic reading stations for conventional analogue (and digital) radiographs are 2–10 lx, in comparison with 200–250 lx in clinical viewing stations in hospitals.¹⁶

The evidence for the need for reduced ambient lighting for dentistry is provided by Haak and others.¹⁷ They found that differences in monochromatic intensity were detected significantly earlier if the ambient lighting was reduced (70 lx versus the 1000 lx recommended for the dental operator). Although both monitors used did not reach the National Electrical Manufacturers Association's standards for DICOM, they found that the flat screen monitor performed better than the cathode ray tube (CRT) in the dental operator, probably because the flat screen was brighter.

In addition to generating an audit trail that records the author (clinician), time and date of the image and the monitor workstation used to identify the original image (which must be preserved), the monitor workstation used for any subsequent modification of the image must also be identified if the workstation is part of a networked system.³

Comparison of Liquid Crystal Displays and Cathode Ray Tubes

Both liquid crystal displays (LCDs) and CRTs yield comparable images for the detection of simulated chest lesions. Oschatz and others¹⁸ compared greyscale models of each that complied with DICOM standards (Barten model) and were set at $300 \text{ cd}/\text{m}^2$. Hwang and others¹⁹ reported that LCD and CRT detected small solitary pulmonary nodules equally well.

Although comparable CRTs are cheaper, they take up more space because of their depth. Therefore, where space is a premium, LCDs are more practical. Unlike CRTs, LCD monitors do not flicker. Their response time is slow, a rate appropriate to the sensitivity of the human eye.²⁰

The Need for Self-Calibration

The luminance of a monitor decreases over time until luminance falls below a level that is adequate for diagnosis. Therefore, screen calibration must be part of a quality assurance system to ensure that the unit is operating at an appropriate level of luminance. A recent Canadian report²¹

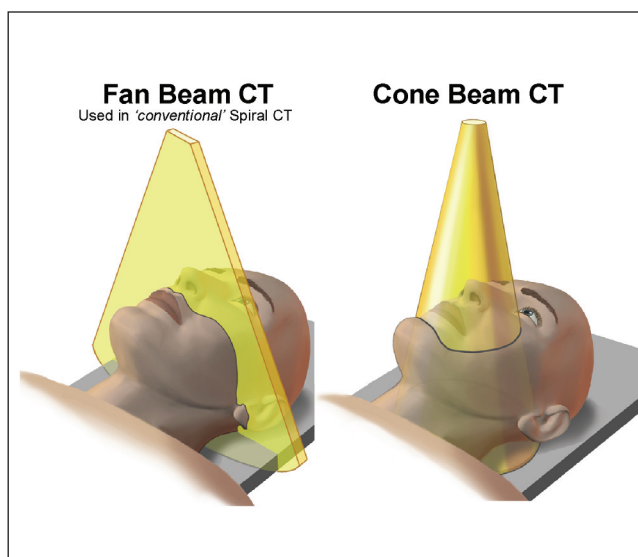


Figure 1: The fan beam on which spiral computed tomography (left) is based interrogates only a slice of tissue, whereas the cone-beam of cone-beam computed tomography (right) interrogates a 3-dimensional region within a 360° rotation. (Reproduced with permission from MacDonald-Jankowski and Orpe.²²)

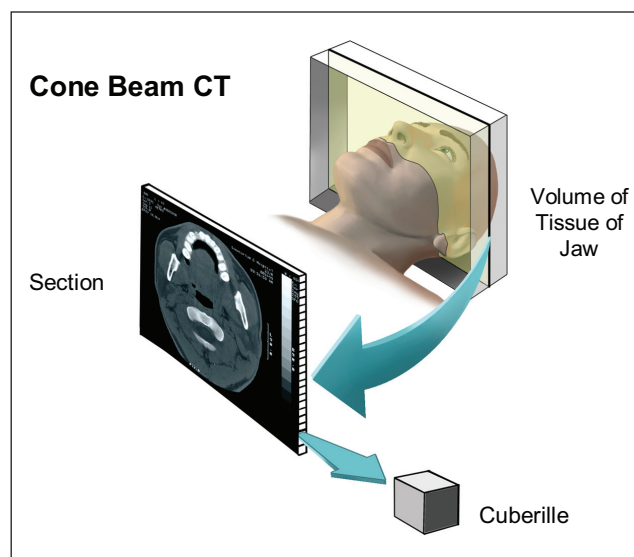


Figure 2: Cone-beam computed tomography reconstructs the 3-dimensional images by generating cuberilles directly, each with its own attenuation coefficient. This allows 3-dimensional reconstructions with better resolution in the Z plane and in the axial (XY) plane. Spiral computed tomography, except the most modern 64-multislice units, can produce cuberilles only secondarily from voxels. (Reproduced with permission from MacDonald-Jankowski and Orpe.²²)

from Toronto found that image quality assurance, which was traditionally high for analogue systems, has been neglected during the transition from film (hard copy) to monitor (soft copy) display. This neglect could lead to misdiagnosis. The report's authors found that 70% of monitors before calibration could not discern a difference between 0% and 5% luminance on an SMPTE (Society of Motion Picture and Television Engineers) pattern (Wade and Brennan reported that the spatial resolution patterns of the SMPTE pattern were inadequate¹⁵; they recommended the TG-18 pattern proposed by the American Association of Physicists in Medicine.^{8,16}). Further, 4 of the 27 monitors tested were inadequate for diagnostic work, even after calibration, because their maximal luminance was grossly inadequate.

Although a self-calibrated monitor would ensure that the system functions within clinical diagnostic limits, other image-quality-degrading factors can affect the optimal quality of the image, such as an LCD's dropped-out pixels, phosphor burn-in from a static image (usually an institutional logo on the CRT's desktop wallpaper) and dirty screens.

CBCT

Although CBCT has emerged only recently, it has completely transformed advanced imaging of the face and jaw. CBCT produces images with greater spatial resolution and a lower radiation dose than spiral CT; although 1 CBCT unit may impart the same radiation dose as spiral CT. This new technology uses a cone-beam rather than the fan used

in spiral CT (**Fig. 1**). In addition, the cuberilles of CBCT are formed directly from the primary data, each with its own attenuation coefficient (**Fig. 2**). In their recent introduction to CBCT, MacDonald-Jankowski and Orpe²² discuss its attributes, potential uses and limitations, and compare it with spiral CT.

Contrast Resolution

The main disadvantage of CBCT is that its dynamic range, although increased from 8-bit to 14-bit depth, is insufficient for displaying contrast within soft tissue; spiral CT, which does display such contrast, ranges from 16-bit in the economy range to 24-bit at the top-end of the range. Generally, the narrow dynamic range of CBCT is not a problem because most patients are investigated for preimplant planning, which is primarily concerned with bone quality and quantity, well within the range of an 8-bit depth. For this purpose, the medium- or high-resolution 0.2-mm voxel size generally available in North America is also adequate for this purpose.

Field of View

Most modern CBCT units offer a choice of fields of view (FOVs). A small FOV used with a high resolution reduces the dose of radiation to the patient by reducing the area irradiated to that of primary clinical interest.

Generally, the dentist reviews areas of primary clinical interest, but failure to consider the whole image has resulted in missed neoplasms and missed atherosclerosis manifested

by calcified carotid arteries. Earlier diagnosis can reduce not only mortality, but also the health care burden. Since the cost of treating end-stage disease in the hospital is 5 times that for treating non-end-stage disease in the community, earlier diagnosis and care can represent substantial savings.²²

In dentistry, imaging taken for other purposes with clear clinical indications such as panoramic radiographs²⁴ and CBCT²⁵ can be reviewed to detect otherwise undetected disease. Failure to identify, report on and appropriately manage significant disease has resulted in legal action against at least 1 medical doctor in Canada. This clinician did not diagnose a lump in the neck that, when definitively diagnosed as a rare sarcoma, was a substantial size.²⁶

Although the advent of CBCT offers exquisite images of the cervical vertebrae and the base of the skull and orbit, dentists have virtually no training in the identification and interpretation of these images. This is a crucial point because, by law, dentists are expected to report and take appropriate action on their findings.

The most effective way for dentists to minimize their liability is to use the smallest FOV possible. This in turn reduces the radiation dose to the patient and allows the dentist to use a higher spatial resolution, if necessary. Regardless of technology, the established standard of care is to use the FOV that adequately encompasses the area of interest. A recent case²⁷ of a missed diagnosis (CanLII records only 6 cases for medicine in total) was the dental case *Holsten v. Card*. The plaintiff's main claim was that the general practice dentist had based his presurgical examination of a lower third molar solely on a bitewing, subsequently causing damage to her inferior alveolar nerve. Although the trial judge dismissed the plaintiff's claim, his Reasons for Judgment ran to an exceptionally 51 pages long. In essence, the defendant succeeded because the third molar was fully, if just barely, displayed on the bitewing.

Conclusions

Although the introduction of digital technology in oral and maxillofacial radiology is relatively recent compared to its longer history in medicine, its impact and development in this area are both far-reaching and sudden. The attention of dentists has been focused largely on the increasingly diverse array of sensors, to the detriment of the displayed diagnostic image. The widespread use of greyscale medical-grade monitors for radiological diagnosis in medicine reflects the demands of diagnostic radiologists for a high-standard reading environment comparable to that for reading films. Although little clinically based research yet supports the current high-resolution, larger-bit-depth LCD technology in dentistry, influential professional bodies such as the American College of Radiologists and the American Association of Physicists in Medicine fully endorse this technology. It is particularly telling that mammography,

the last hold-out in medical radiology against going digital, has now accepted that the technology has developed sufficiently to meet its demanding standards. It is precisely this quality of technology that we require for our diagnostically demanding high spacial resolution, low-contrast resolution environment in oral and maxillofacial radiology. ✦

THE AUTHORS

Acknowledgements: We are grateful to Neville Lobo, managing editor at *Scientific Communications International Limited*, for permission to reproduce Figures 1 and 2.



Dr. MacDonald-Jankowski is associate professor and chair of the division of oral and maxillofacial radiology, department of oral and biological sciences, faculty of dentistry, University of British Columbia, Vancouver, British Columbia.



Dr. Orpe is clinical assistant professor, division of oral and maxillofacial radiology, department of oral and biological sciences, faculty of dentistry, University of British Columbia, Vancouver, British Columbia.

Correspondence to: Dr. MacDonald, Department of Oral and Biological Sciences, Faculty of Dentistry, University of British Columbia, 2199 Wesbrook Mall, Vancouver, BC V6T 1Z3.

The authors have no declared financial interests.

This article has been peer reviewed.

References

- Currie R. Dental negligence and malpractice. In: Downie J, McEwen K, MacInnes W, editors. *Dental law in Canada*. Markham (ON): Butterworths Nexislexis Canada Inc.; 2004. p. 189–218.
- Kantor ML. Dental digital radiography: more than a fad, less than a revolution. *J Am Dent Assoc* 2005; 136(10):1358, 1360, 1362. [Erratum in *J Am Dent Assoc* 2005; 136(12):1652.]
- Fefergrad I. Recordkeeping in dentistry. In: Downie J, McEwen K, MacInnes W, editors. *Dental law in Canada*. Markham (ON): Butterworths Nexislexis Canada Inc.; 2004. p. 271–8.
- McCarthy E, Brennan PC. Viewing conditions for diagnostic images in three major Dublin hospitals: a comparison with WHO and CEC recommendations. *Br J Radiol* 2003; 76(902):94–7.
- MacDonald-Jankowski DS, Orpe EC. Some current legal issues that may affect oral and maxillofacial radiology: Part 1. Basic principles in digital dental radiology. *J Can Dent Assoc* 2007; 73(5):409–14.
- National Electrical Manufacturers Association (NEMA). Digital imaging and communications in medicine (DICOM). Part 145: Grayscale Standard Function. 2006. Available from URL: <http://www.nema.org/stds/complimentary-docs/upload/PS3.14.pdf>.
- Krupinski E, Roehrig H, Furukawa T. Influence of film and monitor display luminance on observer performance and visual search. *Acad Radiol* 1999; 6(7):411–8.
- Samei E, Badano A, Chakraborty D, Compton K, Cornelius C, Corrigan K, and others. Assessment of display performance for medical imaging systems. Report of the American Association of Physicists in Medicine (AAPM) Task Group 18, Medical Physics Publishing, Madison, WI, AAPM On-Line Report No. 03, April 2005.
- Haak R, Wicht MJ, Nowak G, Hellmich M. Influence of displayed image size on radiographic detection of approximal caries. *Dentomaxillofac Radiol* 2003; 32(4):242–6.
- Gutierrez D, Monnin P, Valley JF, Verdun FR. A strategy to qualify the performance of radiographic monitors. *Radiat Prot Dosimetry* 2005; 114(1-3):192–7.
- Goo JM, Choi JY, Im JG, Lee HJ, Chung MJ, Han D, and others. Effect of monitor luminance and ambient light on observer performance in soft-copy reading of digital chest radiographs. *Radiology* 2004; 232(3):762–6.
- Uffmann M, Prokop M, Kupper W, Mang T, Fiedler V, Schaefer-Prokop C. Soft-copy reading of digital chest radiographs: effect of ambient light

- and automatic optimization of monitor luminance. *Invest Radiol* 2005; 40(3):180–5.
13. Nair MK, Ludlow JB, May KN, Nair UP, Johnson MP, Close JM. Diagnostic accuracy of intraoral film and direct digital images for detection of simulated recurrent decay. *Oper Dent* 2001; 26(3):223–30.
14. American College of Radiology. ACR standard for teleradiology. General Diagnostic Radiology. Teleradiology 1994 (Res 21) Revised 2002 (res. 11) Effective 1/1/03. p. 13–21. Available from URL: <http://www.siiimweb.org/assets/E86FFB0D-7F00-4412-8739-D5F882D18A02.pdf>.
15. Wade C, Brennan PC. Assessment of monitor conditions for the display of radiological diagnostic images and ambient lighting. *Br J Radiol* 2004; 77(918):465–71.
16. Samei E, Badano A, Chakraborty D, Compton K, Cornelius C, Corrigan K, and others. Assessment of display performance for medical imaging systems: executive summary of AAPM TG18 report. *Med Phys* 2005; 32(4):1205–25.
17. Haak R, Wicht MJ, Hellmich M, Nowak G, Noack MJ. Influence of room lighting on grey-scale perception with a CRT and a TFT monitor display. *Dentomaxillofac Radiol* 2002; 31(3):193–7.
18. Oschatz E, Prokop M, Scharitzer M, Weber M, Balassy C, Schaefer-Prokop C. Comparison of liquid crystal versus cathode ray tube display for the detection of simulated chest lesions. *Eur Radiol* 2005; 15(7):1472–6.
19. Hwang SA, Seo JB, Choi BK, Do KH, Ko SM, Lee SH, and others. Liquid-crystal display monitors and cathode-ray tube monitors: a comparison of observer performance in the detection of small solitary pulmonary nodules. *Korean J Radiol* 2003; 4(3):153–6.
20. Partan G, Mayrhofer R, Mosser H, Mahdi T, Hruby W. Radiation dose of digital vs conventional fluororadiography of the upper GI tract. *Eur Radiol* 2001; 11(10):2109–11.
21. Seto E, Ursani A, Cafazzo JA, Rossos PG, Easty AC. Image quality assurance of soft copy display systems. *J Digit Imaging* 2005; 18(4):280–6.
22. MacDonald-Jankowski DS, Orpe EC. Computed tomography for oral and maxillofacial surgeons. Part 2: Cone-beam computed tomography. *Asian J Oral Maxillofac Surg* 2006; 18:85–92.
23. Raggi P. Coronary calcium to assess cardiovascular risk in population studies. In: Subclinical atherosclerosis. Bianco JA, editor. New York: Taylor & Francis; 2006. p. 76–7.
24. Tamura T, Inui M, Nakase M, Nakamura S, Okumura K, Tagawa T. Clinicostatistical study of carotid calcification on panoramic radiographs. *Oral Dis* 2005; 11(5):314–7.
25. McKinney AM, Casey SO, Teksam M, Lucato LT, Smith M, Truwit CL, Kieffer S. Carotid bifurcation calcium and correlation with percent stenosis of the internal carotid artery on CT angiography. *Neuroradiology* 2005; 47(1):1–9.
26. Fournier v. Wiens, 2004 ABQB 430 (CanLII). Available from URL: <http://www.canlii.org/en/ab/abqb/doc/2004/2004abqb430/2004abqb430.html>.
27. Holsten v. Card, 1999 CanLII 1358 (BC S.C.) Available from URL: <http://www.canlii.org/bc/cas/bcsc/1999/1999bcsc11805.html>.