

Residual Neonatal Teeth: A Case Report

(Dents néonatales résiduelles : rapport de cas)

- Heather Dymont, DDS, Dip Paed, FRCD(C) •
- Ross Anderson, DDS, Dip Paed, MSc, FRCD(C) •
- Janice Humphrey, BSc, DDS, Dip Paed, MSc, FRCD(C) •
- Isabelle Chase, BSc, DDS, Dip Paed, FRCD(C) •

S o m m a i r e

On présente un cas où un enfant a eu besoin qu'on lui extraie 2 dents néonatales résiduelles. Certains auteurs proposent un curetage systématique des sièges d'extraction des dents natales et néonatales pour empêcher l'apparition de dents résiduelles. À la lumière de la rare apparition de telles dents, le curetage peut constituer un traitement excessif. En effet, le curetage au moment de l'extraction est recommandé seulement dans les cas où un anesthésique local injectable est nécessaire en raison d'une attache gingivale plus importante.

Mots clés MeSH : *infant, newborn; natal teeth/surgery; tooth, deciduous*

© J Can Dent Assoc 2005; 71(6):394-7
Cet article a été révisé par des pairs.

In 1950, Massler and Savara¹ introduced the now commonly used terms “natal teeth” for teeth present at birth and “neonatal teeth” for teeth that erupt within the first 30 days of life.

The incidence of natal and neonatal teeth has been investigated in multiple studies. In a 1995 review article, Zhu and King² tabled results from 10 studies dating from 1876 to 1991. For this group, the reported incidence of both natal and neonatal teeth ranged from 1:716 to 1:30,000. More commonly, as in the review article by Chow³ looking at 7 studies from 1950 to 1966, the incidence of natal and neonatal teeth ranges from 1:2,000 to 1:3,500.

The most common natal and neonatal teeth are the mandibular central incisors.^{1,4} In most cases, these teeth represent the true primary teeth and are not supernumerary teeth.¹ In King and Lee's⁴ 1989 report, 44 subjects presented with natal and neonatal teeth that were part of the primary dentition. In light of this knowledge, these teeth should be left in the mouth to avoid future space management issues. On occasion, they will exfoliate spontaneously or require extraction because of excessive mobility, concerns regarding aspiration or the loss of attachment with subsequent development of abscess. They may also be extracted to alleviate feeding difficulties including Riga-Fede disease, where the presence of

natal or neonatal teeth in association with nursing or sucking leads to ulceration of the ventral surface of the tongue.^{5,6}

Both general practice dentists and pediatric dental specialists may be involved in the supervision or treatment of patients with natal and neonatal teeth. On rare occasions, following spontaneous loss or extraction of these teeth, there may be continued root development necessitating further treatment.

Case Report

A 3-day-old infant was referred to a hospital pediatric dental clinic by her attending pediatrician for evaluation of neonatal teeth that were erupting in the mandibular anterior area. The teeth were not present at the time of her delivery.

A review of her medical chart revealed that she was born prematurely at 33 weeks and 4 days gestation and had a birth weight of 1,665 g. She experienced mild respiratory distress syndrome at birth but did not require ventilatory support. Otherwise, she was a healthy infant. At the time of her visit, she was admitted to the special care nursery for observation.

Examination revealed that the positions of the teeth present corresponded to those of teeth 71 and 81. The teeth did not appear to be excessively mobile and the child was feeding without difficulty. A decision was made to reassess the teeth

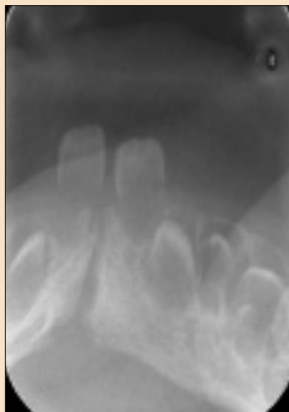

Figure 1: Mandibular anterior occlusal radiograph taken at age 17 days. Neonatal teeth 71 and 81 are present.

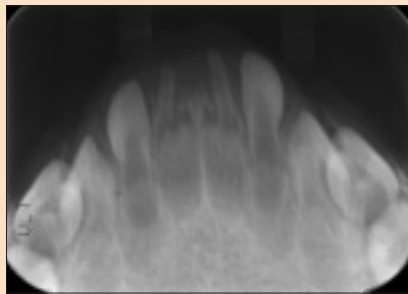


Figure 2: Mandibular anterior occlusal radiograph taken at approximately age 9.5 months. Radiopaque tissue has formed in the areas where tooth 71 exfoliated and tooth 81 was extracted.

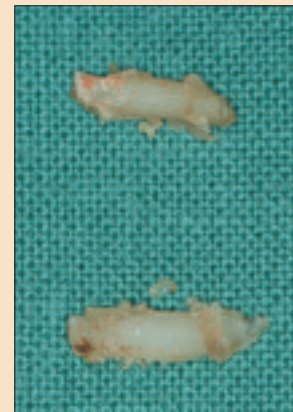

Figure 3: Extracted residual neonatal teeth 71 and 81.

once the child was out of her incubator and ready to be discharged home.

Two weeks after her first visit, the child returned for reassessment. She was continuing to grow appropriately and no feeding issues were identified. There was no evidence of excessive mobility of the teeth nor of Riga-Fede disease. A mandibular anterior occlusal radiograph was obtained with the parents' assistance (Fig. 1). It confirmed that the partly erupted teeth were teeth 71 and 81, the primary mandibular central incisors.

A week later, the dental service was again consulted when the family reported that "one tooth had fallen out and the other was very loose." Clinical examination confirmed that tooth 71 had exfoliated spontaneously. Tooth 81 displayed significant mobility and had only minimal attachment to the surrounding gingiva. After applying topical anesthetic to the adjacent gingiva and placing a piece of gauze lingual to tooth 81 to serve as a pharyngeal guard, the coronal aspect of tooth 81 was simply extracted with rongeur forceps. No curettage of the extraction site was performed. The postoperative course was uneventful and the baby was discharged from the special care nursery one week later.

Nine months later, the child was again referred to the dental clinic by her family physician. Her parents reported that she had been "screaming and crying" for the past 2 weeks and acetaminophen was ineffective in providing relief. Examination revealed 2 areas of hard tissue just visible at the crest of the alveolar ridge at the sites of the exfoliated tooth 71 and the extracted tooth 81. A mandibular anterior occlusal radiograph confirmed the presence of hard tissue at these sites (Fig. 2). There was no clinical or radiographic evidence of localized infection; however, the child appeared inconsolable as had been previously reported.

Behaviour management considerations influenced the decision to remove the remnants of teeth 71 and 81 under

general anesthetic. In the operating room, following the induction of general anesthesia, local anesthetic was infiltrated into the mandibular anterior area and the remnants of teeth 71 and 81 were easily removed with rongeur forceps (Fig. 3). A small piece of a resorbable hemostatic agent and one resorbable suture were placed at each extraction site. There was minimal blood loss and hemostasis was readily achieved. The child had an uneventful postoperative course and her irritability resolved rapidly.

Discussion

As stated by Ryba⁷ in 1962, the dental papilla requires an inductive stimulus from epithelium to form the tissues of the root and pulp. In the root area, this stimulus is provided by the Hertwig's epithelial root sheath (HERS), which grows around the dental papilla between it and the dental follicle.⁸

In his 1968 clinical and histopathologic study of retained dentin papillae in the newborn, Southam⁹ hypothesized that following the loss of the coronal tooth structure of natal and neonatal teeth, the exposed surface of the papilla was likely to become infected and necrotic together with the odontoblasts and remnants of the HERS. In rare cases, including the 2 he reported, enough elements of the tooth-forming tissues might remain vital and retain the capacity to form hard tissues.

There have been multiple case reports of continued development of tooth material following the spontaneous exfoliation or extraction of natal and neonatal teeth.^{4,7,10-15} To date, there has been no consistent nomenclature for describing the formation of dental hard tissue following loss of the coronal elements of natal and neonatal teeth. Reported findings have been variously referred to as "tumourlike masses,"⁷ "toothlike structures,"^{4,9,12,14} "irregular mass(es) of dentin,"⁹ "odontogenic remnants"¹¹ and "pearls of hard tissue."¹³ In 2002, Tsubone and colleagues¹⁰ introduced the term "residual natal tooth" for the calcified structure removed

from a patient described in their case report. We favour this descriptive term and suggest its use in future investigations and reports.

There has only been one published report indicating the frequency of development of residual teeth following loss of natal and neonatal teeth. In 1989, King and Lee⁴ studied 44 infants with natal or neonatal teeth, 4 of whom (9.1%) developed residual teeth following exfoliation or extraction of these teeth. Despite the small size of the study group, these results provide a rough estimate of the frequency of the development of residual natal and neonatal teeth. It would certainly appear that most children with natal and neonatal teeth do not experience residual tooth formation.

What can be done to prevent the development of residual natal teeth? It has been suggested by some authors that if natal or neonatal teeth require extraction, then routine curettage of the underlying tissues of the dental papillae is indicated to prevent formation of residual teeth.^{2,4,6} If curettage is to become the routine treatment, then the injection of local anesthetic to provide adequate anesthesia would be required.

A thorough clinical and radiographic examination provides parents with the information required to give informed consent for treatment. The knowledge that the majority of natal and neonatal teeth are part of the primary dentition and are not supernumerary teeth will influence parent-practitioner discussions relating to future space management and development of the occlusion. If extraction of natal or neonatal teeth is required, the practitioner will assess the amount of gingival attachment and a decision will have to be made as to what type(s) of anesthetic agents, if any, will be required.

For extraction of natal or neonatal teeth in cases where there is minimal gingival attachment, as in this case report, it will likely be possible to achieve adequate soft tissue anesthesia with the application of topical anesthetic. In this scenario, the authors recommend that no curettage of the extraction site be performed. In most cases, this treatment will be adequate and the child will not develop residual natal or neonatal teeth. Where it is possible, this conservative initial treatment will allow most children to avoid exposure to injectable local anesthetic and a lengthier, more stressful surgical procedure associated with curettage of the area. However, recognizing that the risk of residual tooth formation is approximately 9.1%, the parents should be informed of the need for regular follow-up with a dentist. They should also be informed that in the event of residual tooth formation, a second surgical procedure will be required.

For extraction of natal or neonatal teeth in cases where there is more significant gingival attachment, topical anesthetic may be followed with a small amount of an injectable local anesthetic. Only in these cases, where injection of local anesthetic is already indicated, do the authors recommend routinely providing simultaneous curettage of the area.

In both of the above scenarios, if extractions are planned within the first 10 days of life, then it must be confirmed that the child has been given the routine postnatal injection of

vitamin K to ensure that there will be no bleeding problems.¹⁶

Conclusion

A case report is presented in which an infant developed residual teeth following spontaneous exfoliation of neonatal tooth 71 and extraction of neonatal tooth 81. Other such cases have been reported in the literature. The adoption of the term "residual natal and neonatal teeth" is encouraged. In light of the rare occurrence of such teeth, the authors suggest that routine injection of local anesthetic and curettage of the dental papilla area when extracting the coronal portions of natal and neonatal teeth is too aggressive an approach. If it is possible to remove natal and neonatal teeth with only topical anesthetic, then no curettage is recommended and the child should be monitored for the possible development of residual teeth. In cases where there is more gingival attachment and local anesthetic is required to do the initial extraction(s), then it is recommended that the extraction sites be simultaneously curetted. ♦

Dr. Dyment is assistant professor, division of pediatric dentistry, faculty of dentistry, Dalhousie University, and staff pediatric dentist, IWK Health Centre, Halifax, Nova Scotia.

Dr. Anderson is assistant professor and head, division of pediatric dentistry, faculty of dentistry, Dalhousie University, and chief of dentistry, IWK Health Centre, Halifax, Nova Scotia.

Dr. Humphrey is assistant professor, division of pediatric dentistry, faculty of dentistry, Dalhousie University, and staff pediatric dentist, IWK Health Centre, Halifax, Nova Scotia.

Dr. Chase is assistant professor, division of pediatric dentistry, faculty of dentistry, Dalhousie University, and staff pediatric dentist, IWK Health Centre, Halifax, Nova Scotia.

Correspondence to: Dr. Heather Dyment, Department of Dentistry, IWK Health Centre, P.O. Box 3070, Halifax NS B3J 3G9. E-mail: hdyment@supercity.ns.ca.

The authors have no declared financial interests.

References

1. Massler M, Savara BS. Natal and neonatal teeth. A review of 24 cases reported in the literature. *J Pediatr* 1950; 36:349-59.
2. Zhu J, King D. Natal and neonatal teeth. *ASDC J Dent Child* 1995; 62(2):123-8.
3. Chow MH. Natal and neonatal teeth. *J Am Dent Assoc* 1980; 100:215-6.
4. King NM, Lee AM. Prematurely erupted teeth in newborn infants. *J Pediatr* 1989; 114(5):807-9.
5. Kinirons MJ. Prenatal ulceration of the tongue seen in association with a natal tooth. *J Oral Med* 1985; 40(3):108-9.
6. Buchanan S, Jenkins CR. Riga-Fedes syndrome: natal or neonatal teeth associated with tongue ulceration. Case report. *Aust Dent J* 1997; 42(4):225-7.
7. Ryba GE, Kramer IR. Continued growth of human dentine papillae following removal of the crowns of partly formed deciduous teeth. *Oral Surg Oral Med Oral Pathol* 1962; 15:867-75.
8. Ten Cate AR. Development of the tooth and its supporting tissues. In: Ten Cate AR. Oral histology: development, structure and function. 4th ed. St. Louis: Mosby-Year Book Inc.; 1994. p. 58-80.
9. Southam JC. Retained dentine papillae in the newborn. A clinical and histopathological study. *Brit Dent J* 1968; 125(12):534-8.

10. Tsubone H, Onishi T, Hayashibara T, Sobue S, Ooshima T. Clinico-pathological aspects of a residual tooth: a case report. *J Oral Pathol Med* 2002; 31(4):239–41.
11. Nedley MP, Stanley RT, Cohen DM. Extraction of natal and neonatal teeth can leave odontogenic remnants. *Pediatr Dent* 1995; 17(7):457.
12. Ooshima T, Mihara J, Saito T, Sobue S. Eruption of tooth-like structure following the exfoliation of natal tooth: report of case. *ASDC J Dent Child* 1986; 53(4):275–8.
13. Bigeard L, Hemmerle J, Sommermater JI. Clinical and ultrastructural study of the natal tooth: enamel and dentin assessments. *ASDC J Dent Child* 1996; 63(1):23–31.
14. Berendsen WJH, Wakkerman HL. Continued growth of the dentinal papillae after extraction of neonatal teeth: report of case. *ASDC J Dent Child* 1988; 55(2):139–41.
15. Berman DS, Silverstone LM. Natal and neonatal teeth. A clinical and histological study. *Br Dent J* 1975; 139(9):361–4.
16. Routine administration of vitamin K to newborns. Canadian Pediatric Society Clinical Practice Guideline. *Pediatr Child Health* 1997; 2(6):429–31.