


A Review of Bisphosphonate-Associated Osteonecrosis of the Jaws and Its Management

David K. Lam, DDS; George K.B. Sándor, MD, DDS, PhD, FRCD(C), FRCSC, FACS;
Howard I. Holmes, DDS; A. Wayne Evans, MD;
Cameron M.L. Clokie, DDS, PhD, FRCD(C)

Contact Author

Dr. Sándor
Email: george.sandor@utoronto.ca



ABSTRACT

Bisphosphonate-associated osteonecrosis (BON) may result in serious oral complications, such as osteomyelitis and chronic exposure of necrotic bone. Dentists must be familiar with this disorder and pay special attention to all patients on bisphosphonate therapy due to their defective osteoclast function and reduced osseous tissue vascularity, leading to impaired wound healing. The purpose of this paper is to review the history and pathogenesis of BON, discuss its differential diagnosis, provide guidance to dentists on possible measures to prevent BON and review the management of patients with BON.

For citation purposes, the electronic version is the definitive version of this article: www.cda-adc.ca/jcda/vol-73/issue-5/417.html

Bisphosphonate-associated osteonecrosis (BON) is a serious oral complication of bisphosphonate treatment involving the exposure of necrotic maxillary or mandibular bone.¹ BON is a most disappointing complication as bisphosphonates have an otherwise tremendously beneficial effect on the quality of life of patients with bony metastasis and those with severe symptomatic osteoporosis.²

BON is a recently recognized clinical entity, and new cases are being reported daily. As such, epidemiologic data such as prevalence cannot be accurately reported at this time, but the cumulative incidence of BON from intravenous bisphosphonate therapy has been estimated to range from 0.8% to 12%.³ However, with increased recognition of the condition, longer exposure to bisphosphonates and more follow-up, the reported incidence of BON is likely to increase.

Bisphosphonates are used in the treatment of osteopenic disorders as they have a high binding affinity with bone and interfere with osteoclast function, thereby slowing bone remodeling and turnover. Several types of bis-

phosphonates are in current use. Pamidronate and zoledronate are administered intravenously in patients with benign and malignant diseases involving excessive bone resorption, such as metastatic bone lesions of multiple myeloma and breast and prostate cancer. In pediatric patients, intravenous bisphosphonates are used in the management of osteogenesis imperfecta, idiopathic juvenile osteoporosis and osteopenic patients with juvenile rheumatoid arthritis who receive large doses of corticosteroids or methotrexate. However, unlike in adults, BON is thought to occur rarely, if at all, in children.⁴⁻⁶ Alendronate and risedronate are administered orally and are mainly used in the treatment of osteoporosis and Paget's disease. BON has also been observed with oral bisphosphonate use.⁷

In patients at risk for BON, osteomyelitis and osteonecrosis may occur following dental procedures. Thus, an understanding of the role of the oral microbiota and impaired tissue healing following seemingly minor surgical trauma in the pathogenesis of BON is important to the dental practitioner, who must

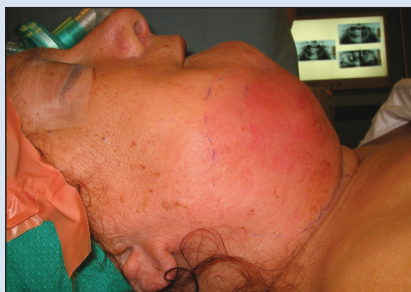

Figure 1a: Lateral view of 55-year-old woman with a past history of intravenous bisphosphonate therapy for multiple myeloma with acute suppurative osteomyelitis of the right mandible.

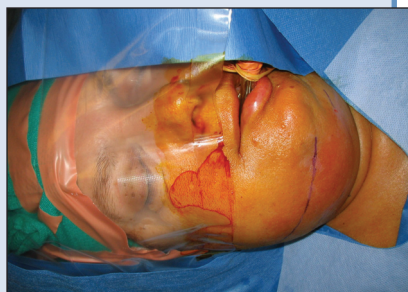

Figure 1b: Anterior view of extensive acute facial swelling associated with suppurative osteomyelitis following intravenous bisphosphonate therapy.

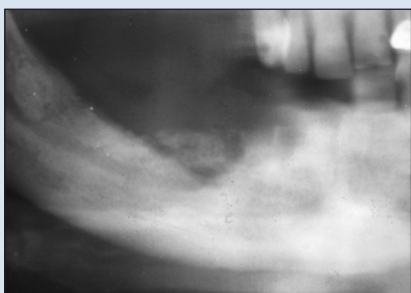


Figure 1c: Panoramic radiograph showing right mandibular osteomyelitis with sequestrum.

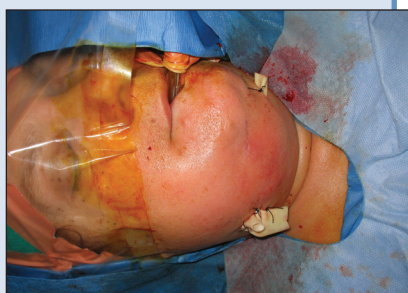

Figure 1d: Anterior view following incision and drainage with minimal debridement of tissue.

be vigilant in this setting to optimize oral health and prevent serious adverse sequelae. In this article, we review the important features of BON, including its pathogenesis, differential diagnosis, clinical findings and prevention, and provide management recommendations relevant to the dental practitioner.

Pathogenesis

Bone remodeling is a physiologically coordinated process involving bone formation by osteoblasts and bone resorption by osteoclasts. Imbalances between osteoblast and osteoclast activities result in skeletal abnormalities characterized by increases or decreases in bone density.^{8,9} Although the exact mechanism of bisphosphonate-induced osteoclast inhibition has not been completely elucidated, the less-potent non-nitrogen-containing bisphosphonates are believed to induce apoptosis in osteoclasts through the formation of cytotoxic metabolites of ATP that accumulate and interfere with intracellular metabolic enzymes.¹⁰ The nitrogen-containing bisphosphonates inhibit the mevalonate pathway.¹¹ Blocking the enzyme farnesyl diphosphate synthase creates an intracellular shortage of substances required for the post-translational lipid modification of small signaling

proteins with GTPase activity and the resulting dysfunction hampers the regulation of osteoclast morphology and activity, leading to poor cell functioning and apoptosis.^{12,13}

Recently, however, it has been suggested that bisphosphonates may inhibit osteoclast function without leading to apoptosis.⁷ The potent antiangiogenic properties of bisphosphonates are also well known.^{2,14} It may be the combination of inhibition of bone remodeling and decreased intraosseous blood flow caused by bisphosphonates that leads to BON.¹⁴

Osteonecrosis of the jaw, and often accompanying osteomyelitis, may be a serious consequence of the inability of the affected bone to meet the increased demand for repair and remodeling from physiologic stress (mastication), iatrogenic injury (dental extraction or denture irritation) or tooth infection in an environment that is trauma intense and bacteria laden.^{15,16} The biologic potency of an individual bisphosphonate is related to its uptake and retention by bone. The effects of bisphosphonates seem to persist for prolonged periods, and this could explain why osteonecrosis

appears after long-term treatment and even in cases in which bisphosphonate treatment has been discontinued.²

Clinical Presentation

Serious and previously unrecognized oral complications of bisphosphonate therapy may manifest as poor wound healing, spontaneous intraoral soft-tissue breakdown leading to intraoral bone exposure and bone necrosis in the oral and maxillofacial region¹ (**Figs. 1a–1d**). Although these complications may be seen in either the maxilla or mandible, the rate of occurrence is higher in the mandible.^{2,3}

According to a recent position paper by the American Association of Oral and Maxillofacial Surgeons,³ patients may be considered to have BON if they have a history of current or previous treatment with a bisphosphonate, exposed bone in the maxillofacial region that has persisted for more than 8 weeks and no history of radiation therapy to the jaws. Risk factors for the development of BON can be grouped as drug-related, local, demographic or systemic.³

Drug-related risk factors may include the potency of the particular bisphosphonate. For example, zoledronate is more potent than pamidronate, which is more potent

than the oral bisphosphonates.² The intravenous administration of bisphosphonates seems to confer a higher risk than oral administration. The duration of therapy is important, as longer duration appears to be associated with increased risk of BON development.

Local risk factors may include recent dentoalveolar surgery, such as extractions, dental implant placement, periapical surgery and periodontal surgery involving osseous injury.³ Other local factors include local anatomy, such as lingual or palatal tori, sharp mylohyoid ridges and concomitant oral disease such as periodontal or dental abscesses (Table 1).

Demographic factors may include increasing age.² Cancer diagnosis has been found to be important; the risk of developing BON is greater among patients with multiple myeloma than among those with breast cancer.^{3,4} The concurrent diagnosis of osteopenia or osteoporosis along with a cancer diagnosis is also a risk factor. Other risk factors may include corticosteroid therapy, diabetes, smoking, alcohol use, poor oral hygiene and chemotherapeutic drugs.³

Among patients taking oral bisphosphonates, the major risk factor is continuous bisphosphonate treatment for more than 3 years.¹⁷ Other risk factors include corticosteroid therapy, diabetes, smoking, alcohol use, poor oral hygiene and widened lamina dura and sclerotic bone seen on dental radiographs.¹⁷ Bisphosphonate exposure seems to render the bones of the jaws unable to respond to the stresses of infection or seemingly minor surgical trauma.

Symptoms in BON patients may be negligible, mild or severe and often occur after dental extraction, but might also occur spontaneously. The appearance of BON (Box 1) is identical to the appearance of osteoradionecrosis in patients who develop it after undergoing head and neck irradiation.¹⁸ The most severe cases can cause intense pain, extensive sequestration of bone and cutaneous draining sinus tracts.^{2,18} The exact reason for this complication is not clear, but the treatment of necrotic bone in BON is problematic and treatment issues are very similar to those in patients with osteopetrosis-related oral complications.

Histopathologic Features

Histopathology may reveal small nonvital bone fragments with bacterial colonies and an absence of inflammatory cells. Gram staining may reveal normal oral flora or, in cases of concomitant osteomyelitis, may include bacteria commonly found in osteomyelitis.^{7,19} It has been suggested that bisphosphonate therapy could induce a condition similar to that found with osteopetrosis. The development of an osteopetrosis-like state has been described in a 12-year-old boy following an extended course of pamidronate therapy.²⁰

Table 1 Assessment of risk of bisphosphonate-associated osteonecrosis in a patient

History of intravenous bisphosphonate therapy with:
Multiple myeloma
Metastatic bone disease with breast or prostate cancer
Osteogenesis imperfecta
Dental comorbidities
Active periodontitis
Dental caries
Dental abscesses
Failing root canal treatment
Any elective surgery in the oral cavity

Box 1 Common orofacial findings associated with BON

- Poor wound healing
- Spontaneous or postsurgical soft-tissue breakdown leading to intraoral or extraoral bone exposure
- Bone necrosis
- Osteomyelitis

Specific Laboratory Investigations

In addition to radiographic imaging, a complete blood count may help assess the state of the patient in terms of possible infection. Cultures of the infected bone tend to yield normal oral flora^{2,18}; however, cultures of draining abscesses may be helpful in tailoring antibiotic treatment.

Assays to monitor markers of bone turnover, such as serum or possibly urine N-telopeptide (NTx) and C-telopeptide (CTx) levels, may help in the future diagnosis of BON.^{21,22} NTx and CTx are fragments of collagen that are released during bone remodeling and turnover. Bisphosphonates reduce NTx and CTx levels. Monitoring of the risk of BON development through the various phases of bisphosphonate therapy may also be possible in the future using serum CTx levels,^{21,22} which are thought to be reliable indicators, although they are subject to some daily variation.¹⁷ Currently, testing for serum CTx levels is available at a few hospitals.

Differential Diagnosis

Patients who are at risk of BON or those with established BON may also present with other common clinical conditions not to be confused with BON. These conditions include, but are not limited to, alveolar osteitis (dry socket), sinusitis, gingivitis, periodontitis, caries, periapical pathology and temporomandibular disorders.³ Some of these conditions, such as periodontitis, and

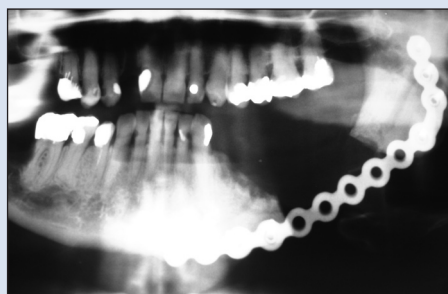


Figure 2a: Panoramic radiograph of dentition in a 70-year-old man with multiple myeloma and bisphosphonate-associated osteonecrosis following a palliative resection of the mandible with insertion of a reconstruction plate.

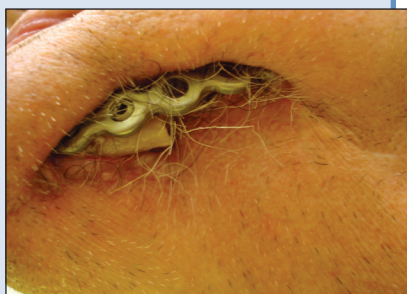

Figure 2b: The reconstruction plate has become exposed despite attempts to keep the wound clean. These wounds are inherently unstable and progressive die-back of tissue and continued exposure of bone and hardware may occur despite well-intentioned minimal wound debridements. All surgical interventions in these patients must be kept to a minimum. The role of salvage surgery is yet to be defined.

bridement cannot be carried out without potentially causing further bone exposure.^{2,18}

A more conservative palliative approach may be the sequential removal of bony sequestra as required but, if more extensive debridement becomes necessary, the goal should be to remove as little bone as possible and, more important, to avoid disturbing the delicate overlying soft tissue. Gentle, frequent rinsing and irrigation with saline and antimicrobials is recommended to keep the wound clean.²⁵ The American Dental Association Council on Scientific Affairs recommends a focus on conservative surgical procedures, proper sterile technique, appropriate use of disinfectants and the principles of effective antibiotic therapy.^{25,26}

periapical pathology could also contribute to the development of BON in patients at risk.

Osteopetrosis may resemble BON, presenting with an area of denuded avascular bone. However, osteopetrosis can easily be differentiated from BON by its classic radiographic appearance and by the lack of history of bisphosphonate exposure.

Treatment and Prognosis

The management of BON of the jaws presents a challenge to dentists as there is no effective treatment for this condition at this time. Patients with asymptomatic exposed bone may be best treated with systemic antibiotics such as penicillin or clindamycin, an oral antimicrobial rinse such as chlorhexidine and close follow-up.^{18,23}

Drug Holidays

Temporary interruption of bisphosphonate treatment can be considered in severe cases if the benefits outweigh the risks of skeletal-related events resulting from drug termination. Some patients may not be able to survive without bisphosphonate therapy. Others may develop further spontaneous fractures if bisphosphonates are discontinued. Improvements in BON may not be observed with drug discontinuation because measurable levels of bisphosphonates may persist in bone for up to 12 years after cessation of therapy.²⁴

Conservative Therapy

Attempts at extensive debridement and local flap closure often seem to be unsuccessful and may result in even larger areas of exposed and painful infected bone.³ The difficulty in treating this condition is that de-

Removal of only symptomatic bony sequestra with minimal disturbance of overlying soft tissues along with topical and systemic antibiotics may be the treatment modality of choice at present.²³⁻²⁸ Patients with draining sinuses, extensive areas of necrotic bone or large sequestra may require more extensive surgical procedures and their treatment course is typically protracted. In extensive cases where purulent exudates or sinus tracts are visualized, culture and microbial sensitivity testing may be warranted.

For many patients, complete healing may never occur and they must resign themselves to living with some degree of bone exposure. Management may then be limited to providing analgesia and controlling disease progression. There have been limited reports of salvage surgery where soft tissue coverage is attempted with transfers of vascularized tissue.²⁹ However, such extensive procedures may be precluded by the patient's otherwise debilitated condition (**Figs. 2a** and **2b**). Although hyperbaric oxygen therapy was first believed not to be effective in treating BON,²⁶ new evidence shows that it may hold some promise.^{27,28}

Prevention and Dialogue

Due to the tremendous difficulty of treating BON, the focus should be on prevention. When intravenous or high-dose oral bisphosphonates are considered appropriate, close and ongoing communication between the dentist and the treating oncologist, endocrinologist or family physician is of paramount importance.¹⁷ Complete dental assessment and treatment before the initiation of therapy should be considered.^{3,14,25} If bisphosphonate therapy can be delayed, preventive surgery to eliminate

Table 2 Summary of Marx's protocol¹⁷ and suggestions for patients on oral bisphosphonates who require oral surgery

Bisphosphonate use > 3 years
<ul style="list-style-type: none"> • Contact physician to discontinue bisphosphonate 3 months before surgery and for at least 3 months postoperatively, but preferably for 1 year. • Determine serum CTx level at time of consultation and immediately before surgery. CTx must be ≥ 150 pg/mL before proceeding with surgery. • Detail informed consent regarding risk of bisphosphonate-associated osteonecrosis (BON). • Use an alternative to bisphosphonate for long-term treatment, if possible.
Bisphosphonate use < 3 years with no clinical or radiographic risk factors ^a
<ul style="list-style-type: none"> • CTx level must be > 150 pg/mL. • Proceed with planned surgery but with informed consent regarding the increased risk of possible future BON with surgical treatment. • Establish a regular recall schedule; contact physician to discuss alternative treatment and intermittent drug holidays.
Bisphosphonate use < 3 years with 1 or more clinical or radiographic risk factors ^a
<ul style="list-style-type: none"> • Stop bisphosphonate therapy for 3-month drug holiday. • If CTx level < 150 pg/mL, <ul style="list-style-type: none"> • delay surgery and stop bisphosphonate therapy for at least 3 more months • recheck CTx level 3 months later. • If CTx level > 150 pg/mL then proceed with surgery. • If CTx remains < 150 pg/mL then no surgery and check CTx level again in 3 months. • 3-month drug holiday post-surgery.

Note: CTx = C-telopeptide.

^aSteroid use, widened lamina dura or sclerotic bone.

potential sites of infection should ideally be performed before the onset of bisphosphonate therapy. Otherwise, any elective dental procedure requiring bone healing should be avoided.^{3,14,25}

Once bisphosphonate therapy has been initiated, optimal oral health is an absolute must and all patients should be educated on the importance of good oral hygiene and regular clinical monitoring by a dentist. In addition, dental caries and periodontal disease should be controlled and denture stresses on mucosa should be minimized in edentulous or partially edentulous pa-

tients. It is also important for dentists to be aware of the poor surgical outcomes in patients receiving bisphosphonate treatment and to recognize poor wound-healing responses early. They should consider referring these patients to an oral and maxillofacial surgeon for even the most routine dental extraction. In general, the goal should be to keep the dentition in such a state as to be able to avoid future extractions.

Suggested Protocols

Marx¹⁷ has suggested a management protocol for bisphosphonate patients who absolutely must have an oral surgical procedure. It takes into account the type and duration of bisphosphonate therapy, bisphosphonate discontinuance and CTx monitoring at the time of consultation and immediately before surgery. For a patient who has been taking an oral bisphosphonate longer than 3 years, serum CTx should ideally be checked at the time of consultation. The bisphosphonate would then be discontinued for 3 months before the procedure if approved by the patient's physician. Serum CTx would be rechecked at the time of surgery; CTx level should be greater than 150 pg/mL before proceeding with surgery. The patient would not take bisphosphonate for a further 3 months following surgery.¹⁷ This protocol is further summarized in **Table 2**.

Conclusion


BON research is rapidly developing. Very recent studies such as the one by Mavrokokki and others,³⁰ which reviews the Australian demographics of BON, are important because they add to our understanding of this serious condition. This study found that 72% of BON cases occurred in patients with bone malignancies. In 73% of the cases, the main trigger was dental extraction.³⁰ A total of 114 cases of BON were reported of which 82 patients had a bone malignancy, 26 patients had osteoporosis and 6 patients had Paget's disease. All the patients with osteoporosis had been treated with oral bisphosphonates.³⁰ The frequency of BON in patients receiving bisphosphonate treatment for osteoporosis was 1 in 2,260. When extractions were performed on these patients, the frequency of BON was 1 in 296. For Paget's disease, the frequency of BON was 1 in 56 and with extractions, it was 1 in 7.4. In patients with bone malignancy, the frequency of BON was 1 in 87 and with extractions, it was 1 in 11.³⁰

Special attention should be given to all patients on bisphosphonate therapy due to their defective osteoclast function and local tissue vascularity, leading to impaired wound healing. These patients should receive maximum attention to prevent dental problems and maintain their oral health. Preventive measures must be instituted before, during and after the treatment of patients taking bisphosphonates. Dentists should consider referring these

patients to a specialist for even the simplest necessary extraction or other dental surgical procedures to manage the serious adverse effects that may arise from oral surgery. Every effort should be made to avoid extractions or other elective surgical procedures in this high-risk group of patients until further clarification from long-term studies becomes available.

Future prospective trials and long-term follow-up in our local Canadian health care environment are necessary to determine future evidence-based recommendations that are relevant to the management of BON in the Canadian context. ❖

THE AUTHORS



Dr. Lam is senior resident, division of oral and maxillofacial surgery and anesthesia, Mount Sinai Hospital; PhD Harron Scholar, Collaborative Program in Neuroscience; and clinician-scientist fellow, University of Toronto Centre for the Study of Pain, University of Toronto, Toronto, Ontario.



Dr. Sándor is professor and clinical director, graduate program in oral and maxillofacial surgery and anesthesia, University of Toronto and Mount Sinai Hospital; coordinator of pediatric oral and maxillofacial surgery at The Hospital for Sick Children and Bloorview Kids Rehab, Toronto, Ontario; and docent in oral and maxillofacial surgery at the University of Oulu, Oulu, Finland.



Dr. Holmes is director of the surgical orthodontic program and undergraduate program in oral and maxillofacial surgery, University of Toronto, Toronto, Ontario.



Dr. Evans is associate professor, hyperbaric medicine unit, department of anesthesia, faculty of medicine, University of Toronto, Toronto, Ontario.



Dr. Clokie is professor and head, oral and maxillofacial surgery and anesthesia, University of Toronto, Toronto, Ontario.

Correspondence to: Dr. George K.B. Sándor, The Hospital for Sick Children, S-525, 555 University Ave., Toronto ON M5G 1X8.

The authors have no declared financial interests.

This article has been peer reviewed.

References

- Melo MD, Obeid G. Osteonecrosis of the jaws in patients with a history of receiving bisphosphonate therapy: strategies for prevention and early recognition. *J Am Dent Assoc* 2005; 136(12):1675–81.
- Ruggiero SL, Mehrotra B, Rosenberg TJ, Engroff SL. Osteonecrosis of the jaws associated with the use of bisphosphonates: a review of 63 cases. *J Oral Maxillofac Surg* 2004; 62(5):527–34.
- Advisory Task Force on Bisphosphonate-Related Osteonecrosis of the Jaws, American Association of Oral and Maxillofacial Surgeons. American Association of Oral and Maxillofacial Surgeons position paper on bisphosphonate-related osteonecrosis of the jaws. *J Oral Maxillofac Surg* 2007; 65(3):369–76.
- Greenberg MS. Intravenous bisphosphonates and osteonecrosis. *Oral Surg Oral Med Oral Pathol Oral Radiol Endod* 2004; 98(3):259–60.

- Rauch F, Glorieux FH. Osteogenesis imperfecta. *Lancet* 2004; 363(9418):1377–85.
- van Beek ER, Cohen LH, Leroy IM, Ebetino FH, Lowik CW, Papapoulos SE. Differentiating the mechanisms of antiresorptive action of nitrogen containing bisphosphonates. *Bone* 2003; 33(5):805–11.
- Leite AF, Figueiredo PT, Melo NS, Acevedo AC, Cavalcanti MG, Paula LM, and others. Bisphosphonate-associated osteonecrosis of the jaws. Report of a case and literature review. *Oral Surg Oral Med Oral Pathol Oral Radiol Endod* 2006; 102(1):14–21. Epub 2006 Mar 20.
- Vaananen K. Mechanism of osteoclast mediated bone resorption — rationale for the design of new therapeutics. *Adv Drug Deliv Rev* 2005; 57(7):959–71.
- Bukowski JF, Dascher CC, Das H. Alternative bisphosphonate targets and mechanisms of action. *Biochem Biophys Res Commun* 2005; 328(3):746–50.
- Rogers MJ, Gordon S, Benford HL, Coxon FP, Luckman SP, Monkkonen J, and other. Cellular and molecular mechanisms of action of bisphosphonates. *Cancer* 2000; 88(12 Suppl):2961–78.
- Shipman CM, Rogers MJ, Apperley JF, Russell RG, Croucher PJ. Bisphosphonates induce apoptosis in human myeloma cell lines: a novel anti-tumor activity. *Br J Haematol* 1997; 98(3):665–72.
- Reszka AA, Rodan GA. Bisphosphonate mechanism of action. *Curr Rheumatol Rep* 2003; 5(1):65–74.
- Halasy-Nagy JM, Rodan GA, Reszka AA. Inhibition of bone resorption by alendronate and risedronate does not require osteoclast apoptosis. *Bone* 2001; 29(6):553–9.
- Migliorati CA, Casiglia J, Epstein J, Jacobsen PL, Siegel MA, Woo SB. Managing the care of patients with bisphosphonate-associated osteonecrosis: an American Academy of Oral Medicine position paper. *J Am Dent Assoc* 2005; 136(12):1658–68.
- Melo MD, Obeid G. Osteonecrosis of the maxilla in a patient with a history of bisphosphonate therapy. *J Can Dent Assoc* 2005; 71(2):111–3.
- Jimenez-Soriano Y, Bagan JV. Bisphosphonates, as a new cause of drug-induced jaw osteonecrosis: an update. *Med Oral Pathol Oral Cir Bucal* 2005; 10(Suppl 2):E88–91.
- Marx RE. Oral and intravenous bisphosphonate-induced osteonecrosis of the jaws. History, etiology, prevention, and treatment. Quintessence Publishing Co Inc; 2007. p. 9–96.
- Marx RE. Pamidronate (Aredia) and zoledronate (Zometa) induced avascular necrosis of the jaws: a growing epidemic. *J Oral Maxillofac Surg* 2003; 61(9):1115–7.
- Dimitrakopoulos I, Magopoulos C, Karakasis D. Bisphosphonate-induced avascular osteonecrosis of the jaws: a clinical report of 11 cases. *Int J Oral Maxillofac Surg* 2006; 35(7):588–93. Epub 2006 May 9.
- Whyte MP, Wenkert D, Clements KL, McAlister WH, Mumm S. Bisphosphonate-induced osteopetrosis. *N Engl J Med* 2003; 349(5):457–63.
- Greenspan SL, Rosen HN, Parker RA. Early changes in serum N-telopeptide and C-telopeptide cross-linked collagen type 1 predict long-term response to alendronate therapy in elderly women. *J Clin Endocrinol Metab* 2000; 85(10):3537–40.
- von Schewelov T, Carlsson A, Dahlberg L. Cross-linked N-telopeptide of type I collagen (NTx) in urine as a predictor of periprosthetic osteolysis. *J Orthop Res* 2006; 24(7):1342–8.
- Hellstein JW, Marek CL. Bisphosphonate osteochemonecrosis (bis-phossy jaw): is this phossy jaw of the 21st century? *J Oral Maxillofac Surg* 2005; 63(5):682–9.
- Lin JH, Russell G, Gertz B. Pharmacokinetics of alendronate: an overview. *Int J Clin Pract Suppl* 1999; 101(1):18–26.
- American Dental Association Council on Scientific Affairs. Dental management of patients receiving oral bisphosphonate therapy: expert panel recommendations. *J Am Dent Assoc* 2006; 137(8):1144–50.
- Van den Wyngaert T, Huizing MT, Vermorken JB. Bisphosphonates and osteonecrosis of the jaw: cause and effect or a post hoc fallacy? *Ann Oncol* 2006; 17(8):1197–204.
- Biasotto M, Chiandussi S, Dore F, Rinaldi A, Rizzardi C, Cavalli F, and other. Clinical aspects and management of bisphosphonate-associated osteonecrosis of the jaws. *Acta Odontolog Scand* 2006; 64(6):348–54.
- Shimura K, Shimazaki C, Taniguchi K, Akamatsu S, Okamoto M, Uchida R, and others. Hyperbaric oxygen in addition to antibiotic therapy is effective for bisphosphonate-induced osteonecrosis in a patient with multiple myeloma. *Int J Hematol* 2006; 84(4):343–5.
- Kademani D, Koka S, Lacy MQ, Rajkumar SV. Primary surgical therapy for osteonecrosis of the jaw secondary to bisphosphonate therapy. *Mayo Clin Proc* 2006; 81(8):1100–3.
- Mavrokokki T, Cheng A, Stein B, Goss A. Nature and frequency of bisphosphonate-associated osteonecrosis of the jaws in Australia. *J Oral Maxillofac Surg* 2007; 65(3):415–23.