

# Resin-Bonded Fixed Partial Dentures: What's New?

Chris C.L. Wyatt, DMD, MSc, FRCD(C)

## Contact Author

Dr. Wyatt

Email: [cwyatt@interchange.ubc.ca](mailto:cwyatt@interchange.ubc.ca)



## ABSTRACT

**Background and Objective:** Dentists often question the use of resin-bonded fixed partial dentures (RBFDPs) for reliable restoration of tooth-bound edentulous spaces. Initial attempts at bonding fixed partial dentures on teeth resulted in early failure due to debonding. In the 1980s and 1990s, improvements in preparation methods, metal alloys and bonding techniques made the RBFDP a more predictable option. In this paper, we summarize recent information concerning its success and failure.

**Methods:** A MEDLINE search using key words describing RBFDPs was carried out to identify pertinent English articles appearing in peer-reviewed journals since 2000.

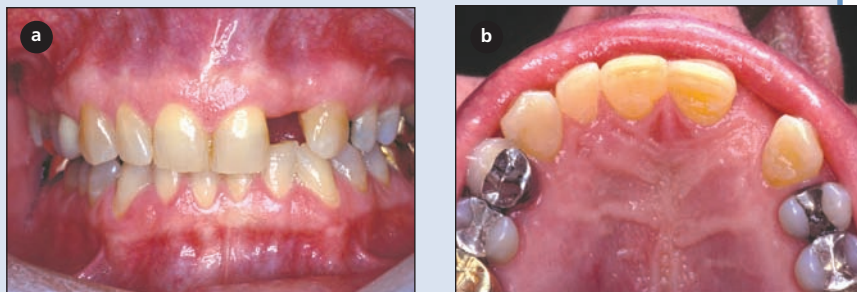
**Results:** The principle reason for failure of RBFDPs remains debonding of the framework from the abutment teeth. Selection of nonmobile abutment teeth, preparation to enhance retention and resistance form, choice of the appropriate alloy and metal, and tooth bonding technique are the keys to success. The use of cantilever and nonrigid attachments may decrease interabutment forces and reduce debonding of retainers.

**Conclusions:** The survival rate of RBFDPs is still considerably lower than that of conventional fixed partial dentures. Although RBFDPs can be used in both the anterior and posterior regions of the mouth to replace 1 or 2 missing teeth, careful abutment selection, tooth preparation, alloy selection and bonding technique are critical for clinical success.

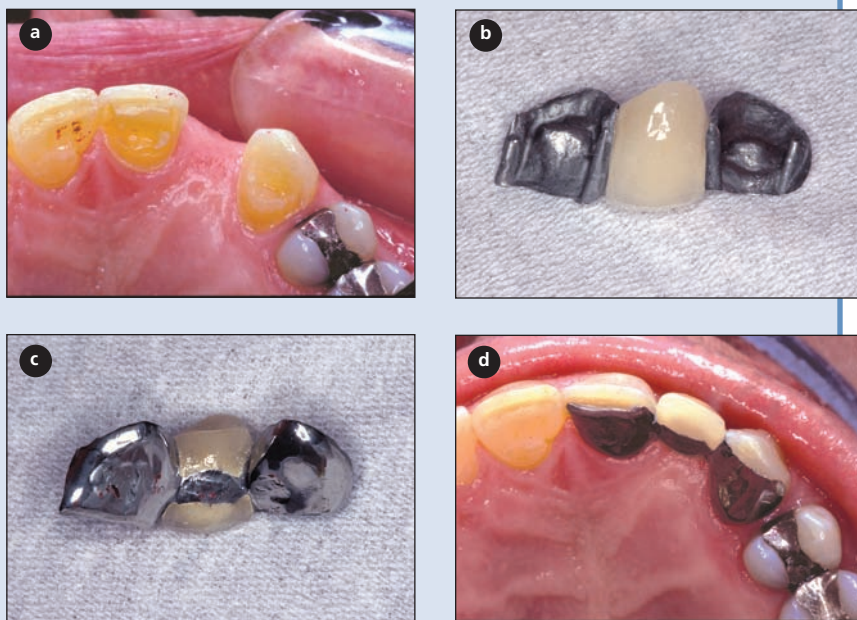
For citation purposes, the electronic version is the definitive version of this article: [www.cda-adc.ca/jcda/vol-73/issue-10/933.html](http://www.cda-adc.ca/jcda/vol-73/issue-10/933.html)

The prosthetic restoration of small edentulous spans poses a dilemma when the adjacent teeth do not require crowns. It is difficult to justify extensive reduction of the adjacent teeth to support a conventional fixed partial denture. A single-tooth implant is an alternative for patients with adequate bone dimensions and who are willing to undergo a minor surgical procedure. However, oral implants are not the treatment of choice for many patients and the resin-bonded fixed partial denture (RBFDP) offers a possible solution.

In the 1970s, Howe and Denehy<sup>1</sup> adapted the Rochette bonded cast-metal periodontal splint concept<sup>2</sup> to create the first RBFDP. The early procedures were conservative, but problems with debonding resulted in a survival rate of only 28% at 7.5 years.<sup>3</sup> To enhance retention and resistance form of posterior RBFDPs, Livaditis<sup>4</sup> recommended preparation of parallel guide surfaces on the interproximal and lingual aspects of the adjacent teeth along with rests on the occlusal aspect to counteract dislodging forces. Resin bonding was further



**Figure 1:** (a) Facial view of missing maxillary left lateral incisor. (b) Occlusal view of missing maxillary left lateral incisor.



**Figure 2:** (a) Tooth preparation finish lines for anterior resin-bonded fixed partial denture (RBFDP). (b) Facial view of anterior RBFDP. (c) Palatal view. (d) Occlusal view.

enhanced by using solid electrolytically etched base-metal-alloy casting.<sup>5</sup> The result was a doubling of the survival rate to 64% at 7.5 years.<sup>3</sup> In the 1980s and 1990s, significant advances in metal surface treatment, dentin bonding and resin cements potentially improved the clinical success rate of RBFPDs. A meta-analysis<sup>6</sup> identified 60 papers published in the 1980s reporting success rates for various designs; Kaplan-Meier statistical analysis determined an overall survival of 74% ± 2% at 4 years for 1,598 RBFPDs compared with 74% ± 2% at 15 years for 4,118 conventional fixed partial dentures.

In this paper, we summarize outcomes of RBFPDs published in English-language, peer-reviewed journals since 2000. In addition, new information concerning preparation, material selection and bonding of RBFPDs is explored. Articles were identified by a MEDLINE search using key words describing RBFPDs.

## Patient Selection

Patients with small edentulous spans bounded by sound teeth are good candidates for RBFPDs (Fig. 1). The potential abutment teeth should be healthy, unrestored or minimally restored, free of caries and periodontal disease, and have an adequate crown height and width. A nonmobile tooth with an adequate surface area of enamel provides an ideal abutment. Although the young are more likely to have sound teeth, debond rates are higher among people under 30 years of age.<sup>7</sup>

Although the RBFDP is considered a definitive solution for single-unit edentulous spaces bounded by healthy teeth, case reports on the use of this procedure as a provisional treatment continue to be published. Poyser and others<sup>8</sup> recommend the Rochette bridge as an alternative to an acrylic resin removable partial denture. Al-Wahadni and Al-Omari<sup>9</sup> calculated a 90.5% success rate over the short term (35 months) for 21 RBFPDs used as provisional prostheses immediately following tooth extraction. Two mandibular posterior devices failed after 3 and 4 months due to trauma, but were successfully rebonded.

## Tooth Preparation

Since 2000, modification of the tooth preparation process has been advocated to enhance retention and resistance form of RBFPDs. The goal is to create a defined path of insertion for the framework while minimizing the display of metal. Frameworks have been extended maximally on the lingual aspect of teeth to improve resistance form and prevent dislodgment of the restoration. The use of defined rest preparations (cingulum and occlusal) has been advocated to provide support or prevent dislodgement toward the gingival aspect. The use of proximal grooves on molars in preparation for RBFPDs has resulted in significant improvements in retention and resistance as measured by dislodgement forces on maxillary ivory teeth; however, no significant improvement has been noted for mandibular molars.<sup>10</sup> Although tooth preparation is required, less than half the amount of coronal tooth structure by weight is removed compared with that removed for complete coverage crowns.<sup>11</sup> According to studies of debonding, the mean debonding rate for RBFPDs placed

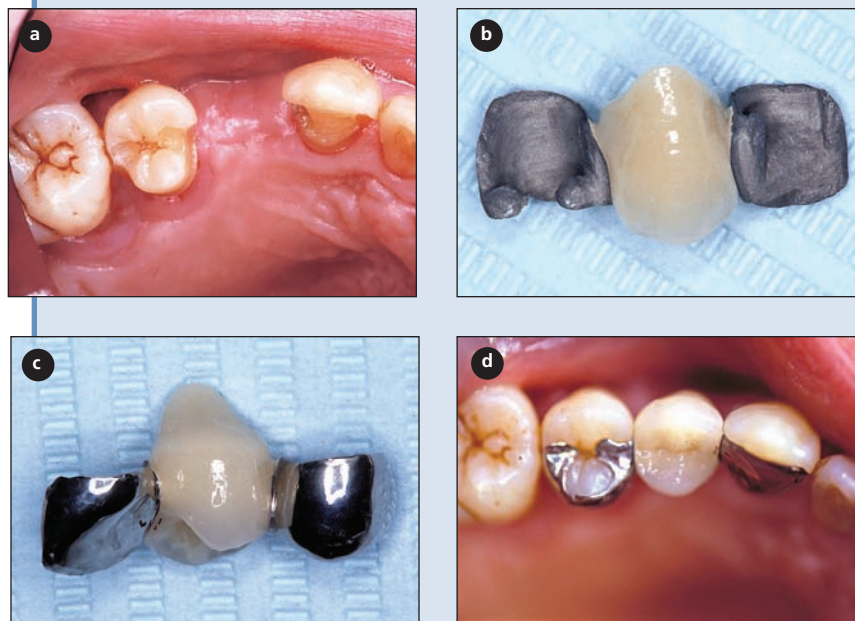
without retentive tooth preparation was 47% compared with only 11% for those with retentive preparation.<sup>7</sup>

El-Mowafy and Rubo<sup>12</sup> recommend an anterior design involving a 0.5-mm lingual reduction of enamel and a 1-mm supragingival reduction extending to the centre of the interproximal contact, with an incisal finish line 2 mm short of the incisal edge for optimal esthetics (Fig. 2). Adequate and parallel axial reduction of the proximal surface adjacent to the edentulous area and extending lingual to the planned interproximal contact is required for a path of insertion and retention. Maximum extension onto the proximal surfaces with proximal grooves will enhance resistance for the RBFDP and prevent mesiodistal and faciolingual dislodgement. A cingulum rest with a flat floor will provide support, preventing movement toward the gingival aspect.

A posterior design that creates parallelism between the proximal surfaces of the teeth adjacent to the edentulous space creates an optimal insertion path.<sup>12,13</sup> The supragingival preparation, 0.5 mm within enamel, should extend from the facial line angle lingual to just short of the interproximal contact area on each of the adjacent teeth. Occlusal rests and the base of the lingual grooves provide support, preventing movement toward the gingival aspect (Fig. 3). Alternatively, slot or box preparations replacing existing restorations may be used for framework support. Creating a box with a slight convergence toward the occlusal aspect to lock in the composite resin cement can enhance retention.<sup>12</sup> A similar posterior design has been recommended by Chow and others<sup>14</sup> with the addition of a palatal groove and an occlusal strut (mesial-distal groove) to enhance resistance form. Shimizu and Takahashi<sup>15</sup> describe a posterior design that involves preparation extending from a mid-buccal to a mid-lingual groove and incorporating an occlusal rest on each abutment tooth. However, this display of metal on the buccal surface may not be acceptable where esthetics are a concern.

### Alternative Designs

The use of a single abutment to support a single pontic may be a viable alternative RBFDP design, at least for anterior regions. The design principles are the same as for the conventional RBFDP, with conservative tooth preparation, but optimizing resistance form.<sup>16</sup> The preparation should be confined to enamel as much as possible and



**Figure 3:** (a) Tooth preparation finish lines for posterior resin-bonded fixed partial denture (RBFDP). (b) Facial view of posterior RBFDP. (c) Palatal view. (d) Occlusal view.

maximize the surface area to enhance bonding of a rigid framework. Occlusion on the pontic should be kept to a minimum and molar-sized pontics should be avoided.

A review<sup>17</sup> of 11 clinical studies using cantilevered RBFDPs concluded that this prosthetic design was reliable and predictable and had greater longevity than conventional RBFDPs with 2 abutments. Compared with conventional RBFDPs, this restoration is claimed to have better esthetics, to involve less tissue damage, to be easier to clean, to be less expensive and to have no chance of undetected debond due to its single retainer.<sup>17</sup> When 269 2-unit cantilevered RBFDPs were followed for at least 2 years, debonding occurred in 14 (94.8% success rate); no changes in occlusion occurred in relation to drifting of abutment teeth.<sup>18</sup>

The integration of a nonrigid connector between the abutment and the pontics of long-span, RBFDPs with 2 or more pontics may reduce debond failure by allowing independent movement of the abutment teeth.<sup>19</sup> This design reduces the interabutment stresses that tend to cause debonding. The nonrigid connector is designed to allow movement in the vertical and horizontal planes, such that the least mobile retainer contains the matrix.<sup>19</sup> A clinical success rate of 92.2% was noted for 43 RBFDPs with 2 or more pontics that were followed up to 87 months.<sup>20</sup> All failed prostheses replaced posterior teeth, and adverse occlusal contacts on the abutment teeth were speculated to be the cause of this failure.

## Bonding

The preparation of abutment teeth for RBFDPs using the previously described 0.5-mm axial reduction with further reduction for grooves, boxes and rest seats likely exposes dentin. An *in vitro* study of 20 extracted premolars after RBFDP preparation noted dentin exposure on all specimens; the mean area of exposure was 11.06 mm<sup>2</sup> (16.15%).<sup>21</sup> Preparation of 1-mm deep interproximal grooves exposed dentin in all teeth. Axial reduction resulted in variable dentin exposure at the gingival margin. Reliance on dentin bonding in modern RBFDP preparation designs seems a reality.

Base metal alloys, typically nickel–chromium–beryllium, are preferred over gold alloys due to their enhanced bond to resin cements. *In vitro* testing using aqueous aging and cyclic loading of Panavia-F (Kuraray Co., Ltd., Osaka, Japan) cemented RBFDPs determined that debonding was a result of cohesive failure within the cement at the filler–resin interface.<sup>22</sup> No difference in debond rates over 6 and 12 months was noted between nickel–chromium based RBFDPs cemented with Panavia 21 Opaque (Kuraray Co., Ltd.) and Scotchbond Multi-Purpose with Scotchbond Resin Cement (3M Dental Products, St. Paul, Minn.); however, the latter (a clear cement) was associated with graying of the abutment teeth.<sup>23</sup>

*In vitro* testing of combinations of chrome–cobalt metal surface treatments and resin cements found the use of Unifix (Cavex Holland BV, Haarlem, Holland) and airborne-particle abrasion (50 micron aluminium oxide) provided the firmest physical bond.<sup>24</sup> Similar research using nickel–chromium alloy also resulted in good bond strengths.<sup>25</sup> Airborne-particle abrasion of the alloy significantly improved bond strength; further enhancement was achieved by using 96% isopropanol for 3 minutes in an ultrasonic cleaner-than-air dryer for an additional 3 minutes.<sup>25</sup>

Use of tin-plating gold alloys to enhance bonding has not been predictable and led researchers to explore other surface treatments. The use of a metal primer (Alloy Primer, Kuraray Co., Ltd.) significantly improved the tensile bond strength between gold–palladium alloys and human enamel compared with airborne-particle abrading and tin plating.<sup>26</sup> This primer is based on acetone, 10-methacryloyloxydecyl dihydrogen phosphate and 6-vinylbenzyl-*n*-propyl amino triazine dithione. The use of a vinyl-thiol primer (a solution of acetone containing 0.5% 6-[4-vinylbenzyl-*n*-propyl] amino-1,3,5-triazine-2,4-dithiol) to bond gold alloy based RBFDPs resulted in a clinical success rate (76.9% at 10 years) similar to that for conventional base-metal alloys.<sup>27</sup> The use of silica coating to enhance bonding of RBFDP frameworks resulted in a similar survival rate.<sup>28</sup>

El-Mowafy and Rubo<sup>12</sup> recommend rubber dam isolation to enhance bonding of the RBFDP to tooth structure.

A retrospective study of 100 RBFDPs placed between 1993 and 2003 found that various preparation designs, metal alloys, metal preparations, number of abutments and pontics were not predictive of debonding.<sup>29</sup> However, the use of rubber dam during cementation significantly reduced the risk of debonding.

## Esthetics

Multiple questionnaires completed by 358 patients during regular recalls revealed that the degree of satisfaction with RBFDPs was high and did not seem to be influenced by the occurrence of failure.<sup>30</sup> However, satisfaction was correlated with complaints about colour and shape of the pontics. The metal framework of resin-bonded bridges may also darken thin or translucent abutment teeth; 5 studies identified this problem, with an overall occurrence of 18%.<sup>7</sup> The fracture of porcelain on the pontics is an esthetic complication that was identified in 15 studies with a mean incidence of 3%.<sup>7</sup>

## Clinical Success and Failure

An extensive literature review<sup>7</sup> to identify the incidence of complications in fixed prosthodontics included RBFDPs. This study reviewed 56 publications, although when multiple reports on the same patient groups were eliminated, only 8 papers published between 1984 and 1998 remained. A total of 1,823 complications occurred in 7,029 RBFDPs in service for 1 month to 15 years. The overall debond rate of 21% affected 1,481 prostheses. The debond rate during the first 2 years was 10%, between 2–5 years the rate was 20%, and at > 5 years the rate was 24%. The debond rate for RBFDPs with more than 1 pontic (52%) was double that for frameworks supporting a single pontic.

Individual studies reporting on success of current design principles and bonding techniques show promise. The mean survival rate, based on bond retention, was 85% after 5 years for 100 RBFDPs placed between 1993 and 2003 at the University of Turin.<sup>29</sup> The annual debond rate over 3 years was 4.6% for 59 RBFDPs placed by predoctoral dental students.<sup>31</sup> The debond rate was 3 times higher in the mandible than the maxilla, with the poorest survival (debond rate 13.4%) in the anterior mandible. No differences in periodontal health (bleeding on probing and pocket depth) were noted between abutment teeth and controls.

Using Kaplan-Meier analysis, Zalkind and others<sup>32</sup> determined that 51 conventional base-metal alloy RBFDPs placed under controlled clinical conditions and followed over 13 years had a mean life expectancy of 85 months (7 years) ± 13%. Cox's proportional hazard analysis revealed that abutment teeth that were periodontally involved (relative risk [RR] 9.40) and were treated following orthodontics (RR 7.88) were significantly

associated with failure of RBFDPs. Tooth mobility was the likely cause of failure in both these situations.

The use of supragingival margins should allow for adequate oral hygiene to control dental plaque and prevent gingivitis, periodontitis and dental caries. A lack of clinical impact on gingival and periodontal conditions has been reported; however, 22 studies of RBFDPs reporting on caries revealed a mean occurrence of 7%.<sup>7</sup> The complicating factor may be debonded frameworks; 7 studies reported on caries in conjunction with debonded retainers.

The use of cantilevered RBFDPs may be a viable alternative to 2 abutment RBFDPs. Kaplan-Meier survival estimates showed no significant difference between the survival rate for 77 RBFDPs (63%) and 25 cantilevered RBFDPs (81%) after 4 years.<sup>33</sup> A review of 2-unit cantilevered RBFDPs at the Prince Philip Dental Hospital (Hong Kong) revealed that 82 prostheses had a survival rate of 95.1% over the short term (mean service life  $36.7 \pm 15.4$  months; range 4.3–95.4 months).<sup>34</sup> This high success rate may be due to minimal function or occlusal load.

### Patient Satisfaction

Mandibular bilateral distal extension cantilevered RBFDPs were found to be equivalent or superior to removable partial dentures for 60 patients who completed satisfaction questionnaires.<sup>35</sup> No difference in quality of life was noted between patients provided with implant crowns and those receiving RBFDPs.<sup>36</sup> This study compared 11 patients with implant crowns and 33 with RBFDPs; the 2 groups were matched for gender, age, edentulous span and location of prostheses within the mouth. The self-administered quality-of-life questionnaire contained 2 subscales related to oral condition (mastication, pronunciation, swallowing, oral cleaning and esthetics) and general condition (physical function and psychological state). No differences were noted between treatment types. Patient satisfaction with cantilevered RBFDPs was also high; however, 10% were concerned about the metal appearance of the prostheses.<sup>34</sup>

### Conclusions

RBFDPs can be used successfully in both the anterior and posterior regions of the mouth to replace 1 or 2 missing teeth. However, the survival rate of RBFDPs is still considerably less than that of conventional fixed partial dentures. The principle reason for failure is debonding of the framework from the abutment teeth. The use of cantilevered and nonrigid attachments may decrease interabutment forces and reduce debonding of retainers. The selection of nonmobile abutment teeth, preparation designs that enhance retention and resist-

ance form, appropriate alloy selection and metal and tooth bonding technique are critical for success. ♦

### THE AUTHOR



**Dr. Wyatt** is associate professor and head of the division of prosthodontics, department of oral health sciences, faculty of dentistry, University of British Columbia, Vancouver, British Columbia.

**Correspondence:** Dr. Chris C.L. Wyatt, Department of Oral Health Sciences, Faculty of Dentistry, University of British Columbia, 2199 Wesbrook Mall, Vancouver, BC V6T 1Z3.

The author has no declared financial interests in any company manufacturing the types of products mentioned in this article.

This article has been peer reviewed.

### References

- Howe DF, Denehy GE. Anterior fixed partial dentures utilizing the acid-etch technique and a cast metal framework. *J Prosthet Dent* 1977; 37(1):28–31.
- Rochette AL. Attachment of a splint to enamel of lower anterior teeth. *J Prosthet Dent* 1973; 30(4):418–23.
- Creugers NH, Kayser AF, van't Hof MA. A seven-and-a-half-year survival study of resin-bonded bridges. *J Dent Res* 1992; 71(11):1822–5.
- Livaditis GJ. Cast metal resin-bonded retainers for posterior teeth. *J Am Dent Assoc* 1980; 101(6):926–9.
- Livaditis GJ, Thompson VP. Etched castings: an improved retentive mechanism for resin-bonded retainers. *J Prosthet Dent* 1982; 47(1):52–8.
- Creugers NH, Kayser AF, Van't Hof MA. A meta-analysis of durability data on conventional fixed bridges. *Community Dent Oral Epidemiol* 1994; 22(6):448–52.
- Goodacre CJ, Bernal G, Rungcharassaeng K, Kan JY. Clinical complications in fixed prosthodontics. *J Prosthet Dent* 2003; 90(1):31–41.
- Poyser NJ, Briggs PF, Chana HS. A modern day application of the Rochette bridge. *Eur J Prosthodont Restor Dent* 2004; 12(2):57–62.
- Al-Wahadni AM, Al-Omari WM. Immediate resin-bonded bridgework: results of a medium-term clinical follow-up study. *J Oral Rehabil* 2004; 31(1):90–4.
- Emara RZ, Byrne D, Hussey DL, Claffey N. Effects of groove placement on the retention/resistance of resin-bonded retainers for maxillary and mandibular second molars. *J Prosthet Dent* 2001; 85(5):472–8.
- Edelhoff D, Sorensen JA. Tooth structure removal associated with various preparation designs for anterior teeth. *J Prosthet Dent* 2002; 87(5):503–9.
- El-Mowafy O, Rubo MH. Retention of a posterior resin-bonded fixed partial denture with a modified design: an in-vitro study. *Int J Prosthodont* 2000; 13(5):425–31.
- El-Mowafy O, Rubo MH. Resin-bonded fixed partial dentures — a literature review with presentation of a novel approach. *Int J Prosthodont* 2000; 13(6):460–7.
- Chow TW, Chung RW, Chu FC, Newsome PR. Tooth preparations designed for posterior resin-bonded fixed partial dentures: a clinical report. *J Prosthet Dent* 2002; 88(6):561–4.
- Shimizu H, Takahashi Y. Retainer design for posterior resin-bonded fixed partial dentures: a technical report. *Quintessence Int* 2004; 35(3):653–4.
- Botelho M. Design principles for cantilevered resin-bonded fixed partial dentures. *Quintessence Int* 2000; 31(9):613–9.
- Van Dalen A, Feilzer AJ, Kleverlaan CJ. A literature review of two-unit cantilever FPDs. *Int J Prosthodont* 2004; 17(3):281–4.
- Botelho MG, Leung KC, Ng H, Chan K. A retrospective clinical evaluation of two-unit cantilevered resin-bonded fixed partial dentures. *J Am Dent Assoc* 2006; 137(6):783–8.
- Botelho MG. Improved design of long-span resin-bonded fixed partial dentures: three case reports. *Quintessence Int* 2003; 34(3):167–71.
- Botelho MG, Dyson JE. Long-span, fixed-movable, resin-bonded fixed partial dentures: a retrospective, preliminary clinical investigation. *Int J Prosthodont* 2005; 18(5):371–6.

21. Bassi GS, Youngson CC. An in vitro study of dentin exposure during resin-bonded fixed partial denture preparation. *Quintessence Int* 2004; 35(7):541–8.
22. Walker MP, Spencer P, Eick JD. Effect of simulated resin-bonded fixed partial denture clinical conditions on resin cement mechanical properties. *J Oral Rehabil* 2003; 30(8):837–46.
23. Aboush YE, Estetah N. A prospective clinical study of a multipurpose adhesive used for the cementation of resin-bonded bridges. *Oper Dent* 2001; 26(6):540–5.
24. Van Dalen A, Feilzer AJ, Kleverlaan CJ. The influence of surface treatment and luting cement on in vitro behavior of two-unit cantilever resin-bonded bridges. *Dent Mater* 2005; 21(7):625–32.
25. Quaas AC, Heide S, Freitag S, Kern M. Influence of metal cleaning methods on the resin bond strength to NiCr alloy. *Dent Mater* 2005; 21(3):192–200.
26. Petrie CS, Eick JD, Williams K, Spencer P. A comparison of 3 alloy surface treatments for resin-bonded prostheses. *J Prosthodont* 2001; 10(4):217–23.
27. Hikage S, Hirose Y, Sawada N, Endo K, Ohno H. Clinical longevity of resin-bonded bridges using a vinyl-thiol primer. *J Oral Rehabil* 2003; 30(10):1022–9.
28. Ketabi AR, Kaus T, Herdach F, Groten M, Axmann-Krcmar D, Probst L, and other. Thirteen-year follow-up study of resin-bonded fixed partial dentures. *Quintessence Int* 2004; 35(5):407–10.
29. Audenino G, Giannella G, Morello GM, Ceccarelli M, Carossa S, Bassi F. Resin-bonded fixed partial dentures: ten-year follow-up. *Int J Prosthodont* 2006; 19(1):22–3.
30. Creugers NH, De Kanter RJ. Patients' satisfaction in two long-term clinical studies on resin-bonded bridges. *J Oral Rehabil* 2000; 27(7):602–7.
31. Aslani E, Johansson J, Moberg LE. Resin-bonded bridges by dental undergraduates: three-year follow-up. *Swed Dent J* 2001; 25(1):21–9.
32. Zalkind M, Ever-Hadani P, Hochman N. Resin-bonded fixed partial denture retention: a retrospective 13-year follow-up. *J Oral Rehabil* 2003; 30(10):971–7.
33. Chai J, Chu FC, Newsome PR, Chow TW. Retrospective survival analysis of 3-unit fixed-fixed and 2-unit cantilevered fixed partial dentures. *J Oral Rehabil* 2005; 32(10):759–65.
34. Botelho MG, Chan AW, Yiu EY, Tse ET. Longevity of two-unit cantilevered resin-bonded fixed partial dentures. *Am J Dent* 2002; 15(5):295–9.
35. Jepson N, Allen F, Moynihan P, Kelly P, Thomason M. Patient satisfaction following restoration of shortened mandibular dental arches in a randomized controlled trial. *Int J Prosthodont* 2003; 16(4):409–14.
36. Sonoyama W, Kuboki T, Okamoto S, Suzuki H, Arakawa H, Kanyama M, and others. Quality of life assessment in patients with implant-supported and resin-bonded fixed prostheses for bounded edentulous spaces. *Clin Oral Implants Res* 2002; 13(4):359–64.