

Nerve Injuries after Dental Injection: A Review of the Literature

Miller H. Smith, BMedSc, DDS; Kevin E. Lung, BSc, DDS, MSc, FRCD(C)

Contact Author

Dr. Lung
Email:
k.lung@kingswayos.com



ABSTRACT

Prolonged and possibly permanent change in sensation due to nerve damage can occur after dental injections. Although the condition is rare, many practitioners will see this form of nerve injury during their careers. The exact mechanism of the injury has yet to be determined, and little can be done to prevent its occurrence. This type of injury carries with it many functional and psychological implications, and referral to both dental and medical specialists may be necessary for continued follow-up and possible treatment.

MeSH Key Words: anesthesia, dental/adverse effects; mandibular nerve/injuries; nerve block/adverse effects; sensation disorders/etiology

© J Can Dent Assoc 2006; 72(6):559–64
This article has been peer reviewed.

A temporary reduction in sensations, notably nociception (pain), during dental procedures can drastically reduce anxiety in the dental workplace and decrease patients' negative experiences.¹ Yet regardless of how beneficial a health care procedure may be, there are always associated disadvantages and risks.² Incomplete anesthesia, hematoma formation, broken needles, trismus, infection, toxic reactions and allergic responses, including anaphylaxis, are all potential problems with dental injections.^{3,4} Another documented complication after injection of local anesthetic in the dental setting is prolonged and possibly permanent alteration of sensation over the areas supplied by the involved nerve(s).^{3–11}

Neural Anatomy

Each peripheral nerve fibre is surrounded by a basal lamina, collagen fibres and endoneurial capillaries, which together form the endoneurial connective tissue layer^{12–15}

(Fig. 1). The nerve fibres are grouped into fascicles surrounded by a connective tissue layer called the perineurium. This perineurial layer helps to support, protect and sustain the individual nerve fibres.^{12–15} The outer layer, the epineurium, protects the underlying fascicles by resisting tensile and compressive forces. This layer is composed of connective tissue, lymphatic vessels and nutrient vessels (the vasa nervorum).¹⁶ A loose areolar connective tissue layer, the mesoneurium, surrounds the epineurium and provides the nerve with a segmental blood supply.^{12–15} If any of these extra-neural tissues are disrupted, a sensory disturbance may result because of interrupted neural transmission.¹⁵

Local anesthetics for use in dentistry are designed to prevent sensory impulses from being transmitted from specific intraoral and extraoral areas to the central nervous system, with minimal effect on muscular tone.¹ Nerve injuries after either supraperiosteal or proximal block injections can affect

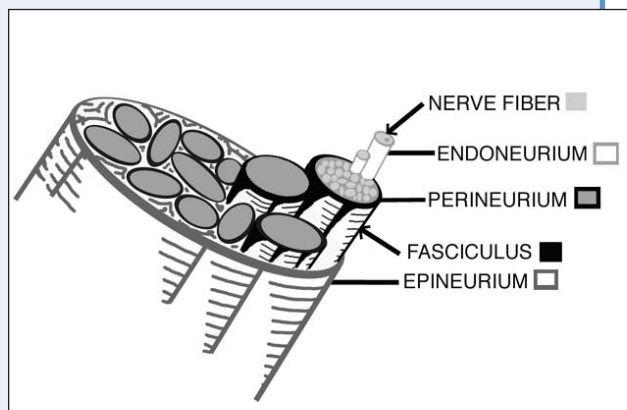


Figure 1: Diagram of peripheral nerve anatomy and individual connective tissue components.

mechanoreception (touch, pressure and position), thermoreception (hot and cold) and nociception (pain).^{8,15,17} In some instances taste sensation may be altered as well.⁸

Mechanisms

The exact mechanism of injury is still a subject of debate but a number of theories have been proposed.⁵

Direct Trauma from the Injection Needle

One of the oldest theories is that the needle contacts the nerve directly, thereby traumatizing the nerve and producing a prolonged change in sensation. This could explain why the lingual nerve, which is only 3 to 5 mm from the mucosa and the intraoral landmark for mandibular nerve block, the pterygomandibular raphe, is most commonly involved (more than 70% of cases).^{1-3,5} When the mouth is open, the lingual nerve is held taut within the interpterygoid fascia, and because of its fixation, it cannot be deflected away by the needle.^{3,5,10,11} However, this nerve may be penetrated initially and further damaged upon localization of the lingula by needle orientation.¹⁸

In correct execution of the mandibular block technique, the practitioner contacts bone to ensure proper deposition of the local anesthetic.¹ A long bevelled needle is often used to create less severe tissue and nerve damage on insertion, but the tip of these needles is much more prone to becoming barbed when contacting the bone or when used for multiple injections.⁵ In one study, 78% of the long bevelled needles used for conventional mandibular block appeared to be barbed at their tips after the procedure, regardless of bevel placement.¹⁹ More than two-thirds of these needles displayed the more dangerous outward facing barb.¹⁹ These barbs can rupture the perineurium, herniate the endoneurium and cause transection of multiple nerve fibres and even entire fascicles, especially on withdrawal.^{8,19,20} The Seddon¹³ and

Sunderland¹² classification systems categorize this type of injury as axonotmesis or second- or third-degree nerve injury, respectively.

Given the number of neurons and the thickness of the connective tissue layers, the lingual nerve averages 1.86 mm in diameter and the inferior alveolar nerve between 2 and 3 mm in diameter,^{8,11} but the diameter of the largest needle (25-gauge) used in dentistry is a mere 0.45 mm. Although any number of fascicles may be injured by direct needle trauma, causing transient paresis, it is believed to be impossible for the needle to shear all nerve fibres and connective tissue layers as in neurotmesis (Seddon classification) or fifth-degree injury (Sunderland classification).^{8,10,11}

Hematoma Formation

Several researchers have hypothesized that the needle may traumatize the intraneural blood vessels, creating an intraneural hematoma.^{5,8,11,19,20} Hemorrhage from the epineurial blood vessels would give rise to constrictive epineuritis, compressing the nerve fibres within the rigid tissue confines and causing localized neurotoxicity.^{5,19} The damage could be extensive a mere 30 minutes after the injection.¹¹ The release of blood and blood products from the epineurial blood vessels into the epineurium during hematoma formation would lead to reactive fibrosis and scar formation, applying pressure to and inhibiting the natural healing of the nerve.^{5,8-10}

Depending on the amount of pressure elicited by the hematoma, the injury could be classified as neurapraxia (Seddon classification) or first-degree injury (Sunderland) or as axonotmesis (Seddon) or second-degree injury (Sunderland). The former is characterized by focal block of neural impulses with maintenance of axonal and connective tissue continuity.^{10,12-14,19} Recovery occurs over several weeks with the release of pressure and subsequent remyelination.¹⁴ The latter is more severe, with variable amounts of axonal and endoneurial discontinuity and ensuing wallerian degeneration.^{10,12,14,15} The proximal segment attempts neurotization, and nerve sprouts can grow as much as 1 to 2 mm per day to span the gap created by the injury.^{12,14,15} The surviving Schwann cells and the empty endoneurial tubes attempt to guide the nerve regeneration and to provide the axon with metabolites for growth.¹⁵

Neurotoxicity of Local Anesthetic

More recent speculation suggests that the anesthetic itself causes localized chemical damage to the nerve, if it is injected intrafascicularly or becomes deposited within the nerve as the needle is withdrawn.^{5,21,22} It has been hypothesized that aromatic alcohols are produced in the area surrounding the nerves as a result of altered local metabolism of the anesthetic.^{8,11} The presence in the anesthetic or on the needle of alcohols and sterilizing solutions, which were

used in the past, has previously been blamed for nerve injuries.^{3,8,20,22} Chemical trauma has been shown to cause demyelination, axonal degeneration and inflammation of the surrounding nerve fibres within the fascicles.²³ As a result, the nerve–blood barrier breaks down, and endoneurial edema follows. One group of authors hypothesized that this edema causes ischemia, which is followed by an attempt by the nerve to heal. During this period of reperfusion, reactive free radicals can cause cytotoxic injury to the nerve.²³

In some studies, the anesthetics prilocaine and articaine have caused more injuries per use than lidocaine.^{5,7,8} Both of these anesthetics are supplied at higher concentrations,⁸ which will (after metabolism) produce greater levels of toxic metabolites.^{23,24} At higher concentrations, lidocaine has also been shown to cause neurotoxic damage following both perineural and intrafascicular injection.^{11,24}

Incidence of Injury

It has become apparent that the injection of local anesthetic can produce prolonged or permanent alteration of sensation along part or all of the distribution of either the maxillary (V₂) or mandibular (V₃) branches of the trigeminal nerve.^{5,11} These altered sensations can be categorized as anesthetics, paresthesias or dysesthesias.^{14,21} Anesthetics represent the total absence of sensation, including pain. Paresthesias encompass a broader category of abnormal sensations, such as “pins and needles,” which may not be unpleasant. Dysesthesias represent a form of spontaneous or mechanically evoked painful neuropathy. This category can encompass hyperalgesia (a rapid and exaggerated painful response to nonpainful stimuli), hyperpathia (a delayed and prolonged pain response), sympathetic mediated pain (pain that is worsened by increasing sympathetic tone) and anesthesia dolorosa (pain in an area of anesthesia).^{14,21}

It is well known that an electric shock sensation, with subsequent immediate anesthesia, can occur when a patient undergoes inferior alveolar, lingual or mental nerve block. This unwelcome shock sensation is believed to occur when the needle contacts part of the nerve trunk.²¹ The incidence of this sensation has been estimated at between 1.3% to 8% of all mandibular block injections, depending on the sample size.^{4–6,10,11,25} Numerous studies have demonstrated that an electric shock sensation is not indicative of permanent nerve injury, even though damage to the nerve may occur because of needle contact.¹¹ This form of direct trauma heals within 2 weeks in 81% of patients, with no residual damage to the nerve.¹¹ Upward of 15% of the patients who experience electric shock sensations may go on to experience further prolonged or even permanent altered

sensation,^{10,11} though this estimate may be high. Only 57% of the patients who experience prolonged altered sensation also experienced an electric shock sensation or painful injection at the time of anesthetic delivery.⁵

When estimating the incidence of nerve injury after dental injection, only noninvasive dental procedures should be included; in the case of a surgical procedure, it must be assumed that the surgery is the cause of any nerve injury.⁵ The most commonly involved nerve is the lingual nerve (tongue) and it accounts for more than two-thirds of the cases in the literature; the inferior alveolar nerve (lip and chin), including the mental nerve, accounts for less than one-third of the injuries, with the chorda tympani (taste) being involved minimally.^{5,8} Although extremely rare, altered sensation in the maxilla can also result from anesthetic injections.⁸ Early estimates predicted the likelihood of such a complication as 1 in 785,000 injections.⁸ More recently, another author approximated this number at between 1 in 160,571 and 1 in 26,762 mandibular blocks;⁵ this increase in incidence was attributed to increased awareness through recent publications and greater use of potentially neurotoxic anesthetics.^{5,26} Using this most recent estimate, we can extrapolate that the average full-time dentist should expect to have 1 or 2 nonsurgical patients affected by this postinjection complication.⁵

Two-thirds of patients with permanent nerve involvement experience anesthesia or paresthesia, whereas one-third experience dysesthesias, which have much greater social and psychological impacts.^{5,8,27} For reasons unknown, dysesthesias occur at higher frequency after dental injections (34%) than after surgery (8%).^{5,7} In comparison to those who underwent surgical procedures, patients who experienced nerve damage after minor dental procedures felt more disabled.⁷ Perhaps patients undergoing surgical treatment are better informed of the risks beforehand.

Sensory Testing

In most sensory testing, the entire distribution of the affected nerve seems to be involved, rather than a small number of fascicles.^{5,11} It has been estimated that the inferior alveolar and lingual nerves contain between 7,000 and 12,000 axons in various fascicular arrangements.¹⁵ In one recent study, the lingual nerve of 33% of patients contained a single fascicle at the level of the lingula.²⁸ More distally, in the third molar region, the lingual nerve may contain between 7 and 39 fascicles. The lower number of proximal fascicles may be the reason for permanent sensory disturbances along the entire distribution of the lingual nerve. The inferior alveolar nerve, however, has a minimum of 3 fascicles, which could account for the

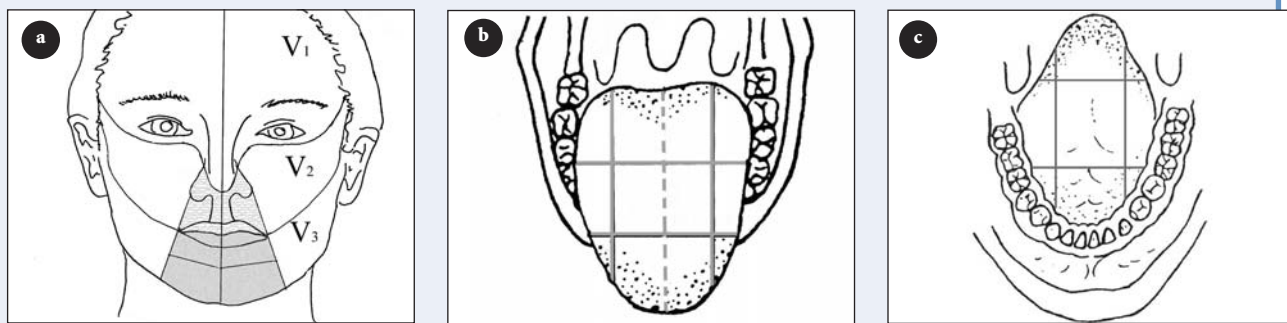


Figure 2: Diagrams for neurosensory assessment. (a) The mental region of V₃ can be tested for inferior alveolar and mental nerve injuries. Note its division into 4 quadrants of approximately equal size. The premaxillary region of V₂ can be tested for superior alveolar nerve injuries. (b) The tongue is divided into sextants on either side of the midline to represent the anterior, middle and posterior thirds of both the medial and lateral halves. (c) The ventral surface of the tongue and floor of the mouth can be documented in a similar fashion.

ability to regain sensation (through compensatory innervation from the uninjured fascicles).²⁸

Following diagnosis of prolonged altered sensation caused by dental injection, continued follow-up is necessary.^{9,29} If there is no improvement within 2 weeks, then referral to an oral surgeon or an oral pain specialist is advised for a baseline sensory exam.⁹ It is essential to document the mechanism and the date of the initial injury, the symptom history, prior treatment and its effect, functional deficits (speech and mastication difficulties, tongue and cheek biting, taste dysfunction^{8,27,29}) and the presence of any underlying medical disorder (e.g., psychological problems).⁹ Altered sensations of either the tongue or the mental area can be documented using the diagram shown in Fig. 2.

Numerous tests are used to define the extent of the injury; however, these tests are qualitative and highly dependent on both the patient's subjective assessment and the practitioner's expertise.³⁰ Pinprick testing, which represents pain, is used to map out the area of altered sensation. Von Frey's hairs are then used to evaluate touch and pressure sensation. Directional sense is determined using a fine paintbrush, and positional sense using a blunt point. Static and moving 2-point discrimination can be useful, as can testing of temperature sensation using Minnesota thermal disks. The taste sensations of sweet, salt, sour and bitter can also be subjectively analyzed.^{5,9,14,21,30,31} If dysesthetic pain is present, then a diagnostic nerve block can be used to determine if the neuropathy is of peripheral origin.^{9,14} Central problems such as anesthesia dolorosa and sympathetic mediated pain will not resolve with local anesthetic.^{9,21} Some people even advocate electroencephalography, although its usefulness has yet to be determined.²¹ It has been proposed that evaluations should continue every 2 weeks for 2 months, then every 6 weeks for 6 months, every 6 months for 2 years and yearly indefinitely if a full recovery has not occurred.²¹

Prognosis

Patients with nerve injury after dental injection, regardless of the presence or absence of electric shock sensation, have a good prognosis. Spontaneous complete recovery from the altered sensation occurs within 8 weeks in 85% to 94% of cases.^{4,5,7,14} The inferior alveolar nerve often carries a more favourable prospect of recovery because of the confines of the bony canal and the lack of mobility relative to the lingual nerve.⁷ Patients with paresthesia lasting beyond 8 weeks after the initial injury have less chance of full recovery.^{11,21,29}

Treatment

Few studies have specifically addressed treatment for this type of nerve injury. Both surgical and pharmaceutical management have been used, with varying success.^{11,14–16,29,32–39} Patients who experience troublesome prolonged alteration in sensation may be candidates for treatment based loosely on the inclusion criteria for nerve injuries sustained by surgical procedures. The selection criteria of some authors include anesthesia for 2 to 3 months with no improvement, paresthesia for 4 to 6 months with no improvement for 2 months or dysesthesias of minimum duration 2 to 3 months.⁷ Dysesthesias relieved by diagnostic injections of local anesthetic show the most potential to benefit from surgical treatment; however, symptoms may not completely resolve and in some cases may worsen with invasive surgical investigation or treatment.^{5,9,14}

In the rare instance when the microneurosurgeon and the patient agree on exploratory surgery, variable results can be achieved with decompression involving external and internal neurolysis, excision with direct anastomosis or excision with placement of a nerve graft (including autogenous sural, greater auricular and medial antebraichial nerve grafts,^{9,14} saphenous vein grafts,³⁵ and alloplastic Gore-Tex, collagen and polyglycolic acid

tubes^{9,32}). However, most results in the literature reflect treatment for nerve injuries related to surgical trauma.^{11,14–16,29,32–39} Only one study has published results directly related to a microneurosurgical approach to nerve injuries caused by dental injection; in that study, the overall treatment outcome with exploration and neurolysis was poor.⁵

Long-term nonsurgical pharmacologic therapy has also been used for some patients. Medications such as anticonvulsants (carbamazepine, phenytoin, gabapentin, topiramate), benzodiazepines, tricyclic antidepressants, antispasmodics (e.g., baclofen) and anesthetics (e.g., lidocaine)^{9,11,40} have been shown to benefit patients suffering from dysesthesias, especially those that are sympathetically mediated.⁹

Conclusions

Nerve injuries after dental injection are of concern to dentists, as injection of local anesthetic is one of the procedures that dentists perform most frequently. Although this form of injury is rare, more patients are being referred to dental or medical specialists, who have experience in nerve assessment and repair, for follow-up and possible treatment. Overall, the prognosis is excellent, and the vast majority of patients recover during the first few weeks. However, the longer the symptoms persist, the less promising the outcome. Increased awareness of this form of complication will allow the general practitioner to effectively communicate the implications and prognosis of the altered sensation to affected patients. Because anesthetic solutions with elevated concentrations are implicated in many such injuries, their widespread use may need to be reconsidered by dentists and dental specialists alike. ✦

THE AUTHORS



Dr. Smith is a third-year resident in the department of oral and maxillofacial surgery, University of Michigan, Ann Arbor, Michigan.



Dr. Lung is clinical associate professor in the department of medicine and dentistry, University of Alberta, Edmonton, Alberta. He is also in private practice at Kingsway Oral Surgery in Edmonton.

Correspondence to: Dr. Kevin Lung, Suite 107E, 14310-111 Ave., Main Floor, Coronation Plaza, Edmonton, AB T5M 3Z7.


The authors have no declared financial interests.

References

- Malamed SF. Handbook of local anesthesia. 4th ed. St. Louis: Mosby; 1997.
- Blanton PL, Roda RS. The anatomy of local anaesthesia. *J Calif Dent Assoc* 1995; 23(4):55–58, 60–2, 64–5.
- Kramer HS Jr, Mitton VA. Complication of local anaesthesia. *Dent Clin North Amer* 1973; 17(3):443–60.
- Krafft TC, Hickel R. Clinical investigation into the incidence of direct damage to the lingual nerve caused by local anaesthesia. *J Craniomaxillofac Surg* 1994; 22(5):294–6.
- Pogrel MA, Thamby S. Permanent nerve involvement resulting from inferior alveolar nerve blocks. *J Am Dent Assoc* 2000; 131(7):901–7.
- Lustig JP, Zusman SP. Immediate complications of local anaesthetic administered to 1,007 consecutive patients. *J Am Dent Assoc* 1999; 130(4):496–9.
- Pogrel MA, Thamby S. The etiology of altered sensation in the inferior alveolar, lingual, and mental nerves as a result of dental treatment. *J Calif Dent Assoc* 1999; 27(7):531, 534–8.
- Haas DA, Lennon D. A 21 year retrospective study of reports of paresthesia following local anesthetic administration. *J Can Dent Assoc* 1995; 61(4):319–20, 323–6, 329–30.
- Ruggiero SL. Trigeminal nerve injury and repair. *N Y State Dent J* 1996; 62(8):36–40.
- Harn SD, Durham TM. Incidence of lingual nerve trauma and postinjection complications in conventional mandibular block anesthesia. *J Am Dent Assoc* 1990; 121(4):519–23.
- Pogrel MA, Bryan J, Regezi J. Nerve damage associated with inferior alveolar dental blocks. *J Am Dent Assoc* 1995; 126(8):1150–5.
- Sunderland SS. Nerve injuries and their repair. London: Churchill Livingstone; 1991.
- Seddon SH. Surgical disorders of the peripheral nerves. 2nd ed. London: Churchill Livingstone; 1975.
- Colin W, Donoff RB. Restoring sensation after trigeminal nerve injury: a review of current management. *J Am Dent Assoc* 1992; 123(12):80–5.
- Day RH. Diagnosis and treatment of trigeminal nerve injuries. *J Calif Dent Assoc* 1994; 22(6):48–51, 53–4.
- Assael LA. The nerve under the microscope. *J Oral Maxillofac Surg* 2002; 60(5):483–4.
- Campbell RL, Shamaskin RG, Harkins SW. Assessment of recovery from injury to inferior alveolar and mental nerves. *Oral Surg Oral Med Oral Pathol* 1987; 64(5):519–26.
- Hutchings ML. Nerve damage and nerve blocks. *J Am Dent Assoc* 1996; 127(1):25.
- Stacy GC, Hajjar G. Barbed needle and inexplicable paresthesias and trimus after dental regional anaesthesia. *Oral Surg Oral Med Oral Pathol* 1994; 77(6):585–8.
- Crean SJ, Powis A. Neurological complications of local anaesthetics in dentistry. *Dent Update* 1999; 26(8):344–9.
- Pogrel MA, Kaban LB. Injuries to the inferior alveolar and lingual nerves. *J Am Dent Assoc* 1993; 21(1):50–4.
- Nickel AA Jr. A retrospective study of paresthesia of the dental alveolar nerves. *Anesth Prog* 1990; 37(1):42–5.
- Saray A, Apan A, Kisa U. Free radical-induced damage in experimental peripheral nerve injection injury. *J Reconstr Microsurg* 2003; 19(6):401–6.
- Kirihara Y, Saito Y, Sakura S, Hashimoto K, Kishimoto T, Yasui Y. Comparative neurotoxicity of intrathecal and epidural lidocaine in rats. *Anesthesiology* 2003; 99(4):961–8.
- Takasugi Y, Furuya H, Moriya K, Okamoto Y. Clinical evaluation of inferior alveolar nerve block by injection into the pterygomandibular space anterior to the mandibular foramen. *Anesth Prog* 2000; 47(4):125–9.
- Haas DA, Lennon D. Local anesthetic use by dentists in Ontario. *J Am Dent Assoc* 1995; 61(4):297–304.
- Sandstedt P, Sorensen S. Neurosensory disturbances of the trigeminal nerve: a long-term follow-up of traumatic injuries. *J Oral Maxillofac Surg* 1995; 53(5):498–505.
- Pogrel MA, Schmidt BL, Sambajon V, Jordan RC. Lingual nerve damage due to inferior alveolar nerve blocks: a possible explanation. *J Am Dent Assoc* 2003; 134(2):195–9.
- Zuniga JR, Labanc JP. Advances in microsurgical nerve repair. *J Oral Maxillofac Surg* 1993; 51(1 Suppl 1):62–8.
- Gratt BM, Shetty V, Sair M, Sickles EA. Electronic thermography for the assessment of inferior alveolar nerve deficit. *Oral Surg Oral Med Oral Pathol Oral Radiol Endod* 1995; 80(2):153–60.
- Robinson PP. Observations on the recovery of sensation following inferior alveolar nerve injuries. *Br J Oral Maxillofac Surg* 1988; 26(3):177–89.
- Pogrel MA. The results of microneurosurgery of the inferior alveolar and lingual nerve. *J Oral Maxillofac Surg* 2002; 60(5):485–9.
- Robinson PP, Loescher AR, Smith KG. A prospective, quantitative study on the clinical outcome of lingual nerve repair. *Br J Oral Maxillofac Surg* 2000; 38(4):255–63.

34. Joshi A, Rood JP. External neurolysis of the lingual nerve. *Int J Oral Maxillofac Surg* 2002; 31(1):40–3.
35. Pogrel MA, Maghen A. The use of autogenous vein grafts for inferior alveolar and lingual nerve reconstruction. discussion 988–93. *J Oral Maxillofac Surg* 2001; 59(9):985–8;
36. Pogrel MA, McDonald AR, Kaban LB. Gore-Tex tubing as a conduit for repair of lingual and inferior alveolar nerve continuity defects: a preliminary report. *J Oral Maxillofac Surg* 1998; 56(3):319–21.
37. Robinson PP, Smith KG. A study on the efficacy of late lingual nerve repair. *Br J Oral Maxillofac Surg* 1996; 34(1):96–103.
38. Scrivani SJ, Moses M, Donoff RB, Kaban LB. Taste perception after lingual nerve repair. *J Oral Maxillofac Surg* 2000; 58(1):3–5.
39. Zuniga JR, Meyer RA, Gregg JM, Miloro M, Davis LF. The accuracy of clinical neurosensory testing for nerve injury diagnosis. *J Oral Maxillofac Surg* 1998; 56(1):2–8.
40. Graff-Radford SB, Evans RW. Lingual nerve injury. *Headache* 2003; 43(9):975–83.

DioGuardi
p/u June 2006 p.425
Eng only 4/C



Policy on Advertising

It is important for readers to remember that the Canadian Dental Association (CDA) does not endorse any product or service advertised in the publication or in its delivery bag. Furthermore, CDA is in no position to make legitimizing judgments about the contents of any advertised course. The primary criterion used in determining acceptability is whether the providers have been given the ADA CERP or AGD PACE stamp of approval.

John O'Keefe
1-800-267-6354 ext. 2297
jokeefe@cda-adc.ca