

Fractures of the Supraorbital Rim: Principles and Management

Taylor P. McGuire, BSc, DDS; Petrus P. Gomes, DDS, MSc, PhD;
Cameron M.L. Clokie, DDS, PhD, FRCD(C);
George K.B. Sándor, MD, DDS, PhD, FRCD(C), FRCSC, FACS

Contact Author

Dr. Sándor
Email:
george.sandor@utoronto.ca



ABSTRACT

Dentists may be asked to provide consultations for patients who have sustained trauma to their facial structures. Supraorbital rim fractures, although uncommon, must be recognized and promptly referred to an oral and maxillofacial surgeon or other specialist skilled in the management of facial bone fractures. Supraorbital rim fractures commonly coexist with other craniomaxillofacial injuries, especially with fractures of the anterior table of the frontal sinus. In this article, we review the frequency, management and complications associated with the treatment of supraorbital rim fractures in adults.

A series of 5 cases was reviewed; 4 of the 5 patients were male, with a mean age of 21.6 years (range 17–28 years). All injuries involved the supraorbital rim and the anterior table of the frontal sinus and occurred concurrently with other facial injuries. Treatment ranged from conservative observation to open reduction and internal fixation of the fractures. No associated perioperative or postoperative complications occurred. The follow-up ranged from 6 months to 26 years, with satisfactory subjective esthetic outcomes in all cases.

MeSH Key Words: fractures, bone/diagnosis; fractures, bone/surgery; orbit/injuries

© J Can Dent Assoc 2006; 72(6):537–40
This article has been peer reviewed.

Fractures of the supraorbital region are rare and are frequently associated with high-energy craniomaxillofacial trauma. When displacement of the orbital roof occurs, exploration and precise reconstruction are warranted to limit such ocular complications as exophthalmos, enophthalmos, proptosis, diplopia, restricted ocular movement, altered vision, pain and discomfort.^{1–13} Fractures of the supraorbital rim can result in significant ophthalmologic and cosmetic morbidity (Fig. 1).

Isolated supraorbital rim fractures are rare.^{14,15} However, an estimated 1% to 9% of facial fractures can involve the supraorbital

ridges and the anterior table of the frontal sinus, and many supraorbital rim fractures are associated with other forms of craniomaxillofacial injury.^{1–6,13} The degree of association has been reported to be 95% with fractures of the anterior table or wall of the frontal sinuses, 60% with the orbital rims, 60% with complex injuries of the naso-orbital-ethmoid region, 33% with other orbital wall fractures and 27% with Le Fort level fractures.¹ Many of these patients have multisystem injuries, most of which are neurologic.^{16,17}

Adults who sustain such fractures are generally between 20 and 40 years of age, and the vast majority are male.^{1,2,18} These fractures are

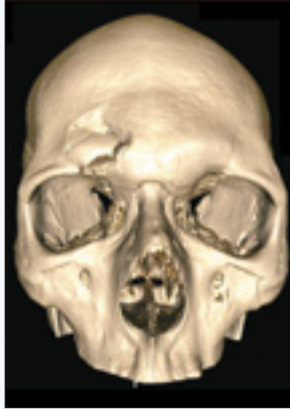

Figure 1: A 3-dimensional computed tomography (CT) image of patient with right supraorbital rim fracture.

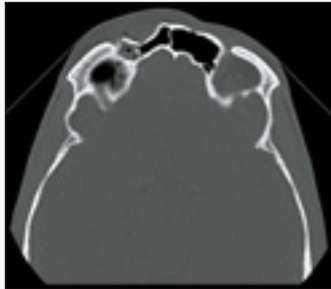


Figure 2a: Axial CT image of patient with right supraorbital rim fracture and concomitant fracture of the anterior table of the frontal sinus.

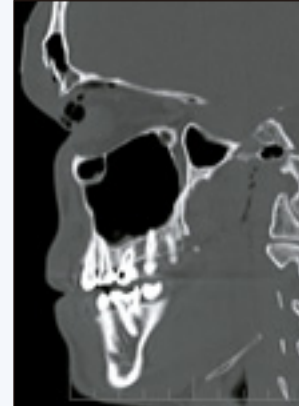

Figure 2b: Sagittal CT image of patient with right supraorbital rim fracture and concomitant fracture of the anterior table of the frontal sinus.

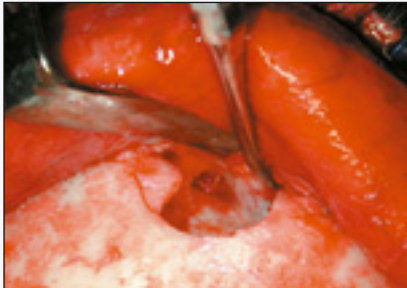


Figure 3: Fractures of the supraorbital rim and anterior table of the frontal sinus exposed through a coronal incision.

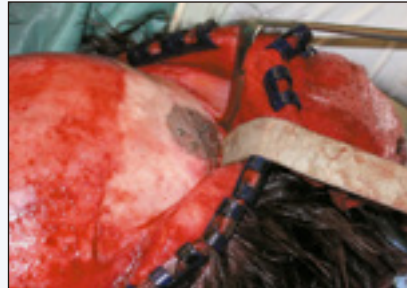

Figure 4: Fractures of the right supraorbital rim and anterior table of the frontal sinus fixed with titanium mesh and 1.0-mm fixation screws.

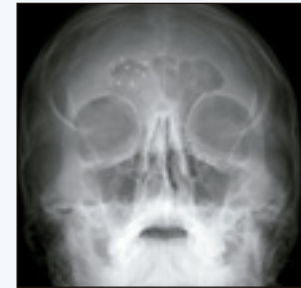

Figure 5: Postoperative Water's view of fracture reduction.

associated with high-energy impacts, motor vehicle collisions being the most frequently reported etiology.^{1,18} Many other causes have been identified, including tire explosions, ruptured garage door springs, chain saws, high-voltage electric shocks, swinging objects and falls from high places.^{1,3,9,10,18,19} Statistical information is unavailable for the frequency of nondisplaced, or isolated, orbital roof fractures, although a few case reports appear in the literature.^{6,11,13}

Patients with supraorbital rim fractures have characteristic physical signs and symptoms.^{1,2,12,18} If they are seen soon after the traumatic episode, then a cosmetic deformity consisting of depression or flattening of the supraorbital ridge can be visualized. Later these injuries may present with intensely turgid periorbital ecchymoses, edema, soft tissue lacerations and paresthesia over the area of distribution of the supraorbital and supratrochlear nerves. If the fracture is displaced, enophthalmos, exophthalmos and proptosis may be noted, along with

diplopia.¹² Ocular discomfort, epiphora, limitation of eye movement, increased scleral show and increased width of the palpebral fissure have all been reported.¹²

A review of the literature reveals no uniform system for the classification of supraorbital rim fractures; most authors rely on descriptive terminology.

A nondisplaced supraorbital rim fracture generally requires no surgical intervention.^{20,21} Treatment of concomitant neurologic or soft tissue injuries may be the only management needed. An orbital roof fracture, with undisplaced supraorbital rim involvement and no frontal sinus fracture, is common in children.²² When the fractured segments are displaced, surgical exploration, reduction and stabilization are indicated. Supraorbital rim fractures frequently involve the frontal sinus. If the anterior table of the frontal sinus and the supraorbital rim are displaced, then operative treatment is required^{14,15} (Figs. 2a and 2b).

A computed tomography (CT) scan can rule out damage to the posterior table of the frontal sinus. If there

Table 1 Demographics and perioperative summary of a series of patients with frontal sinus and supraorbital rim fracture

Patient	Sex	Age (years)	Location of fractures	MOI	Associated injuries	Surgical approach	Hospital stay (days)	Follow-up
AD	F	18	Right SOR + AT	Bicycle fall	Multiple facial lacerations	ORIF via forehead laceration + frontal sinus drain	3	26 years
JK	M	22	Bilateral SOR + AT	Motorcycle accident	Open nasal fracture	ORIF via nasofrontal laceration + frontal sinus drain	3	25 years and 10 months
JL	M	23	Right SOR + AT	Baseball	Proptosis of right globe	ORIF via coronal flap	2	8 months
KF	M	28	Right SOR + AT	Skateboard fall	None	ORIF via coronal flap	2	6 months
LC	M	17	Right SOR + AT + PT	Bicycle fall	SD + right OF/IOR	None	2	6 months

AT/PT = anterior table/posterior table of frontal sinus; IOR = infraorbital rim; MOI = mechanism of injury; OF = orbital floor; ORIF = open reduction internal fixation; SD = subdural hematoma; SOR = supraorbital rim.

is a displaced fracture of the posterior table, then a dural tear is quite possible. However, treatment of such an injury is beyond the scope of this article and must be carried out with a neurosurgeon on the team. If the involvement of the fracture is limited to the anterior table of the frontal sinus, then an assessment of the frontonasal duct is important to assure continued drainage of the frontal sinus after fracture reduction. The patency of the frontonasal duct is important to help prevent the formation of a mucocoele of the frontal sinus, which could result in the formation of a mucopyocoele, a delayed but serious infectious complication.^{22,23} These patients, therefore, require long-term follow-up. In patients who are at high risk of not returning for follow-up evaluation, cranialization of the frontal sinus with complete removal of all mucosal elements may be necessary to eliminate the risk of later mucocoele formation.^{10-13,24,25}

The need for fixation in supraorbital rim fractures depends on the type of fracture encountered. The reduction is often stable once the fragments have been levered into position because of the absence of muscular displacing forces¹⁴ (Fig. 3). Treatment involving the orbital skeleton has evolved considerably in the past century. Closed reduction, external fixators, antral packing and Kirschner wires were all used until open reduction with internal wire fixation was introduced in the 1940s

and became widely adopted by the 1950s.²⁴ The introduction of rigid fixation into craniomaxillofacial fracture management revolutionized the treatment of orbital injuries²⁵ (Figs. 4 and 5).

Patients and Methods

The records of patients treated by the members of the division of oral and maxillofacial surgery between January 1980 and December 2005 were reviewed retrospectively. Those with injuries not involving the orbit were excluded from this analysis.

Results

A total of 5 patients — 4 males and 1 female — with supraorbital involvement are reviewed in this report (Table 1). The mean age at presentation was 21.6 years, with a range of 17–28 years. Two patients fell from bicycles, 1 from a skateboard, another from a motorcycle and 1 patient was struck in the orbit by a baseball. Most injuries involved the right side, although one patient had bilateral fractures. Approaching the supraorbital rim and frontal sinus by a coronal scalp flap, using an incision well above the hairline, or through a pre-existing facial laceration offered wide access with minimal surgical morbidity and satisfactory cosmetic results.

Discussion

This series of patients supports previous observations that this fracture is more common in males than females.^{1,2,18} The fractures in this series seemed to occur as a result of localized trauma and involved the anterior table of the frontal sinus in every case.

The treatment of supraorbital rim fractures is indicated for functional and esthetic reasons.^{14,15} These fractures often require open reduction, as in the case of 4 of the 5 patients in this study. The results of treatment in all 5 patients in this series were satisfactory. No frontal sinus mucocoeles have occurred in these patients to date; however, long-term follow-up is necessary. ❖

THE AUTHORS



Dr. McGuire is chief resident of the division of oral and maxillofacial surgery and anesthesia, Mount Sinai Hospital, University of Toronto, Toronto, Ontario.



Dr. Gomes is Douglas Stoneman scholar and clinical fellow in the division of oral and maxillofacial surgery and anesthesia, University of Toronto, Toronto, Ontario.



Dr. Clokie is professor and head of the division of oral and maxillofacial surgery and anesthesia, University of Toronto, Toronto, Ontario.



Dr. Sándor is clinical director of the graduate program in oral and maxillofacial surgery and anesthesia, Mount Sinai Hospital; coordinator of pediatric oral and maxillofacial surgery, Hospital for Sick Children and Bloorview Kids' Rehab; professor of oral and maxillofacial surgery, University of Toronto, Ontario, and docent, University of Oulu, Finland.

Correspondence to: Dr. George K.B. Sándor, The Hospital for Sick Children, S-525, 555 University Ave., Toronto, ON M5G 1X8.

The authors have no declared financial interests.

References

- Haug RH. Management of the trochlea of the superior oblique muscle in the repair of orbital roof trauma. *J Oral Maxillofac Surg* 2000; 58(6):602–6.
- Sullivan WG. Displaced orbital roof fractures: presentation and treatment. *Plast Reconstr Surg* 1991; 87(4):657–61.
- Penfold CN, Lang D, Evans BT. The management of orbital roof fractures. *Br J Oral Maxillofac Surg* 1992; 30(2):97–103.
- McLachlan DL, Flanagan JC, Shannon GM. Complications of orbital roof fractures. *Ophthalmology* 1982; 89(11):1274–8.
- Schultz RC. Supraorbital and glabellar fractures. *Plast Reconstr Surg* 1970; 45(3):227–33.
- Smith RR, Blount RL. Blowout fracture of the orbital roof with pulsating exophthalmos, blepharoptosis, and superior gaze paresis. *Am J Ophthalmol* 1971; 71:1052–4.
- Horowitz JH, Persing JA, Winn HR, Edgerton MT. The late treatment of vertical orbital dystopia resulting from an orbital roof fracture. *Ann Plast Surg* 1984; 13(6):519–24.
- Bloem JJ, Meulen JC, Ramselaar JM. Orbital roof fractures. *Mod Prob Ophthalmol* 1975; 14:510–2.
- Ma C, Nerad JA. Orbital roof fracture with ocular herniation. *Am J Ophthalmol* 1988; 105(6):700–1.
- Al-Qurainy IA, Dutton GN, Moos KF, Reynolds ST, McMillan N. Orbital injury complicated by entrapment of the superior oblique tendon: a case report. *Br J Oral Maxillofac Surg* 1988; 26(4):336–40.
- McClurg FL Jr, Swanson PJ. An orbital roof fracture causing diplopia. *Arch Otolaryngol* 1976; 102(8):497–8.
- Gabrielli MA, Viera EH, Gabrielli MF, Barbiero RH. Orbital roof blow-in fracture: report of a case. *J Oral Maxillofac Surg* 1997; 55(12):1475–8.
- Ochs MW. Discussion: management of the trochlea of the superior oblique muscle in the repair of orbital roof trauma. *J Oral Maxillofac Surg* 2000; 58(6):606.
- Janigan DT, Stoelting PJ. Fractures of the supraorbital rim. *J Oral Surg* 1980; 38(10):764–70.
- Haug RH, Van Sickels JE, Jenkins WS. Demographics and treatment options for orbital roof fractures. *Oral Surg Oral Med Oral Pathol Oral Radiol Endod* 2002; 93(3):238–46.
- Flanagan JC, McLachlan DL, Shannon GM. Orbital roof fractures: neurologic and neurosurgical considerations. *Ophthalmology* 1980; 87(4):325–9.
- Donahue DJ, Smith K, Church E, Chaddock WM. Intracranial neurological injuries associated with orbital fractures. *Pediatr Neurosurg* 1997; 26(5):261–8.
- Piotrowski WP, Beck-Mannagetta J. Surgical techniques in orbital roof fractures: early treatment and results. *J Craniomaxillofac Surg* 1995; 23(1):6–11.
- Marchau M. Explosion of the orbital roof due to electrical current. *Neurosurgery* 1988; 23(6):769–70.
- Manfre L, Nicoletti G, Lombardo M, Consoli V, Pero G, Albanese V. Orbital "blow-in" fracture: MRI. *Neuroradiology* 1993; 35(8):612–3.
- Schultz RC. Supraorbital and glabellar fractures. *Plast Reconstr Surg* 1970; 45(3):227–33.
- Hirano A, Tsuneda K, Nisimura G. Unusual fronto-orbital fractures in children. *J Craniomaxillofac Surg* 1991; 19(2):81–6.
- Stanley RB Jr, Becker TS. Injuries of the nasofrontal orifices in frontal sinus fractures. *Laryngoscope* 1987; 97(6):728–31.
- Stranc MF, Gustavson EH. Plastic surgery. Primary treatment of fractures of the orbital roof. *Proc R Soc Med* 1973; 66(4):303–4.
- Luhr HG. Orbital fractures. In: Maxillofacial traumatology. Vol. 1. Chicago: Quintessence Publishing; 1982. p. 319–48.