

Transmigration of Impacted Mandibular Canines — Report of 4 Cases

Ajit Auluck, MDS; Archana Nagpal, MDS; Suhas Setty, MDS; Keerthilatha M. Pai, MDS; James Sunny, MDS

Contact Author

Dr. Auluck

Email:
drajitauluck@yahoo.co.in



ABSTRACT

Impacted canines are not uncommon in clinical practice, but intraosseous movement of impacted canines crossing the midline (transmigration) is a rare phenomenon. We report 4 cases of mandibular canine transmigration to emphasize the need to supplement periapical radiographs with a panoramic radiographic examination in patients with over-retained deciduous canines or missing permanent canines.

MeSH Key Words: cuspid/physiopathology; mandible; tooth, impacted/etiology; tooth migration/complications

© J Can Dent Assoc 2006; 72(3)249–52
This article has been peer reviewed.

Pre-eruptive migration of a tooth across the midline is termed transmigration.¹ Transmigration typically affects the mandibular canines, but occurs rarely in maxillary canines as well.¹ Transmigrated canines usually remain impacted and asymptomatic or they ectopically erupt at the midline or on the opposite side of the arch.² Transmigrating teeth can cause pressure resorption of roots or tilting of adjacent teeth^{3,4} and neuralgic symptoms⁴ or these teeth migrate to adjacent structures like the coronoid process⁵ causing pain and discomfort to the patient. We report 4 cases of mandibular canine transmigration to highlight the importance of early detection by panoramic radiographic examination. Early diagnosis with a timely orthodontic or surgical intervention can help dentists preserve the canines, which play an important role, in both esthetics and function, in human dentition.

Case Reports

Case 1

A 25-year-old man reported for postoperative evaluation of a single-tooth implant prosthesis placed in the 43 region 1 year earlier.

The patient had had a mobile tooth 73, which was extracted and an implant was placed (at a different hospital).

A periapical radiograph of the 43 region and a panoramic radiograph were requested. The periapical radiograph showed no abnormalities and adequate marginal bone support. The panoramic radiograph revealed the presence of a canine apical to the mesial aspect of tooth 48 (**Fig. 1**). The migrating canine showed no evidence of resorption or pericoronary radiographic changes suggestive of cystic degeneration. Adjacent teeth appeared normal. The panoramic radiograph revealed bilateral flattening of the posterior slopes as well as superior-medial portions of condyle together with bird-beak-shaped condyles and decreased joint spaces indicative of degenerative joint disease. The patient was asymptomatic; he was informed of the condition and was scheduled for periodic follow-up.

Case 2

A 25-year-old man underwent a panoramic radiographic examination before orthodontic treatment. Teeth 13, 23 and 43 were missing. The radiograph showed that both maxillary

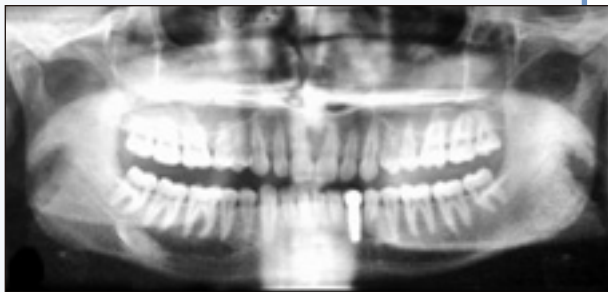

Figure 1: Panoramic radiograph showing the transmigrated tooth 33 apical to the mesial aspect of tooth 48.

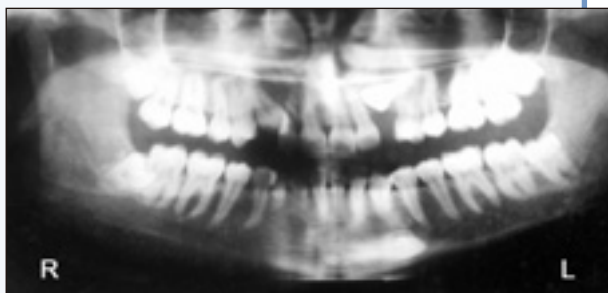

Figure 2: Panoramic radiograph showing transmigrated right canine below the apices of teeth 33 and 34. (Note: The patient was positioned too far back in the machine; thus, the anterior focal trough was not in the tomographic layer when the radiograph was taken.)

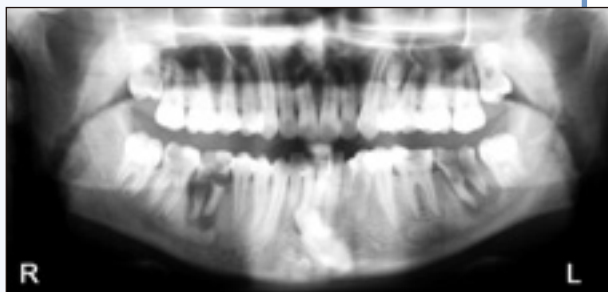


Figure 3: Panoramic radiograph showing impacted tooth 33 that has crossed the midline and is below the apices of the mandibular incisors.

impacted canines as well as an impacted mandibular right canine had crossed the midline. The transmigrated tooth 43 could be seen below the apices of teeth 33 and 34 (Fig. 2).

Case 3

A 20-year-old woman presented with pain in the left mandibular molars over the previous 3 days. A periapical radiograph showed an ill-defined periapical radiolucency, the extent of which could not be completely determined. Subsequently, a panoramic radiograph was obtained for evaluation of the extent of the lesion (Fig. 3). It showed grossly decayed molars with periapical abscess, widening

of the periodontal ligament space and inter-radicular bone loss. It also revealed the presence of an impacted tooth 33 below the apices of the mandibular incisors. Tooth 43 was in place, but tooth 73 was over-retained. Teeth 37 and 46 had gross carious lesions, and significant periapical rarefying osteitis was present in teeth 37, 36, 46 and 47. Tooth 47 also had condensing osteitis. A supernumerary tooth apical to tooth 24 was noted as well.

Case 4

A 40-year-old man presented with pain in the upper right first molar over the previous week. Oral examination revealed a tooth simulating a 43 in the midline; the tooth was rotated and a root stump was evident in the tooth 43 region (Fig. 4a). A periapical radiograph of teeth 44, 43, 42, 41 and 31 region revealed the presence of the over-retained root stump of tooth 83 (Fig. 4b). A second periapical radiograph of teeth 31, 32, 41, 42 and the tooth simulating a 43 at the midline showed a permanent mandibular canine between the mandibular central incisors (Fig. 4c). Tooth 83 did not show any signs of physiologic resorption.

Discussion

Canine impaction is more prevalent in the maxilla than in the mandible, but canine transmigration is more frequent in the mandible.⁶ The mandibular canine is the only tooth in which migration and crossing of the midline has been documented.^{1-3,7} The larger cross-sectional area of the anterior mandible compared with the anterior maxilla may be a reason for the higher frequency of mandibular canine transmigration.⁶ Transmigration of maxillary canines is uncommon due to the shorter distance between the roots of maxillary incisors and the floor of the nasal fossa and restriction of the path of tooth movement by the roots of adjacent teeth, the maxillary sinus and the mid-palatal suture, which act as a barrier.³ In the first 3 cases described above, impacted mandibular canines transmigrated. In case 3, a maxillary canine was impacted but did not transmigrate. In case 4, a transmigrated canine had erupted in the midline.

Studies have suggested that transmigration of canines is a rare phenomenon with an incidence of about only 0.31%.⁴ Mupparapu⁷ reported an incidence of 1.5% for Type 4 canine transmigration. Transmigration of canines has been reported more frequently in females than males in the ratio 1.6:1.⁸ The mandibular left side is affected more than the right side.⁹ The etiology of transmigration is unknown; however, abnormal displacement of the tooth bud or deviation during development is the most commonly accepted explanation.¹⁰

Javid and others¹⁰ suggest that the conical crown shape and long root of the mandibular canine aid in transmigration. The migratory passage of the canine through the mandible is in the direction of its long axis

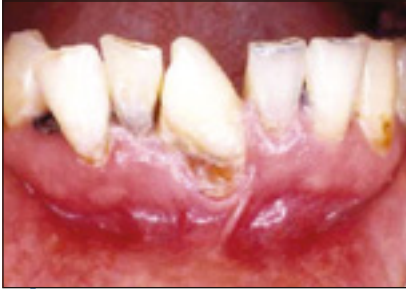

Figure 4a: Permanent right mandibular canine in the midline.

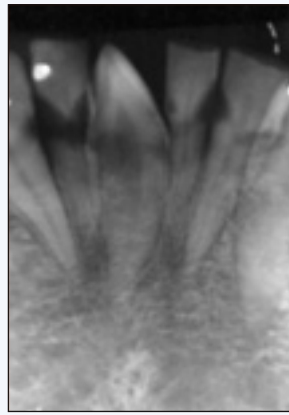


Figure 4b: Periapical radiograph showing permanent right mandibular canine in the midline.

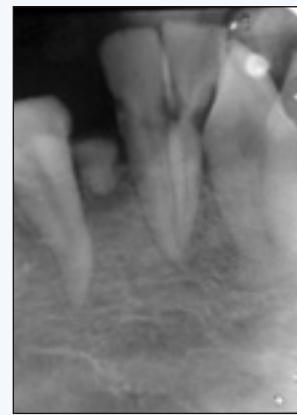

Figure 4c: Periapical radiograph showing the over-retained tooth 83.

with the tip of the crown leading the way.⁹ The movement takes place along the path of least resistance.^{4,9,11} The crown deviates to a more horizontal position and an abnormally strong eruptive force directs it through the dense mandibular symphysis.¹² Other local and pathologic factors implicated in the etiology of transmigration include premature loss of primary teeth and subsequent occupation of the space by adjacent teeth, unfavourable alveolar arch length, discrepancies in tooth size, fractures with displacement of tooth buds, odontomas and cysts.^{4,11,12} The 3 cases of transmigration of impacted mandibular canines and 1 case of erupted transmigrated mandibular canine we report here had no associated pathology. In the absence of previous clinical and radiographic records, the exact cause of the transmigration could not be determined.

Javid and others¹⁰ propose that transmigration should be considered when half the length of the crown crosses the midline. Recently, it has been suggested that it is not the distance of migration after crossing the midline that is important but rather the tendency of canines to cross the midline, which is significant as the distance can vary according to the stage of transmigration.^{6,12} In 3 of the cases the crowns had crossed the midline and, in the first 2 cases, the impacted mandibular canines had even migrated a significant distance on the contralateral side.

Mupparapu⁷ proposed a classification of mandibular canine transmigration based on the migratory pattern and position of the canines in the jaw: Type 1 for a canine impacted mesio-angularly across the midline, labial or lingual to the anterior teeth; Type 2 for a canine horizontally impacted near the lower border of the mandible inferior to the apices of the incisors; Type 3 for a canine erupting on the contralateral side; Type 4 for a canine horizontally impacted near the inferior border of the opposite side; and Type 5 for a canine positioned vertically in the midline

with the long axis of the tooth crossing the midline. Our first 2 cases are Type 4, the third case is a Type 2 variant and the fourth, a Type 5 variant.

The absence or delayed eruption of permanent mandibular canines in the arch or over-retained primary canines are common clinical findings suggestive of impacted or transmigrated canines.^{4,11} In cases of impacted mandibular canines where periapical radiographs fail to detect any abnormality (with no history of extraction), transmigration of canines should be suspected. These canines lie horizontally below the inferior alveolar canal or migrate toward the midline and, as a result, may not be visible in periapical radiographs.^{9,12} This emphasizes the need for a panoramic radiograph. In cases 1 and 2, transmigration was only detected on panoramic radiographs.

Even though the teeth have transmigrated to the contralateral side, they maintain their nerve connection to the originating side.⁹ Therefore, it is important to anesthetize the nerve on the originating side. One case report described a patient who had severe pain during extraction of the transmigrated canine when the contralateral inferior alveolar nerve was not anesthetized.¹³

Treatment options proposed for transmigrated mandibular canines are surgical removal, transplantation and surgical exposure with orthodontic alignment.¹¹ Surgical extraction is the most favoured treatment.¹¹ If the patient is symptomatic and has any associated abnormalities, such as a developing apical cyst, neuralgia, resorption of an adjacent tooth root or displacement of teeth, then surgical extraction should be planned immediately. If the patient is asymptomatic, the transmigrated canine can be left in place^{11,14}; however, regular follow-up with radiographs is required to monitor movement of these teeth.

If the mandibular incisors are in a normal position and space for the transmigrated canine is sufficient, transplantation may be undertaken.¹¹ Howard¹⁵ transplanted a transmigrated canine when there was enough space to accommodate the tooth. Surgical exposure with orthodontic realignment can also be done for labially impacted transmigrated canine.¹⁶ However, if the crown of the transmigrated canine moves past the opposite incisor area or if the apex is seen to have migrated past the apex of the adjacent lateral incisor, it might be mechanically impossible to bring the tooth back into place. In such cases, extraction is preferred.¹²

In cases 1 and 2, the canines had migrated to the opposite molar and premolar regions, respectively. But as the patients were asymptomatic, extraction was deferred and patients were kept on periodic recall. Case 3 was referred for orthodontic consultation but was lost for follow-up. As for the patient in case 4, he was not willing to undergo any treatment for the malpositioned tooth.

Conclusions

The presence of an over-retained mandibular deciduous canine or missing permanent canines should always be clinically and radiographically investigated. An intra-oral periapical radiograph may not be sufficient to detect transmigration except in cases where the transmigrated tooth has erupted and should be supplemented by a panoramic radiograph. Before extraction, care must be taken to administer proper anesthesia on the side from which the transmigrated tooth originated. ❖

2. Kuflinec MM, Shapira Y, Nahlieli O. A case report. Bilateral transmigration of impacted mandibular canines. *J Am Dent Assoc* 1995; 126(7):1022-4.
3. Costello JP, Worth JC, Jones AG. Transmigration of permanent mandibular canines. *Br Dent J* 1996; 181(6):212-3.
4. Alaejos-Algarra C, Berini-Aytes L, Gay-Escoda C. Transmigration of mandibular canines: report of six cases and review of the literature. *Quintessence Int* 1998; 29(6):395-8.
5. Okada H, Miyake S, Toyama K, Yamamoto H. Intraosseous tooth migration of impacted mandibular premolar: computed tomography observation of 2 cases of migration into the mandibular neck and the coronoid process. *J Oral Maxillofac Surg* 2002; 60(6):686-9.
6. Aydin U, Yilmaz HH, Yildirim D. Incidence of canine impaction and transmigration in a population. *Dentomaxillofac Radiol* 2004; 33(3):164-9.
7. Mupparapu M. Patterns of intra-osseous transmigration and ectopic eruption of mandibular canines: review of literature and report of nine additional cases. *Dentomaxillofac Radiol* 2002; 31(6):355-60.
8. Peck S. On the phenomenon of intraosseous migration of nonerupting teeth. *Am J Orthod Dentofacial Orthop* 1998; 113(5):515-7.
9. Shapira Y, Kuflinec MM. Intrabony migration of impacted teeth. *Angle Orthod* 2003; 73(6):738-43.
10. Javid B. Transmigration of impacted mandibular cuspids. *Int J Oral Surg* 1985; 14(6):547-9.
11. Camilleri S, Scerri E. Transmigration of mandibular canines — a review of the literature and a report of five cases. *Angle Orthod* 2003; 73(6):753-62.
12. Joshi MR. Transmigrant mandibular canines: a record of 28 cases and retrospective review of the literature. *Angle Orthod* 2001; 71(1):12-22.
13. Shanmuhasuntharam P, Boon LC. Transmigration of permanent mandibular canines. Case report. *Aust Dent J* 1991; 36(3):209-13.
14. Abbott DM, Svirsky JA, Yarborough BH. Transposition of permanent mandibular canine. *Oral Surg Oral Med Oral Pathol* 1980; 49(1):97.
15. Howard RD. The anomalous mandibular canine. *Br J Orthod* 1976; 3(2):117-21.
16. Wertz RA. Treatment of transmigrated mandibular canines. *Am J Orthod Dentofacial Orthop* 1994; 106(4):419-27.

THE AUTHORS



Dr. Auluck is an assistant professor in oral medicine and radiology at the Manipal College of Dental Sciences, Mangalore, India.

Dr. Nagpal is a senior lecturer, department of oral medicine and radiology, Institute of Dental Studies and Technology, Modinagar, Uttar Pradesh.

Dr. Setty is a reader at the Manipal College of Dental Sciences, Manipal, India.



Dr. Pai is a professor and head of oral medicine and radiology at the Manipal College of Dental Sciences, Manipal, India.

Dr. Sunny is an assistant professor in the department of orthodontics, Manipal College of Dental Sciences, Manipal, India.

Correspondence to: Dr. Ajit Auluck, Department of Oral Medicine and Radiology, Manipal College of Dental Sciences, Mangalore, Light House Hill Road, Mangalore – 576104, Karnataka, India.

The authors have no declared financial interests.

References

1. Aydin U, Yilmaz HH. Transmigration of impacted canines. *Dentomaxillofac Radiol* 2003; 32(3):198-200.