

# Management of a Patient with an Accessory Maxilla and Congenital Facial Fistula

- Vesa T. Kainulainen, DDS, EHL, PhD •
- George K.B. Sándor, MD, DDS, PhD, FRCD(C), FRCSC, FACS •
- Douglas W. Stoneman, DDS, FRCD(C) •

## A b s t r a c t

*Although accessory jaws are a rare occurrence, the presence of such accessory tissue may cause some bothersome symptoms. This case report helps identify these unusual developmental lesions so that dentists can refer such patients for definitive care and management.*

**MeSH Key Words:** child; dental fistula/radiography; maxilla/abnormalities; tooth supernumerary/radiography

© J Can Dent Assoc 2005; 71(3):161-3  
This article has been peer reviewed.

Developmental aberrations may result in the formation of supernumerary or extra structures. Polydactily or extra fingers or toes and supernumerary teeth are examples of such developmental duplications. Accessory or supplementary jaws are duplicated portions of jaws or entire jaws, with or without teeth.<sup>1</sup> In the case of the maxilla, such accessory jaws are called distomus.<sup>2,3</sup> Distomus formation is extremely rare.<sup>2</sup> Accessory jaws may be associated with the formation of an accessory rudimentary or vestigial mouth.<sup>1</sup> Reports indicate that distomus has been observed more commonly in association with lateral facial clefts.<sup>2</sup> Congenital facial clefts, which have been classified by Tessier,<sup>4</sup> may occur where embryologic processes fuse. The most common facial clefts are cleft lip and palate; the prevalence of cleft lip with or without cleft palate in the largest study to date is 1.2 per 1,000 live births.<sup>5</sup> The incidence of lateral facial clefts in various series ranges from 0.3% to 0.67% of all facial clefts.<sup>5,6</sup> Facial clefts associated with duplication of various oral structures have also been reported.<sup>7-11</sup> Stoneman<sup>1</sup> and DeGurse and others<sup>2</sup> have reported cases of a congenital facial fistula with an accessory maxilla and teeth.

This article reports the management, over 9 years, of a patient with an accessory maxilla with supernumerary teeth and a congenital facial fistula, who required treatment due to increasingly bothersome symptoms.

## Case Report

An 8-year-old boy was referred for assessment of a fistula that occasionally drained milk-like fluid from an opening on the left nasolabial groove of the face. The parents stated that this drainage had been present since birth. The patient had been previously diagnosed as having an incomplete facial cleft. Serial panoramic radiographs and a computed tomography (CT) scan revealed the progressive development of first 2, then 3 tooth-like structures in the left cheek in a cavity with a fluid-filled lumen. A diagnosis of odontoma was dismissed, on the basis of the appearance and position of the lesion. Rather the lesion was thought to resemble an accessory maxilla. The past medical history was otherwise unremarkable.

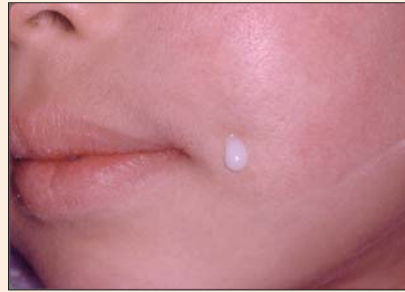The patient was followed regularly with semi-annual visits over the next 7 years. A creamy-white milk-like fluid was initially expressible by palpation of a dimple of the left cheek in the nasolabial groove (Fig. 1). The volume of the drainage progressively increased over the years of follow-up, such that each time the patient smiled, he expressed the fluid spontaneously onto his cheek. This steadily increasing spontaneous drainage became distressing to the patient, to the point of being socially unacceptable. Bacterial culture and sensitivity testing of the facial discharge revealed normal skin flora with a scant growth of coagulase-negative *Staphylococcus* species. Surgery had been delayed at the request of the boy's parents. At the age of 15 years, the

patient had a fistula on the left cheek approximately 3 cm lateral to the left oral commissure. It was secreting spontaneously or when the left cheek was rubbed.

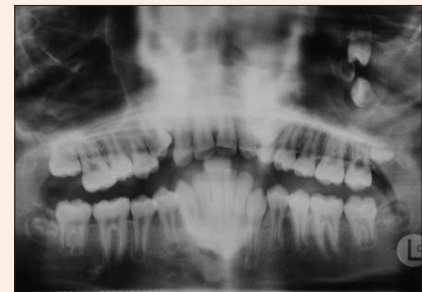
Radiographic examination revealed a 4-cm-wide round cavity with 3 supernumerary teeth in the left maxillary sinus area (Fig. 2). In panoramic radiographs taken 6 years earlier, there were 2 premolar-like supernumerary teeth. A CT scan showed a cavity with a sharp delineation from the maxillary bone and its zygomatic process. The lesion extended from the orbital floor to the zygomatic buttress area. It did not extend into the inferior part of the left maxillary sinus or into the maxillary alveolar process. Otherwise the whole sinus was full of accessory tissue. The teeth within the lesion were attached to the bony walls of the cavity (Fig. 3a). This bony cavity was filled with fluid and connected to a cavity in the soft tissues of the left cheek (Fig. 3b).

Surgery was performed under general anesthesia. A plastic catheter was threaded into the fistula and methylene blue dye was injected into the catheter to help delineate the accessory structures connected to the fistula (Fig. 4). A vestibular incision was used to expose the entire anterior maxilla. Bone over the soft tissue capsule was removed (Fig. 5). The fistula and the soft tissues surrounding the blue-stained structures in the left cheek were removed in 1 piece. The teeth and the bony cavity, which contained a brownish liquid, were removed in a separate piece. Care was taken not to damage the parotid duct and branches of the facial nerve. The specimens were sent for histopathologic evaluation (Fig. 6).

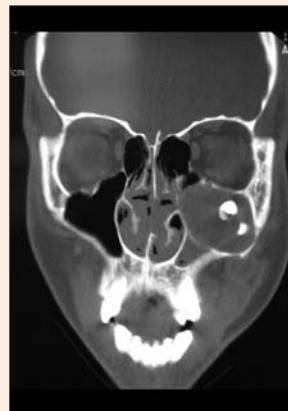Histologic sections revealed bone, developing teeth and a stratified squamous epithelium lining the lumen of the bony and soft-tissue cavities. Postoperative healing was uneventful and neither the lesion nor the fistula has shown any clinical or radiographic signs of recurrence in over 3 years of follow-up (Fig. 7).



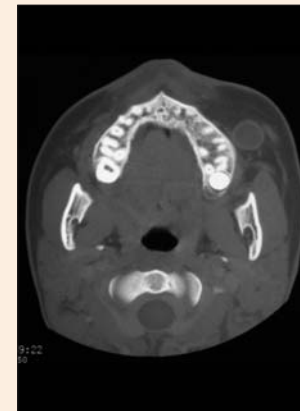
**Figure 1:** Drainage of a milk-like fluid from the left nasolabial groove.



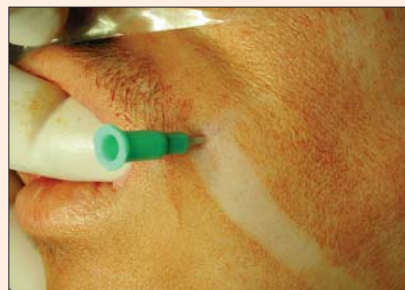**Figure 2:** Preoperative panoramic radiograph showing 3 supernumerary teeth developing in a bony cavity in the left maxillary sinus.



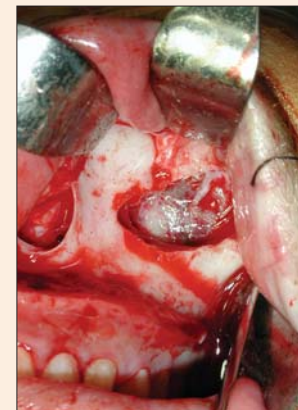**Figure 3a:** Computed tomography image (coronal view) showing the lesion occupying most of the left maxillary sinus.



**Figure 3b:** Computed tomography image (axial view) showing the lumen of the soft-tissue lesion located lateral to the anterior maxillary wall.



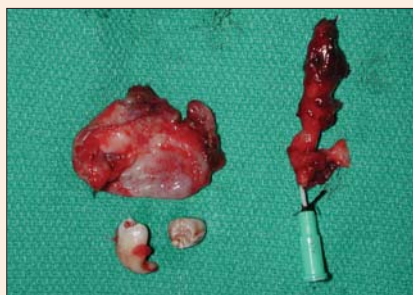**Figure 4:** A catheter is threaded through the cutaneous opening of the fistula into the lumen of the lesion in the left cheek.



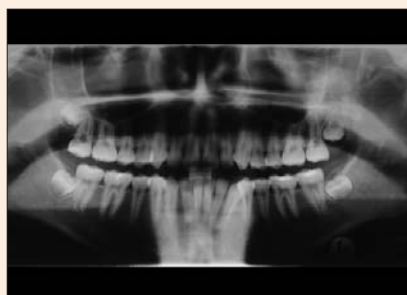**Figure 5:** The anterior wall of the left maxilla is exposed and removed. A separate bony wall is removed to gain access to the bony cavity of the lesion.

## Discussion

This case report presents the long-term management and closely supervised follow-up of a congenital facial fistula with an accessory maxilla and teeth. The diagnosis of incomplete facial cleft had been suggested when the patient was 6 years of age. Because the only complaint was a fistula



**Figure 6:** Teeth with the excised bony and soft-tissue specimens.



**Figure 7:** After 3 years of follow-up, a panoramic radiograph shows a normally pneumatized left maxillary sinus with no signs of recurrence.

that was occasionally draining, the parents opted for long-term observation. The drainage progressively worsened until the patient found it intolerable and requested removal of the lesion. Serial assessments were conducted to ensure that the patient was not lost to follow-up and that the related structures near the lesion were growing and developing normally.

The development of an accessory jaw is very rare. The lesion may occur as a mass of bone containing teeth or as a complete jaw.<sup>1,2,7-11</sup> Stoneman<sup>1</sup> and DeGurse and others<sup>2</sup> have suggested that some facial fistulas are vestiges of facial clefts. In this case, in addition to the accessory jaw tissue, a fistula connected the skin to a separate lumen or rudimentary mouth in the cheek. The management of such lesions must be guided by the symptoms and their potential to interfere with the development of surrounding structures. The timing of their removal depends on these 2 factors and the progressive development of bothersome symptoms. Dentists can contribute to the management of such lesions by identifying them and referring the patient for definitive management. ♦

## References

1. Stoneman DW. Congenital facial fistula with formation of accessory bone and teeth. Report of a case. *Oral Surg Oral Med Oral Pathol* 1978; 45(1):150-4.
2. DeGurse K, Chung H, Pharoah M. Facial dimple with accessory bone and teeth. *Dentomaxillofac Radiol* 1995; 24(2):135-8.
3. Worth HM. Principles and practice of oral radiologic interpretation. Chicago (IL): Year Book Medical Publishers; 1963. p 114-5.
4. Tessier P. Anatomical classification of facial, cranio-facial and latero-facial clefts. *J Maxillofac Surg* 1976; 4(2):69-92.
5. Cooper ME, Stone RA, Liu Y, Hu DN, Melnick M, Marazita ML. Descriptive epidemiology of nonsyndromic cleft lip with or without cleft palate in Shanghai, China, from 1980 to 1989. *Cleft Palate Craniofac J* 2000; 37(3):274-80.
6. Fogh-Andersen P. Rare clefts of the face. *Acta Chir Scand* 1965; 129:275-81.
7. Pitanguy I, Franco T. Nonoperated facial fissures in adults. *Plast Reconstr Surg* 1967; 39(6):569-77.
8. Smylski PT. Accessory jaw bones; a report of a case. *J Oral Surg Anesth Hosp Dent Serv* 1952; 10(1):70-4.
9. Chowdhury SR, Roy A. Duplication of the upper lip and maxilla. *Br J Plast Surg* 1991; 44(6):468-9.
10. Avery JK, Hayward JR. Case report: duplication of oral structures with cleft palate. *Cleft Palate J* 1969; 6:506-15.
11. Ball IA. Klippel-Feil syndrome associated with accessory jaws (distomus). *Br Dent J* 1986; 161(1):20-3.



*Dr. Kainulainen is a former fellow in oral and maxillo-facial surgery, The Hospital for Sick Children and University of Toronto, Toronto, Ontario, and is currently an assistant professor in oral and maxillofacial surgery, University of Oulu, Oulu, Finland.*



*Dr Sándor is an associate professor and director, graduate program in oral and maxillofacial surgery and anesthesia, University of Toronto, and the coordinator of oral and maxillofacial surgery at The Hospital for Sick Children and Bloorview MacMillan Children's Centre, Toronto, Ontario, and docent in oral and maxillofacial surgery, University of Oulu, Oulu, Finland.*



*Dr. Stoneman is deceased; he was professor emeritus in oral radiology at the University of Toronto, and consultant oral radiologist at The Hospital for Sick Children, Toronto, Ontario.*

*Correspondence to: Dr. George K.B. Sándor, The Hospital of Sick Children, S-527, 555 University Ave., Toronto ON M5G 1X8. E-mail: [george.sandor@utoronto.ca](mailto:george.sandor@utoronto.ca).*

*The authors have no declared financial interests.*