

Clinical Showcase

With this issue, JCDA introduces *Clinical Showcase*, a series of pictorial essays that focus on the technical art of clinical dentistry. This new section features step-by-step case demonstrations of clinical problems encountered in dental practice. If you would like to propose a case or recommend a clinician who could contribute to *Clinical Showcase*, contact editor-in-chief Dr. John O'Keefe at jokeefe@cda-adc.ca.

There Is No Age Limit for Rejuvenative Dentistry

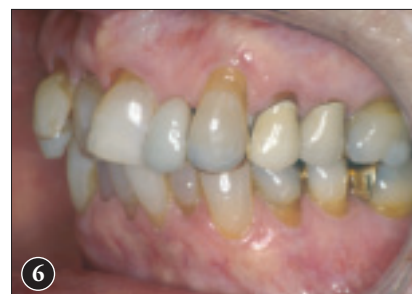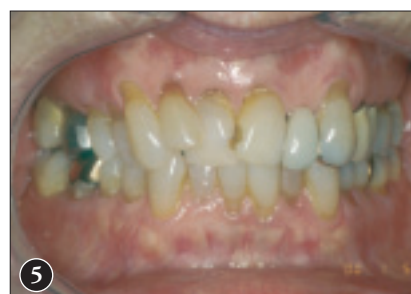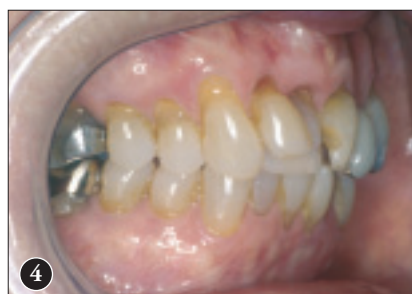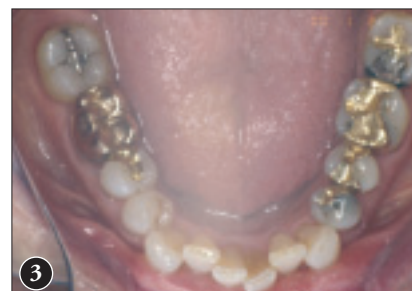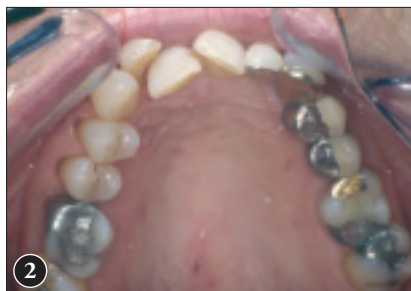Eric VanGorder, BSc, DDS

An 80-year-old woman presented to my office, wishing to correct a lifelong esthetic complaint. She had always been disturbed by the severe crowding and overlap in the maxillary anterior sextant. However, she felt this was unabashed vanity on her part and had accepted this condition, until now.

Options were presented for the correction of the misalignment of the anterior teeth. An orthodontic

consultation provided necessary input, but the timeline required for treatment with braces was not consistent with the patient's wishes. She agreed to have the endodontically treated teeth 16 and 26 restored and to replace the failing (50-year-old!) cantilever bridge on teeth 22 and 23 and the porcelain-fused-to-metal crown on tooth 24 with a 3-unit cantilevered fixed prosthesis.

Figures 1 to 6: Diagnostic photos taken at the first exam in January 2000. The patient wished to have the crowding in the maxillary anterior sextant corrected.

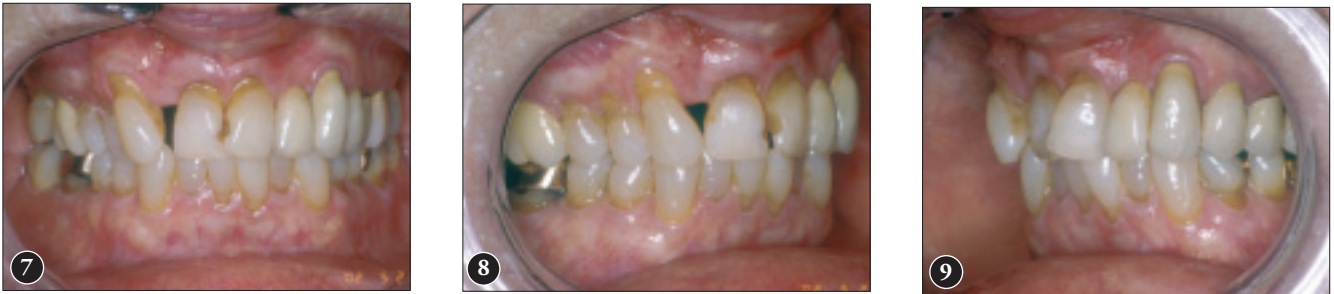

Two and a half years later, the patient again expressed a desire to improve the esthetics of her smile. She was insistent that she would accept a lesser result than what could be achieved with orthodontics, preferring a treatment that required a shorter time frame.

With the help of the laboratory technician, models were used to determine the space increase needed to correct rotations and the degree of tooth reduction required to ensure

an emergence profile that would achieve an optimal esthetic result without affecting periodontal health. It was agreed that the removal of tooth 12 would be a suitable first step for the esthetic alteration to come. Improvement was marginal, however, and it was determined that neither direct resin veneers nor porcelain veneers would create a satisfactory result. Tooth 12 had to be replaced.

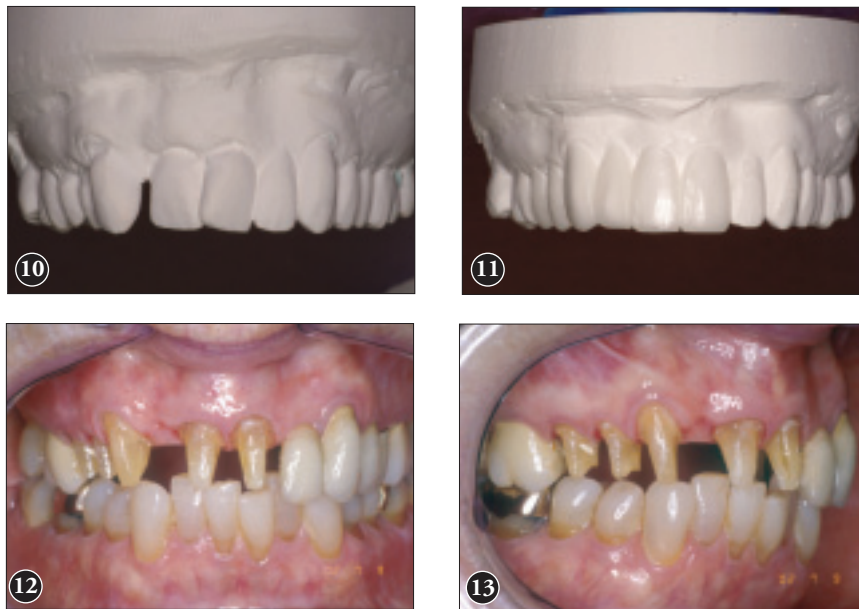
Figures 7 to 9: Intraoral view of healed soft tissue after removal of tooth 12 (**Fig. 7**). The porcelain-fused-to-metal crowns on tooth 16 (**Fig. 8**) and tooth 26 and the 3-unit cantilevered fixed prosthesis (**Fig. 9**) had been placed earlier.



Study models were redone and a diagnostic wax-up presented to the patient for her approval. The primary concern at this point was the degree of tooth reduction that was needed and the potential impact on pulpal health.

Calcific degeneration of the root canal space, resulting from extensive cervical abrasions, made it possible to do a coronal reduction of teeth 11, 13, 14, 15 and 21 without root canal therapy.

Figures 10 to 13: A study model was used (**Fig. 10**) to prepare a diagnostic wax-up (**Fig. 11**). Coronal reduction was performed to prepare the teeth for provisional restorations (**Figs. 12 and 13**).

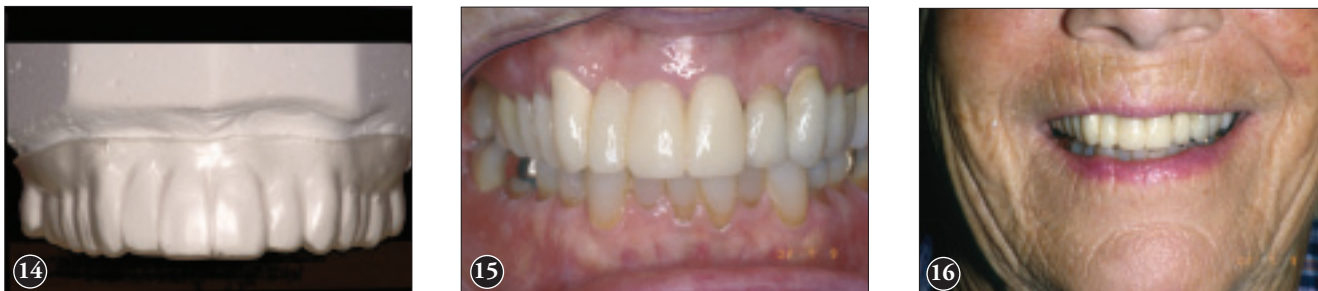

Clinical Showcase

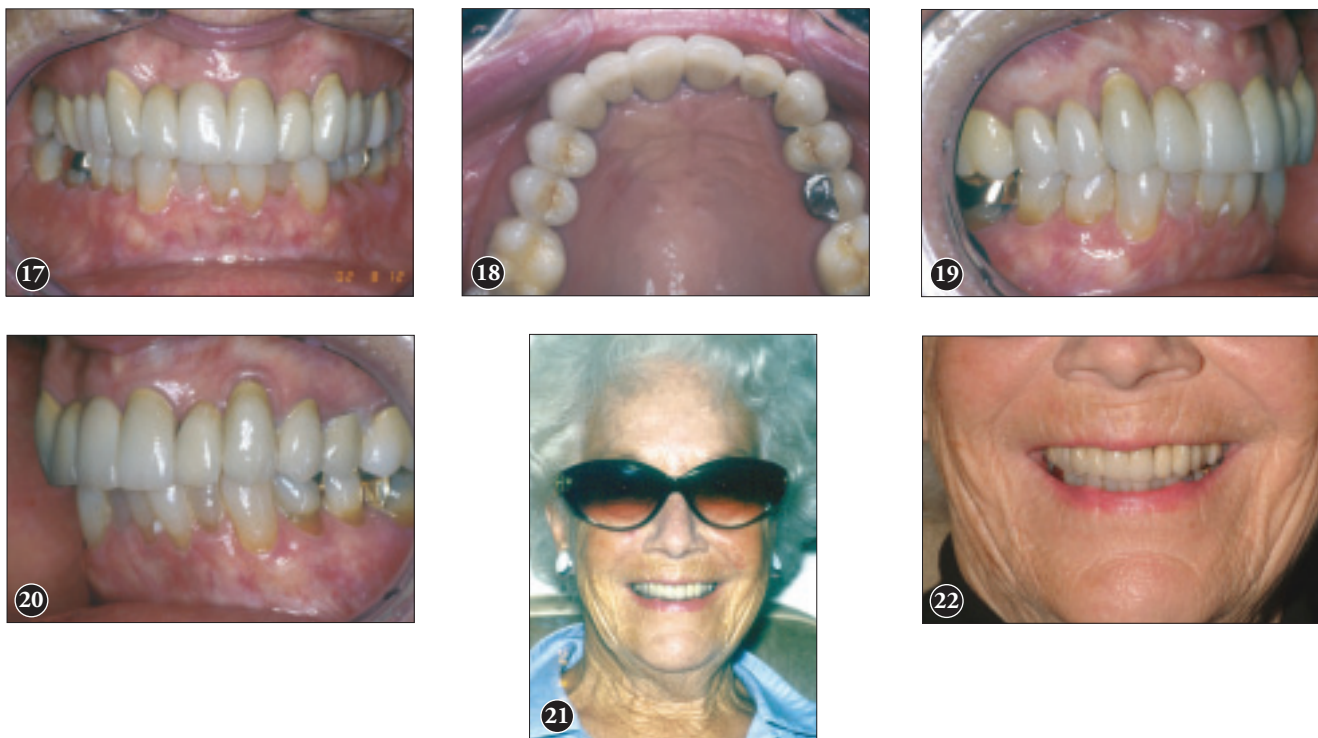Direct provisional restorations were made using an acetate shell constructed on a solid model of the diagnostic wax-up. Final impressions were delayed for several weeks to evaluate pulpal response and receive patient feedback on the esthetics of the provisional restorations. This informa-

tion was communicated to the laboratory and the final restorations were completed. Teeth 14 and 15, which were lingually inclined, were “repositioned” labially with individual porcelain-fused-to-metal crowns.

Figures 14 to 16: A solid model of the diagnostic wax-up was used to construct an acetate shell (Fig. 14). Figures 15 and 16 show intraoral and extraoral views of the provisional restorations.



Figures 17 to 22: The patient returned for follow-up exams in August 2002 (Figs. 17 to 21) and June 2003 (Fig. 22).



Two important lessons were learned from this case: it is possible to prosthetically correct an occlusal problem that may at first appear to require orthodontic treatment, and never prejudge a patient's treatment desires based on appearance or age. ♦

Acknowledgements: Many thanks to the registered dental technicians at Ardent Laboratories for their assistance in this case and to Dr. Ken Serota for his help in the preparation of this manuscript.

Dr. VanGorder is a dental surgeon who maintains a private practice in Mississauga, Ontario.

The views expressed are those of the author and do not necessarily reflect the opinion or official policies of the Canadian Dental Association.