

Rapid Palatal Expansion in the Young Adult: Time for a Paradigm Shift?

• Dan A. Stuart, DDS •

• William A. Wiltshire, BChD, BChD (Hons), MDent, MChD, DSc •

A b s t r a c t

A 19-year-old man presented for correction of a malocclusion that included a transverse maxillary deficiency. The patient was informed that he required orthognathic surgery to expand his upper jaw and correct his malocclusion, but he refused surgical expansion. Recent evidence indicates that rapid palatal expansion can be used without surgery in young adults; the decision was therefore made to treat the patient nonsurgically. Rapid palatal expansion of the maxillary arch was accomplished by means of a Hyrax appliance, with post-treatment radiographs revealing an opening of the midpalatal suture. The belief still persists among some clinicians that young adult patients require orthognathic surgery for palatal expansion, despite recent evidence supporting a nonsurgical approach after closure of the midpalatal suture.

MeSH Key Words: adult; dental arch/abnormalities; palatal expansion technique

© J Can Dent Assoc 2003; 69(6):374-7
This article has been peer reviewed.

Maxillary width deficiencies normally do not present an orthodontic challenge if they are detected before or during the adolescent growth spurt. Correction of these deficiencies with a maxillary rapid palatal expander, first popularized more than 40 years ago by Haas,¹ yielded well-controlled and predictable results. However, once patients are past their growth spurt, which occurs at about the age of 12–13 years in females and 14–15 years in males,² the protocol for rapid palatal expansion (RPE) is not quite so clear. According to some authors, expansion of the maxillary arch in mature patients is not feasible.^{3–5} Proffit³ reports that “by the late teens, interdigation and areas of bony bridging across the suture develop to the point that maxillary expansion becomes impossible,” a belief based on Melsen’s⁶ study on histological suture appearance. Other recent evidence suggests that it is indeed possible to successfully expand the palate in young adults.^{7–11} This article reviews the recent literature on nonsurgical RPE in young adults and provides a rationale for using this approach based on a case the authors successfully treated by RPE alone.

Patients and parents are sometimes reluctant to accept treatment plans that incorporate surgically assisted RPE, because they are concerned about the inherent risks of

surgery and the gravity of the procedure. Clinicians are thus faced with a dilemma when treating patients after the palatal sutures have closed. The palatal sutures reportedly close as early as when a patient reaches 12–13 years of age.¹² Furthermore, other sutures adjacent to the midpalatal suture reportedly are too rigid to expand past the late teens.^{3,4,6,13} A popular treatment option from early adulthood onwards is the LeFort 1 osteotomy, or osteotomies of the palatal midline and the lateral aspects of the maxillae combined with orthodontics. However, many patients decline surgery, and until recently, no other alternative was readily available for late teens and young adults. The following case report presents the authors’ experience of treating one patient with maxillary deficiency using nonsurgical RPE.

Case Report

A young adult male (19 years, 7 months of age) presented for the orthodontic correction of a malocclusion. Clinical examination and orthodontic records revealed a skeletal deficiency in the transverse dimension of the maxillary arch. The patient had been informed that surgery would most likely be required to expand the palate, but he had concerns regarding this approach and refused the surgical option. Given the

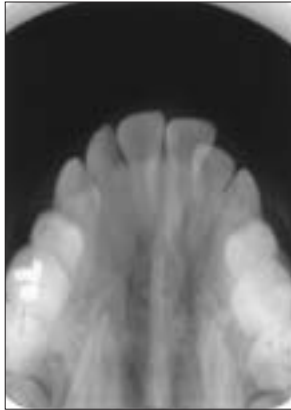


Figure 1: Pretreatment radiograph of the midpalatal suture.

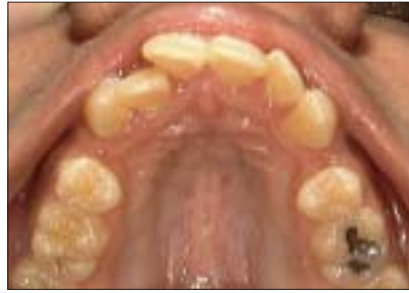

Figure 2: Pretreatment occlusal view. The patient had his first premolars extracted 2 years before being evaluated by the authors.

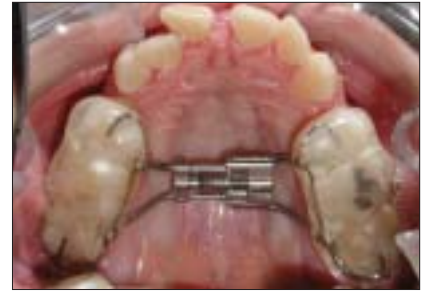

Figure 3: Occlusal view of diastema between the central incisors after 3 weeks of rapid palatal expansion.

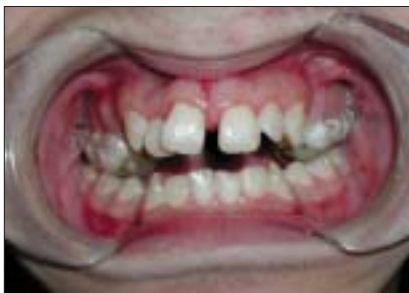

Figure 4: Frontal view of diastema after 3 weeks of rapid palatal expansion.

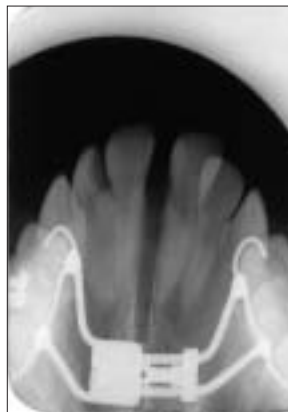


Figure 5: Post-treatment radiograph revealing an opening of the midpalatal suture following rapid palatal expansion.

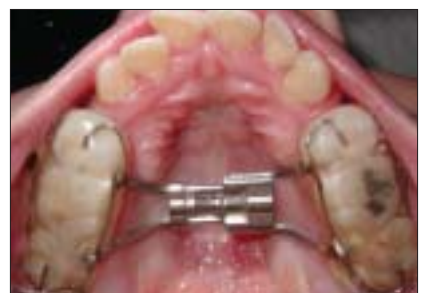

Figure 6: Palatal view of self-closed diastema due to transseptal fibre forces.

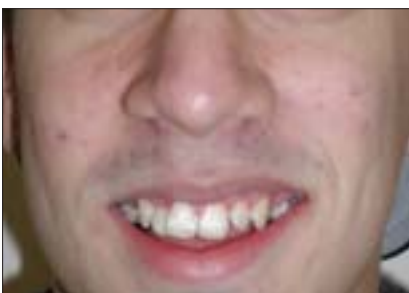

Figure 7: Frontal view of self-closed diastema due to transseptal fibre forces.

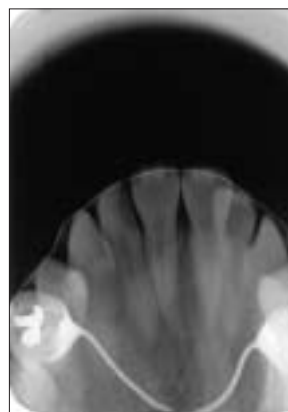


Figure 8: Occlusal radiograph taken 6 months after rapid palatal expansion. The molar width has been maintained and new bone has formed at the midpalatal suture.

patient's reluctance to undergo surgery, it was decided that nonsurgical RPE should be performed before placing full-fixed orthodontic appliances. The patient was informed of all possible sequelae, risks and benefits, including possible termination of the nonsurgical treatment and use of surgical expansion should the nonsurgical RPE procedure fail.

The expansion measured on the Hyrax appliance was approximately 1.5 mm at the expansion screw. No midline diastema was present and the patient did not report any pain. The patient was then instructed to continue turning the expansion screw twice a day, once in the morning and once in the evening for the next 5 days. One week later the

As part of a thorough clinical assessment, an anterior maxillary occlusal radiograph (Fig. 1) was taken to record the midpalatal suture before treatment (the corresponding occlusal view is shown in Fig. 2). A maxillary Hyrax appliance (Dentaurum, Germany) was designed for the patient, with full acrylic coverage of the maxillary posterior teeth to maintain the vertical dimension and prevent cuspal interferences during the expansion procedure. The patient was instructed to turn the screw only once a day for the first few days to loosen the sutural juncture and keep pain to a minimum. The patient turned the screw once a day for 7 days.

expansion measured 5 mm and there was still no midline diastema present. The patient was then instructed to continue turning the screw twice a day for 3 days, then once a day for 2 days. Twenty-four days after initial activation, the expansion measured on the Hyrax appliance was 7 mm and the patient presented with a midline diastema of 3 mm (Figs. 3 and 4). A post-treatment maxillary anterior occlusal radiograph was taken to verify that the midpalatal suture had opened (Fig. 5). A stainless steel ligature was placed through the expansion screw to fixate its position. The patient's midline diastema self-closed completely after approximately 6 weeks, as a result of periodontal transseptal fibre forces (Figs. 6 and 7). The patient reported minor discomfort for one short period when he thought he had mistakenly activated the appliance more than twice on the same day. Following RPE, a 3-month retention phase was instituted to allow for osteogenic formation in the midpalatal suture. Six months following RPE, an occlusal radiograph revealed the presence of new bone formation in the midpalatal suture area (Fig. 8).

Discussion

When RPE is being considered for a young adult, the palatal suture is often evaluated on an occlusal film. Radiographic studies¹⁴ have demonstrated that the midline palatal suture frequently begins to close during the early teens and that maxillary expansion is best performed before the end of adolescence. It is generally assumed that the palatal suture is a straight-running oronasal suture and that the radiographic path projects through this suture.¹⁵ Midpalatal sutures, however, do not always run straight.⁶ If an occlusal film does not show a suture, it may be because the suture runs in an oblique direction in relation to the radiographic path or because the bone structures (such as the vomer) project above the suture.¹⁵ Results of one study¹⁵ found that 9 out of 10 individuals (ranging in age from 18 to 38 years) examined post mortem could have undergone successful RPE, because less than 5% of the midpalatal suture was obliterated. This finding is based on earlier research,¹⁶ which found that if a 5% midpalatal sutural closure is set as a limit for splitting the intermaxillary suture, this 5% closure will not have been reached in most patients younger than 25 years of age. Recent research¹⁵ indicates that a "radiologically closed" midpalatal suture is not the histological equivalent of a fused or closed suture.

Researchers⁹ attempting RPE in 38 patients ranging in age from the late teens to adulthood (7 males aged 17 years to 23 years [mean age: 21 years, 4 months] and 31 females aged 15 years to 44 years [mean age: 20 years, 6 months]) found that although nonsurgical expansion failed in some subjects because of painful reactions, RPE in younger adults was completed successfully. The definition of "successful" expansion was judged by clinical evidence of

the creation of a midline diastema. Out of the 38 patients, 33 were successfully treated with RPE alone in the age group 15 years to 28 years (mean age of 18 years, 9 months). The 5 individuals who required RPE with surgery ranged in age from 22 years to 44 years (mean age of 30 years, 7 months). It should be noted that most subjects in this study experienced a significant amount of pain, which can be attributed to the very rapid expansion regimen of 4 turns per day of the expansion screw until the appearance of a midline diastema. This very rapid rate of expansion reportedly creates pain and discomfort; the authors of this article and other researchers^{1,8,11} disagree with this protocol and prefer an expansion rate of a maximum of 2 turns per day.

Other similar studies also support the use of nonsurgical RPE in young adults. One such study¹¹ assessed 82 patients under the age of 25 who underwent successful RPE without surgery. Of the 82 patients, 12 were female (mean age of 16 years, 6 months), with the oldest being 20 years of age. The oldest male to undergo expansion without surgery was 25 years of age. Studies^{7,8} evaluating long-term stability have also produced encouraging results. Fifteen patients ranging in age from 15 to 39 (mean age of 22.3) were followed for 11 years; none of the patients experienced a recurrence of their crossbite, although the authors reported concerns over the level of gingival recession that was observed.⁸

Another recent report⁷ concluded that nonsurgical RPE in adults is a clinically successful and safe method for correcting transverse maxillary arch deficiency. This finding is based on comparisons of 47 adults and 47 children treated with nonsurgical RPE and a control group of 52 adult orthodontic patients who did not require RPE. The 47 adults ranged in age from 18 years to 49 years (mean age of 29 years, 9 months \pm 8 years). There was no relapse of the crossbite in the adults treated with RPE following discontinuation of retainers for at least one year (mean time of discontinuation of 5.9 \pm 3.9 years). The method of expansion used in this study was a Haas-type expander with acrylic pads on the hard palate. The expansion screw was turned once per day, which is a different method of achieving expansion. With this technique, no midline diastema appeared in any of the patients. The authors demonstrated that the alveolar bone was in fact translated with minimal molar tipping and the maxillae were not separated in their sample of successfully treated adults. Nine of the 47 subjects experienced pain or tissue swelling, but all were able to complete their expansion regimen after a rest period of one week, with the appliance turned back a few times and a slower expansion schedule every other day. Some buccal gingival attachment loss was seen in the female subjects but the attachment loss was deemed clinically acceptable.

Conclusions

Histological and radiological evidence indicates that the maxillary suture is not fused enough to inhibit the opening of the maxillary palatal suture in patients who are in their late teens or their early twenties. Clinical evidence supports this finding. RPE should be limited to 2 turns per day and may have to be reduced to only one turn every other day to ensure patient comfort. A growing body of evidence is refuting the belief that palatal expansion without surgery is not possible in patients older than 15 or 16 years of age. Our case report and the literature provide clinically based evidence indicating that although the midpalatal suture may be closed when evaluated radiographically, it is not necessarily fused. Therefore, the midpalatal suture can be orthopedically manipulated through RPE in patients at least into their early twenties. Some authors even provide evidence of success beyond this age. There are 2 distinct nonsurgical approaches to expanding maxillary arch width in young adults: the palatal suture may be opened with an RPE appliance, or teeth and alveolar processes can be expanded with a Haas-type expansion appliance. Both methods are stable expansion methods. Clinicians are cautioned that proper case selection is critical to the success of these 2 methods; consultation with an orthodontist or an oral surgeon may be prudent in some cases.

There is an increasing body of evidence that supports nonsurgical RPE in young adults. A comprehensive review of clinical outcomes indicates that it is time for a paradigm shift. Nonsurgical RPE is a viable procedure for young adults who are well into their early twenties. ♦

Dr. Stuart is an orthodontic resident in the faculty of dentistry, University of Manitoba, Winnipeg, Manitoba.

Dr. Wiltshire is professor and head of orthodontics, faculty of dentistry, University of Manitoba, Winnipeg, Manitoba.

Correspondence to: Dr. Dan A. Stuart, Graduate Orthodontic Program, Faculty of Dentistry, University of Manitoba, 780 Bannatyne Ave., Winnipeg, MB R3E 0W2. E-mail: danstuart96@hotmail.com.

The authors have no declared financial interests in any company manufacturing the types of products mentioned in this article.

References

1. Haas AJ. Rapid expansion of the maxillary dental arch and nasal cavity by opening the mid-palatal suture. *Angle Orthod* 1961; 31(2):73–90.
2. Marshall WA, Tanner JM. Puberty. In: Falkner F, Tanner JM, editors. Human growth; a comprehensive treatise. 2nd ed. New York: Plenum Publishing; 1986. p. 171–209.
3. Proffit WR. The biological basis of orthodontic therapy. In: Contemporary orthodontics. 3rd ed. St. Louis: Mosby, Inc; 2000. p. 296–325.
4. McNamara JA, Brudon WL. Treatment of tooth-size/arch-size discrepancy problems. In: Orthodontic and orthopedic treatment in the mixed dentition. Michigan: Needham Press; 1993. p. 67–93.
5. Bishara SE, Staley RN. Maxillary expansion: clinical implications. *Am J Orthod Dentofacial Orthop* 1987; 91(1):3–14.
6. Melsen B. Palatal growth studied on human autopsy material. A histologic microradiographic study. *Am J Orthod* 1975; 68(1):42–54.

7. Handelman CS, Wang W, BeGole EA, Haas AJ. Nonsurgical rapid maxillary expansion in adults: report of 47 cases using the Haas expander. *Angle Orthod* 2000; 70(2):129–44.
8. Northway WM, Meade JB Jr. Surgically assisted rapid maxillary expansion: a comparison of technique, response and stability. *Angle Orthod* 1997; 67(4):309–20.
9. Capelozza Filho L, Cardoso Neto J, daSilva Filho OG, Ursi WJ. Non-surgically assisted rapid maxillary expansion in adults. *Int J Adult Orthodon Orthognath Surg* 1996; 11(1):57–66.
10. Handelman CS. Nonsurgical rapid maxillary alveolar expansion in adults: a clinical evaluation. *Angle Orthod* 1997; 67(4):291–308.
11. Alpern MC, Yurosko JJ. Rapid palatal expansion in adults with and without surgery. *Angle Orthod* 1987; 57(3):245–63.
12. Bell RA. A review of maxillary expansion in relation to rate of expansion and patient's age. *Am J Orthod* 1982; 81(1):32–7.
13. Melsen B, Melsen F. The postnatal development of the palatomaxillary region studied on human autopsy material. *Am J Orthod* 1982; 82(4):329–42.
14. Revelo B, Fishman LS. Maturational evaluation of ossification of the midpalatal suture. *Am J Dentofacial Orthop* 1994; 105(3):288–92.
15. Wehrbein H, Yidizhan F. The mid-palatal suture in young adults. A radiological-histological investigation. *Eur J Orthod* 2001; 23(2):105–14.
16. Persson M, Thilander B. Palatal suture closure in man from 15 to 35 years of age. *Am J Orthod* 1977; 72(1):42–52.