

# Endodontic Therapy in a 3-Rooted Mandibular First Molar: Importance of a Thorough Radiographic Examination

- Juan J. Segura-Egea, DDS, MD, PhD •
- Alicia Jiménez-Pinzón, DDS •
- José V. Ríos-Santos, DDS, MD, PhD •

## A b s t r a c t

*This case report describes endodontic therapy on a mandibular first molar with unusual root morphology. In the initial treatment the working length had been determined with only an apex locator; no periapical radiographs had been obtained because the patient was pregnant. The root canal into an additional distolingual root had not been found and was therefore left untreated, which led to treatment failure after 11 months. The radiographic examination performed in a subsequent endodontic treatment allowed detection of the anomalous root and completion of the root canal treatment. The distolingual root canal would have been identified during the initial endodontic therapy if a thorough radiographic examination had been carried out. This report highlights the importance of radiographic examination and points out the need to look for additional canals and unusual canal morphology associated with a mandibular first molar. Radiographic examination during pregnancy is also discussed.*

**MeSH Key Words:** dental care; molar/anatomy and histology; tooth root/anatomy and histology; pregnancy

© J Can Dent Assoc 2002; 68(9):541-4  
This article has been peer reviewed.

Root canals may be left untreated during endodontic therapy if the dentist fails to identify their presence, particularly in teeth with anatomical variations or extra root canals.<sup>1</sup> Therefore, a thorough radiographic examination, including preoperative radiographs, is essential for success in endodontic therapy. An apex locator can help in determining the working length during root canal treatment, but it cannot replace periapical radiography because it does not provide the detailed information about root canal morphology that radiography does.

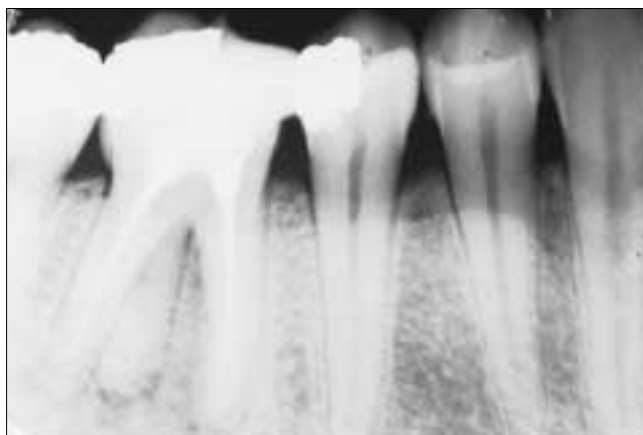Anatomical variations are an acknowledged characteristic of mandibular permanent molars.<sup>2,3</sup> Most mandibular first and second molars in Caucasians have 2 roots, with 2 mesial canals and 1 distal canal.<sup>4,5</sup> The presence of a third root in the permanent first molar is the major variant in this group. The frequency of this trait is less than 5% in Caucasian, African, Eurasian and Indian populations, whereas it occurs in 5% to more than 40% of people of Mongolian origin.<sup>6</sup> Gulabivala and others<sup>7</sup> recently reported that 13% of mandibular first molars in people of

Thai origin had a third distolingual root. The additional root is generally located on the lingual aspect and has a Vertucci type I canal configuration.<sup>2</sup> Such a variant has not been reported for the mandibular second molar, but it is found (rarely) in the mandibular third molar.<sup>7</sup>

This report describes endodontic therapy on a 3-rooted mandibular first molar. The canal in the additional distolingual root was left untreated during initial endodontic treatment because radiographic examination was not carried out at that time.

### Case Report

A 34-year-old Caucasian woman in good health sought treatment for pain in the region of the right mandibular first molar. The patient had undergone endodontic therapy of the same tooth 11 months earlier, when she was 4 months pregnant. At that time, she had asked her dentist to perform the root canal treatment without radiographic examination because of the pregnancy. Therefore, the dentist had used only an apex locator to determine the

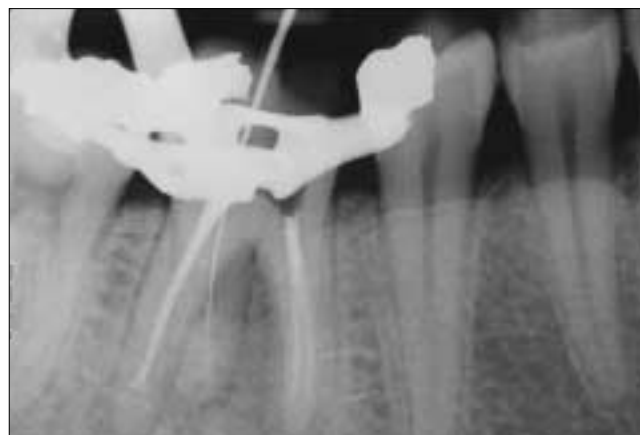


**Figure 1:** Preoperative radiograph shows that the right mandibular permanent first molar (tooth 46) has an additional distolingual root and that its root canal has not been treated endodontically.

working length. During the current presentation, the patient reported recent spontaneous pain around the apical area of the tooth, as well as pain upon mastication. Clinical examination of the right mandibular first molar revealed a disto-occlusal silver amalgam restoration and a mesio-occlusal resin composite restoration. The tooth was discoloured and was sensitive to percussion and palpation. A periapical radiograph (Fig. 1) showed that the tooth had a total of 3 roots; the 2 canals of the mesial root and the single canal of 1 of the distal roots had all been treated endodontically, but the canal of the second distal root had not been treated, probably because the dentist failed to identify its presence. The radiograph revealed radiolucency in the periapical area of the distolingual root and apparent widening of the periodontal ligament space of this additional root. Radiography also revealed double periodontal ligament (PDL) spaces in the mesial root. The apical portion of the distobuccal canal seemed to be infraobtured.

Observation via a conventional access cavity revealed the presence of 3 canal orifices, 2 mesial and 1 distobuccal, all of them filled with gutta percha. The access cavity was enlarged distolingually by means of an Endo-Z bur (Dentsply Maillefer, Ballaigues, Switzerland). Careful investigation of the pulp chamber with a K-file #15 (Dentsply Maillefer) and ethylenediaminetetraacetic acid (EDTA; Glyde File Prep, Dentsply Maillefer) revealed a distolingual orifice with 1 canal. Coronal flaring was accomplished with Gates Glidden burs (sizes 3 and 4) (Dentsply Maillefer). The distolingual canal was cleaned and shaped by hand with K-Flexfiles (Dentsply Maillefer), with a balanced force action under irrigation with 5% sodium hypochlorite (NaOCl) and EDTA.

The distobuccal canal was re-treated to achieve better obturation. The cervical third of the gutta percha was removed with a heated 5/7 plugger (Kerr/Sybron, Romulus,



**Figure 2:** Periapical radiograph shows tooth length; a K-file #25 is evident in the additional distolingual root.

Michigan). The apical two-thirds of the gutta percha and sealer combination were re-treated with conventional hand files and chloroform. Aliquots of 0.05 mL of chloroform were injected into the canal to soften the gutta percha. Hedstrom files (size 25 to 45; Dentsply Maillefer) were used for re-treatment of the working length. During the re-treatment, the root canal was constantly irrigated with 5% NaOCl. The criteria for completion of re-treatment were the cleanliness of the filings, absence of gutta percha or sealer on the files or the paper points, and smoothness of the canal walls.

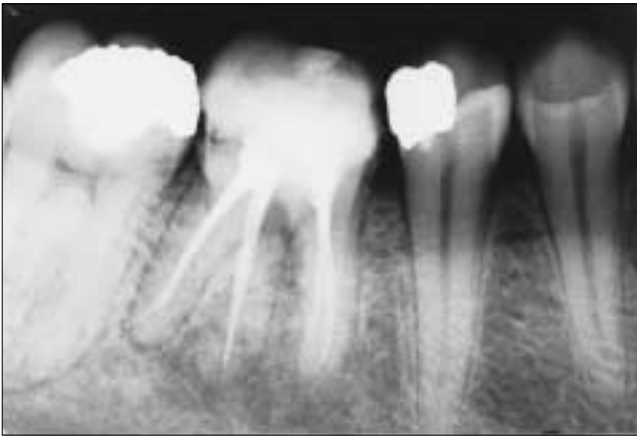
For both the distobuccal and distolingual roots, the canals were instrumented to one size larger than the previous master apical file used. The root length was estimated with an apex locator (Root ZX, Morita, Tokyo, Japan) and confirmed with periapical radiography (Fig. 2).

After being cleaned and shaped, the canals were dried and obturated by cold lateral condensation of gutta percha (Dentsply Maillefer) and sealer (AH Plus, Dentsply DeTrey, Konstanz, Germany), and the tooth was filled with resin composite (Fig. 3).

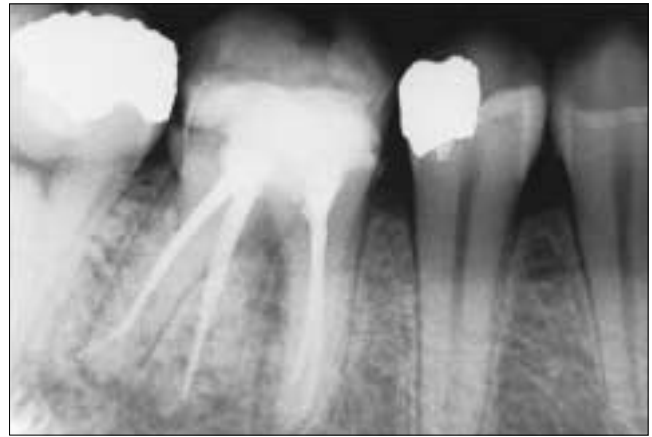At follow-up 14 months later, the tooth was asymptomatic and there was radiographic evidence of progressive periapical healing (Fig. 4). The tooth was completely asymptomatic at 2 years. Further radiographic examination showed that the left mandibular permanent first molar of this patient also had 3 roots (Fig. 5). Moreover, double PDL spaces were also present in the mesial root of this tooth.

## Discussion

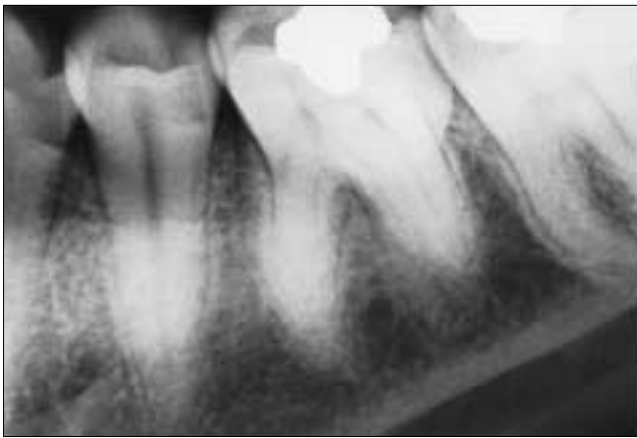This report describes initial failure of endodontic therapy in a 3-rooted right mandibular permanent first molar. The fourth root canal, which occurred in a supernumerary distolingual root, was not identified during the first treatment because periapical radiography was not performed;



**Figure 3:** Postoperative radiograph shows the endodontically treated distolingual canal and the re-treated distobuccal canal.



**Figure 4:** Radiograph obtained at 14-month follow-up. The tooth was asymptomatic. Double periodontal ligament spaces are visible in the mesial root, which suggests root bifurcation.



**Figure 5:** Periapical radiograph shows the left mandibular permanent first molar with an additional distal root. Double periodontal ligament spaces are visible in the mesial root of this tooth, which again suggests root bifurcation.

this canal was therefore left untreated. Eventual treatment success was achieved by endodontic therapy of this extra canal and re-treatment of the distobuccal canal.

The 3-rooted mandibular first molar reported here had 1 mesial root with 2 canals and 2 distal roots with a single canal each. This structure is the same as that of other 3-rooted mandibular first molars described previously.<sup>8</sup>

The roots and canals of mandibular permanent first molars have several typical anatomical features, as well as a great number of anomalies. The presence of 4 canals is relatively frequent,<sup>6</sup> but the presence of 2 distal roots is uncommon.<sup>9</sup> Using radiographic examination, Steelman<sup>10</sup> found that 10 (6.4%) of 156 Hispanic children had an accessory distal root of the mandibular permanent first molar. The prevalence of an extra root is about equal in males and females, but the anomaly is more frequent on the left side.<sup>11</sup> An additional distolingual root occurred unilaterally in approximately 40% of the cases summarized by Quackenbush,<sup>12</sup> predominantly on the right side. The extra

root is smaller than the distobuccal root and is usually curved.<sup>13</sup> In the case reported here the trait occurred bilaterally, and both of the extra distolingual roots seemed to be smaller than their respective distobuccal roots.

The number of roots in the mandibular first molar may be increased not only by the presence of a distolingual root, but also through bifurcation of the mesial root, a trait found in 0.5% of mandibular permanent first molars.<sup>14</sup> In the case reported here, periapical radiographs of both the right and left mandibular permanent first molars revealed double PDL spaces in the mesial roots. This trait could be interpreted in 3 ways: bifurcation of the mesial root, presence of 2 mesial roots or a very broad faciolingually oriented mesial root. The most probable cause in this patient was bifurcation of the mesial root.<sup>14</sup>

Knowledge of both normal and abnormal anatomy of the molars dictates the parameters for execution of root canal therapy and can directly affect the probability of success. Therefore, practitioners must be familiar with all molar abnormalities, as well as their prevalence.

In the case presented here, initial endodontic therapy was unsuccessful because of the dentist's failure to identify the fourth canal in the additional root, as well as inadequate obturation of the distobuccal canal. The distolingual canal would have been identified during the first visit if a thorough radiographic examination had been carried out. However, the patient was pregnant and asked that radiography not be performed. Pregnancy is not an absolute contraindication to dental radiography.<sup>15</sup> A pregnant patient's exposure to dental X-rays should be limited to what is required for treatment to be rendered immediately (while the patient is pregnant),<sup>16</sup> but the absorbed radiation dose to the pelvic region from a full-mouth series of dental radiographs, if done properly, is only about 1  $\mu\text{Gy}$  (0.1 mrad). For comparison, for the U.S. population, the average annual dose of radiation from natural

environmental sources is about 0.8 mGy or 800 µGy (80 mrad).<sup>17</sup> Thus, the dose from typical periapical radiography is equivalent to about one-half day of unavoidable exposure to natural background radiation. Moreover, during dental radiography, as for most other types of radiography, the radiation source is focused on the area being imaged and there is virtually no exposure to any body part other than the part of interest.

This case highlights the importance of radiographic examination, especially preoperative radiography, for success in endodontic therapy. Although uncommon, an extra root containing an independent canal may be present. The third root is radiographically evident in about 90% of cases,<sup>18</sup> but may be difficult to see because of its slender dimensions. In such cases, vertically and horizontally angled views may be helpful.<sup>19</sup> ♦

---

*Dr. Segura-Egea is an associate professor in the department of stomatology, school of dentistry, University of Seville, Seville, Spain.*

*Dr. Jiménez-Pinzón is a doctoral fellow in the department of stomatology, school of dentistry, University of Seville, Seville, Spain.*

*Dr. Ríos-Santos is a lecturer in the department of stomatology, school of dentistry, University of Seville, Seville, Spain.*

*Correspondence to: Dr. Juan J. Segura-Egea, C/Cueva de Menga nº 1, portal 3, 6º-C 41020-SEVILLA, SPAIN. E-mail: segurajj@wanadoo.es.*

*The authors have no declared financial interests in any company manufacturing the types of products mentioned in this article.*

---

## References

1. Reeh ES. Seven canals in a lower first molar. *J Endod* 1998; 24(7):497-9.
2. Sperber GH, Moreau JL. Study of the number of roots and canals in Senegalese first permanent mandibular molars. *Int Endod J* 1998; 31(2):117-22.
3. Sidow SJ, West LA, Liewehr FR, Loushine RJ. Root canal morphology of human maxillary and mandibular third molars. *J Endod* 2000; 26(11):675-8.
4. Barker BC, Parsons KC, Mills PR, Williams GL. Anatomy of root canals. III. Permanent mandibular molars. *Aust Dent J* 1974; 19(6):408-13.
5. Vertucci FJ, Williams RG. Root canal anatomy of the mandibular first molar. *J N J Dent Assoc* 1974; 45(3):27-8.
6. Gulabivala K, Aung TH, Alavi A, Ng YL. Root and canal morphology of Burmese mandibular molars. *Int Endod J* 2001; 34(5):359-70.
7. Gulabivala K, Opananon A, Ng YL, Alavi A. Root and canal morphology of Thai mandibular molars. *Int Endod J* 2002; 35(1):56-62.
8. Kimura Y, Matsumoto K. Mandibular first molar with three distal root canals. *Int Endod J* 2000; 33(5):468-70.
9. Prabhu NT, Munshi AK. Additional distal root in permanent mandibular first molars: report of a case. *Quintessence Int* 1995; 26(8):567-9.
10. Steelman R. Incidence of an accessory distal root on mandibular first permanent molars in Hispanic children. *ASDC J Dent Child* 1986; 53(2):122-3.
11. Loh HS. Incidence and features of three-rooted permanent mandibular molars. *Aust Dent J* 1990; 35(5):434-7.
12. Quackenbush LE. Mandibular molar with three distal root canals. *Endod Dent Traumatol* 1986; 2(1):48-9.
13. Weine FS. Access cavity preparation and initiating treatment. In: Weine FS, editor. *Endodontic therapy*, 3rd ed. St. Louis, MO: The C. V. Mosby Company; 1982. p. 207-55.
14. Onda S, Minemura R, Masaki T, Funatsu S. Shape and number of the roots of the permanent molar teeth. *Bull Tokyo Dent Coll* 1989; 30(4):221-31.
15. Livingston HM, Dellinger TM, Holder R. Considerations in the management of the pregnant patient. *Spec Care Dentist* 1998; 18(5):183-8.
16. Lee A, McWilliams M, Janchar T. Care of the pregnant patient in the dental office. *Dent Clin North Am* 1999; 43(3):485-94.
17. Lubenau JO. Unwanted radioactive sources in the public domain: a historical perspective. *Health Phys* 1999; 76(2 Suppl):S16-22.
18. Walker RT, Quackenbush LE. Three-rooted lower first permanent molars in Hong-Kong Chinese. *Br Dent J* 1985; 159(9):298-9.
19. Somogyi-Csizmazia W, Simons AJ. Three-rooted mandibular first molars in Alberta Indian children. *J Can Dent Assoc* 1971; 37(3):105-6.