

# Management of Traumatic Dislocation of the Mandibular Condyle into the Middle Cranial Fossa

- Robert P. Barron, DMD, BSc •
- Vesa T. Kainulainen, DDS •
- Albert W. Gusenbauer, DDS •
- Richard Hollenberg, BA, MD, FRCS(C), FACS •
- George K.B. Sándor, MD, DDS, FRCD(C), FRCS(C), FACS •

## A b s t r a c t

*Dislocation of the mandibular condyle into the middle cranial fossa is a rare complication of facial trauma that can have neurological and life-threatening implications. This article discusses the anatomic features that predispose patients to this type of injury, as well as the clinical features and mechanism of injury for this rare type of condylar deformity, to help practitioners recognize this easily overlooked injury and avoid disastrous complications. The article summarizes previously published case reports of this rare complication of condylar trauma and presents a case for which initial diagnosis and a management protocol are described.*

**MeSH Key Words:** *dislocations/surgery; mandibular condyles/injuries; mandibular fractures/surgery*

© J Can Dent Assoc 2002; 68(11):676–80  
This article has been peer reviewed.

**M**andibular condylar fractures commonly occur after trauma, generally presenting as fracture of the condylar neck or dislocation of the temporomandibular joint. According to Bradley,<sup>1</sup> condylar fractures account for 25% to 35% of all mandibular fractures. Both intracapsular and extracapsular fractures of the condyle have been thought to dissipate energy and thus prevent penetrating injuries to the brain and skull.<sup>2</sup> The tendency therefore is for the mandibular condyle to fracture and dislocate, but not into the middle cranial fossa.

Dislocation of the condyle has been described as the clinical condition “when the condyle head is displaced out of the glenoid fossa but still remains within the capsule of the joint.”<sup>3</sup> In cases where the condyle is severely displaced, it may lie within remnants of the capsule and yet be contemporaneously displaced from its native anatomic position.

Dislocation of the mandibular condyle into the middle cranial fossa is a rare form of condylar dislocation. This article describes the clinical and neurologic features of this

complication of condylar trauma and describes the diagnosis and management of a new case.

### Mechanism of Injury

De Fonseca<sup>4</sup> demonstrated that although it is difficult to fracture the roof of the glenoid fossa, because of its morphology, a small round condyle can penetrate this structure more readily than the normal scroll-shaped condyle. A rounded condyle has no accentuated medial and lateral poles and consequently has less surface area available for ligament attachment. This creates a situation wherein a more superiorly directed force may cause the condyle to penetrate through the thinnest part of the glenoid fossa into the middle cranial fossa. The floor of the middle cranial fossa is thin, especially on the medial aspect of the condyle, whereas the lateral aspect is reinforced by the zygomatic process of the squamous portion of the temporal bone. Other factors predisposing to penetration into the middle cranial fossa include a thin condylar neck,<sup>5,6</sup> increased

**Table 1 Clinical signs and diagnostic aids in diagnosing trauma to the temporomandibular joint (TMJ)**

TMJ trauma	Signs and symptoms	Diagnostic aids	ENT and neurologic signs
Condylar dislocation into middle cranial fossa	Shortening of height of mandibular ramus Open bite or crossbite Inability to perform lateral excursions Deviated mandibular midline	Panoramic radiograph, mandibular series: PA, lateral cephalogram, Townes views CT scan	CSF otorrhea Lacerations of external auditory canal Paralysis of facial nerve Hearing deficit Hemorrhage from middle meningeal artery Dural tears Subdural and epidural hematoma Altered level of consciousness Pupillary dilatation Nausea
Condylar fracture	Deviation of mandible to opposing side Pre-auricular hollow or depression Pain on mandibular movement and on pre-auricular palpation Shortening of height of mandibular ramus Premature occlusion with open bite Chin abrasion or laceration with or without symphysis fracture	Panoramic radiographs CT scan	Laceration of external auditory canal

ENT = ear, nose and throat, PA = posteroanterior, CT = computed tomography, CSF = cerebrospinal fluid.

pneumatization of the temporal bone, lack of posterior dentition, and an open-mouth position upon impact.<sup>7</sup>

Most blows to the mandible come from a frontal or lateral direction. Either of these directions of force drives one or both of the condyles against the posterior slope of the glenoid fossa. Since this is a very dense area, the result is fracture of the neck of the condyle. Even in the case of a posterior-superior blow directed at the angle of the mandible, occlusion of the posterior teeth would block the upward thrust of the mandible and limit potential damage to the glenoid fossa.<sup>8</sup> However, an open-mouth position combined with deficient posterior dentition and a posterior-superior blow to the chin will result in condylar neck fracture.<sup>8</sup>

Condylar dislocation most commonly occurs in the anterior, or anteromedial direction, with or without other associated mandibular fractures.<sup>9</sup> Less common is dislocation in the medial or posterior direction. Superior dislocations, including central dislocations cranially through the glenoid fossa and into the middle cranial fossa, are very rare. Lateral dislocation is extremely uncommon because of buttressing by the lateral temperomandibular ligaments.<sup>9</sup>

### Clinical and Neurologic Signs

Clinical suspicion of superior condylar displacement should be raised if there is a history of severe trauma to the chin, limitation of jaw mobility, inability to reach stable and reproducible occlusion, deviation of the chin toward the side of injury (laterognathism), premature occlusion on the side of injury, a leak of the cerebrospinal fluid or hemorrhage from the external auditory canal.<sup>10</sup> Additional clinical findings include asymmetry of the face, with shortening of

the ramus on the affected side, and a pre-auricular hollow caused by the empty glenoid fossa. With this type of injury, it is often difficult to interpret condylar position from plain radiographs.<sup>11</sup> Most of these symptoms are also observed in typical condyle fractures (Table 1).

Neurologic signs such as loss of consciousness, nausea, evidence of cerebrospinal fluid leak, paresis of facial muscles due to facial nerve damage, or deafness may indicate intracranial involvement with possible edema or injury. Damage to vascular structures such as the middle meningeal artery or the posterior cerebral arteries is unlikely but may occur. Laceration of the middle meningeal artery results in epidural hematoma, whereas disruption of the posterior cerebral artery causes subdural hematoma. Clinical signs of subdural hematoma are lethargy, restlessness or combativeness soon after injury.<sup>6</sup> Dural tears caused by the shearing effect of the condyle as it tears through the middle cranial fossa have also been reported. Focal neurologic signs may develop within a few hours of injury, beginning with weakness of the facial muscles and progressing to hemiparesis by the third day after injury. Pupillary dilatation caused by the expanding hematoma occurs late in the clinical course.<sup>11</sup>

When any of these neurologic signs are present, a neurologic consultation is mandatory. Computed tomography (CT) is the mainstay of imaging studies for these injuries. It has been especially useful for avoiding misdiagnosis and ensuring that injuries are detected. The literature is rich in descriptive cases of injuries to the middle cranial fossa attributed to superiorly dislocated condyles that have been difficult to diagnose from plain film radiographs alone.<sup>3,11</sup>

**Table 3** Cause of injury and sex of patient by age group

Age (yr)	Cause of injury (no. and % of cases)			Sex (no. and % of cases)	
	MVA	Bicycle	Other <sup>a</sup>	Male	Female
0–15	4 (24)	7 (78)	1 (14)	2 (17)	10 (48)
16–30	6 (35)	2 (22)	2 (29)	6 (50)	4 (19)
31–50	7 (41)	0 (0)	2 (29)	3 (25)	6 (29)
51–70	0 (0)	0 (0)	2 (29)	1 (8)	1 (5)
<b>Total</b>	<b>17 (100)</b>	<b>9 (100)</b>	<b>7 (100)</b>	<b>12 (100)</b>	<b>21 (100)</b>

MVA = motor vehicle accidents.

<sup>a</sup> Includes industrial accidents.

### Reported Cases of Condylar Dislocations into the Middle Cranial Fossa

A search of the existing literature through Index Medicus using the terms “condylar dislocations” and “middle cranial fossa” yielded 30 articles,<sup>2,3,6–9,11–34</sup> which described a total of 32 fractures. These articles were reviewed to determine patient age, mechanism of injury, imaging modality used to reach definitive diagnosis, treatment rendered including neurosurgic consultation or surgical intervention, complications and patient follow-up (see **Table 2**, Reported cases of condylar dislocation of the middle cranial fossa, at the end of the article).

Including the case reported here, 33 cases of superior dislocations into the middle cranial fossa have been reported (**Table 3**). The average age at occurrence was 24.7 years (range 7–64 years). Nearly twice as many females as males were affected (21 females or 64% and 12 males or 36%), and 10 of 12 patients younger than 16 years of age were female. Motor vehicle accidents were the primary cause of injury in more than half of the injuries, bicycle injuries accounted for one-quarter of the injuries, and other injuries, such as industrial accidents, accounted for the remaining injuries (**Tables 2** and **3**). These data indicate a lack of any pattern in the causes of the injuries, aside from the fact that most of the injured patients were young.

### Case Report

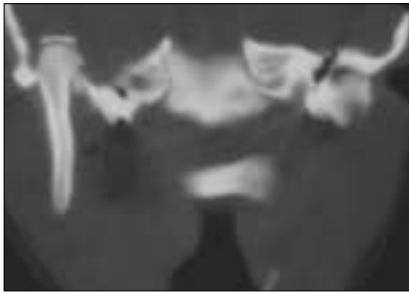
An 8-year-old girl fell off her bicycle, sustaining lacerations to her chin. Upon presentation to the emergency room, the patient had a Glasgow coma score (see **Table 4** at the end of the article) of 15 and normal vital signs. She reported difficulty moving her lower jaw. Her mandible deviated to the right, which was not coincident with the findings on the plain films. Initial review of the radiographs did not indicate any abnormal findings, but closer scrutiny revealed shortening of the right ascending ramus of the mandible. The patient underwent CT, which revealed an intracapsular fracture and displacement of the right condyle 12 mm into the right middle cranial fossa, along with displacement of bone fragments from the glenoid fossa (**Fig. 1**). After a neurosurgical consultation, further CT of

the brain was performed. These studies did not provide any definitive evidence of intracranial hematoma or cerebrospinal fluid leak. All other potential clinical signs of ear, nose and throat (ENT) and neurologic injury were investigated and ruled out.

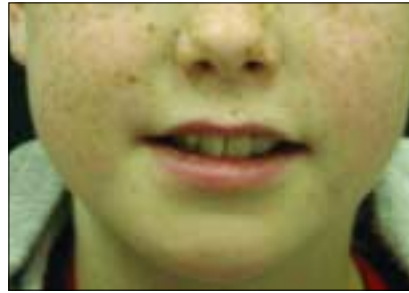With the patient under general anesthesia, the condylar fracture and dislocation were reduced by means of the closed-reduction technique described in the literature.<sup>15,30</sup> This technique involves applying slow, sustained, inferiorly directed traction until the patient’s mandible becomes freely movable. The patient was then placed into maxillo-mandibular fixation, which creates stable occlusion and thereby prevents acute postreduction relapse.

In the event of failure of this procedure, an open-reduction procedure via the pre-auricular approach with the intra-operative assistance of a neurosurgeon was planned. However, the condyle did not relapse or displace back into the superior position. There was a slight (2 mm) deviation of the mandible to the right, which was observed at the incisor midlines, so the patient underwent maxillo-mandibular fixation for 1 week.

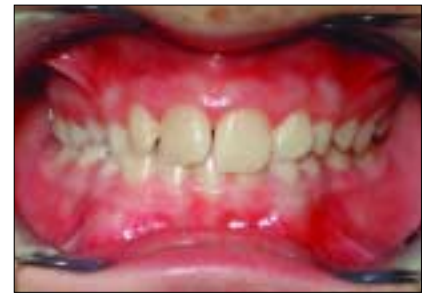The patient returned for regularly scheduled follow-up visits. Her parents were notified of the possibility that the condyle might re-dislocate into the middle cranial fossa, which would necessitate open reduction with bone grafting. Fortunately, the patient’s occlusion remained stable, and she has not required any additional surgery. At the time of writing, the patient had been followed for 2 years, and at her most recent follow-up appointment her maximal mouth opening was 35 mm, with slight deviation of the mandible to the right (**Figs. 2a** and **2b**). Radiographic images showed that the right condylar head had resorbed and remodelled (**Fig. 2c**). The patient has been informed that she will require long-term follow-up because of the mandibular deviation. This follow-up may include orthodontic intervention and, once growth is complete, orthognathic surgery for possible facial asymmetries, which may develop with future growth. In addition, the potential for future temporomandibular joint dysfunction has been discussed with the parents.



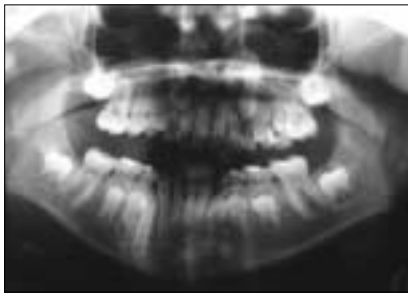
**Figure 1:** Coronal computed tomography image illustrating fracture of the right glenoid fossa, and condylar penetration into the middle cranial fossa.



**Figure 2a:** Anterior facial view of the patient illustrates slight mandibular deviation to the right at the 2-year follow-up visit.



**Figure 2b:** Intraoral view illustrates mild shift in occlusion to the right at the 2-year follow-up visit.



**Figure 2c:** Panoramic radiographs obtained at the 2-year follow-up visit demonstrate right condylar remodelling.

## Discussion

The patient described here had no evidence of neurologic injury. The inferior part of the temporal lobe is a relatively “silent” area of the brain, and epilepsy and other cerebral deficits are uncommon in this region.<sup>15</sup> Other cases have involved dural tears necessitating neurosurgical intervention (**Table 2**),<sup>3,8,23,30</sup> Persistent cerebrospinal fluid leaks require direct dural repair via a craniotomy approach, to avoid complications such as meningitis.<sup>36</sup>

A variety of surgical treatments have been considered, from closed-reduction techniques with manual manipulation to open reduction combined with intracranial bone grafting. Closed reduction has been accomplished by means of manual traction applied to the condyle in a direction dorsal-inferior to the mandible. This technique is most useful in young children, whose injuries occurred within 4 weeks of treatment. In this population, manual reduction plays a large role in this technique. Most patients have subsequently undergone maxillomandibular fixation either with wires or with light occlusion-guiding elastics.<sup>3,6,9,14,23</sup>

In situations where closed reduction has failed because of re-dislocation or the condyle has lodged within the middle cranial fossa, open-reduction procedures have been required.<sup>12,14,18–20</sup> Open reduction involves either condylectomy under direct vision via an intracranial approach combined with craniotomy or condylotomy via a pre-

auricular incision. In situations where the condyle cannot be removed from the middle cranial fossa by an open approach, the size of the condyle may be reduced by means of gap arthroplasty, and fascia lata can be placed as an interpositional layer, to prevent ankylosis.<sup>3,8,14,33</sup>

The glenoid fossa itself may need to be reconstructed. Sources of autogenous bone such as cranial and rib grafts have typically been used, in addition to allogeneic bone.<sup>11,14,16</sup> The type of reconstruction chosen is based upon the size of the defect and the amount of condylar displacement. The goals of glenoid fossa reconstruction are to prevent recurrent condylar dislocation, to re-establish posterior facial height, and to restore normal joint function by repairing the damaged articular disk, if it is salvageable.<sup>6,13,14,16,19</sup>

## Conclusions

This article has described the unusual mechanism of injury in superiorly dislocated fractures of the mandibular condyle, in which the middle cranial fossa is penetrated. Upon presentation to the emergency department or a private dental office, patients with such a history should undergo a thorough clinical examination, since injuries to the middle cranial fossa are easily overlooked. The potential for neurologic complications must also be recognized. Any patient with a superiorly dislocated condyle requires neurosurgical and ENT consultation. Patients presenting with altered state of consciousness must be referred immediately to the nearest emergency department that can provide neurologic support, since delay of referral in cases of neurologic involvement could have disastrous outcomes.

Patients with condylar fractures require long-term follow-up because of the potential for craniofacial asymmetries. General practitioners, orthodontists, oral and maxillofacial surgeons, ENT specialists and neurosurgeons should all be involved in this follow-up. As growth progresses towards its completion, the patients are at risk of developing mandibular asymmetries and temporomandibular joint dysfunction with potentially significant osteoarthritic changes.

*Dr. Barron is senior exchange resident, department of oral and maxillofacial surgery, University of Toronto, Toronto, Ontario, and senior resident, Hadassah Medical Center, The Hebrew University, Jerusalem, Israel.*

*Dr. Kainulainen is clinical fellow, department of oral and maxillofacial surgery, University of Toronto, Toronto, Ontario, and lecturer in the department of oral and maxillofacial surgery, Institute of Dentistry, University of Oulu, Oulu, Finland.*

*Dr. Gusenbauer is oral and maxillofacial surgeon, Hamilton Health Sciences Corporation, McMaster University Medical Centre Campus, Hamilton, Ontario.*

*Dr. Hollenberg is pediatric neurosurgeon, Children's Hospital, Hamilton Health Sciences Corporation, McMaster University Medical Centre, Hamilton, Ontario.*

*Dr. Sàndor is director, graduate program in oral and maxillofacial surgery, and associate professor, University of Toronto, and coordinator of OMFS Hospital for Sick Children and Bloorview MacMillan Children's Centre, Toronto, Ontario.*

*Correspondence to: Dr. George K.B. Sàndor, Hospital for Sick Children, S-527, 555 University Ave., Toronto, ON M5G 1X8. E-mail: gsandor@sickkids.ca.*

*The authors have no declared financial interests.*

## References

- Bradley P. Injuries of the condylar and coronoid process. In: Rowe NL, Williams JL, editors. Maxillofacial injuries. New York: Churchill Livingstone; 1985. p. 337–62.
- Engvall S, Fischer K. Dislocation of the mandibular condyle into the middle cranial fossa: review of the literature and report of a case. *J Oral Maxillofac Surg* 1992; 50(5): 524–7.
- Baldwin AJ. Superior dislocation of the intact mandibular condyle into the middle cranial fossa. *J Oral Maxillofac Surg* 1990; 48(6):623–8.
- da Fonseca GD. Experimental study on fractures of the mandibular condylar process (mandibular condylar process fractures). *Int J Oral Surg* 1974; 3(3):89–101.
- Smith RR. Essentials of neurosurgery. Philadelphia (PA): Lippincott; 1980. p. 6, 108, 118–23.
- Chuong R. Management of mandibular condyle penetration into the middle cranial fossa: case report. *J Oral Maxillofac Surg* 1994; 52(8):880–4.
- Musgrove BT. Dislocation of the mandibular condyle into the middle cranial fossa. *Br J Oral Maxillofac Surg* 1986; 24(1):22–7.
- Seymour RL, Irby WB. Dislocation of the condyle into the middle cranial fossa. *J Oral Surg* 1976; 34(2):180–3.
- Worthington P. Dislocation of the mandibular condyle into the temporal fossa. *J Maxillofac Surg* 1982; 10(1):24–7.
- Loh FC, Tan KB, Tan KK. Auditory canal haemorrhage following mandibular condylar fracture. *Br J Oral Maxillofac Surg* 1991; 29(1):12–3.
- Sandler NA, Ozaki WH, Ochs MW, Marion DW. Intracranial reduction of an intact mandibular condyle displaced into the middle cranial fossa. *J Oral Maxillofac Surg* 1996; 54(4):506–10.
- Koretsch LJ, Brook AL, Kader A, Eisig SB. Traumatic dislocation of the mandibular condyle into the middle cranial fossa: report of a case, review of the literature and a proposal management protocol. *J Oral Maxillofac Surg* 2001; 59(1):88–94.
- Long X, Hu C, Zhao J, Li J, Zhang G. Superior dislocation of mandibular condyle into the middle cranial fossa. A case report. *Int J Oral Maxillofac Surg* 1997; 26(1):29–30.
- Melugin MB, Indresano AT, Clemens SP. Glenoid fossa fracture and condylar penetration into the middle cranial fossa: report of a case and review of the literature. *J Oral Maxillofac Surg* 1997; 55(11):1342–7.
- Tornes K, Lind O. Cranial dislocation of the mandibular condyle. A case report with an unusual hearing loss. *J Craniomaxillofac Surg* 1995; 23(5):302–4.
- Christiansen RL. Condylar penetration into the middle cranial fossa. *J Craniomandib Disord* 1989; 3(2):100–4.
- Paulette SW, Trop R, Webb MD, Nazif MM. Intrusion of the mandibular condyle into the middle cranial fossa: report of a case in an 11-year-old girl. *Pediatr Dent* 1989; 11(1):68–71.
- Copenhaver RH, Dennis MJ, Kloppedal E, Edwards DB, Scheffer RB. Fracture of the glenoid fossa and dislocation into the middle cranial fossa. *J Oral Maxillofac Surg* 1985; 43(12):974–7.
- Pepper L, Zide MF. Mandibular condyle fracture and dislocation into the middle cranial fossa. *Int J Oral Maxillofac Surg* 1985; 14(3):278–83.
- Ihalainen U, Tasanen A. Central luxation or dislocation of the mandibular condyle into the middle cranial fossa. A case report and review of the literature. *Int J Oral Surg* 1983; 12(1):39–45.
- Pieritz U, Schmidseher R. Central dislocation of the jaw-joint into the middle cranial fossa. Case report. *J Maxillofac Surg* 1981; 9(1):61–3.
- Iannetti G, Martucci E. Fracture of glenoid fossa following mandibular trauma. *Oral Surg Oral Med Oral Pathol* 1980; 49(5):405–8.
- Kallal RH, Gans BJ, Lagrotteria LB. Cranial dislocation of mandibular condyle. *Oral Surg Oral Med Oral Pathol* 1977; 43(1):2–10.
- Zecha JJ. Mandibular condyle dislocation into the middle cranial fossa. *Int J Oral Surg* 1977; 6(3):141–6.
- Pons J, Pasturel A, Desgeorges M, De Greslan M. Pénétration traumatique intracranienne d'un condyle mandibulaire. *Rev Stomatol Chir Maxillofac* 1976; 77(6):869–74.
- Lund K. Central luksation i kaebeledet. *Tanglaegebladet* 1971; 75:803–8.
- Pirok DJ, Merrill RG. Dislocation of the mandibular condyle into the middle cranial fossa. Report of a case. *Oral Surg Oral Med Oral Pathol* 1970; 29(1):13–8.
- Rowe NL, Killely HC. Fractures of the facial skeleton. Edinburgh-London: E&S Livingstone; 1968. p. 145–6.
- Peltier JR, Matthews TA. Mandibular condyle in middle cranial fossa: report of a case. *J Oral Surg* 1965; 23:74–7.
- Whitacre WB. Dislocation of the mandibular condyle into the middle cranial fossa: review of the literature and report of a case. *Plastic & Reconstructive Surg* 1965; 38(1):23–6.
- Stoltmann HF. Fracture dislocation of the temporomandibular joint. Report of two cases. *J Neurosurg* 1964; 22:100–1.
- Doane HF. Dislocation of the right mandibular condyle into the middle cranial fossa. *J Oral Surg Anesth & Hosp D Serv* 1963; 21:510–4.
- Dingman RO, Grabb WC. Mandibular laterognathism. *Plastic & Reconstructive Surg* 1962; 31(6):563–75.
- Heidsieck C. Beitrag zur sogenannten zentralen Kiefergelenkluxation. In: Schuchardt K, editor. Fortschritte der kiefer- und Geichts- Chirurgie. Stuttgart, Germany, Georg Thieme Verlag; 1960. p. 105–8.
- Head trauma. In: American College of Surgeons. Advanced trauma life support for doctors ATLS. Sixth edition. Chicago (IL); 1997. p. 188–90.
- Lew D, Birbe J. Zygomatic complex fractures. In: Fonseca RJ. Oral and maxillofacial surgery. Philadelphia (PA): W.B.Saunders Company; 2000. p. 187–8.

**Table 2** Reported cases of condylar dislocation of the middle cranial fossa

Author	Age (yr) and sex	Diagnosis	Treatment	Complications	Follow-up
Barron and others (current study)	8, F	R condylar fracture and dislocation	CR: manual reduction of condyle, MMF	None	2 yr; mandibular deviation to R, good function
Koretsch and others (2001) <sup>12</sup>	6, F	L condylar dislocation	CR: manual reduction of condyle, MMF	Contusion of L temporal lobe, subarachnoid hemorrhage	2 yr; deviation of chin to L when patient opened mouth
Long and others (1997) <sup>13</sup>	38, F	L condylar dislocation	OR: manual reduction of condyle, condylotomy, disk repair, glenoid fossa implant	Bone fragment adherent to dura mater in MCF	Duration of follow-up and function not reported
Melugin and others (1997) <sup>14</sup>	37, F	Fractures of orbital floor, L temporal bone, R PS and L ramus; L condylar dislocation	OR: condylotomy, insertion of allogeneic rib for reconstruction of glenoid fossa	Skull base fracture, L-sided hearing loss and facial paresis	Duration of follow-up and function not reported
Sandler and others (1996) <sup>11</sup>	16, M	R condylar dislocation	R temporal craniotomy, OR (manual reduction of condyle, reconstruction of glenoid fossa with temporal bone graft, repair of dural tear with temporal fascia)	R CSF otorrhea, dural tear, contusion of temporal lobe, R-sided hemiparesis due to occlusion of common carotid artery	Duration of follow-up and function not reported
Tornes and Lind (1995) <sup>15</sup>	37, F	R condylar dislocation	OR: condylotomy and coronoidectomy; MMF with elastics	Cerebral contusion, R-sided hearing loss	5 yr; jaw deviation to R
Chuong (1994) <sup>6</sup>	28, F	R condylar dislocation	CR unsuccessful; OR with manual reduction, disk suturing, MMF	R-sided hearing loss	Duration of follow-up and function not reported
Engvall and Fischer (1992) <sup>2</sup>	37, F	R SC fracture, symphysis fracture, L condylar dislocation	Temporal craniotomy, MMF, prosthetic glenoid fossa	Anterior open bite, treated by bimaxillary orthognathic surgery	3 yr; slight tenderness in L TMJ but good function
Baldwin (1990) <sup>3</sup>	10, M	R condylar fracture and dislocation	CR, MMF with elastics	None	2 yr; good function
Christiansen (1989) <sup>16</sup>	9, M	R condylar dislocation, L SC fracture with anteromedial displacement	OR: craniotomy, manual reduction of condyle, rib grafting to MCF, disk repair; MMF with elastics	Dura mater tear, treated by fascia lata graft; subdural hematoma	Duration of follow-up not reported; good function, with jaw deviation to L
Christiansen (1989) <sup>16</sup>	35, F	R condylar dislocation	OR: manual reduction of condyle, disk repair; MMF with elastics	R-sided hearing loss, constant headaches, dizziness	Duration of follow-up and function not reported
Paulette and others (1989) <sup>17</sup>	11, F	L condylar dislocation	CR with towel clips, MMF	None	10 months; good function with slight deviation to L
Musgrove (1986) <sup>7</sup>	7, F	L condylar fracture and dislocation	CR initially unsuccessful, then reduction obtained with transmandibular wires and MMF	None	6 months; slightly limited mouth opening
Copenhaver and others (1985) <sup>18</sup>	9, F	R condylar dislocation	CR: manual reduction, MMF	Temporal lobe hematoma	8 months; slight deviation to R

**Table 2 Continued**

Author	Age (yr) and sex	Diagnosis	Treatment	Complications	Follow-up
Pepper and Zide (1985) <sup>19</sup>	32, F	R condylar fracture and dislocation	OR: temporal fascia grafting to MCF defect, disk repair, Proplast interpositional device, condylotomy	None	1.5 yr; good function
Ihalainen and Tasanen (1983) <sup>20</sup>	11, F	R condylar fracture and dislocation	CR: manual reduction	R hemotympanum	1.5 yr; good function, slight mandibular deviation to R
Worthington (1982) <sup>9</sup>	11, F	R SC fracture, R PS fracture, L condylar dislocation	CR twice unsuccessful followed by OR with reduction of condyle	Fibroankylosis of L TMJ, treated by gap arthroplasty with silicone interpositional device	2 yr; limited mouth opening (36 mm)
Pieritz and Schmidseider (1981) <sup>21</sup>	18, M	R condylar dislocation	CR: manual reduction, MMF	Skull base fracture, L cerebral contusion, R facial paresis and hearing loss	19 months; good function
Iannetti and Martucci (1980) <sup>22</sup>	38, M	R condylar dislocation, L SC fracture	OR: manual reduction, reconstruction of glenoid fossa	None	Duration of follow-up and function not reported
Kallal and others (1977) <sup>23</sup>	15, F	R condylar fracture and dislocation	CR: manual reduction, MMF with elastics	At 3.5 yr post-op, microgenia with flattening of condylar surface, advancement genioplasty	Duration of follow-up and function not reported
Zecha (1977) <sup>24</sup>	25, F	R condylar dislocation, symphysis fracture, L SC fracture	CR: manual reduction, MMF	None	1.5 yr; limited movement
Pons and others (1976) <sup>25</sup>	26, M	Condylar dislocation	Intracranial condylectomy, fixation	None	Duration of follow-up not reported; laterognathism
Seymour and Irby (1976) <sup>8</sup>	64, M	L condylar fracture and dislocation	OR: condylar shave and shaping, silicone (Silastic) glenoid fossa implant	Skull base fracture, R otorrhea, BL facial nerve paralysis, L abducens nerve paresis, L-sided hearing loss	Duration of follow-up and function not reported
Lund (1971) <sup>26</sup>	56, F	Not indicated	New prosthesis fabricated	Cerebral contusion, impaired chewing function	Not indicated
Pirok and Merrill (1970) <sup>27</sup>	19, M	R mandibular angle fracture, R condylar dislocation	MMF	R-sided hearing loss, nausea	1.5 yr; good function
Rowe and Killey (1968) <sup>28</sup>	50, M	R condylar dislocation	CR unsuccessful; OR (condylar neck resection, disk repair, Ivy loops)	LOC	Duration of follow-up not reported; normal function
Peltier and Matthews (1965) <sup>29</sup>	18, F	R condylar dislocation, R PS fracture	CR unsuccessful; OR (condylar neck resection)	Laceration of R external auditory canal	9 months; normal range of motion
Whitacre (1965) <sup>30</sup>	15, F	L condylar dislocation	Condylectomy	Not indicated	26 months; good function, deviation to L on excursion
Stoltmann (1964) <sup>31</sup>	25, M	R condylar dislocation	R subtemporal craniotomy, use of rongeur on condyle	Tear in dura mater, LOC	5 yr; good function, no limitation of movement

**Table 2 Continued**

Author	Age (yr) and sex	Diagnosis	Treatment	Complications	Follow-up
Stoltmann (1964) <sup>31</sup>	25, M	L condylar fracture and dislocation	L subtemporal craniotomy, use of rongeur on condyle, MMF	L-sided hearing loss with slight L-sided facial paresis	Duration of follow-up not reported; good function, no limitation of movement
Doane (1963) <sup>32</sup>	13, F	R condylar dislocation	CR unsuccessful; OR (craniotomy, gap arthroplasty, MMF)	Retrograde amnesia, concussion, LOC	3 yr; residual impaired L lateral mobility
Dingman and Grabb (1962) <sup>33</sup>	28, F	R condylar dislocation	Division of condylar neck, fascia lata graft, MMF	Cerebral concussion, mandibular deviation to the R, followed by correction with orthognathic surgery	Duration of follow-up and function not reported
Heidsieck (1960) <sup>34</sup>	38, M	Condylar dislocation	None	Cerebral contusion, facial nerve paralysis, loss of hearing	Duration of follow-up and function not reported

*F = female, M = male, R = right, L = left, CR = closed reduction, OR = open reduction, MMF = maxillomandibular fixation, MCF = middle cranial fossa, PS = parasymphysis, CSF = cerebrospinal fluid, SC = subcondylar, TMJ = temporomandibular joint, BL = bilateral, LOC = loss of consciousness.*

**Table 4 Glasgow coma score<sup>35</sup>**

Score	Eye opening (E)	Verbal response (V)	Motor response (M)
6	NA	NA	Normal, follows simple commands
5	NA	Normal conversation	Localizes to pain; pulls examiner's hand away when pinched
4	Spontaneous	Disoriented conversation	Withdraws to pain; pulls part of body away when examiner pinches patient
3	To voice	Words, but not coherent	Decorticate posture; flexes body inappropriately to pain
2	To pain	No words; sounds only	Decerebrate posture (i.e., body becomes rigid in an extended position when examiner pinches patient)
1	None	None	None

*Note: Patient's total score = E + V + M.  
NA = not applicable.*