

# Treatment Options for Teeth with Open Apices and Apical Periodontitis

*Denise Pontes Raldi, DDS, MSc, PhD; Isabel Mello, DDS, MSc, PhD;  
Sandra Márcia Habitante, DDS, MSc, PhD; Jose Luiz Lage-Marques, DDS, MSc, PhD;  
Jeffrey Coil, DMD, MDS, PhD*

## Auteure-ressource

*Dre Mello*  
Courriel :  
[mello@cc.umanitoba.ca](mailto:mello@cc.umanitoba.ca)



## SOMMAIRE

Trois protocoles différents ont été utilisés dans des cas cliniques pour le traitement de dents avec apex ouverts et périodontite apicale. Dans le premier cas, une pâte intracanal à base d'hydroxyde de calcium a été mise en place pendant 12 mois avant l'obturation avec de la gutta-percha et un scellant. Pour le deuxième cas, un bouchon apical fait d'agrégat minéral de trioxyde (MTA) a été utilisé avant l'obturation par de la gutta-percha et un scellant, et le traitement a été complété en 2 visites. Dans le troisième cas, du MTA a été utilisé pour l'obturation complète de la dent dont le canal radiculaire était divergent, et le traitement a à aussi été complété en 2 visites. Dans les 3 cas, une guérison osseuse consécutive au traitement a été observée.

Pour les citations, la version définitive de cet article est la version électronique : [www.cda-adc.ca/jcda/vol-75/issue-8/591.html](http://www.cda-adc.ca/jcda/vol-75/issue-8/591.html)

The major challenges associated with endodontic treatment of teeth with open apices are achieving complete debridement, canal disinfection and optimal sealing of the root canal system.<sup>1</sup> In the absence of a natural apical constriction, the production of mineralized tissue in the apical region is important to create an apical barrier and allow 3-dimensional adaptation of obturating material within the root canal system. Calcium hydroxide has been commonly used as an intracanal dressing to induce hard tissue deposition in necrotic teeth with open apices. The calcium hydroxide is renewed periodically until an apical barrier is formed.<sup>2</sup> The time needed to form an apical barrier is unpredictable and depends on the size of the apical foramen, the presence of infection and the host.<sup>2,3</sup>

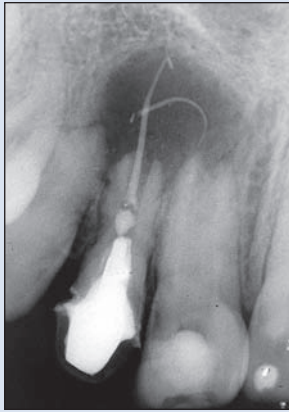
Mineral trioxide aggregate (MTA) is a powder consisting of fine hydrophilic particles

that bind in the presence of moisture. Set MTA provides a good seal and excellent marginal adaptation.<sup>4</sup> In vivo studies have confirmed biocompatibility of this material and have shown a hard tissue inductive effect.<sup>4,5</sup> MTA can be used as an apical plug allowing for prompt obturation of the root canal.<sup>6-8</sup>

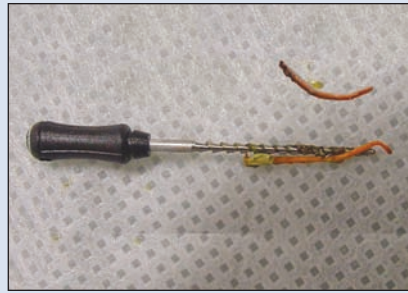
In this paper, we present 3 clinical cases of teeth with open apices and associated apical periodontitis and describe 3 protocols used to treat them.

### Case 1

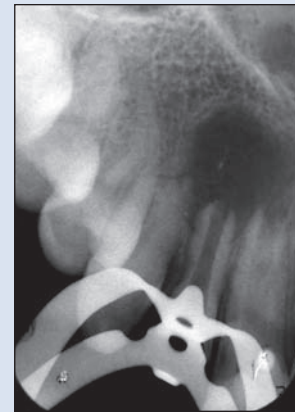A 16-year-old girl suffered subluxation trauma of her maxillary front teeth at 10 years of age. The patient, who was first seen at an emergency appointment, presented with pain originating from tooth 11, which was sensitive to percussion and palpation. During intraoral examination, a sinus tract was found between



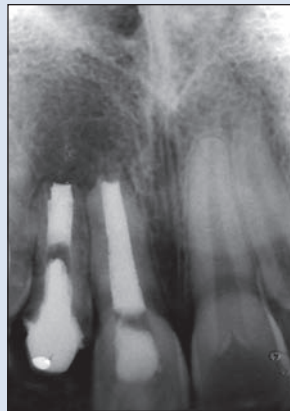
**Figure 1a:** Preoperative diagnostic radiograph in case 1 showing teeth 11 and 12 with open apices and periapical radiolucencies. Tooth 12 presents over-extension of gutta-percha points.



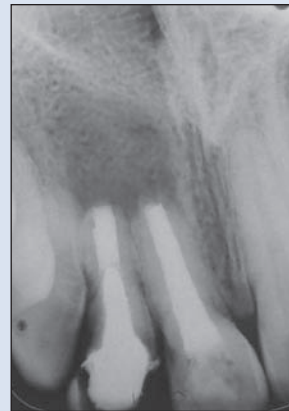**Figure 1b:** Gutta-percha points removed with Hedström file.



**Figure 1c:** Tooth 12 after removal of the gutta-percha.



**Figure 1d:** Radiograph taken at 12-month recall, showing initiation of bone healing.



**Figure 1e:** Follow-up radiograph taken 24 months after completion of treatment.

teeth 11 and 12. A radiographic image revealed that teeth 11 and 12 had open apices and apical periodontitis. Tooth 12 had an intracanal post, inadequate root canal obturation and overextension of gutta-percha points. Tooth 11 contained a radiopaque material in the root canal, suggestive of an intracanal paste (**Fig. 1a**).

After administration of local anesthetic (1.8 mL of 2% lidocaine with 1:100,000 epinephrine [Alphacaine, DFL Indústria e Comércio S.A., Rio de Janeiro, Brazil]), a rubber dam was placed and an access cavity was prepared in tooth 11. To remove the intracanal paste, the canal was lightly cleaned mechanically using hand K-files (Dentsply Maillefer, Ballaigues, Switzerland) to the working length, which was determined radiographically. The root canal was irrigated with 1% sodium hypochlorite (NaOCl), then dried with paper points (Dentsply/Tulsa Dental, Tulsa, OK). Calcium hydroxide (2.5 g [Farmácia de Manipulação Fórmula e Ação,

São Paulo, Brazil]), mixed with saline to a toothpaste consistency, was placed in the canal using an amalgam carrier (Moyco Union Broach, York, PA). The access cavity was sealed with Cavit (3M, ESPE, Saint Paul, MN) placed over a sterile cotton pellet left in the pulp chamber. One tablet of acetaminophen 750 mg was prescribed for postoperative pain.

At a second appointment, root canal retreatment of tooth 12 was initiated; a surgical approach after endodontic retreatment was planned. After administration of local anesthetic (1.8 mL 2% lidocaine with 1:100,000 epinephrine [Alphacaine]) and application of a rubber dam, an access cavity was prepared in tooth 12 and the post was removed using ultrasonics. The canal was irrigated with 1% NaOCl. The gutta-percha points were retrieved via the root canal using #70 and #80 Hedström files (Dentsply Maillefer) (**Fig. 1b** and **1c**). The canal was lightly instrumented using hand K-files (Dentsply Maillefer) at the working length,

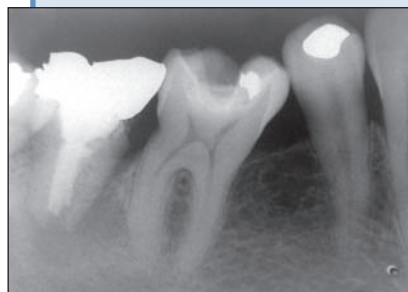
while irrigating with 1% NaOCl. After a final flush with NaOCl, the canal was rinsed with 5 mL 17% EDTA (ethylenediamine tetra-acetic acid) to remove the smear layer. After drying the canal with paper points, calcium hydroxide (2.5 g [Farmácia de Manipulação Fórmula e Ação]), mixed with saline to a toothpaste consistency, was placed in the canal with an amalgam carrier. The access cavity was sealed with Cavit. Diclofenac (50 mg, 3 times a day for 3 days), a nonsteroidal anti-inflammatory drug, was prescribed to manage postoperative pain.

After 1 week, the patient was asymptomatic and her sinus tract had healed. Calcium hydroxide was removed from both teeth by rinsing with 1% NaOCl. After drying the root canals with paper points, a paste of calcium hydroxide (2.5 g [Farmácia de Manipulação Fórmula e Ação]) and 2 mL of polyethylene glycol 400 was placed as an intracanal dressing. This dressing was renewed every 2 months and a radiograph was taken to ensure thorough filling of the root canal with the dressing, as well as to monitor development of a hard tissue barrier. This procedure was repeated over a year, until a hard tissue barrier was detected using a size 40 K-file (Dentsply-Maillefer).

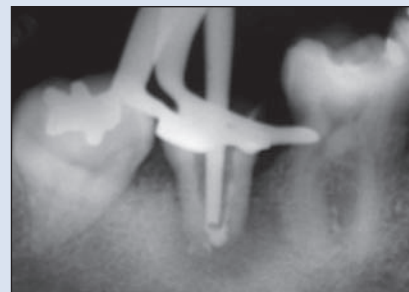At 1 year, the canals of both teeth were flushed with 5 mL of 1% NaOCl followed by 5 mL of 17% EDTA, then dried with paper points. Obturation was completed by lateral compaction, using gutta-percha (Dentsply-Maillefer) and AH Plus sealer (Dentsply Maillefer, Konstanz, Germany) (Fig. 1d). The access cavity in tooth 11 was sealed with a cotton pellet and glass ionomer (Ketac Cem, 3M do Brazil, São Paulo, Brazil) and tooth 12 was sealed with a temporary crown. The patient was referred for permanent restoration of these teeth. As the sinus tract had healed, the patient was asymptomatic and there was evidence of hard tissue healing of the apical periodontitis at the time of obturation, a surgical approach was not necessary. Follow-up radiographs were taken after 6 months, 1 and 2 years (Fig. 1e).

### Case 2

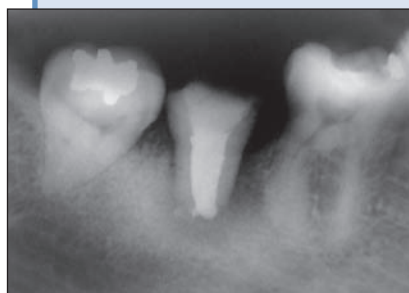A 30-year-old woman complaining of severe pain in her right mandibular area reported that she had had root canal treatment of tooth 47 when she was 13 years old. Clinical examination revealed gingival swelling in the region of tooth 47. Radiography revealed inadequate root



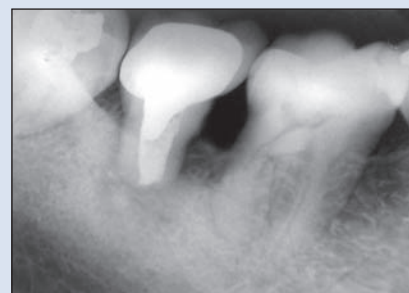**Figure 2a:** Preoperative diagnostic radiograph in case 2 showing tooth 47 with open apex and apical periodontitis.



**Figure 2b:** Mineral trioxide aggregate (MTA) plug placement in the canal and gutta-percha point adjusted 3 mm short of the working length for conventional obturation.



**Figure 2c:** Radiograph taken after root canal obturation.

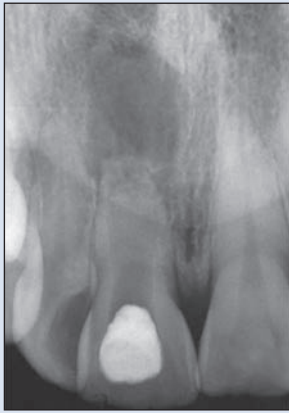


**Figure 2d:** Follow-up radiograph after 5 years showing deposition of hard tissue in the apical area.

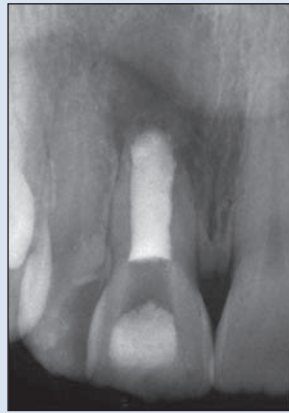canal treatment and apical periodontitis associated with the tooth (Fig. 2a).

At the first appointment, the obturation material was removed with Hedström files while irrigating with 1% NaOCl. After irrigating the canal with 5 mL of 17% EDTA and drying with paper points, calcium hydroxide (2.5 g [Farmácia de Manipulação Fórmula e Ação]) mixed with saline to obtain a toothpaste consistency was placed as an intracanal dressing. After 2 weeks, this dressing was flushed out of the canal with 1% NaOCl. After the canal was dried with paper points (Dentsply/Tulsa Dental), a master gutta-percha point (Dentsply-Maillefer) was selected and adjusted to 3 mm short of the working length. An MTA plug (White MTA-Angelus, Angelus, Londrina, Brazil) was placed with a small amalgam carrier and adapted to the apical canal walls using the pre-adjusted gutta-percha point (Fig. 2b). The position of the MTA plug was checked radiographically and a wet cotton pellet was placed on top of it before sealing the access cavity with Cavit. Lateral compaction of gutta-percha and AH Plus sealer over the set apical MTA was completed at a second appointment 1 week later (Fig. 2c).

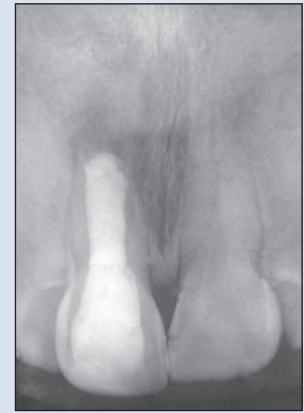After root canal treatment, the patient was referred for permanent restoration of this tooth. At follow-up appointments (at 1, 2 and 5 years) the patient had no symptoms and



**Figure 3a:** Preoperative diagnostic radiograph in case 3 showing tooth 11 with wide open apex and apical periodontitis.



**Figure 3b:** Radiograph taken after complete root canal obturation with MTA.



**Figure 3c:** Follow-up radiograph taken 9 months after root canal treatment showing initial bone healing.

radiographs showed increasing hard tissue formation in the apical area (Fig. 2d).

### Case 3

A 28-year-old woman had suffered subluxation trauma of tooth 11 at 7 years of age. The tooth presented as an uncomplicated crown fracture with normal mobility and darkening of the clinical crown. Radiographic examination revealed a very immature tooth with a wide open apex and apical periodontitis (Fig. 3a).

The clinical protocol was similar to that in the 2 previous cases. After 4 weeks with an intracanal dressing (2.5 g of calcium hydroxide [Farmácia de Manipulação Fórmula e Ação] mixed with 2 mL of polyethylene glycol 400), the root canal was rinsed with 5 mL of 1% NaOCl, then with 5 mL of 17% EDTA. After the canal was dried with paper points (Dentsply/Tulsa Dental), an MTA (ProRoot Dentsply/Tulsa Dental) mixture was placed in the root canal with an amalgam carrier and condensed apically using large paper points. The position of the apical MTA plug was checked radiographically. As the root canal was very wide, a decision was made to fill the entire canal with MTA (Fig. 3b). A cotton pellet moistened in saline was placed over the MTA in the pulp chamber and the access cavity was sealed with Cavit and later restored with composite. At 9 months follow-up, a radiograph showed early bone healing (Fig. 3c).

### Discussion

The teeth described in these 3 cases had different degrees of open apices and associated apical periodontitis. None of the patients had a medical condition that would interfere with either the treatment plan or the outcome of the treatment.

When treating nonvital teeth, a main issue is eliminating bacteria from the root canal system. As instruments cannot be used properly in teeth with open apices, cleaning and disinfection of the root canal system rely on the chemical action of NaOCl as an irrigant and calcium hydroxide as an intracanal dressing.<sup>9</sup>

NaOCl is known to be toxic, especially in high concentrations. When rinsing immature teeth with open apices, there is an increased risk of pushing the irrigant beyond the apical foramen. Therefore, it is advisable to use less concentrated NaOCl, which is less toxic.<sup>10</sup> In all 3 cases, 1% NaOCl was used.

Calcium hydroxide pastes were used in all cases because of their antimicrobial activity and to prevent MTA extravasation into the periapical area.<sup>11</sup> Different vehicles can be used depending on the length of time the dressing will remain in the canal. When the period was up to 2 weeks, saline was used as the vehicle. For more extended periods, polyethylene glycol was used as the vehicle because calcium hydroxide ions are released more slowly and the medication can remain active in the canal for longer periods.<sup>12</sup> A 17% EDTA rinse was carried out before placement of the intracanal dressing to remove the smear layer and facilitate diffusion of calcium hydroxide through the dentin and before obturation to ensure better removal of calcium hydroxide.<sup>13</sup>

In case 1, apexification was reached and osseous healing occurred. Although calcium hydroxide has been shown to be a good material for treating immature teeth, various studies have revealed some disadvantages to using this material, such as long treatment time, the need for multiple appointments and several radiographs and possible canal infection as the crown is sealed with only temporary materials over a long period.<sup>3,14,15</sup> The treatment

time for our apexification procedure was approximately 12 months. A recent prospective clinical study<sup>16</sup> showed that the mean time necessary for the formation of an apical barrier with this technique is more than 12 months. The barrier formed using calcium hydroxide for apexification may be porous and has sometimes even been found to contain small amounts of soft tissue.<sup>17</sup> In our case, even after tactile and radiographic checking of the barrier, the first gutta-percha point was pushed beyond the apex on tooth 12 during obturation and had to be discarded. Also, due to the width of the canals, adaptation of gutta-percha to the apical area was difficult.

Because of MTA's excellent biological properties and ability to create a good seal, it has been recommended for creating an artificial barrier in the apical area of teeth with open apices, thus compressing treatment time to 1 or 2 visits.<sup>18</sup> The cell's response to MTA and the mechanism of deposition in barrier formation are unknown and require further investigation.<sup>3</sup>

MTA was used in case 2 as an apical plug and in case 3 as the filling material. In case 2, a 2-mm MTA plug was placed in the apical area of the root canal and conventional obturation was performed. Placement of the MTA plug facilitated obturation of the root canal without overextension of the filling material. In case 3, because the tooth was very immature and adaptation of a gutta-percha master point would be very difficult, the root canal was completely obturated with MTA.

MTA consists of fine hydrophilic particles that set in the presence of moisture in approximately 4 hours.<sup>5</sup> In case 2, final obturation was carried out at a subsequent visit to avoid dislocation of the MTA plug beyond the apex. In both cases 2 and 3, a moist cotton pellet was left over the MTA to facilitate setting.

Follow-up radiographs in all 3 cases showed osseous healing and, during clinical examination, the patients were asymptomatic. The results obtained with MTA in cases 2 and 3 seem to be similar to those of other studies.<sup>8,11,19</sup>

The choice of treatment regimen for teeth with open apices depends on the individual case and operator experience and familiarity with handling the various materials. Patient availability for follow-up appointments should be considered as well if multiple sessions are required.

## Conclusions

The 3 cases reported here all revealed signs of bone healing, regardless of the treatment protocol used. ♦

## THE AUTHORS



**Dr. Raldi** is an endodontist and assistant professor in the division of endodontics, University of Taubaté, Taubaté, Brazil.



**Dr. Mello** is an endodontist and assistant professor in the division of endodontology, University of Manitoba, Winnipeg, Manitoba.



**Dr. Habitante** is an endodontist and assistant professor in the division of endodontics, University of Taubaté, Taubaté, Brazil.



**Dr. Lage-Marques** is an endodontist and chair of the division of endodontics, University of Taubaté, Taubaté, Brazil.



**Dr. Coil** is an endodontist and assistant professor in the department of oral biological and medical sciences, faculty of dentistry, University of British Columbia, Vancouver, British Columbia.

**Correspondence to:** Dr. Isabel Mello, University of Manitoba, D226B-780 Bannatyne Ave., Winnipeg, MB R3E 0W2.

The authors have no declared financial interests in any company manufacturing the types of products mentioned in this article.

This article has been peer reviewed.

## References

- Andreasen JO, Flores MT. Injuries to developing teeth. In: Andreasen JO, Andreasen FM, Andersson L, editors. Textbook and color atlas of traumatic injuries to the teeth. 4th ed. Copenhagen: Munksgaard; 2007. p. 542-76.
- Leonardo MR, Silva LA, Leonardo Rde, Utrilla LS, Assed S. Histological evaluation of therapy using a calcium hydroxide dressing for teeth with incompletely formed apices and periapical lesions. *J Endod.* 1993;19(7):348-52.
- Felippe MC, Felipe WT, Marques MM, Antoniazzi JH. The effect of renewal of calcium hydroxide paste on the apexification and periapical healing of teeth with incomplete root formation. *Int Endod J.* 2005;38(7):436-42.
- Torabinejad M, Hong CU, Lee SJ, Monsef M, Pitt Ford TR. Investigation of mineral trioxide aggregate for root-end filling in dogs. *J Endod.* 1995; 21(12):603-8.
- Torabinejad M, Pitt Ford TR, McKendry DJ, Abedi HR, Miller DA, Kariyawasam SP. Histologic assessment of mineral trioxide aggregate as a root-end filling in monkeys. *J Endod.* 1997;23(4):225-8.
- Torabinejad M, Watson TF, Pitt Ford TR. Sealing ability of a mineral trioxide aggregate when used as a root end filling material. *J Endod.* 1993;19(12):591-5.
- Simon S, Rilliard F, Berdal A, Machtou P. The use of mineral trioxide aggregate in one-visit apexification treatment: a prospective study. *Int Endod J.* 2007;40(3):186-97.
- D'Arcangelo C, D'Amario M. Use of MTA for orthograde obturation of nonvital teeth with open apices: report of two cases. *Oral Surg Oral Med Oral Pathol Oral Radiol Endod.* 2007;104(4):e98-101. Epub 2007 Jul 10.
- Siqueira JF Jr, Guimarães-Pinto T, Rôças IN. Effects of chemomechanical preparation with 2.5% sodium hypochlorite and intracanal medication with calcium hydroxide on cultivable bacteria in infected root canals. *J Endod.* 2007;33(7):800-5.
- Hülsmann M, Hahn W. Complications during root canal irrigation—literature review and case reports. *Int Endod J.* 2000;33(3):186-93.
- Ghaziani P, Aghasizadeh N, Sheikh-Nezami M. Endodontic treatment with MTA apical plugs: a case report. *J Oral Sci.* 2007;49(4):325-9.
- Camões IC, Salles MR, Chevitarrese O. Ca<sup>2+</sup> diffusion through dentin of Ca(OH)<sub>2</sub> associated with seven different vehicles. *J Endod.* 2003;29(12):822-5.
- Hülsmann M, Heckendorff M, Lennon A. Chelating agents in root canal treatment: mode of action and indications for their use. *Int Endod J.* 2003;36(12):810-30.

14. Metzger Z, Solomonov M, Mass E. Calcium hydroxide retention in wide root canals with flaring apices. *Dent Traumatol.* 2001;17(2):86-92.
15. Andreasen JO, Farik B, Munksgaard EC. Long-term calcium hydroxide as a root canal dressing may increase risk of root fracture. *Dent Traumatol.* 2002;18(3):134-7.
16. Dominguez Reyes A, Muñoz Muñoz L, Aznar Martín T. Study of calcium hydroxide apexification in 26 young permanent incisors. *Dent Traumatol.* 2005;21(3):141-5.
17. Binnie WH, Rowe AH. A histological study of the periapical tissues of incompletely formed pulpless teeth filled with calcium hydroxide. *J Dent Res.* 1973;52(5):1110-6.
18. Shabahang S, Torabinejad M, Boyne PP, Abedi H, McMillan P. A comparative study of root-end induction using osteogenic protein-1, calcium hydroxide, and mineral trioxide aggregate in dogs. *J Endod.* 1999;25(1):1-5.
19. El-Meligy OA, Avery DR. Comparison of apexification with mineral trioxide aggregate and calcium hydroxide. *Pediatr Dent.* 2006;28(3):248-53.