

# Hemisection as an Alternative Treatment for Decayed Multirooted Terminal Abutment: A Case Report

*M. Najeeb Saad, BDS, Cert Prosth; Jorge Moreno, DDS, Cert Endo; Cameron Crawford, BSc (Hons)*

## Auteur-ressource

*Dr Saad*  
Courriel : [najeeb.saad@schulich.uwo.ca](mailto:najeeb.saad@schulich.uwo.ca)



## SOMMAIRE

L'hémisection d'une molaire inférieure peut s'avérer un traitement approprié lorsque la carie se limite à une racine et que l'autre racine est saine. Cet article décrit et illustre un cas où la dent-pilier terminale cariée faisait partie d'une prothèse fixe. L'hémisection et la restauration prothétique ont donné des résultats satisfaisants.

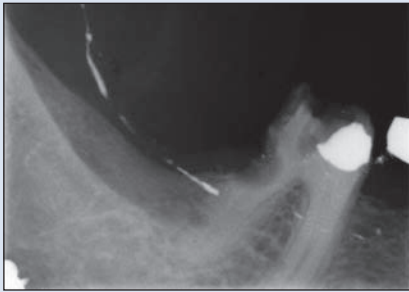
Pour les citations, la version définitive de cet article est la version électronique : [www.cda-adc.ca/jcda/vol-75/issue-5/387.html](http://www.cda-adc.ca/jcda/vol-75/issue-5/387.html)

A terminal abutment molar with extensive decay may be unsuitable for restoration. In such cases, the treatment options are limited and may include a removable partial denture or a dental implant to replace the missing tooth.<sup>1</sup> Alternatively, if the decay is limited to one root, a hemisection procedure may be possible. This procedure represents a form of conservative dentistry, aiming to retain as much of the original tooth structure as possible.<sup>2</sup> The results are predictable, and success rates are high if certain basic considerations are taken into account.<sup>3</sup>

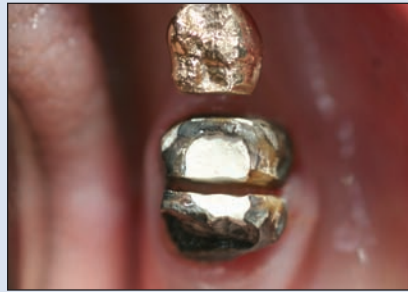Periodontal, prosthodontic and endodontic assessment for appropriate selection of cases is important. From a periodontal perspective, this procedure is indicated if there is severe bone loss limited to one root or involvement of a Class III furcation that could produce a stable root after hemisection. This procedure is also appropriate if the patient is unable to perform appropriate oral hygiene in the area. Extensive exposure of the roots because of dehiscence is another indication for excision of one root.<sup>4</sup> From a restorative standpoint, treatment by hemisection

is indicated for failure of an abutment within a fixed prosthesis, provided a portion of the tooth can be retained to act as the abutment for the prosthesis. Untreatable endodontic failure, due to circumstances such as perforations and broken instruments, is another indication for hemisection. Other indications include vertical root fracture confined to a single root of a multirooted tooth or any severe destructive process that is confined to a single root, including caries, external root resorption and trauma. Contraindications include the presence of a strong abutment tooth adjacent to the proposed hemisection, which could act as an abutment to a prosthesis. The remaining root may be inoperable for the necessary root canal treatment. Also, fusion or proximity of the roots may prevent their separation.<sup>4</sup>

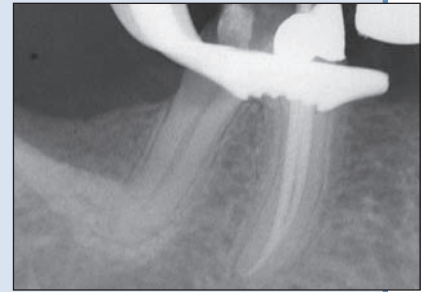
Hemisection (removal of one root) involves removing significantly compromised root structure and the associated coronal structure through deliberate excision.<sup>5</sup> Appropriate endodontic therapy must be performed before these tooth modifications to avoid intrapulpal



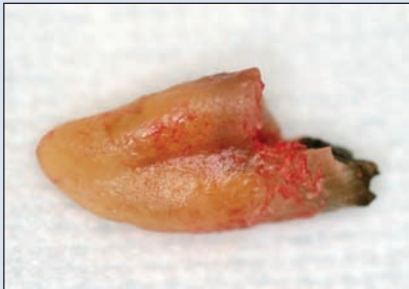**Figure 1:** Radiograph showing near obliteration of the distal root of tooth 46 by decay.



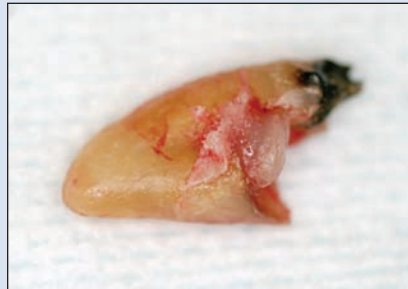**Figure 2:** Sectioned tooth after pulpectomy.



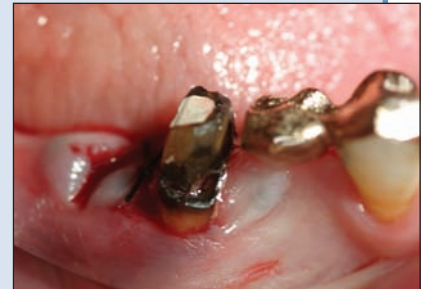**Figure 3:** Periapical radiograph of endodontically treated mesial canals.



**Figure 4a:** Distal view of extracted root.



**Figure 4b:** Mesial view of extracted root.



**Figure 5:** After extraction, the distal aspect of the mesial root was smoothed and the tissue sutured.

dystrophic calcification and postoperative tooth sensitivity.<sup>6</sup> The furcation region is carefully smoothed, to allow proper cleansing and thus to prevent accumulation of plaque.<sup>6</sup> Root fracture is the main cause of failure after hemisection, so occlusal modifications are required to balance the occlusal forces on the remaining root.<sup>7</sup>

### Case Report

An 82-year-old woman reported to the dental clinic with intermittent pain on the lower right side of the mouth. The patient was missing several teeth in the maxillary arch, which had been replaced by a removable partial denture; she was also missing several teeth in the posterior mandibular arch. There were two 3-unit fixed partial dentures replacing teeth 35 and 45 on either side. In the mandibular left quadrant, teeth 34 and 36 acted as retainers; in the mandibular right quadrant, teeth 44 and 46 were the retainers. The fixed partial denture in the fourth quadrant was an all-gold prosthesis; tooth 46 had a full-coverage retainer, and tooth 44 was a three-quarter retainer.

Intraoral examination revealed no clinically relevant findings for the fixed partial denture in the third quadrant, but the distal margin of the tooth 46 retainer was open, and there was evidence of decay extending subgingivally. Radi-

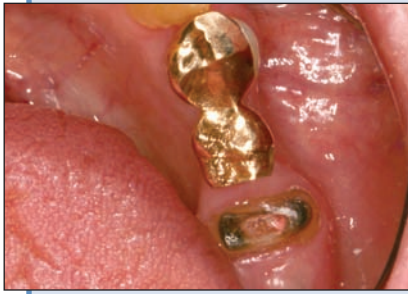ography revealed that the decay had almost obliterated the coronal third of the distal root (Fig. 1).

The extent of decay rendered the tooth nonrestorable. However, the patient was reluctant to lose the tooth, as she had enjoyed success with her fixed partial denture for over 10 years, with good chewing efficiency and function. She asked if there was any treatment available that would preserve her prosthesis. Various options were presented, including extraction followed by placement of 2 implants to replace the tooth in the extraction site and the pontic area of tooth 45. Because the decay was limited to the distal root, hemisection with a remake of the existing fixed partial denture was also suggested. Given the patient's reluctance to lose the fixed partial denture, she chose hemisection, as the result would be most similar to her existing prosthesis.

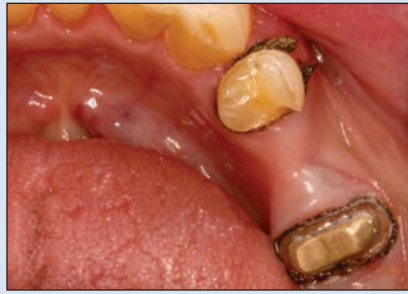The procedure was performed as follows:

1. The fixed partial denture was sectioned at the connector between teeth 45 and 46, and the crown on tooth 46 was removed. Pulpectomy was performed, and a temporary glass ionomer restoration was placed (Ketac Silver Aplicap, 3M ESPE, St. Paul, Minn.) (Fig. 2).


2. At the next appointment the root canal treatment was completed in both of the mesial canals (Fig. 3). Obturation was accomplished with a thermoplastic synthetic polymer filling material (Resilon, Pentron,



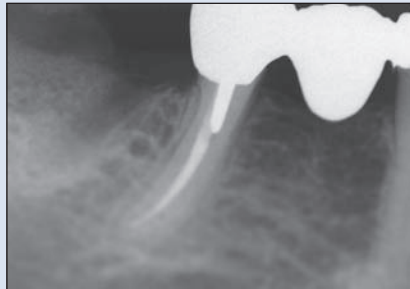**Figure 6:** Occlusal view of glass ionomer build-up after fracture.



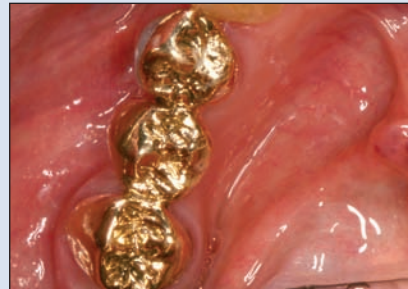**Figure 7:** Occlusal view of cemented post.



**Figure 8:** Fixed partial denture, fabricated in the laboratory.



**Figure 9:** Final radiograph, confirming proper seating.



**Figure 10:** Final result.

Wallington, Conn.), and a glass ionomer temporary restoration (Ketac Silver Aplicap) was completed to seal the pulp chamber. A mucoperiosteal flap was raised to expose the bony crest preparatory to the hemisection procedure. The mesial and distal roots were sectioned at the level of the furcation. The distal root was extracted (Figs. 4a and 4b), and the flap was closed. A finishing diamond bur was used to smooth the distal area of the mesial root and its coronal portion (Fig. 5).

3. At a follow-up appointment 2 weeks later, it was noted that the glass ionomer build-up had fractured (Fig. 6). At this point, it was determined that sufficient tooth structure remained for fabrication of a post-and-core restoration. Gutta-percha (10 mm) was removed from the orifice. A polyvinyl siloxate (PVS) impression was obtained with a sterilized metal post and a ¼-inch stock tray. A cotton pellet and temporary restorative material were placed in the tooth (Cavit, 3M ESPE, St. Paul).

4. When the patient returned for the next appointment, the cotton pellet and temporary restorative material were removed from the tooth, and the post was tried in. Once the seating had been confirmed radiographically, the abutment and pontic were removed, and the path of insertion for the 3-unit fixed partial denture was verified visually. The post was then cemented using glass ionomer cement (Fig. 7). The

margin was modified, a retraction cord was placed, and a final impression was made using PVS in a full-arch stock tray. Bite registration was recorded with rigid resin on the distal abutment. A temporary fixed partial denture was fabricated from BIS-GMA (bisphenylglycidyl dimethacrylate (Integrity, Dentsply, Philadelphia, Penn.) and cemented with non-eugenol temporary cement (Temp-Bond NE, Orange, Calif.).

5. The mandibular impression and the bite record were sent to the laboratory, for pouring and mounting to the maxillary cast (which was also provided). Instructions for the laboratory included a request for fabrication of a 3-unit fixed partial denture in type IV gold (Fig. 8), with no excursive contact and contacts only in maximum intercuspation.

6. When the laboratory-fabricated fixed partial denture was received, the temporary denture was removed. Proper seating was verified, and the proximal contacts on the mesial surface of tooth 44 and the distal surface of tooth 43 were checked. Occlusion was checked with articulating paper, and the fixed partial denture was cemented with an auto-cure resin-based cement (RelyX ARC, 3M ESPE). The excess cement was removed, occlusion was re-verified and a periapical radiograph was obtained to ensure proper seating (Fig. 9).

7. At follow-up, occlusion was stable, there was no inflammation, and the patient was satisfied with the outcome (Fig. 10). No complications were noted when the patient was seen 1 year later.

## Discussion

For this patient, hemisection was selected for treatment of root decay in the terminal abutment of a fixed prosthesis. Implant therapy was considered but not chosen; instead, a 3-unit fixed partial denture, extending from the hemisected molar to the premolar, was completed. The distal root was resected because of the location of the decay. The literature on distal root resection is limited; more often, this root is retained and the mesial root removed. However, the distal root is broader and straighter, making it more suitable as an abutment.<sup>8</sup> The mesial root contains a longitudinal groove, which decreases its surface area and contraindicates the use of posts.

Implant therapy is a predictable option with good functionality;<sup>9</sup> however, in this case, the patient chose an alternative treatment because of financial considerations and her desire to retain a previously placed fixed partial denture. The implant option would have required either placement of a single implant in the region of the missing second premolar or placement of 2 implants to replace an extracted molar and a missing premolar; the latter option would have required ridge augmentation.

Hemisection allows for physiologic tooth mobility of the remaining root, which is thus a more suitable abutment for fixed partial dentures than an osseointegrated counterpart.<sup>2</sup> The smaller size of the occlusal tables, undercutting of the embrasure spaces and ensuring that the crown margin encompasses the furcation are all factors in the high success rates observed with hemisection therapy.<sup>6</sup>

In conclusion, hemisection may be a suitable alternative to extraction and implant therapy and should be discussed with patients during consideration of treatment options. ♦

**Correspondence to:** Dr. M. Najeeb Saad, Schulich School of Medicine & Dentistry, The University of Western Ontario, Dental Sciences Building, Room 0148, London, ON N6A 5C1.

The authors have no declared financial interests in any company manufacturing the types of products mentioned in this article.

This article has been peer reviewed.

## References

1. Koka S. Is an implant-supported restoration better than a fixed partial denture to replace single missing teeth? *Compend Contin Educ Dent* 2006; 27(3):156, 158–61.
2. Kost WJ, Stakiw JE. Root amputation and hemisection. *J Can Dent Assoc* 1991; 57(1):42–5.
3. Kurtzman GM, Silverstein LH, Shatz PC. Hemisection as an alternative treatment for vertically fractured mandibular molars. *Compend Contin Educ Dent* 2006; 27(2):126–9.
4. Weine FS. Endodontic therapy. 5th ed. St. Louis: Mosby; 1996.
5. Bühler H. Survival rates of hemisected teeth: an attempt to compare them with survival rates of alloplastic implants. *Int J Periodontics Restorative Dent* 1994; 14(6):536–43.
6. Rapoport RH, Deep P. Traumatic hemisection and restoration of a maxillary first premolar: a case report. *Gen Dent* 2003; 51(4):340–2.
7. Kryshalskyj E. Root amputation and hemisection. Indication, technique and restoration. *J Can Dent Assoc* 1986; 52(4):307–8.
8. Rosenstiel SF, Land MF, Fujimoto J. Contemporary fixed prosthodontics. 2nd ed. St. Louis: MosbyYear Book, Inc.; 1995.
9. Bashutski JD, Wang HL. Common implant esthetic complications. *Implant Dent* 2007; 16(4):340–8.

## THE AUTHORS



**Dr. Saad** is assistant professor in the division of restorative dentistry, Schulich School of Medicine & Dentistry, The University of Western Ontario, London, Ontario.



**Dr. Moreno** is assistant professor in the division of restorative dentistry, Schulich School of Medicine & Dentistry, The University of Western Ontario, London, Ontario.



**Mr. Crawford** is a dental student, Schulich School of Medicine & Dentistry, The University of Western Ontario, London, Ontario.