

# Radiographic Diagnosis of Synovial Chondromatosis of the Temporomandibular Joint: A Case Report

**Ashok Balasundaram, BDS, DDS, MDS, MS; James R. Geist, DDS, MS;**  
**Sara C. Gordon, DDS, MSc, FRCD(C); Gary D. Klasser, DMD**

## Auteur-ressource

**Dr Balasundaram**  
Courriel :  
[balasuas@udmercy.edu](mailto:balasuas@udmercy.edu)



## SOMMAIRE

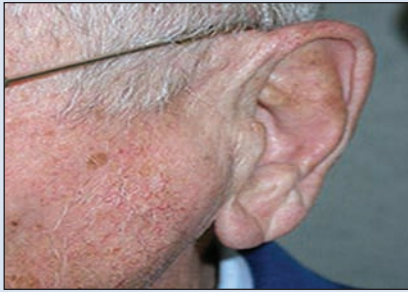La chondromatose synoviale est une affection bénigne rare qui touche habituellement les plus grosses diarthroses du squelette axial. Quelque 120 cas de chondromatose synoviale de l'articulation temporomandibulaire (ATM) ont été répertoriés. La chondromatose synoviale peut s'accompagner d'œdème, de douleur, de bruits intracapsulaires et d'une limitation des mouvements mandibulaires. Comme il est important de distinguer la chondromatose synoviale des autres pathologies articulaires, il est essentiel d'obtenir une anamnèse complète et de faire une évaluation approfondie des caractéristiques cliniques. La radiographie est un élément important de l'arsenal diagnostique utilisé pour distinguer les affections qui ressemblent à la chondromatose synoviale. Nous décrivons un cas de chondromatose synoviale diagnostiqué par tomodensitométrie volumétrique, puis discutons des facteurs étiologiques possibles et de stratégies de prise en charge. Un bref aperçu du diagnostic différentiel de la chondromatose synoviale de l'ATM est aussi présenté.

Pour les citations, la version définitive de cet article est la version électronique : [www.cda-adc.ca/jcda/vol-75/issue-10/711.html](http://www.cda-adc.ca/jcda/vol-75/issue-10/711.html)

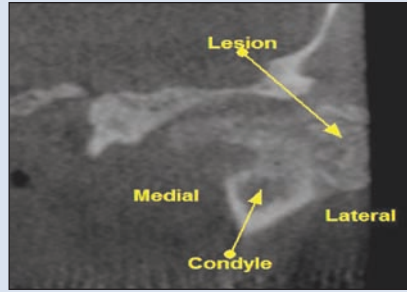
Synovial chondromatosis is a rare benign condition that usually affects the larger diarthroidal joints of the axial skeleton,<sup>1</sup> typically the knee (35%), elbow (22%), wrist (11%) and hip (4%). The temporomandibular joint (TMJ) is infrequently affected, with approximately 120 cases reported in the literature. Bilateral involvement is extremely rare (only 1 case reported). It appears that in the TMJ, synovial chondromatosis involves only the superior joint space. "Loose bodies" found in the inferior joint space are due to perforation of the articular disk and migration of these bodies from the superior joint space.<sup>2,3</sup> Females are affected more frequently than males. The average age of those affected is 44.4 years (range: 21–66 years). Signs and symptoms of

synovial chondromatosis of the TMJ typically include swelling, pain, intracapsular sounds (clicking, crepitation or both) and limitation of mandibular movement.

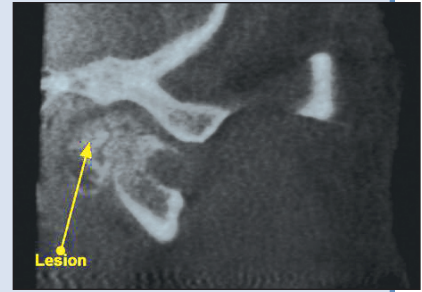
Synovial chondromatosis is characterized by the formation of fragments of cartilage, i.e., loose bodies, in the synovial membrane of the affected joint. In the primary form, fibroblasts beneath the synovial membrane undergo metaplasia and deposit chondromucin. These cartilaginous bodies enlarge and finally detach from the synovial membrane. The secondary form occurs subsequent to pre-existing joint disease, such as arthritis or traumatism, and involves synovial nourishment of dislodged fragments of soft tissue.<sup>4</sup> It is difficult to determine whether synovial chondromatosis is



**Figure 1:** Clinical photograph of patient with preauricular swelling.



**Figure 2:** Coronal cone beam volumetric computed tomography image slice showing the left condyle and lesion.



**Figure 3:** Sagittal cone beam volumetric image slice showing condyle and lesion.

primary or secondary until a careful history and clinical examination are undertaken.

Accurate diagnosis of synovial chondromatosis is based on history and clinical, radiographic and microscopic examination. Signs and symptoms of synovial chondromatosis of the TMJ do not differ from those of other conditions affecting the TMJ. Therefore, careful attention must be paid to the clinical and radiologic features of all lesions affecting this joint.

Radiographic modalities available for diagnosis of synovial chondromatosis include plain film radiography, plain film tomography, computed tomography (CT), magnetic resonance imaging (MRI) and radionuclide scanning. Plain film radiography is inexpensive but the images suffer from distortion. CT produces excellent detail of hard and soft tissue, but with higher radiation doses than for plain film radiography. MRI is non-ionizing and produces excellent soft tissue resolution, but is costly and of limited availability. Radionuclide scanning is usually used to determine metabolic activity in a lesion.

Advanced imaging methods, such as CT and MRI, reveal the extent and character of the lesion and have contributed to an increase in the number of reported cases of synovial chondromatosis.<sup>4</sup> CT and MRI are invaluable diagnostic tools, as they can also show changes associated with synovial chondromatosis, such as temporal bone sclerosis and extension of the lesion into the cranial cavity. On both plain films and CT, findings associated with synovial chondromatosis may also include widening of joint space, irregularity of the joint surface, the presence of loose calcified nodules and sclerosis of the glenoid fossa and mandibular condyle.<sup>5</sup>

CT is particularly useful in the radiographic diagnosis of synovial chondromatosis because hard tissues, such as calcified cartilaginous bodies, are easily identified. CT also depicts the lesion in multiple planes. For example, coronal CT can help detect intracranial extension of synovial

chondromatosis of the TMJ. Also, CT allows customization of specific protocols to visualize bone or soft tissue.

Volumetric computed tomography (VCT) has wide application, such as presurgical assessment of implant sites, orthodontics and evaluation of TMJ-related pathology in the maxillofacial region. In cone beam VCT, the scanning process involves a single rotation of the x-ray source contiguous with the detector, thus reducing scan time. The advantages of cone beam VCT include simplified design and, most important, reduced radiation dose to the patient.<sup>6</sup>

### Case Report

An 82-year-old man presented to the University of Detroit Mercy School of Dentistry clinic with a swelling on the left side of his face that had developed over the past 5 years (**Fig. 1**). Discomfort, which occurred before the swelling, was described as persistent, gnawing and worse at night. No history of limitation of mandibular movement or intracapsular sounds was associated with the swelling. For many decades after suffering painful repetitive jaw trauma while serving in the armed forces during World War II, the patient had experienced episodic tenderness in the left TMJ on prolonged mouth opening. Three years before presentation, he had visited his primary care physician for evaluation of the swelling, which had been clinically diagnosed as a benign tumour.

The patient's current medical history included managed hypertension and hypercholesterolemia; he had a past history of adenoma of the thyroid gland and cerebrovascular accident (without neurologic deficit). The patient's medications included acetylsalicylic acid, furosemide, benazepril, simvastatin, calcium carbonate, glucosamine and omega-3 fatty acid. His dental history included previous visits for periodontal maintenance, restoration and maxillary and mandibular partial denture fabrication.

A well-circumscribed 50 mm × 40 mm extraoral swelling was present in the left preauricular region (**Fig. 1**). Palpation revealed a hard, non-tender mass. The patient's

**Table 1** Differential diagnosis of synovial chondromatosis

Diagnosis	Distinguishing characteristics
Synovial chondromatosis	Loose bodies in synovial space; cortical outline of bone unaltered; calcifications can attain a large size
Osteoarthritis (joint mice)	Small calcifications
Chondrocalcinosis (pseudogout)	Fine calcifications; even distribution
Osteochondroma	Arises from condylar head; cartilage cap present
Pigmented villonodular synovitis	Not localized to a portion of the joint
Osteochondritis dissecans	Younger patients; associated with osteochondral fracture

maximum mouth opening was 35 mm, both assisted and unassisted, with deflection of the mandible to the left side. An asymptomatic click was identified on the left side of the TMJ on closing. No associated tenderness or pain in the lateral capsules of the TMJ was elicited on palpation, at rest or during mandibular movements.

A panoramic radiograph revealed a radiopacity adjacent to the left condyle. As the extent of the lesion could not be evaluated in its entirety, we decided to image the patient's TMJ using a cone beam VCT scanner. The classic i-CAT standard VCT scanner (Imaging Sciences International, Hatfield, PA) was used. The x-ray tube and detector rotated 360° around the head of the patient at a constant beam angle.

Cone beam VCT images localized the lesion in all planes, revealing a well-defined radiopaque–radiolucent mass on the anteromedial aspect of the left condyle, extending to completely involve the posterior region of the condyle (Figs. 2 and 3). The lesion was clearly separated from the condylar surface. There was evidence of mild flattening of the condyle suggesting degenerative change, but the cortical outline appeared intact. Joint space was reduced due to expansion of the lesion into the glenoid fossa.

The history, clinical examination and especially the cone beam VCT findings helped to establish a presumptive radiographic diagnosis of synovial chondromatosis of the left TMJ in this patient. The patient was referred to an oral and maxillofacial surgeon for biopsy and treatment.

## Discussion

Synovial chondromatosis of extragnathic joints is rare and involvement of the TMJ even rarer. Georg Axhausen<sup>7</sup> first described synovial chondromatosis of the TMJ in 1954 as metaplastic chondrogenesis in the synovial membrane.

The secondary form of synovial chondromatosis is particularly relevant in our case report. The patient was a World War II veteran with a convincing history of repeated trauma to the jaws and the TMJ and symptoms of joint disease extending over many decades. Several studies<sup>8,9</sup> report a correlation between traumatic events and develop-

ment of synovial chondromatosis. Repeated trauma to the jaws and the resulting blunt force transmitted to the joint could have been an initiating factor in the formation of loose bodies that later calcified and presented as synovial chondromatosis of the TMJ in our patient.

Synovial chondromatosis of the TMJ is difficult to differentiate from similar lesions affecting the TMJ (Table 1). Osteoarthritis is an age-related degenerative disease, common in women. Common radiographic findings in osteoarthritis include osteophyte formation, erosion, flattening, sclerosis of mandibular fossa and reduction in joint space.<sup>10</sup> Although osteoarthritis may affect the joint space, the calcifications (joint mice) are smaller. In our patient, the size of the calcifications and the apparently normal cortical outlines of the mandibular condyle and fossa did not favour a diagnosis of osteoarthritis.

Calcium pyrophosphate dihydrate disease (CPDD), or pseudogout, is a type of arthritis caused by the precipitation of calcium pyrophosphate crystals. It is considered a disease of older patients. Fewer than 30 cases affecting the TMJ have been described. The radiographic appearance of CPDD is called chondrocalcinosis, which resembles synovial chondromatosis histologically and radiographically.<sup>11,12</sup> However, CPPD of the TMJ is rare and usually associated with predisposing factors.<sup>13</sup> There were no predisposing factors evident in our patient, nor did he show any sign of a metabolic disease (gout).

Osteochondroma is a cartilage-capped bony growth usually affecting the appendicular skeleton and rarely involving the mandibular condyle. CT usually depicts the continuity between the cortical outline of native bone and the tumour, a feature that was absent in our patient.<sup>14</sup> Cone beam VCT images of our patient clearly showed a distinct separation of the calcified lesion from the adjacent condylar head.

Pigmented villonodular synovitis and osteochondritis dissecans are both reactive joint conditions that can cause focal calcifications and should be included in the differential diagnosis.<sup>15,16</sup> However, neither of these conditions is accompanied by large calcifications such as those found in our patient.

The appropriate treatment for synovial chondromatosis includes surgical removal of calcifications followed by total or subtotal synovectomy. Our patient, considering his age and medical condition, declined intervention. The lesion is stable 5 years after diagnosis with no evidence of change in size or character.

The diagnostic yield from a readily accessible 3D imaging modality cannot be underestimated. Although a panoramic image confirmed the presence of the lesion, spatial information in all 3 dimensions was critical in establishing a diagnosis. The distinct separation of the lesion from the condyle, only seen in the cone beam VCT images, and the massive size of the calcifications helped us arrive at a diagnosis. Cone beam VCT images also confirmed the site of origin of the lesion at the joint space, which helped narrow our diagnosis. It does not seem that the calcified lesion in our case report could represent any lesion other than synovial chondromatosis, pending microscopic examination.

### Conclusion

The various radiographic modalities used to evaluate a case of synovial chondromatosis of the TMJ have been elucidated. In particular, the utility of a dental CT scanner in diagnosing a lesion involving the TMJ is emphasized. General dentists must be aware of the availability of this new imaging technology and its ability to diagnose maxillofacial anomalies with radiation doses as low as reasonably achievable. ✦

### THE AUTHORS



**Dr. Balasundaram** is an assistant professor in the radiology division, department of diagnostic sciences, School of Dentistry, University of Detroit Mercy, Detroit, Michigan.



**Dr. Geist** is a professor in the department of diagnostic sciences, School of Dentistry, University of Detroit Mercy, Detroit, Michigan.



**Dr. Gordon** is an associate professor in the department of oral medicine and diagnostic sciences, University of Illinois at Chicago, College of Dentistry, Chicago, Illinois.



**Dr. Klasser** is an assistant professor in the department of oral medicine and diagnostic sciences, University of Illinois at Chicago, College of Dentistry, Chicago, Illinois.

**Correspondence to:** Dr. Ashok Balasundaram, Radiology division, Department of diagnostic sciences, University of Detroit Mercy, 2700 Martin Luther King Boulevard, Detroit, MI 48208, USA.

The authors have no declared financial interests in any company manufacturing the types of products mentioned in this article.

This article has been peer reviewed.

### References

- Reddy PK, Vannemreddy PS, Gonzalez E, Nanda A. Synovial chondromatosis of the temporomandibular joint with intracranial extension. *J Clin Neurosci*. 2000;7(4):332-4.
- von Lindern JJ, Theuerkauf I, Niederhagen B, Berge S, Appel T, Reich RH. Synovial chondromatosis of the temporomandibular joint: clinical, diagnostic, and histomorphologic findings. *Oral Surg Oral Med Oral Pathol Oral Radiol Endod*. 2002;94(1):31-8.
- Holmlund AB, Eriksson L, Reinholt FP. Synovial chondromatosis of the temporomandibular joint: clinical, surgical and histological aspects. *Int J Oral Maxillofac Surg*. 2003;32(2):143-7.
- Huh JK, Park JY, Lee S, Lee SH, Choi SW. Synovial chondromatosis of the temporomandibular joint with condylar extension. *Oral Surg Oral Med Oral Pathol Oral Radiol Endod*. 2006;101(6):e83-8. Epub 2006 Apr 24.
- Nitzan DW, Marmary Y, Fields SI, Shteyer A. The diagnostic value of computed tomography in temporomandibular joint synovial chondromatosis. *Comput Med Imaging Graph*. 1991;15(1):53-6.
- Sukovic P. Cone beam computed tomography in craniofacial imaging. *Orthod Craniofac Res*. 2003;6 Suppl 1:31-6; discussion 179-82.
- Axhausen G. Arthritis deformans of the temporomandibular joint. *Dtsch Zahnarztl Z*. 1954;9(15):852-9. German.
- Reyes Macías JF, Sánchez Prieto M. Synovial chondromatosis of the temporomandibular joint. *Med Oral Patol Oral Cir Bucal*. 2007;12(1):E26-9.
- Nussenbaum B, Roland PS, Gilcrease MZ, Odell DS. Extra-articular synovial chondromatosis of the temporomandibular joint: pitfalls in diagnosis. *Arch Otolaryngol Head Neck Surg*. 1999;125(12):1394-7.
- Alexiou K, Stamatakis H, Tsiklakis K. Evaluation of the severity of temporomandibular joint osteoarthritic changes related to age using cone beam computed tomography. *Dentomaxillofac Radiol*. 2009;38(3):141-7.
- Eriksson L, Mertens F, Akerman M, Wiegant J. Calcium pyrophosphate dihydrate crystal deposition disease in the temporomandibular joint: diagnostic difficulties and clonal chromosome aberrations in a case followed up for 5 years. *J Oral Maxillofac Surg*. 2001;59(10):1217-20.
- Covani U, Orlando B, Galletti C, Nuterini C, Barone A. Chondrocalcinosis of the temporomandibular joint: clinical considerations and case report. *Cranio*. 2009;27(2):134-9.
- Chuong R, Piper MA. Bilateral pseudogout of the temporomandibular joint: report of case and review of literature. *J Oral Maxillofac Surg*. 1995;53(6):691-4.
- Avinash KR, Rajagopal KV, Ramakrishnaiah RH, Carnelio S, Mahmood NS. Computed tomographic features of mandibular osteochondroma. *Dentomaxillofac Radiol*. 2007;36(7):434-6.
- Oda Y, Izumi T, Harimaya K, Segawa Y, Ishihara S, Komune S, et al. Pigmented villonodular synovitis with chondroid metaplasia, resembling chondroblastoma of the bone: a report of three cases. *Mod Pathol*. 2007;20(5):545-51. Epub 2007 Mar 2.
- Orhan K, Arslan A, Kocyigit D. Temporomandibular joint osteochondritis dissecans: case report. *Oral Surg Oral Med Oral Pathol Oral Radiol Endod*. 2006;102(4):e41-6. Epub 2006 Jul 14.