

Primary Squamous Cell Carcinoma of the Maxillary Alveolus in a 10-year-old Girl

Aziz Binahmed, DDS, MDent, MSc, FRCD(C); **Makepeace Charles**, BSc, Med, DDS;
Paolo Campisi, MSc, MD, FRCSC, FAAP; **Vito Forte**, MD, FRCSC;
Robert P. Carmichael, DMD, MSc, FRCD(C);
George K.B. Sándor, MD, DDS, PhD, FRCD(C), FRCSC, FACS

Auteur-ressource

Dr Sándor
Courriel : george.sandor@utoronto.ca



SOMMAIRE

Le carcinome spinocellulaire de la bouche est rare dans la population pédiatrique. Toutefois, lorsqu'il survient, on le voit le plus souvent sur la langue ou la lèvre. Dans le présent article, on signale un cas rare de carcinome spinocellulaire de la gencive et de l'alvéole du maxillaire supérieur chez une fillette de 10 ans et on examine la littérature disponible au sujet du carcinome spinocellulaire de la bouche dans la population pédiatrique.

Pour les citations, la version définitive de cet article est la version électronique : www.cda-adc.ca/jcda/vol-73/issue-8/715.html

Cancers of the oral cavity account for about 3% of all cancers diagnosed each year in North America: 27,000 newly diagnosed cases a year in the United States and 3,200 in Canada. Slightly more than 10,000 Americans and 1,100 Canadians die of oral cancer each year.^{1,2}

The incidence of oral cancer increases with age in all parts of the world. In western countries, 98% of patients are over 40 years of age.³ In areas of high prevalence, due to heavy use of various forms of tobacco, many patients are < 35 years of age. During the past 3 decades, there has been an alarming rise in the incidence of oral cancer, particularly among younger men.³

Squamous cell carcinoma (SCC) of the oral cavity is rare in pediatric patients. The tongue and lower lip are the most frequently reported sites.⁴ In this article, we report a rare case of SCC of the maxillary gingiva in a prepubescent female.

Case Report

A healthy 10-year-old girl was referred to a community oral and maxillofacial surgeon by her pediatric dentist for investigation of a nonhealing ulcer surrounding mobile teeth, including the permanent left maxillary canine and first and second premolars (**Fig. 1**). A lytic lesion of the left maxillary alveolus was noted on periapical radiographs (**Fig. 2**). After an incisional biopsy, a diagnosis of an invasive well-differentiated SCC was made, and the patient was referred to a tertiary medical centre for definitive management.

Clinical examination revealed an ulcerative lesion encompassing the area of the left maxillary canine and extending distally to the first premolar on the left side, with mobility of teeth 22, 24 and 25 (**Figs. 3 and 4**). There were no palpable lymph nodes in the cervical area. Panoramic radiographs and computed tomography (CT) of the head and neck showed

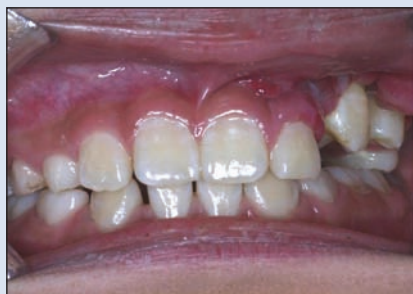

Figure 1: Ulcerative lesion on the labial aspect of the maxillary left canine and first premolar before incisional biopsy.

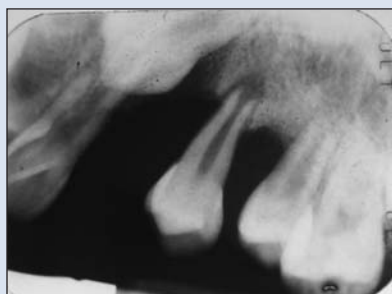


Figure 2: Periapical radiograph showing bone destruction around the maxillary left canine and first premolar.

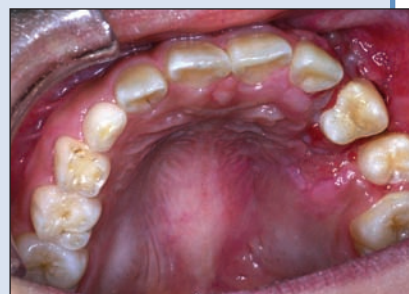

Figure 3: At the time of referral, the lesion had extended to involve the palatal aspect of the maxillary left first premolar.

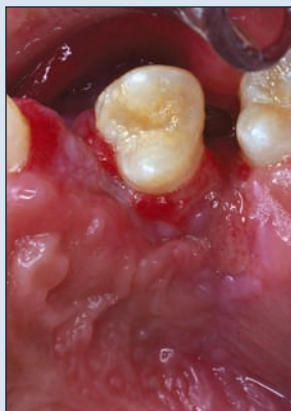

Figure 4: Close-up view of the lesion, which extends around the palatal aspect of the maxillary first premolar.

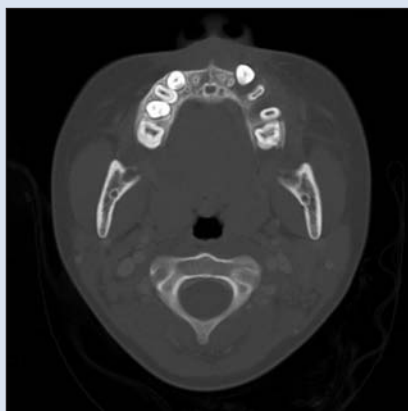

Figure 5: Computed tomography scan with axial cut showing the lytic lesion in the left maxilla involving the permanent left canine and premolars.

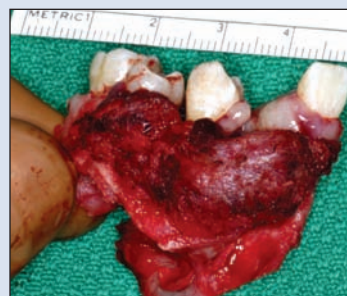

Figure 6: Specimen tissue from the partial maxillectomy resection containing the maxillary left lateral incisor, canine, first and second premolars and permanent first molar.

a lytic lesion involving the alveolus of the left maxilla (**Fig. 5**). No evidence of regional or distant metastases appeared on plain radiograph films or CT and magnetic resonance imaging scans. The initial biopsies were re-evaluated by the department of pathology at the tertiary care centre, confirming the diagnosis of SCC. The stage of the tumour was estimated to be T1N0M0.

The patient had no family history of childhood malignancy or of exposure to secondhand smoke. She had no history of systemic disease, previous trauma or extensive dental treatment. The patient's growth and development had been normal, and she had attained all expected milestones.

The patient underwent a left partial maxillectomy using an intraoral approach and a left supraomohyoid neck dissection (**Fig. 6**). The maxillary sinus mucosa was removed and the sinus defect was packed with iodine gauze. The palate was reconstructed with a prefabricated interim obturator that was secured in position with palatal screws. The post-operative period was uneventful.

Histologic examination of the excised specimen revealed a well-differentiated SCC (**Fig. 7**) with negative margins. None of the lymph nodes from the neck dissection specimen showed any evidence of metastatic disease. The interim obturator (**Fig. 8**) and packing were removed 2 weeks after surgery, and a more permanent obturator bearing prosthetic teeth was inserted. The patient has been followed closely for 2 years since her surgery and is disease free (**Fig. 9**).

Discussion

SCC of the head and neck is rare in the pediatric population: fewer than 2% of all pediatric head and neck malignancies.⁵ Very few cases of pediatric SCC have been reported in the medical literature; the tongue is the most commonly reported site.^{4,6} In an extensive review of the literature, Amichetti⁷ identified 21 cases of SCC of the tongue in patients < 15 years of age and added 1 case of his own.

In a review by the Armed Forces Institute of Pathology (AFIP),⁴ 20 cases of oral SCC in patients < 20 years of age

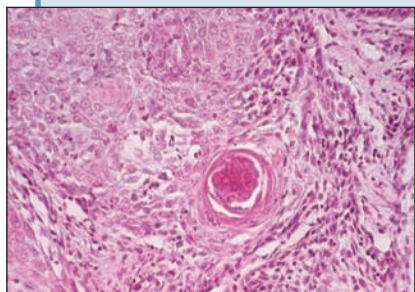


Figure 7: Excised tissue stained with hematoxylin and eosin showing the histologic appearance of a well-differentiated squamous cell carcinoma.

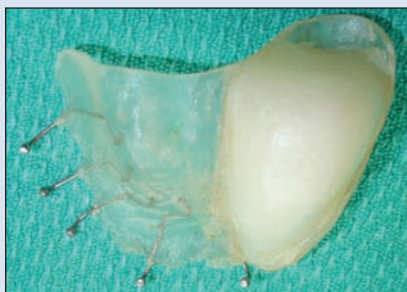

Figure 8: The temporary obturator keeps the maxillectomy wound dressed with packing and separates the oral and nasal cavities to allow the swallowing of solids and fluids without nasal regurgitation. The obturator also permits intelligible speech; it would otherwise have a hypernasal quality.

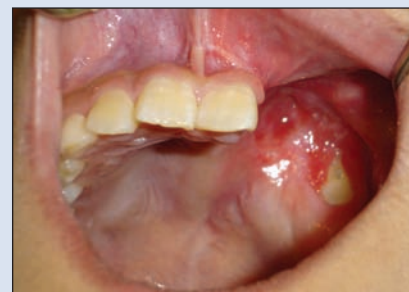

Figure 9: Intraoral defect resulting from excision of the lesion. This was ultimately reconstructed with an obturator bearing teeth.

were identified (mean age 15 years). Nine of these were in the tongue. The male to female ratio was 1:1. Of the 18 patients receiving long-term follow-up, 14 were treated with surgery only, while the remaining 4 patients received adjuvant radiotherapy for cervical lymph node metastasis. After a follow-up of at least 5 years, 14 patients were disease free (mean age 17.9 years), 2 had died of the disease (the mean survival time from diagnosis in these 2 patients was 0.7 years) and 2 had died with no evidence of disease. The AFIP reports a good prognosis with adequate surgical treatment of these tumours. Zwetyenga and others⁸ reported a treatment failure rate of 50% in 16 patients, but this was for epidermoid carcinoma of the oral cavity among patients who were < 20 years of age. In a recent review of Mayo clinic cases, Thompson and others⁶ reported 3 more cases of oral SCC, 2 in the tongue and 1 involving the hard palate.

Etiologic factors associated with oral SCC in adults, such as tobacco, alcohol, viruses and nutritional deficiencies, do not necessarily apply to pediatric cases. Genetic conditions such as Fanconi's anemia,⁹ xeroderma pigmentosum¹⁰ and keratitis, ichthyosis and deafness (KID) syndrome¹¹ convey an increased risk of mucosal carcinoma in children. Amichetti⁷ suggests that chewing and sucking plastic material may be a predisposing factor in his case, due to exposure to a carcinogenic material (polyvinyl chloride) and chronic irritation. Others have suggested an association of these tumours with extensive dental treatment⁶ and exposure to human papilloma virus. None of these etiologic factors was present in our case.

A relatively rare location for SCC, the maxillary alveolus is the site of fewer than 10% of all oral carcinomas in the adult population.¹² The reported 5-year survival rate is 21%–76%.^{12,13}

Earls and others¹⁴ described the case of a 6-year-old boy with SCC of the maxillary alveolus that was treated

with a subtotal maxillectomy and reconstructed with a prosthetic obturator. The patient was disease free 30 months after surgery. Sacks and others¹⁵ also reported a case of a 13-year-old boy who presented with an upper gingival mass that was initially diagnosed as pseudoepitheliomatous hyperplasia on biopsy. After local excision of the lesion, histologic examination of the tissue showed a well-differentiated SCC with positive margins. The patient was then treated with a subtotal maxillectomy and was disease free 2 years after the second surgery.

In 1998, the head and neck service at Heliopolis Hospital in São Paulo, Brazil,¹⁶ reported another 4 cases of pediatric oral SCC, 2 of them in the upper gingiva. A 6-year-old girl with a T1N0M0 stage tumour of the upper gingiva was treated with wide intraoral excision and reconstructed with a prosthetic obturator. The patient was disease free 10.5 years after her surgery. The second case involved the gingivobuccal sulcus of a 14-year-old boy who was diagnosed with a T4N2bM0 SCC. He was treated with surgical resection and neck dissection, followed by adjuvant radiotherapy. The patient died 6 months after treatment with local failure and distant metastasis.

Review of the literature suggests that wide surgical resection is the preferred treatment modality, as radiotherapy in this age group may have a significant negative impact on facial growth and soft and hard tissue development and increase the risk of developing a second malignancy.⁸

This case report, together with previously reported cases, indicates that oral SCC can occur in pediatric patients. Biopsies of nonhealing lesions in the oral cavity are, therefore, essential. The prognosis of the disease can be altered by early diagnosis and surgical treatment. ♦

THE AUTHORS



Dr. Binahmed is consultant, department of surgery, King Abdulaziz Medical City, Riyadh, Saudi Arabia, and former fellow, pediatric oral and maxillofacial surgery, The Hospital for Sick Children and University of Toronto, Toronto, Ontario, and department of surgical oncology, Cancer Care Manitoba, University of Manitoba, Winnipeg, Manitoba.



Dr. Charles is chief resident, division of oral and maxillofacial surgery and anesthesia, University of Toronto, Toronto, Ontario.



Dr. Campisi is assistant professor, department of otolaryngology — head and neck surgery, The Hospital for Sick Children, University of Toronto, Toronto, Ontario.



Dr. Forte is otolaryngologist-in-chief, The Hospital for Sick Children, and professor, department of otolaryngology — head and neck surgery, University of Toronto, Toronto, Ontario.



Dr. Carmichael is chief of dentistry, Bloorview Kids Rehab, coordinator of prosthodontics, The Hospital for Sick Children, and assistant professor, University of Toronto, Toronto, Ontario.



Dr. Sándor is clinical director, graduate program in oral and maxillofacial surgery and anesthesia, Mount Sinai Hospital, coordinator, pediatric oral and maxillofacial surgery, The Hospital for Sick Children and Bloorview Kids Rehab, professor of oral and maxillofacial surgery, University of Toronto, Toronto, Ontario, and docent in oral and maxillofacial surgery, University of Oulu, Oulu, Finland.

Correspondence to: Dr. George K.B. Sándor, The Hospital for Sick Children, S-525, 555 University Ave., Toronto ON M5G 1X8.

The authors have no declared financial interests.

This article has been peer reviewed.

References

1. Jemal A, Murray T, Samuels A, Ghafoor A, Ward E, Thun MJ. Cancer statistics, 2003. *CA Cancer J Clin* 2003; 53(1):5–26.
2. National Cancer Institute of Canada. Canadian Cancer Statistics 2006. Toronto: Ontario. Canadian Cancer Society. Available from URL: www.cancer.ca/vgn/images/portal/cit_86751114/31/21/935505792cw_2006stats_en.pdf (accessed September 4, 2007).
3. Llewellyn CD, Johnson NW, Warnakulasuriya KA. Risk factors for squamous cell carcinoma of the oral cavity in young people — a comprehensive literature review. *Oral Oncol* 2001; 37(5):401–18.
4. Thompson L, Castle J, Heffner DK. Oral squamous cell carcinoma in pediatric patients: a clinicopathologic study of 20 cases. [Abstract] *Oral Surg Oral Med Oral Pathol Oral Radiol Endod* 1999; 88(2):204.
5. Albright JT, Topham AK, Reilly JS. Pediatric head and neck malignancies: US incidence and trends over 2 decades. *Arch Otolaryngol Head Neck Surg* 2002; 128(6):655–9.
6. Thompson DM, Olsen K, Hinni M. Oral cavity SCCA: a rare entity in adolescent patients. [Abstract] Presented at the 11th International Conference on Oral Cancer, Grado, Italy, 14–17 May 2006.
7. Amichetti M. Squamous cell carcinoma of the oral tongue in patients less than fifteen years of age. Report of a case and review of the literature. *J Craniomaxillofac Surg* 1989; 17(2):75–7.
8. Zwetyenga N, Gargiulo M, Demeaux H, Siberchicot F, Majoufre-Lefebvre C. Epidermoid carcinoma of oral cavity in patients less than twenty. *Rev Stomatol Chir Maxillofac* 2004; 105(4):201–5. [Article in French]
9. Kaplan MJ, Sabio H, Wanebo HJ, Cantrell RW. Squamous cell carcinoma in the immunosuppressed patient: Fanconi's anemia. *Laryngoscope* 1985; 95(7 Pt 1):771–5.
10. Grob JJ, Breton A, Bonafe JL, Sauvan-Ferdani M, Bonerandi JJ. Keratitis, ichthyosis, and deafness (KID) syndrome. Vertical transmission and death from multiple squamous cell carcinomas. *Arch Dermatol* 1987; 123(6):777–82.
11. Kraemer KH, Lee MM, Scotto J. Xeroderma pigmentosum. Cutaneous, ocular, and neurologic abnormalities in 830 published cases. *Arch Dermatol* 1987; 123(2):241–50.
12. Evans JF, Shah JP. Epidermoid carcinoma of the palate. *Am J Surg* 1981; 142(4):451–5.
13. Shibuya H, Horiuchi J, Suzuki S, Amagasa M, Mashima K. Oral carcinoma of the upper jaw. Results of radiation treatment. *Acta Radiol Oncol* 1984; 23(5):331–5.
14. Earle AS, Park CH, Vlastou C. Oral squamous cell carcinoma in children. *Ann Plast Surg* 1988; 20(2):148–52.
15. Sacks HG, Holly R, Blum B, Joy ED. Case 58: maxillary alveolar mass in a 13-year-old boy. *J Oral Maxillofac Surg* 1985; 43(12):958–63.
16. de Carvalho MB, Sobrinho Jde A, Rapoport A, Fava AS, Mendes AF, Kanda JL, and others. Head and neck squamous cell carcinoma in childhood. *Med Pediatr Oncol* 1998; 31(2):96–9.