

External Cervical Resorption Associated with Traumatic Occlusion and Pyogenic Granuloma

Rouzbeh Vossoughi, DDS; Henry H. Takei, DDS, MS

Auteur-ressource

Dr Vossoughi
Courriel : [rvossoughi@
yahoo.com](mailto:rvossoughi@yahoo.com)



SOMMAIRE

Cet article décrit un cas rare, où une résorption cervicale externe a été associée à une tuméfaction gingivale (granulome pyogène) au niveau de l'incisive centrale gauche supérieure (dent 21), chez un homme de 28 ans. Un examen histopathologique a été fait des tissus de la lésion; des traitements parodontaux, endodontiques et restaurateurs ont ensuite été pratiqués et la disharmonie occlusale, qui avait causé l'occlusion traumatique, a été corrigée. Trois ans après ces traitements, les gencives étaient normales et en bonne santé, sans aucun signe de récurrence de la tuméfaction pathologique. Depuis, l'état du parodonte du patient est évalué régulièrement. Dans les cas de tuméfaction gingivale causée par une inflammation, l'occlusion traumatique peut entraîner une résorption radiculaire externe évolutive.

Pour les citations, la version définitive de cet article est la version électronique : www.cda-adc.ca/jcda/vol-73/issue-7/625.html

P yogenic granuloma is a reactive lesion that represents an overexuberant reaction by connective tissue to a known stimulus or injury. It appears as a red mass because it is composed of hyperplastic granulation tissue in which capillaries are prominent. It is commonly seen on the gingiva, where it is presumably caused by calculus or foreign material within the gingival crevice.¹ Although peripheral giant-cell granuloma may, rarely, cause bone or tooth resorption,² cervical resorption has never been associated with pyogenic granuloma.

Resorption of teeth on the external surface may be caused by chronic inflammatory lesions, cysts, benign or malignant tumours,³ trauma from a single event, malocclusion⁴ or excessive orthodontic forces⁵ or it may be idiopathic. The pathogenesis of external resorption from these causes has been related to the release of chemical mediators, increased vascularity and pressure. External root resorption may occur in 2 patterns: the resorption may start at the root apex

and progress coronally or it may occur immediately apical to the cemento-enamel junction (CEJ)⁶ below the epithelial attachment and coronal to the alveolar process, which is the zone of connective tissue attachment. The latter pattern results in external cervical resorption.⁷

In 1967, Southam⁸ described external cervical resorption as a separate category from other forms of external resorption. He stated that, in most cases, it is possible to probe the defect via the gingival sulcus.

Radiographically, external root resorption may appear as a uniform radiolucency with a smooth, regular outline; macroscopically, a concave cavity is seen. However, a non-uniform preferential spread is also possible and may result in fingers of resorptive tissue extending in different directions, often with little lateral spread at the site of initiation. Radiographically, this produces an irregular, diffuse radiolucency of non-uniform radiodensity.⁹

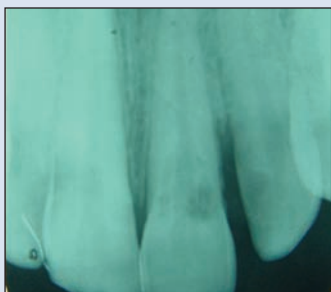

Figure 1: Periapical radiograph of tooth 21 showing a radiolucent area at the distal aspect of the tooth.

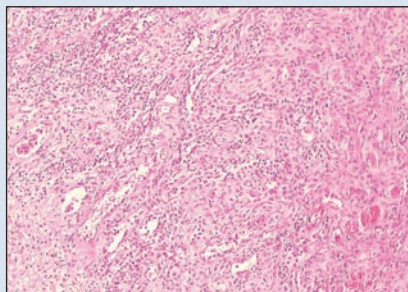


Figure 2: Microscopic view of pyogenic granuloma showing hyperplastic granulation tissue and numerous chronic inflammatory cells and capillaries (hematoxylin and eosin stain, 100x).

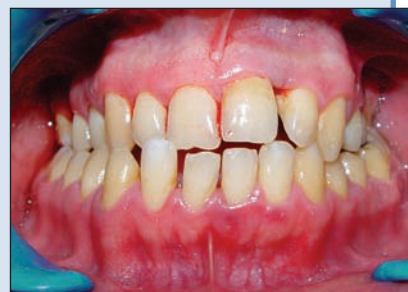

Figure 3: Clinical view of tooth 21 at the beginning of the second appointment. Note the occlusal disharmony.

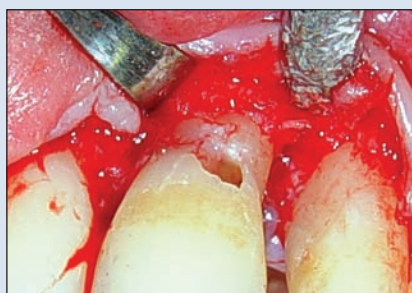

Figure 4: The extent of the resorption lesion and the granulation tissue occupying it.

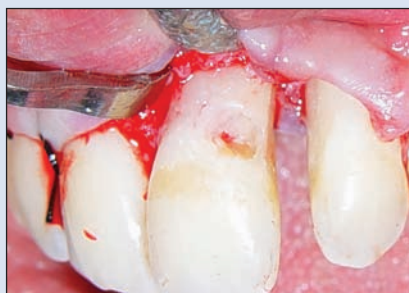

Figure 5: Pulp exposure.

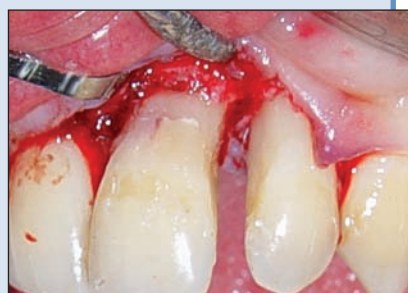

Figure 6: Restoration of the resorption defect with conventional glass ionomer cement.

When occlusal force exceeds the adaptive capacity of the tissues, injury results, i.e., trauma from occlusion. The most common result of traumatic occlusion is the resorption of the alveolar bone in the areas under excessive pressure, resorption of cementum and root surface and formation of cemental tears.¹⁰

Case Report

A 28-year-old man with unremarkable medical history presented with a mass on the palatal and interproximal aspect of tooth 21. Intraoral examination revealed poor oral hygiene, generalized inflammation of the gingiva and bleeding on probing, especially around the incisor and molar regions. Traumatic occlusion of tooth 21 and resulting labial migration were noted. The traumatic occlusion was associated with fremitus on centric occlusion and occlusal interference during protrusive movements. A 6-mm pocket on the distal aspect of tooth 21 and calculus were detected during the clinical examination. During a radiographic survey, an irregular radiolucency was noticed on the cervical portion of the crown (**Fig. 1**). The patient had no previous endodontic signs or symptoms. Both teeth 11 and 21 responded positively to an electric pulp test. A provisional diagnosis of

mild chronic periodontitis associated with a reactive lesion and a defect of unknown etiology was made.

The first treatment session was aimed at managing the enlarged mass and controlling gingival inflammation. The main body of the mass, which also involved the interproximal and labial aspects of tooth 21, was completely excised and submitted for histopathologic examination (**Fig. 2**). During scaling and debridement, a resorptive lesion was discovered in the cervical portion of the crown. The patient was informed of this and scheduled to return for a corrective procedure.

A week later, the patient returned for a second appointment (**Fig. 3**). A full-thickness periodontal flap was raised (**Fig. 4**), the surgical site was thoroughly scaled and the root was planed. The flap was extended to the adjacent incisor to maintain an even gingival contour. The enlarged gingival tissue at the distal and labial aspect was excised, recontouring the gingival margin. The raising of the flap and removal of the tissue from the resorptive cavity revealed well-demarcated external cervical resorption bordered mostly by enamel except in the apical portion, which had also involved the CEJ. There was no soft dentin, but exposed pulp was revealed during the excavation (**Fig. 5**). The cavity was

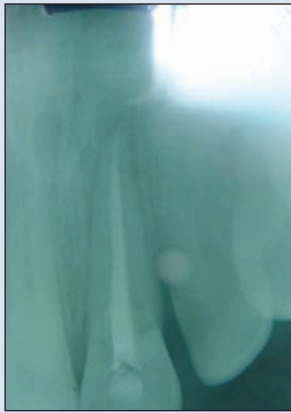

Figure 7: Radiographic view after root canal.

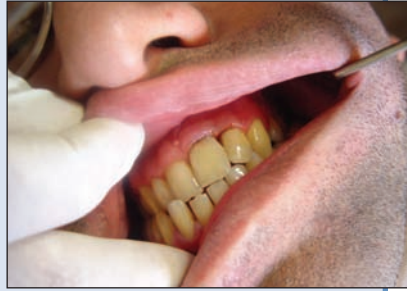

Figure 8: Labial view after restoration with light-cured composite.

cleaned and shaped using a diamond bur, then restored with conventional glass ionomer (**Fig. 6**).

The flap was approximated and sutured and occlusal adjustment was carried out to correct the occlusal interference in both centric and eccentric movements. Endodontic therapy was carried out at another appointment (**Fig. 7**) and required esthetic therapy with conventional tooth-coloured material to correct the existing diastema and to enhance appearance (**Fig. 8**). Orthodontic treatments were ruled out because the patient refused 18 months of fixed orthodontic therapy.

Discussion

This is a very rare case of external cervical resorption, bordered at the surface mostly by enamel and associated with localized gingival enlargement on a tooth with traumatic occlusion.

The enlarged mass was diagnosed as a pyogenic granuloma. The cause of such soft tissue enlargement is a chronic localized irritating factor, such as dental plaque or calculus,¹ both of which were found in this case. The unusual characteristic of this lesion was its association with external cervical resorption. Recently a case of external cervical resorption associated with gingival overgrowth (fibrous epulis) was reported,¹¹ and another report described the association of external cervical resorption with a peripheral giant-cell granuloma.² External cervical resorption has never been associated with a pyogenic granuloma.

Many causes have been suggested for external cervical resorption, of which inflammation of the periodontal tissues,^{12,13} trauma⁴ and internal bleaching¹⁴ are among the most common. The congenital absence of cementum⁸ or the presence of cemental defects¹⁵ due to physical injuries to the root surface⁷ have been mentioned as predisposing factors in the pathogenesis of root resorption.

In 1999, Heithersay¹⁶ reported that 16.4% of 257 teeth showing cervical resorption did not have predisposing factors. He suggested that some of these cases may have had undetectable developmental defects, such as hypoplasia or hypomineralization of cementum.

Studies of the CEJ reveal that dentin exposure occurs in 18% of all cases.¹⁷ Schroeder and Scherle¹⁸ found that 4 aspects of the same tooth may have different CEJ characteristics, with dentin exposure occurring more often on the buccal and distal surfaces. These reports suggest that the CEJ area may often be devoid of cementum in healthy teeth. In 2000, Neuvald and Consolaro¹⁹ examined CEJs using scanning electron microscopy and concluded that the cervical region may be prone to external resorption.

The cause of this resorption is thought to be related to local alteration in the periodontal microenvironment, leading to exposure of specific dentin proteins. During development of immunity, these structural proteins remain isolated from the cellular elements responsible for antigen recognition. When such proteins are exposed, they are not recognized by the body, causing an immune response represented by cellular mobilization to eliminate the antigens, with clast cells as the principal agents.¹⁹ Dentin exposure alone can lead to transitory resorption,¹⁸ but is not sufficient to cause a progressive resorption process because its proteins are embedded within a mineralized, well-organized structure.²⁰

Tronstad⁷ hypothesized that cervical resorption is probably initiated by injury to the cervical periodontal ligament apparatus apical to the epithelial attachment. This may be initially transient, but if bacterial challenge is superimposed, the process is perpetuated and becomes progressive.

The close relation of periodontal connective tissues to a root surface deprived of cementum and periodontal ligament cells may result in significant root resorption.²¹ In the present case, the lesion was mainly in enamel. Patel and others¹¹ explained the histogenesis of enamel resorption in a report of gingival overgrowth associated with external cervical resorption. They suggested that the resorption had begun on the denuded root surface (immediately apical to the CEJ) and progressed to involve mainly enamel because of the proximity of the periodontal connective tissue fibres to the denuded root surface.

In the present case, traumatic occlusion of tooth 21 could also lead to external root resorption. It has been widely accepted that heavy occlusal forces can cause resorption of a tooth and its lateral bony support.²² Many reports consider traumatic occlusion to be the initiating factor in external resorption^{23,24} and a propagating stimulus for progressive resorption.²⁵ One can hypothesize that alteration of the root

surface (i.e., cemental tears and a resulting denuded root surface) because of traumatic occlusion can instigate transitory resorption,¹⁹ which in the presence of inflammation in the area can lead to a progressive pathologic state.^{7,13} The resulting defect on the root surface can also propagate and aggravate inflammation of the adjacent gingiva as it may retain plaque.

Our patient claimed that he had noticed the existence of the enlarged mass 3 months before visiting his dentist, but he had experienced gingival bleeding in the incisor region while brushing for years. Thus, the etiologic origin of the lesion in this case was not identified, and inflammation in the periodontium in combination with the traumatic occlusion resulting from the antagonist tooth 31 were most probably the responsible factors. We were unable to identify which of these 2 factors was the inductive factor and which was the contributing factor.

In theory, pulp should not have been exposed as a result of the external cervical resorption as predentin inhibits this process. However, residual dentin may be thin and weakened enough to be broken mechanically.²⁶ Although the patient had no signs or symptoms of pulpal involvement, pulp exposure was detected during excavation and probing at the second treatment session. Due to the time-consuming nature of root canal treatment, the restorative treatment was performed before the endodontic treatment. We suggest that endodontic treatment be carried out before restoring a resorptive defect²⁷ because of the probability of damage to the restoration during root canal therapy. ❖

THE AUTHORS



Dr. Vossoughi is a resident in the general practice residency program, SUNY Stony Brook School of Dental Medicine, Stony Brook, New York.



Dr. Takei is professor, periodontics section, UCLA School of Dentistry, Los Angeles, California.

Correspondence to: Dr. Rouzbeh Vossoughi, 300 Edwards St. #GEE, Roslyn Heights, New York 11577 USA.

The authors have no declared financial interests.

This article has been peer reviewed.

References

1. Regezi J, Sciubba J. Oral pathology: clinical-pathologic correlations. 2nd ed. Philadelphia: WB Saunders; 1993. p. 142.
2. Nedir R, Lombardi T, Samson J. Recurrent peripheral giant cell granuloma associated with cervical resorption. *J Periodontol* 1997; 68(4):381-4.
3. Fuss Z, Tsesis I, Lin S. Root resorption — diagnosis, classification and treatment choices based on stimulation factors. *Dent Traumatol* 2003; 19(4):175-82.
4. Brin I, Tulloch JF, Koroluk L, Philips C. External apical root resorption in Class II malocclusion: a retrospective review of 1- versus 2-phase treatment. *Am J Orthod Dentofacial Orthop* 2003; 124(2):151-6.
5. Weiland F. External root resorptions and orthodontic forces: correlations and clinical consequences. *Prog Orthod* 2006; 7(2):156-63.

6. Regezi J, Sciubba J. Abnormalities of the dental pulp. In: Oral pathology: clinical-pathologic correlations. 2nd ed. Philadelphia: WB Saunders; 1993. p. 515-7.
7. Tronstad L. Root resorption — etiology, terminology and clinical manifestations. *Endod Dent Traumatol* 1988; 4(6):241-52.
8. Southam JC. Clinical and histological aspects of peripheral cervical resorption. *J Periodontol* 1967; 38(6):534-8.
9. Makkes PC, Thoden van Velzen SK. Cervical external root resorption. *J Dent* 1975; 3(5):217-22.
10. Ishikawa I, Oda S, Hayashi J, Arakawa S. Cervical cemental tears in older patients with adult periodontitis. Case reports. *J Periodontol* 1996; 67(1):15-20.
11. Patel K, Darbar UR, Gulabivala K. External cervical resorption associated with localized gingival overgrowth. *Int Endod J* 2002; 35(4):395-402.
12. Kerr DA. The cementum: its role in periodontal health and disease. *J Periodontol* 1961; 32(3):183-9.
13. Dragoo MR, Sullivan HC. A clinical and histological evaluation of autogenous iliac bone grafts in humans. External root resorption. *J Periodontol* 1973; 44(10):614-25.
14. Cvek M, Lindvall AM. External root resorption following bleaching of pulpless teeth with oxygen peroxide. *Endod Dent Traumatol* 1985; 1(2):56-60.
15. Rotstein L, Torek Y, Misgav R. Effect of cementum defects on radicular penetration of 30% H₂O₂ during intracoronary bleaching. *J Endod* 1991; 17(5):230-33.
16. Heithersay GS. Invasive cervical resorption: an analysis of potential predisposing factors. *Quintessence Int* 1999; 30(2):83-95.
17. Muller CJ, van Wyk CW. The amelo-cemental junction. *J Dent Assoc S Africa* 1984; 39(12):799-803.
18. Schroeder E, Scherle WF. Cemento-enamel junction — revisited. *J Periodontol Res* 1988; 23(1):53-9.
19. Neuvald L, Consolaro A. Cementoenamel junction: microscopic analysis and external cervical resorption. *J Endod* 2000; 26(9):503-8.
20. Butler WT, D'Souza RN, Bronckers AL, Happonen RP, Somerman MJ. Recent investigations on dentin specific proteins. *Proc Finn Dent Soc* 1992; 88(Suppl 1):369-76.
21. Nyman S, Karring T, Lindhe J, Planten S. Healing following implantation of periodontitis-affected roots into gingival connective tissue. *J Clin Periodontol* 1980; 7(5):394-401.
22. Hallmon WW. Occlusal trauma: effect and impact on the periodontium. *Ann Periodontol* 1999; 4(1):102-8.
23. Yusof WZ, Ghazali MN. Multiple external root resorption. *J Am Dent Assoc* 1989; 118(4):453-5.
24. Bergamo FC. Total root resorption due to occlusal trauma. *Oral Surg Oral Med Oral Pathol* 1969; 27(5):647.
25. Wood P, Rees JS. An unusual case of furcation external resorption. *Int Endod J* 2000; 33(6):530-3.
26. Bergmans L, Van Cleynenbreugel J, Verbeke E, Wevers M, Van Meerbeek B, Lambrechts P. Cervical external root resorption in vital teeth. *J Clin Periodontol* 2002; 29(6):580-5.
27. Gulabivala K, Searson LJ. Clinical diagnosis of internal resorption: an exception to the rule. *Int Endod J* 1995; 28(5):255-60.