

# Bruxism in Children: A Warning Sign for Psychological Problems

Andréa Gonçalves Antonio, DDS; Viviane Santos da Silva Pierro, DDS;  
Lucianne Cople Maia, DDS, MSD, PhD

## Auteure-ressource

Dre Antonio  
Courriel : [agantonio2002@yahoo.com.br](mailto:agantonio2002@yahoo.com.br)



## SOMMAIRE

Le bruxisme correspond au serrement ou au grincement non fonctionnels des dents. Il s'agit d'une habitude destructrice qui peut mener à l'usure des dents. Bien que les recherches sur le bruxisme soient poussées, son étiologie est encore sujette à débat. La littérature suggère que le bruxisme est lié au stress de la vie à la fois vécu et projeté. Le but de cette étude est de décrire 2 cas graves de bruxisme chez des enfants de même âge mais dont le vécu diffère, et de discuter des facteurs qui pourraient déclencher cet état pathologique parafunctionnel.

Mots clés MeSH : bruxism/etiology; bruxism/psychology; child

© J Can Dent Assoc 2006; 72(2):155–60  
Cet article a été révisé par des pairs.

**B**ruixism is involuntary, excessive grinding, clenching or rubbing of teeth during nonfunctional movements of the masticatory system.<sup>1,2</sup> Reported prevalence in children ranges from 7% to 15.1%,<sup>3–5</sup> with girls apparently more frequently affected.<sup>6</sup>

Bruxism can occur during the day or night.<sup>7</sup> Generally, patients clench their teeth throughout the day and gnash and clench them during sleep.<sup>8</sup> However, nocturnal bruxism is more frequent; it varies with the individual and has been related to emotional or physical stress.<sup>9</sup>

Bruxism usually causes tooth wear as evidenced by wear facets that can range from mild to severe and can be localized or found throughout the dentition.<sup>9</sup> Other trauma to the dentition and supporting tissues include thermal hypersensitivity, tooth hypermobility, injury to the periodontal ligament and periodontium, hypercementosis, fractured cusps and pulpitis and pulpal necrosis.<sup>2</sup>

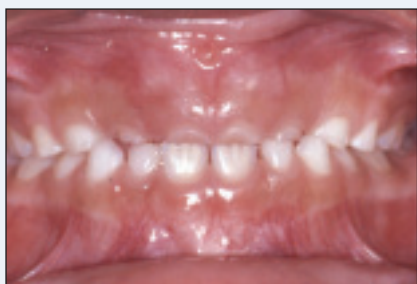Various theories regarding the etiology of bruxism have been reported and they fall into the following categories: occlusion-

related,<sup>2,10,11</sup> psychological<sup>9,12,13</sup> and originating within the central nervous system.<sup>11</sup> Before instituting any therapeutic measures, the practitioner must look at all the medical and dental data, particularly because the etiology of bruxism may be multifactorial.<sup>2,14</sup> Therapeutic approaches can include occlusal adjustment of dentition, use of interocclusal appliances,<sup>15</sup> behaviour modification<sup>13</sup> and pharmaceuticals.<sup>16</sup>

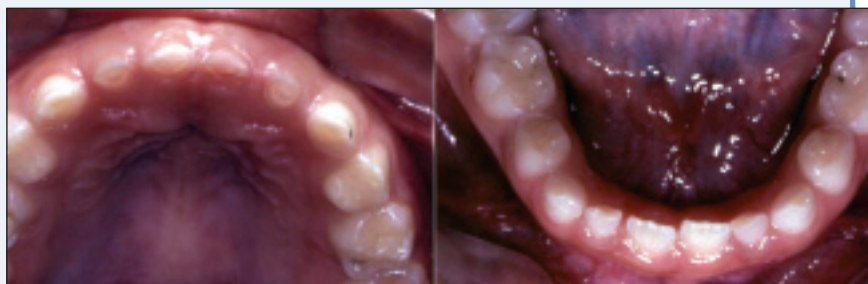Owing to inconsistent support for a physical propensity for bruxism, some researchers have explored the effect of life events on this activity.<sup>1</sup> In this report, we describe 2 cases of severe bruxism in children with different life histories and discuss the possible factors that could have triggered this parafunctional condition.

## Case Reports

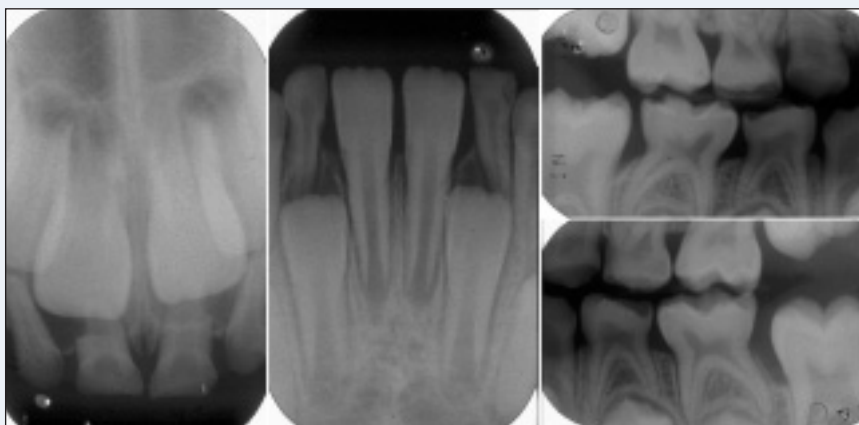
The case reports are of 2 children referred to the pediatric dental clinic of a public university in Rio de Janeiro, Brazil. The chief complaint of both mothers was the presence of tooth wear in their children's dentition.



**Figure 1a:** Frontal view of the patient's occlusion.



**Figure 1b:** Pronounced wear in all anterior primary teeth and worn occlusal facets in teeth 55, 65, 75, 74 and 84.



**Figure 1c:** Radiography confirms the wear and fractures in the primary teeth, as well as lack of damage to the supporting tissues.

### Case 1

A 6-year-old boy was brought to the pediatric dental clinic by his mother. On history, his mother revealed that he gnashed his teeth at night, but she could not tell for how long this had been going on. The child's medical history showed chronic respiratory problems, due to allergy, and an absence of gastroesophageal reflux. No previous dental treatment was reported. Ingestion of acid drinks or medication was denied. Although the mother described the child as highly excitable, during the consultation he was extremely shy and introspective. His mother reported that they lived in a violent area, where shootings frequently occurred and that her child usually became apprehensive after these incidents.

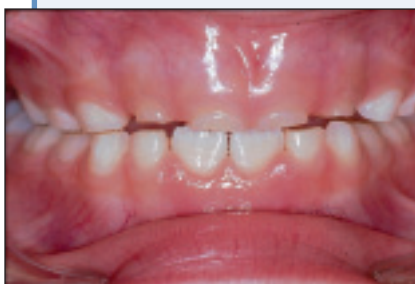Clinical examination revealed that the patient was at the early mixed-dentition stage, with erupting maxillary and mandibular permanent first molars and mandibular permanent central incisors. There was a mesial step relation between maxillary and mandibular primary second molars on both the right and left sides, while maxillary and mandibular primary canines showed a bilateral Class I relation. There was no midline deviation or malocclusions (**Fig. 1a**). No occlusal interferences, mandibular deviation, mouth-opening limitation or any other clinical sign indicating temporomandibular

dysfunction was noticed during intraoral clinical examination. Good oral hygiene was observed; no carious lesions or gingival inflammation were present, although the patient presented a worn glass ionomer cement restoration in tooth 55. The incisal faces of all anterior maxillary primary teeth were badly worn. Worn occlusal facets in teeth 55, 65, 75, 74, 73, 72, 82, 83 and 84 were also present (**Fig. 1b**). There were small fractures in the palatine cusps of teeth 54 and 64 and in the distovestibular cusp of tooth 85. The child had no history of pain, even with mechanical stimulation.

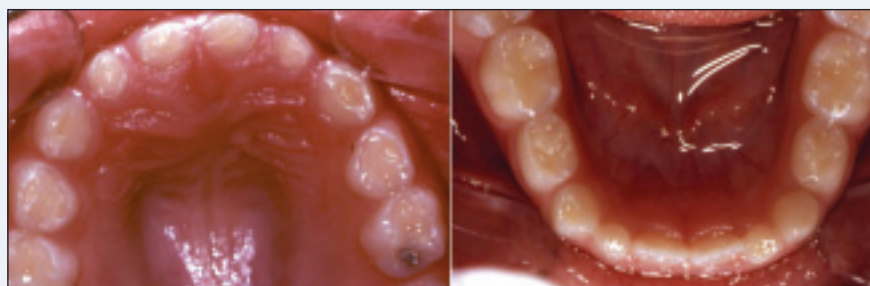
Radiographic examination confirmed pronounced wear in the above-mentioned primary teeth and small fractures in the cusps of teeth 54, 64 and 85. No damage to supporting tissues was verified (**Fig. 1c**).

The treatment plan for this patient was threefold: replacement of the worn glass ionomer restoration in tooth 55 with composite resin; placement of a soft-based bite-plate, 3 mm thick, on the maxillary arch for night use; and referral for psychological monitoring and allergy treatment.

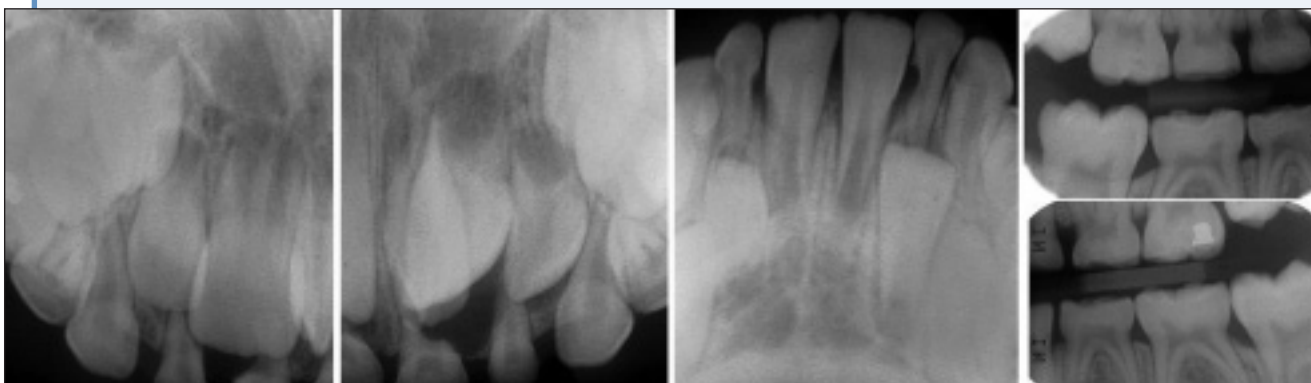
Follow-up visits were scheduled every third month to verify tooth wear and monitor eruption of permanent teeth and bone growth. When necessary, splints were modified to allow adequate bone growth.



**Figure 2a:** Functional mandibular deviation without crossbite.



**Figure 2b:** Pronounced wear in all primary teeth.



**Figure 2c:** Radiography confirms the pronounced wear on the primary teeth, the presence of a mesiodens and the absence of injury to the supporting tissues.

## Case 2

A 7-year-old boy was brought to the pediatric dental clinic by his parents. According to his mother, the child usually clenched his teeth throughout the day and gnashed and clenched them during sleep. She stated that he suffered from “night terror,” diagnosed by his pediatrician, although he was not being treated for it. His mother reported that the bruxism had started 2 years earlier, after his parents’ separation. The history also revealed treatment by a private dentist soon after tooth wear had been noticed, and that an acrylic bite-plate had been placed on the maxillary arch for both day and night use. However, the child was not using the plate, claiming that it hurt him. During consultation, the patient was very expansive and interested. His medical history was uneventful and evaluation of his diet revealed no ingestion of acid drinks or medication.

Intraoral clinical examination showed that the patient was in the early mixed-dentition stage. The relation between maxillary and mandibular permanent first molars was Angle Class I on both right and left sides; a Class I relation was also observed between maxillary and mandibular primary canines bilaterally. Neither mouth-opening limitation nor crepitation was detected during the examination of the temporomandibular

joint. The patient presented functional mandibular deviation without crossbite (Fig. 2a). Maxillary and mandibular permanent first molars and mandibular permanent central incisors were already in the arches. Furthermore, good oral hygiene was observed; probing revealed neither carious lesions nor gingival bleeding, although the patient presented a glass ionomer cement restoration in tooth 55 and an amalgam filling in tooth 65. Pronounced wear was observed in all primary teeth (Fig. 2b). The child did not report a history of pain in either worn teeth or the temporomandibular joint.

Radiographic examination confirmed pronounced wear on primary teeth and the absence of injury to supporting tissues. The presence of a supernumerary element (mesiodens) between teeth 51 and 61 (Fig. 2c) was verified.

The treatment plan for this patient included surgical extraction of the mesiodens, placement of a soft-based bite-plate, 3 mm thick, on the maxillary arch for day and night use and referral for psychological monitoring.

Follow-up visits were scheduled every third month to verify tooth wear and monitor eruption of permanent teeth and bone growth. When necessary, splints were modified to allow adequate bone growth.

## Discussion

Etiologic factors that might be associated with bruxism are amply discussed in the literature.<sup>1,6,9,17</sup> Our report focused on 2 children with severe wear of primary teeth caused by gnashing. In both cases, the condition was believed to have been triggered by psychological disturbances, resulting from harrowing — although different — experiences. Furthermore, both had been influenced by certain local factors, also different for each patient. Funch and Gale<sup>18</sup> state that bruxism is correlated with psychological factors, suggesting that the kind of life the patient leads exerts great influence on the frequency, duration and severity of the condition. Thus, based on the presence of the emotional problems reported by the parents, we believed that in all probability the condition presented by these patients was bruxism.

Although some authors do not consider tooth wear a reliable indicator of bruxism,<sup>19–21</sup> both patients presented extremely marked tooth wear, even nearing the dental pulp. Thus, the possibility of physiological wear was discarded. In addition, parents were emphatic in their statement that the children had episodes of tooth gnashing and grinding.

Taking diet and the absence of medical history of reflux in the patients into account, the possibility of the observed dental wear arising from a chemical process was discarded in accordance with Imfeld<sup>22</sup> and Lussi and others,<sup>23</sup> who have stated that the etiological factors contributing to chemical dissolution of dental enamel in children are related to either acid diet or medication.

Sleep-related xerostomia is a sensation of dry mouth associated with mouth or throat discomfort that induces wakening for water intake. According to Thie and others,<sup>24</sup> lubrication from saliva is necessary during sleep to protect tissue integrity and the health of oroesophageal structures. Nevertheless, it is problematic to assert that the salivary flow of the children reported here contributed to the tooth wear for 2 reasons: first, the wear was extremely accentuated; and, most important, no salivary flow test was performed on the children.

The prevalence of bruxism in children is estimated to range from 7% to 15.1%.<sup>3–5</sup> A few studies confirm a higher rate in females than males.<sup>6,25</sup> However, as bruxism is a condition related to certain personality characteristics — aggression, anxiety and hyperactivity — mainly triggered by life events,<sup>26</sup> significant differences between sexes are unlikely.<sup>17</sup>

Some authors describe bruxism as a condition of multifactorial etiology, determined by an association of psychological, local and systemic factors.<sup>2,14</sup> Local factors include occlusal interferences, malocclusion and temporomandibular dysfunction.<sup>27</sup> Allergic diseases represent systemic factors.<sup>28</sup> The patient in case 1 did not show occlusal interferences, temporomandibular dysfunction or malocclusion, as verified by intraoral examination. However, his medical history pointed to respiratory allergy. On the other

hand, the patient in case 2 presented mandibular deviation under clinical examination. Although we believe that both cases are a consequence of psychological factors, respiratory allergy could also be associated with bruxism in the first case and mandibular deviation could be linked to the condition in the second case. Thus, the multifactorial etiology defended by several authors was confirmed.<sup>2,6,14</sup>

There is also evidence that, in younger children, bruxism may be a consequence of the immaturity of the masticatory neuromuscular system. No catecholamine measurement of any type was performed on the patients in this report. Nevertheless, Vanderas and others<sup>29</sup> have demonstrated that stress and anxiety may be directly related to bruxism, as patients suffering from bruxism show a higher catecholamine level, generally ascribed to emotional stress.

There is controversy among clinicians over the treatment of children with bruxism.<sup>13</sup> Both our patients were referred to a psychologist, as we believed that the level of emotional stress generated by life events experienced by the patients was a factor in their bruxism. A study by Restrepo and others<sup>13</sup> demonstrated that several psychological techniques have been efficacious in reducing signs of bruxism when they were applied to 33 children aged 3–6.

Soft-based tailor-made bite-plates were prescribed for both children. According to Hachmann and others<sup>15</sup> and McDonald and others,<sup>27</sup> a bite-plate covering the occlusal surfaces of all teeth should be used by patients suffering from bruxism to prevent continuous abrasion. Specifically in the case of the second patient — who had mandibular deviation, a possible sign of temporomandibular dysfunction — the use of a myorelaxing plate is indicated and constitutes the initial phase of the therapy.<sup>28</sup> Solberg and others<sup>30</sup> assert that the use of bite-plates reduces muscular activity, thus giving more comfort to the patient. A soft-based material was chosen to protect the primary teeth, as suggested by Casamassimo.<sup>28</sup> Furthermore, the thickness (3 mm) was sufficient to prevent perforation and increase resistance to impact. McDonald and others<sup>27</sup> recommend that the bite-plate be 2–3 mm thick and extend from the vestibular to the lingual surfaces.

Craniofacial growth involves distinct structures and follows a complex chronological pattern, peaking in pre-puberty.<sup>27</sup> Thus, when removable prostheses are placed in young children, osseous discrepancies may arise. Although the bite-plates planned for the cases reported here are not removable, quarterly revision appointments were scheduled to monitor patients' bone growth and the eruption of permanent teeth.<sup>31</sup>

In certain cases, when systemic factors are associated with bruxism, patients should be referred to a specialist to eliminate or control the problem.<sup>28</sup> Our first patient presented with respiratory allergy — a factor that was probably connected with his parafunctional habit. Thus, to

eliminate any factor that could be contributing to his bruxism, the patient was referred to a specialist for treatment of the allergy.

On radiographic examination of the second patient, extraction of a supernumerary tooth was indicated; Hedge and Munshi<sup>32</sup> recommend removal of supernumerary teeth as they may impede the eruption of adjacent permanent teeth or be associated with certain pathological conditions, such as cysts and radicular resorptions.

Research has attempted to correlate bruxism with socioeconomic factors.<sup>17</sup> Although both patients in this study displayed the habit of gnashing their teeth, they belonged to distinctly different socioeconomic strata. Thus, we believe that bruxism is independent of socioeconomic level, but rather much more closely associated with each patient's life events.

According to Lobbezoo and Naeije,<sup>8</sup> level of stress and personality type have been included in the etiology of bruxism for many years. However, the exact contribution of psychological factors remains debatable. A controlled questionnaire study<sup>33</sup> demonstrated that those with bruxism generally present emotional imbalance and tend to develop more psychosomatic disorders. These findings have been confirmed by Kampe and others,<sup>34</sup> who also demonstrated the presence of a higher level of anxiety in a group of people with bruxism.

As this article deals with isolated clinical cases, its findings cannot be generalized. Therefore, we suggest that more epidemiological investigations be made to provide a better understanding of the etiological factors in bruxism.

Considering the problems intrinsic in modern society, bruxism is becoming an increasingly common condition in children. In treating this parafunctional habit, clinicians play a leading role in determining possible etiological factors. In many situations it is the dentist's task to warn parents and institute multidisciplinary treatment. ♦

## THE AUTHORS



**Dr. Antonio** is a postgraduate student in the department of pediatric dentistry and orthodontics, School of Dentistry, Federal University of Rio de Janeiro, Brazil.



**Dr. Piero** is a postgraduate student in the department of pediatric dentistry and orthodontics, School of Dentistry, Federal University of Rio de Janeiro, Brazil.



**Dr. Maia** is an associate professor in the department of pediatric dentistry and orthodontics, School of Dentistry, Federal University of Rio de Janeiro, Brazil.

**Correspondence to:** Dr. Andréa Gonçalves Antonio, Av. Armando Lombardi 633/215, Barra da Tijuca, Rio de Janeiro, Brazil 22.640-020.

The authors have no declared financial interests.

## References

- Pingitore G, Chrobak V, Petrie J. The social and psychologic factors of bruxism. *J Prosthet Dent* 1991; 65(3):443-6.
- Attanasio R. Nocturnal bruxism and its clinical management. *Dent Clin North Am* 1991; 35(1):245-52.
- Nilner M. Prevalence of functional disturbances and diseases of the stomatognathic system in 15-18 year olds. *Swed Dent J* 1981; 5(5-6):189-97.
- Nilner M, Kopp S. Distribution by age and sex of functional diseases of the stomatognathic system in 7-18 year olds. *Swed Dent J* 1983; 7(5):191-8.
- Laberge L, Tremblay RE, Vitaro F, Montplaisir J. Development of parasomnias from childhood to early adolescence. *Pediatrics* 2000; 106(1 Pt 1):67-74.
- Bayardo RE, Mejia JJ, Orozco S, Montoya K. Etiology of oral habits. *ASDC J Dent Child* 1996; 63(5):350-3.
- Vanderas AP, Manetas KJ. Relationship between malocclusion and bruxism in children and adolescents: a review. *Pediatr Dent* 1995; 17(1):7-12.
- Lobbezoo F, Naeije M. Bruxism is mainly regulated centrally, not peripherally. *J Oral Rehabil* 2001; 28(12):1085-91.
- Monaco A, Ciammella NM, Marci MC, Pirro R, Giannoni M. The anxiety in bruxer child. A case-control study. *Minerva Stomatol* 2002; 51(6):247-50.
- Graf H. Bruxism. *Dent Clin North Am* 1969; 13(3):659-65.
- Kopp S. Pain and functional disturbances of the masticatory system — a review of etiology and principles of treatment. *Swed Dent J* 1982; 6(2):49-60.
- Rugh JD, Barghi N, Drago CJ. Experimental occlusal discrepancies and nocturnal bruxism. *J Prosthet Dent* 1984; 51(4):548-53.
- Restrepo CC, Alvarez E, Jaramillo C, Velez C, Valencia I. Effects of psychological techniques on bruxism in children with primary teeth. *J Oral Rehabil* 2001; 28(4):354-62.
- Okeson JP. Temporomandibular disorders in children. *Pediatr Dent* 1989; 11(4):325-9.
- Hachmann A, Martins EA, Araujo FB, Nunes R. Efficacy of the nocturnal bite plate in the control of bruxism for 3 to 5 year old children. *J Clin Pediatr Dent* 1999; 24(1):9-15.
- Pidcock FS, Wise JM, Christensen JR. Treatment of severe post-traumatic bruxism with botulinum toxin-A: case report. *J Oral Maxillofac Surg* 2002; 60(1):115-7.
- Vanderas AP, Papagiannoulis L. Multifactorial analysis of the aetiology of craniomandibular dysfunction in children. *Int J Paediatr Dent* 2002; 12(5):336-46.
- Funch DP, Gale EN. Factors associated with nocturnal bruxism and its treatment. *J Behav Med* 1980; 3(4):385-7.
- Marbach JJ, Raphael KG, Janal MN, Hirschhorn-Roth R. Reliability of clinician judgements of bruxism. *J Oral Rehabil* 2003; 30(2):113-8.
- Chung SC, Kim YK, Kim HS. Prevalence and patterns of nocturnal bruxofacets on stabilization splints in temporomandibular disorder patients. *Cranio* 2000; 18(2):92-7.
- Ekfeldt A, Hugoson A, Bergendal T, Helkimo M. An individual tooth wear index and an analysis of factors correlated to incisal and occlusal wear in an adult Swedish population. *Acta Odontol Scand* 1990; 48(5):343-9.
- Imfeld T. Dental erosion. Definition, classification and links. *Eur J Oral Sci* 1996; 104(2 Pt 2):151-5.
- Lussi A, Kohler N, Zero D, Schaffner M, Megert B. A comparison of the erosive potential of different beverages in primary and permanent teeth using an in vitro model. *Eur J Oral Sci* 2000; 108(2):110-4.
- Thie NM, Kato T, Bader G, Montplaisir JY, Lavigne GJ. The significance of saliva during sleep and the relevance of oromotor movements. *Sleep Med Rev* 2002; 6(3):213-27.
- Gorayeb MA, Gorayeb R. [Association between headache and anxiety disorders indicators in a school sample from Ribeirao Preto, Brazil]. *Arq Neuropsiquiatr* 2002; 60(3-B):764-8. Portuguese.
- Rugh JD, Harlan J. Nocturnal bruxism and temporomandibular disorders. *Adv Neurol* 1988; 49:329-41.
- McDonald RE, Hennon DK, Avery DR. Diagnosis and correction of minor irregularities in the developing dentition. In: McDonald RE, Avery DR, Dean JA, editors. Pediatric dentistry for the child and adolescent. 7th ed. Chicago: Mosby; 2000. p. 487.
- Casamassimo P. Periodontal considerations. In: Pinkham J, Casamassimo OS, Fields HW, McTigue DJ, Nowak A, editors. Pediatric dentistry — infancy through adolescence. 2nd ed. Philadelphia: WB Saunders Co.; 1994. p. 372.
- Vanderas AP, Menenakou M, Kouimtzi TH, Papagiannoulis L. Urinary catecholamine levels and bruxism in children. *J Oral Rehabil* 1999; 26(2):103-10.

30. Solberg WK, Clark GT, Rugh JD. Nocturnal electromyographic evaluation of bruxism patients undergoing short term splint therapy. *J Oral Rehabil* 1975; 2(3):215–23.
31. Kotsiomiti E, Arapostathis K, Kapari D, Konstantinidis A. Removable prosthodontic treatment for the primary and mixed dentition. *J Clin Pediatr Dent* 2000; 24(2):83–9.
32. Hedge SV, Munshi AK. Late development of supernumerary teeth in the premolar region: a case report. *Quintessence Int* 1996; 27(7):479–81.
33. Olkinuora M. Psychosocial aspects in a series of bruxists compared with a group of non-bruxists. *Proc Finn Dent Soc* 1972; 68(4):200–8.
34. Kampe T, Edman G, Bader G, Tagdae T, Karlsson S. Personality traits in a group of subjects with long-standing bruxing behaviour. *J Oral Rehabil* 1997; 24(8):588–93.