

# Mandibular Distraction Osteogenesis for Endosseous Dental Implants

(L'ostéogénèse mandibulaire par distraction pour les implants dentaires intra-osseux)

• David A. Walker, DDS, MS, FRCD(C) •

## S o m m a i r e

*Les patients atteints d'un édentement partiel ou complet qui n'ont pas assez d'os pour qu'on puisse donner un traitement par implant intra-osseux présentent une difficulté pour le dentiste. L'ostéogénèse alvéolaire par distraction est une technique pour créer de l'os et des tissus mous, sans avoir besoin de faire une greffe osseuse, évitant ainsi les complications éventuelles. Dans le présent article, on compare l'ostéogénèse alvéolaire par distraction avec les techniques traditionnelles de greffe osseuse. On présente un cas pour illustrer une ostéogénèse verticale mandibulaire bilatérale par distraction avec création d'un volume osseux suffisant pour une restauration dentaire implanto-portée.*

**Mots clés MeSH :** alveolar ridge augmentation/methods; dental implantation, endosseous; osteogenesis, distraction/methods

© J Can Dent Assoc 2005; 71(3):171-5  
Cet article a été révisé par des pairs.

Dental practitioners frequently encounter partially edentulous patients. Replacement of the lost dentition by dental implant-supported restoration offers many advantages over fixed bridgework or removable partial dentures.

Some patients present with insufficient bone for conventional implant-supported restoration. Traditional treatment approaches have included augmentation of the alveolar ridge with autologous, homologous or xenogenic bone. Alloplastic materials and various other osteoinductive or osteoconductive biomaterials have also been used for ridge augmentation.<sup>1</sup> Autologous bone grafting has many advantages over other techniques but is not without risks and potential complications, including wound dehiscence, infection, partial or total loss of the bone graft, and donor site morbidity.<sup>2</sup> The difficulties that can be encountered with vertical ridge augmentation by means of bone grafting techniques are frequently limited to soft-tissue tolerances and bone graft resorption.<sup>3</sup>

Alveolar distraction osteogenesis is a surgical technique that encourages creation of new bone and soft tissue through incremental lengthening of osseous segments.<sup>4</sup> The technique is relatively uncomplicated and avoids the need for bone grafting. The secondary effect of stretching and creating new soft tissues, a technique called distraction histogenesis, is

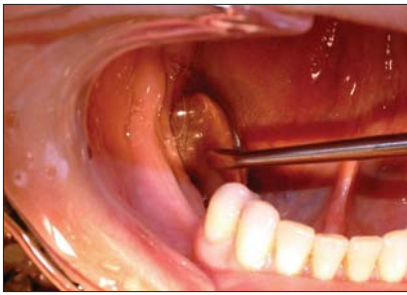
particularly helpful in vertical ridge augmentation. The following case illustrates successful alveolar distraction osteogenesis to allow dental implant-supported restoration.

### Case Report

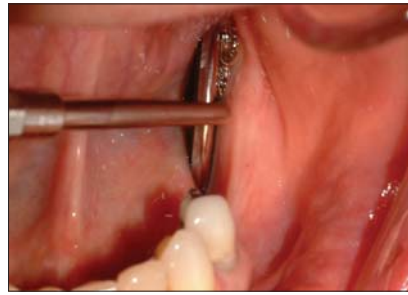A 52-year-old woman reported that she did not like her lower removal partial denture (RPD) and rarely wore it. The mandibular posterior teeth had been extracted 36 years before, and one removable mandibular partial denture had been made 15 years ago. The patient related that the RPD moved under function, which resulted in food trapping, and she never felt comfortable eating while wearing the denture.

The patient had undergone uterine surgery for endometriosis 1 year before the current presentation, and she had undergone cosmetic facial surgery 10 years before, without complications. Her medications included hormone replacement therapy and calcium supplements.

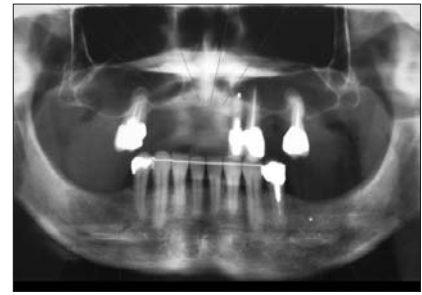
Clinical examination confirmed that the posterior mandibular alveolar ridges were thin bilaterally, and there was adequate maxillary structure for her complete upper denture (Figs. 1a, 1b). The patient had a Class II occlusion, with moderate mandibular retrognathia, and there were no significant findings on examination of the temporomandibular joint. Panoramic radiography confirmed a moderate bilateral saddle defect of the posterior mandible (Fig. 2). Tomography



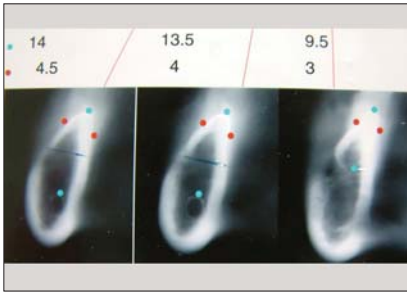
**Figure 1a:** Clinical evaluation showing knife-edged right mandibular ridge.



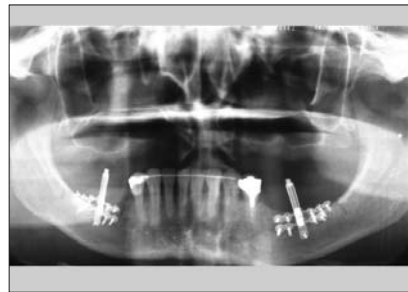
**Figure 1b:** Clinical evaluation showing knife-edged left mandibular ridge.



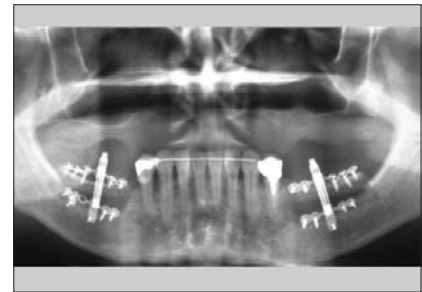
**Figure 2:** Panoramic radiograph showing moderate saddle defect.



**Figure 3:** Tomographic image of the left and right posterior mandible demonstrating 3- to 4-mm width of the crestal region of the alveolus.



**Figure 4:** Panoramic radiograph obtained immediately after placement of the alveolar distraction devices.



**Figure 5:** Panoramic radiograph at the completion of 8 mm of vertical distraction.

revealed a bony width of 3 to 4 mm in the crestal region bilaterally in the posterior mandible (Fig. 3).

On the basis of the clinical and radiographic evaluation, the patient consented to bilateral mandibular alveolar distraction osteogenesis.

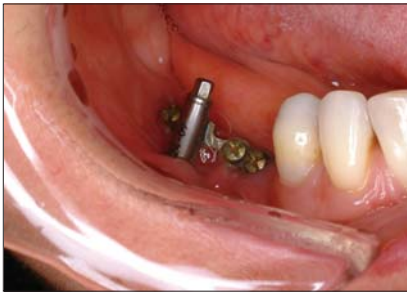### Surgical Procedure

The patient received intravenous sedation and local anesthesia. A vestibular incision was made in the right posterior mandible 5 mm inferior to the junction of the attached gingiva and alveolar mucosa; the incision extended from the retromolar region to the bicuspid region. A subperiosteal dissection was developed inferiorly to allow identification of the mental foramen and the mental neurovascular bundle with minimal dissection on the superior aspect of the alveolus. The alveolar distraction device (KLS Martin Track Plus, Jacksonville, Fla.) was contoured to fit the bony anatomy, and the outline of the osteotomy for the transport disk was marked with a #701 bur. A vertical vector of distraction close to the sagittal plane was selected to avoid lingual distraction of the transport segment. Holes were drilled for placement of monocortical and bicortical 1.5-mm screws, to stabilize the device, and the device was subsequently removed. The trapezoidal osteotomy of the transport segment was carefully completed with the #701 bur, reciprocating saw, and spatula osteotome. Care was taken to protect the vascular pedicle and to leave soft-tissue attachments to the transport segment except in the areas of the flaring vertical osteotomy cuts. The vascularity of the transport segment is predominantly from the lingual periosteum, the mucosa and the mylohyoid muscle.

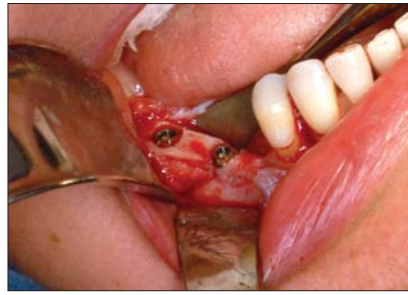The distraction osteogenesis device was re-applied, stabilized with the monocortical and bicortical 1.5-mm screws, and tested for movement of the transport bone segment. Mucosal closure was accomplished with interrupted 4.0 Vicryl horizontal mattress sutures with running 4.0 gut oversew (Ethicon, Johnson & Johnson, Somerville, N.J.) The same procedure was performed for the left mandible.

The patient was given postoperative instructions to maintain a liquid or pureed diet for 1 month and to progress to a soft diet after that time. Acetaminophen with codeine was prescribed for analgesia, and oral clindamycin 150 mg 4 times daily was maintained for 10 days. Chlorhexidine gluconate 0.12% mouth rinse 15 mL twice daily was used for 2 weeks postoperatively.

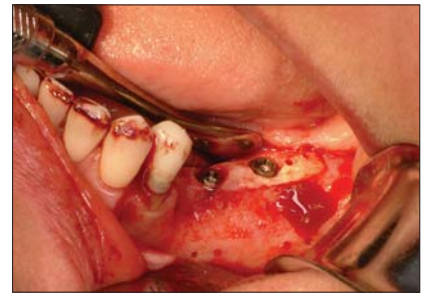
The latency (waiting) period, for initial healing, was 5 days, and the distraction rate was 0.33 mm, 3 times a day (for a total of 1 mm/day), which resulted in total device activation of 8.33 mm over 8 days (Figs. 4 and 5). During the follow-up period, portions of the superior arm of the distraction device became exposed bilaterally, and 2 loose screws were removed, the first at 3 months and the second at 4 months after the completion of distraction (Fig. 6). The patient experienced mild bilateral paresthesia, which completely resolved by 2 months after distraction. Four months after insertion of the distraction devices, they were removed under intravenous sedation and local anesthetic. The distraction regenerate was well ossified and stable. Four cylindrical threaded endosseous implants (TiUnite, Nobel Biocare, Goteborg, Sweden) were placed through the transport segment and the distraction regenerate (Figs. 7a and 7b). The following implants



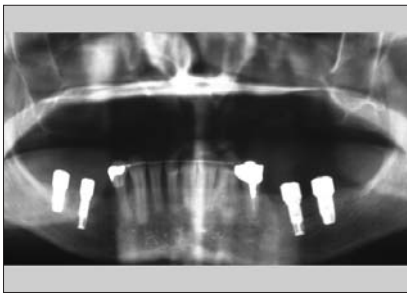
**Figure 6:** Alveolar distraction device with a portion of the bone plate exposed, 2 months after the distraction procedure.



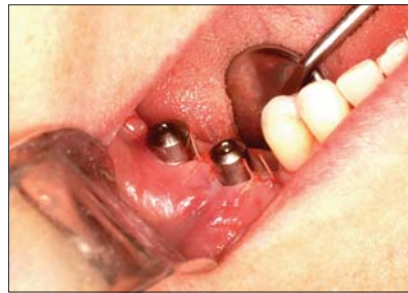**Figure 7a:** Placement of the right mandibular implant through the distraction regenerate 4 months after distraction (the distraction device has been removed).



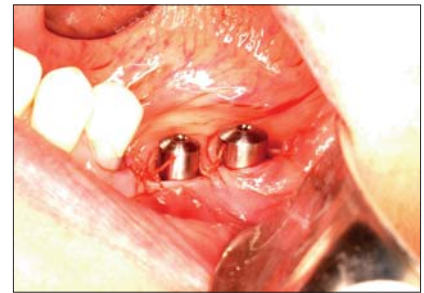**Figure 7b:** Placement of left mandibular implant through distraction regenerate.



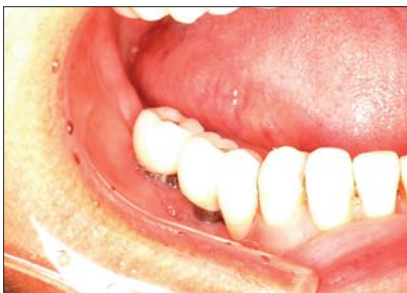**Figure 8:** Panoramic radiograph 6 months after placement of the implant, at the time of abutment placement; the distraction regenerate has matured well.



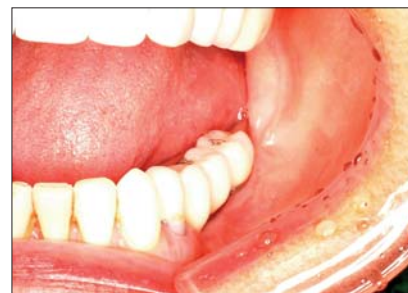**Figure 9a:** Placement of healing abutments in the right mandible



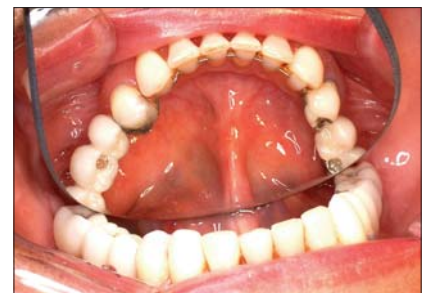**Figure 9b:** Placement of healing abutments in the left mandible



**Figure 10a:** Final restoration, right mandible (prosthodontist Dr. G. Zarb).



**Figure 10b:** Final restoration, left mandible.



**Figure 10c:** Final restoration, occlusal view.

were placed: right mandible, 11.5 mm × 3.75 mm fixture and 8.5 mm × 5 mm fixture; left mandible, 11.5 mm × 3.75 mm fixture and 10 mm × 5 mm fixture. The implant treatment was performed in 2 stages, with abutment connection occurring 6 months after placement of the implant fixtures. Clinical and radiographic examination revealed that the implants were osseointegrated at the time of stage II placement of transmucosal healing abutments (Figs. 8, 9a, 9b). The fixed prosthodontic rehabilitation was carried out 2 months after placement of the abutment, and the fixtures were loaded over a follow-up period of 8 months (Figs. 10a, 10b, 10c).

## Discussion

Distraction osteogenesis techniques were pioneered in modern times by a Russian orthopedic surgeon, Dr. Gavriel Ilizarov.<sup>5,6</sup> Distraction osteogenesis involves an osteotomy or cut through the bony segment, a latency or waiting period to

allow resolution of inflammation and initial healing, a distraction or callus manipulation period and a bony consolidation period.

Maxillofacial distraction techniques have led to successful lengthening of the mandible and maxilla. The procedures have been particularly helpful in patients with craniofacial syndromes, cleft maxilla or tumour defects of the maxillofacial region.<sup>7-10</sup> Alveolar distraction osteogenesis is the latest application of this exciting technique, and success has been widely documented.<sup>11-13</sup> In addition, development of miniaturized distraction devices has made distraction osteogenesis of small bone segments feasible.

Alveolar distraction osteogenesis offers many advantages over traditional bone grafting techniques. An increase in alveolar bone height and concomitant increase in vestibular alveolar mucosa is a result of gradual bone distraction. Only bone grafting techniques can present difficulties, mainly

because of the acute soft-tissue stretch required to cover block or particulate bone grafts. This factor becomes more complex when a scarred tissue bed is present. Wound dehiscence is a potentially serious complication resulting in exposure of the nonvital bone graft to oral microflora and potential infection. When such infection occurs, the result can be partial or total loss of the graft, which necessitates retreatment.

Donor site complications of the hip (ilium)<sup>2</sup> and tibia<sup>14</sup> have been reported, including infection, peritonitis, persistent pain, hip or tibia fracture, permanent paresthesias and permanent gait disturbance. Potential morbidity of cranial or rib donor sites include scalp hematoma, intracranial hemorrhage and brain injury for the former and pneumothorax and persistent chest wall pain for the latter.<sup>15,16</sup> Potential complications associated with intraoral donor sites include pain, bleeding, infection, and temporary or permanent paresthesia or dysesthesia of the teeth, gingiva, lip and chin.<sup>3,17</sup> Although such donor site complications can be serious, they are uncommon. Nonetheless, alveolar distraction osteogenesis avoids the inherent risks, complications and donor site morbidity associated with bone grafting.

A variety of intraosseous and extraosseous devices are available for alveolar distraction osteogenesis.<sup>18</sup> The extraosseous device used in the case presented here allowed good stability of both the device and the transport bone segment during distraction and consolidation. It also allowed intraoperative adjustments to the vector of distraction. The height of the transport osseous segment was 5 mm and its length was 2 cm bilaterally. Adequate osseous volume is necessary for stabilization of the device and successful creation of the distraction regenerate. The location of the trapezoidal osteotomy was based on the position of the inferior alveolar nerve, the location and vector of the device, and the thickness of the alveolar bone.

A 5-day latency period was allowed, and distraction was started on the fifth postoperative day. The latency period is important for resolution of inflammation from the initial surgical procedure. It also allows cellular induction and differentiation of fibroblasts, formation of collagen and subsequent induction of osteoblasts during the early stages of new bone formation.<sup>19</sup> The distraction rate for this patient was 1 mm/day, performed in 3 activations. The greater the frequency of activation, the more favourable the distraction regenerate.<sup>6</sup> Patient cooperation is important to achieve successful activation of the distraction device.

Adequate consolidation time is required for maturation of the distraction regenerate so that it can support dental implant placement. Various consolidation times have been reported, but 3 to 4 months is typically adequate.<sup>4</sup> Further remodelling of the distraction regenerate occurs during the implant healing period. In this case, the distraction devices were easily removed at the same time as the titanium implants were placed. The endosseous implants were placed in a 2-stage technique, similar to that used with conventional bone grafting techniques. Excellent primary implant stability was achieved at all implant fixture sites.

The patient had mild to moderate requirements for analgesia over the first 5 days and experienced no pain during activation. There was no evidence of infection around the distraction device during the 4-month consolidation period, even though a portion of the stabilization plate became exposed and 2 screws loosened. The distraction regenerate has neovascularity, which appears to be more resistant to infection<sup>20</sup> than is the case with bone grafting. The loosening of 2 screws at 3 and 4 months after distraction appeared to have no clinical impact, as the distraction regenerate was mature enough by then to support the placement of titanium implants.

Continued bony maturation during the consolidation period was evident on the panoramic radiographs. The implants remained stable under functional loading during the 8-month follow-up period. At the time of writing, the patient was contemplating a fixed maxillary implant-supported prosthesis. Because there was insufficient bone stock in the maxilla for distraction osteogenesis, autologous bone grafting was an option.

## Conclusions

Alveolar distraction osteogenesis can be used to augment deficient bony ridges to allow subsequent endosseous implants. The procedure is associated with minimal morbidity and avoids the need for bone grafting and potential donor site morbidity. This report has documented the creation of adequate height and volume of bone for placement of an endosseous implant-supported dental restoration. ♦

*Acknowledgements: I would like to thank Dr. George Zarb for prosthodontic restoration of this patient's occlusion, and I would like to thank Goretti Sozinbo for typing the manuscript.*



*Dr. Walker is an assistant professor and staff oral and maxillofacial surgeon at the implant prosthodontic unit, faculty of dentistry, University of Toronto, Toronto, Ontario; staff oral and maxillofacial surgeon, The Hospital for Sick Children, Toronto; and a Diplomate of the American Board of Oral and Maxillofacial Surgery.*

*Correspondence to: Dr. David A. Walker, 419-170 St. George St., Toronto, ON M5R 2M8. E-mail: davidwalker@bellnet.ca.*

*The author has no declared financial interests in any company manufacturing the types of products mentioned in this article.*

## References

1. Levin L, Barber D, Betts N, MacAfee K, Feinberg S, Fonseca R. Bone induction and the biology of grafting. In: Fonseca R, Davis W, editors. *Reconstructive preprosthetic oral and maxillofacial surgery*. 2nd ed. Philadelphia: W. B. Saunders; 1995. p. 41-72.
2. Cricchio G, Lundgren S. Donor site morbidity in two different approaches to anterior iliac crest bone harvesting. *Clin Implant Dent Relat Res* 2003; 5(3):161-9.
3. Clavero J, Lundgren S. Ramus or chin grafts for maxillary sinus inlay and local onlay augmentation: comparison of donor site morbidity and complications. *Clin Implant Dent Relat Res* 2003; 5(3):154-60.
4. Clarizio L. Vertical alveolar distraction versus bone grafting for implant cases. In: Jensen O, editor. *Alveolar distraction osteogenesis*, Chicago: Quintessence Publishing; 2002. p. 59-68.
5. Ilizarov GA. The tension stress effect on the genesis and growth of tissues. Part I. The influence of stability fixation and soft tissue reservation. *Clin Orthop* 1989; (238):249-81.

6. Ilizarov GA. The tension stress effect on the genesis and growth of tissues. Part II. The influence of rate and frequency of distraction. *Clin Orthop* 1989; (239):263–85.
7. Chin M, Toth BA. Distraction osteogenesis in maxillofacial surgery using internal devices: review of five cases. *J Oral Maxillofac Surg* 1996; 54(1):45–53.
8. McCarthy JG, Schreiber J, Karp N, Thorne CH, Grayson BH. Lengthening of the human mandible by gradual distraction. *Plast Reconstr Surg* 1992; 89(1):1–8.
9. Molina F, Ortiz Monasterio F. Mandibular elongation and remodeling by distraction: a farewell to major osteotomies. *Plast Reconstr Surg* 1995; 96(4):825–40.
10. Walker DA. Management of severe mandibular retrognathia in the adult patient using distraction osteogenesis. *J Oral Maxillofac Surg* 2002; 60(11):1341–6.
11. Hidding J, Lazar F, Zoller J. The Cologne concept on vertical distraction osteogenesis. In: Arnaud E, Diner P, editors. 3rd International Congress on Cranial and Facial Bone Distraction Processes (June 14–16, 2001, Paris, France). Bologna (Italy): Monduzzi Editore; 2001. p. 65–72.
12. Chin M. Alveolar distraction osteogenesis with endosseous devices in 175 cases. In: Arnaud E, Diner P, editors. 3rd International Congress on Cranial and Facial Bone Distraction Processes (June 14–16, 2001, Paris, France). Bologna (Italy): Monduzzi Editore; 2001. p. 73–80.
13. Gaggl A, Schultes G, Karcher H. Vertical alveolar ridge distraction with prosthetic treatable distractors: a clinical investigation. *Int J Oral Maxillofac Implants* 2000; 15(5):701–10.
14. Marchena JM, Block MS, Stover JD. Tibial bone harvesting under intravenous sedation: morbidity and patient experiences. *J Oral Maxillofac Surg* 2002; 60(10):1151–4.
15. Sawin PD, Traynelis VC, Menezes AH. A comparative analysis of fusion rates and donor-site morbidity for autogeneic rib and iliac crest bone grafts in posterior cervical fusions. *J Neurosurg* 1998; 88(2):255–65.
16. Bolger WE, McLaughlin K. Cranial bone grafts in cerebrospinal fluid leak and encephalocele repair: a preliminary report. *Am J Rhinol* 2003; 17(3):153–8.
17. Nkenke E, Radspiel-Troger M, Wiltfang J, Shultze-Mosgau S, Winkler G, Newkam FW. Morbidity of harvesting retromolar bone grafts: a prospective study. *Clin Oral Implants Res* 2002; 13(5):514–21.
18. Stucki-McCormick, Moses J, Robinson R, Laster Z, Mommaerts M, Jensen O. Alveolar distraction devices. In: Jensen O, editor. Alveolar distraction osteogenesis. Chicago: Quintessence Publishing; 2002. p. 41–58.
19. Samchukov M, Cope J, Cherkashin A. Biological basis of new bone formation under the influence of tension stress. In: Samchukov M, Cope J, Cherkashin A, editors. Craniofacial distraction osteogenesis. St. Louis (MO): Mosby; 2001. p. 21–36.
20. Walker D. Buried bidirectional telescopic mandibular distraction. In: Samchukov M, Cope J, Cherkashin A, editors. Craniofacial distraction osteogenesis. St. Louis (MO): Mosby; 2001. p. 313–22.