

Use of Photographs for Communicating with the Laboratory in Indirect Posterior Restorations

(Utilisation de photographies pour communiquer avec le laboratoire, dans les cas de restaurations postérieures indirectes)

• Stephen Phelan, DDS •

S o m m a i r e

Cet article porte sur un cas d'onlay simple, sensiblement amélioré grâce à un système de communication détaillé entre le clinicien et le technicien de laboratoire. L'auteur a constaté qu'en incluant l'utilisation de diapositives en couleurs dans le système de communication entre le dentiste et le technicien, ce dernier était mieux en mesure de créer une restauration esthétique, précise et réussie qui répondait bien aux besoins du patient.

Mots clés MeSH : communication; dental technicians; dentists; photography

© J Can Dent Assoc 2002; 68(4):239-42
Cet article a fait l'objet d'une révision par des pairs.

In the practice of esthetic restorative dentistry, clinicians and laboratory technicians work as a team to restore both form and function for their patients. Each member of the restorative team contributes his or her expertise to meeting this goal. Although working as a team, the dentist and ceramist are seldom able to sit face-to-face to go over the particulars of a case, and the ceramist is rarely, if ever, able to evaluate the patient in person. In fact, frequently — as in the case presented here — the dentist and the technician are thousands of miles apart. In short, the parameters of modern dentistry make it imperative that the protocol for communication between the clinician and the technician be ideal.

Historically, dentist-laboratory communication procedures have consisted primarily of handwritten prescriptions, in which the dentist attempts to record the desired shade and shape of the prescribed restoration. Furthermore, the communication has typically been one-way, with the dentist simply telling the technician what is required. However, as demonstrated by Culpepper¹ in a 1970 study, colour perception among individuals varies greatly. Because the technician cannot see the patient, he or she has little or no input in response to the prescribed treatment.

Clinicians and patients expect excellent esthetic restorations, but the traditional written prescription alone does not always yield the desired results. Since teams work best when all of the players can evaluate and provide input to the situation,

it is natural to seek out methods that enable team members to best assess the case. In doing so, it is logical to assume that technicians could better visualize a restoration and reproduce inherent characteristics if they could, quite simply, see the patient's teeth. Photographs are the ideal answer to this dilemma. By providing colour slides, the clinician gives the ceramist a window through which to view the patient.² When used appropriately, photographic slides are the ideal communication medium in the dental setting.³ In addition to providing the technician with information about the desired shade of the restoration, slides can also be used to relay information about the individual tooth characteristics that, if incorporated, can make a restoration exceptional.

Colour reproduction can vary greatly in photographic prints. Colour slides taken with Kodak EPN 100 professional slide film, which is a neutral-based film without a colour bias and which is very true to the subject matter, provides exceptionally accurate colour reproduction and detail.² As such, a 35-mm camera with a macro lens and flash system customized for dental photography is recommended for taking the images; colour-corrected lighting is also recommended for the photographic session.⁴ If the slides are paired with a detailed laboratory prescription and an excellent impression, the technician will have the information necessary to create an optimal restoration.

When restoring posterior teeth, as in the case presented

here, enough time must be taken to thoroughly assess the subtleties that make these teeth unique. Reproduction of the nuances of colour and form is what makes a restoration successful.⁵ In addition, the shade should always be determined before tooth preparation, as dehydration of the tooth makes accurate shade selection nearly impossible.⁶

Shade Matching

An excellent shade prescription for posterior restorations can be obtained with a 6-step system to determine the following characteristics: value, hue, chroma, colour of the occlusal fossa halo, pit and fissure characterization, and hypocalcification. Of these, the 3 dimensions that define colour are value, hue and chroma.

The value, the amount of lightness or darkness of a colour, is of great importance to the restorative process; if the value is correct, the restoration can be successful even if the wrong hue and chroma have been selected.⁷ There is a significant difference between high-value restorations (brighter or more white-like) and low-value restorations (darker or more black-like). In cases where it is difficult to decide which of 2 values is best for posterior teeth, the lesser value should be selected. When deciding on the value of a restoration, the teeth and the shade tabs should be observed with the eyes squinted, because brightness in the eye is measured by retinal rods, and squinting increases the ratio of rods to cones; this makes it easier to observe any differences in value.⁸

In determining hue, the name of the colour, such as yellow or blue, the first impression obtained when looking at the shade guide is usually correct.⁹ Once the hue has been selected, only the shade tabs from the selected colour family — white, yellow, orange, grey, or brown — should be used to determine the chroma, the saturation or intensity of the hue. In deciding between 2 shade tabs for posterior teeth the one with more chroma should be selected.

It is important not to stare at the tooth for longer than 5 seconds when determining hue and chroma. The retinal cones that are responsible for colour perception can become adapted with staring, in which case colour perception will be reduced.⁸ Furthermore, the colour of the occlusal fossa halo (the pale colour near the fissures, which warms the colour of the occlusal surface) is usually in the same colour family as the hue.

Finally, in the interest of the patient–clinician relationship, it is a good idea to get the patient's approval to include occlusal pit and fissure characteristics in the restoration and to avoid referring to these characteristics as "pit staining." Although these brown grooves enhance the naturalistic appearance of the restoration, some patients prefer to avoid them. The same can be said for the amount of hypocalcified areas on the tooth surface that are incorporated into the restoration.

Case Report

A 26-year-old woman presented with breakdown around an amalgam filling on tooth 36 (**Fig. 1**). The treatment plan called for an onlay to replace one cusp. The material selected for

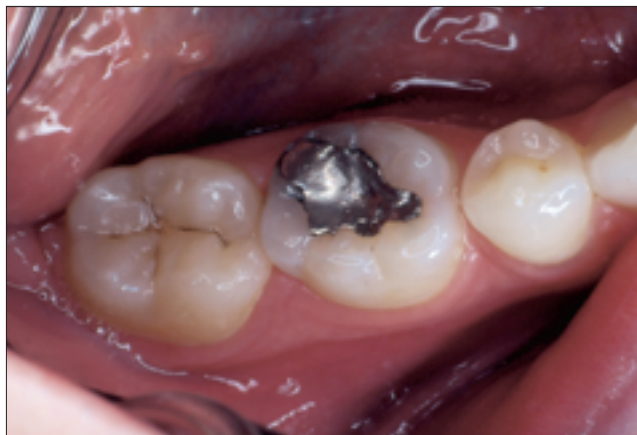

Figure 1: Tooth 36 before treatment.

restorative treatment was Targis 99 (Ivoclar North America, Inc., St. Catharines, Ontario).

The Targis 99 system is designed to work with the Chromascope shade guide (Ivoclar North America, Inc.); therefore, this guide is used to accurately communicate the required shades to the laboratory. The guide is divided into 5 categories of hues (white, yellow, orange, grey, and brown), each numbered in the 100s through 500s, respectively (**Figs. 2** and **3**). Within each category, the chroma progressively increases. For example, within the white hue family, shade 130 has a lower chroma than shade 150. The Mosaic shade guide system (Detnal Illusions, Woodland Hills, Calif.) was also used. This unique system provides information about the degree of fissure staining and hypocalcification (**Fig. 4**).¹⁰ The Mosaic system has 4 shade tabs dedicated to the amount of brown fissure staining that might be desired for a restoration (**Fig. 5**) and 3 shade tabs dedicated to various intensities of white hypocalcification (**Fig. 6**).¹⁰

Before tooth preparation in this case, the shade was recorded according to the 6-step system described above, and slide images were obtained of the teeth and the Chromascope and Mosaic shade tabs. It should be noted that the tooth to be restored is often not in good enough shape to be used for shade matching, so it may be necessary to use an adjacent tooth for colour selection. If the adjacent teeth are not satisfactory, a tooth on the opposite side can be used (**Figs. 2** and **3**). All of the teeth used for colour selection must be photographed. The camera must be held off angle, not perpendicular to the shade guide, so as to eliminate excessive reflection from the flash onto the shade guide.¹

After preparation and impression procedures, a Fermit N (Ivoclar North America, Inc.), chairside temporary restoration was created. A detailed laboratory prescription, impressions, and several colour slides were then sent to the laboratory, where the Targis 99 onlay was fabricated. Because of the nature of the communication process in this case, the laboratory technician was able to create a restoration that satisfied the goals of an esthetic restoration as outlined by Preston,¹¹ in that it achieved morphologic, optical and biologic acceptance (**Figs. 7** and **8**).

Figs. 9 and **10** depict the lower arch for another patient for

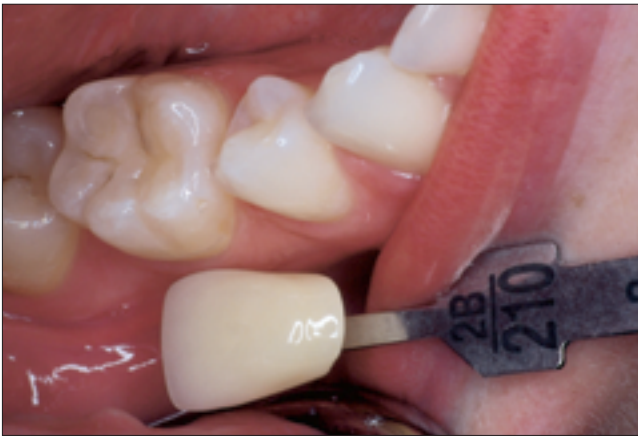

Figure 2: Shade tab and tooth 46.

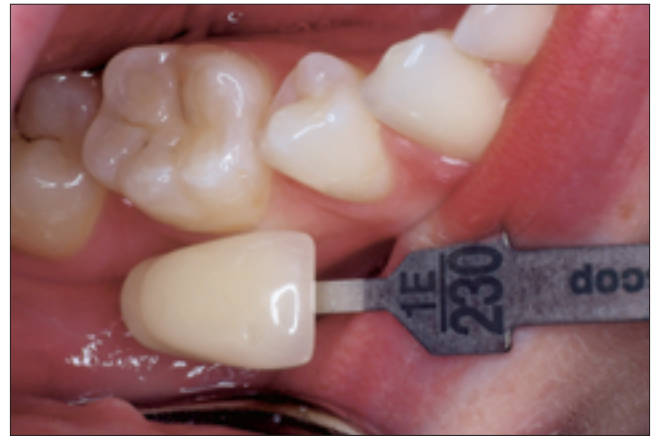

Figure 3: Alternate shade tab and tooth 46.

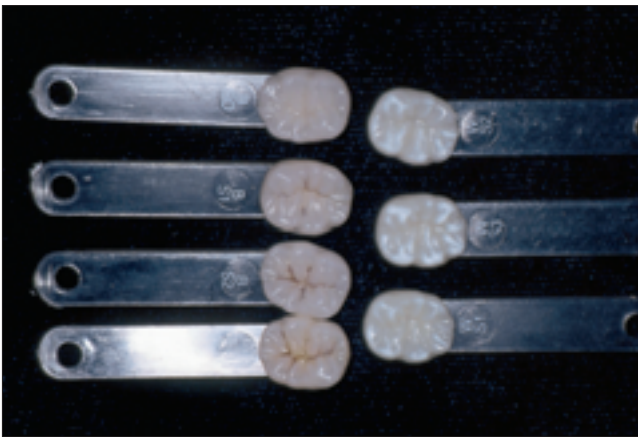


Figure 4: Mosaic shade tabs.

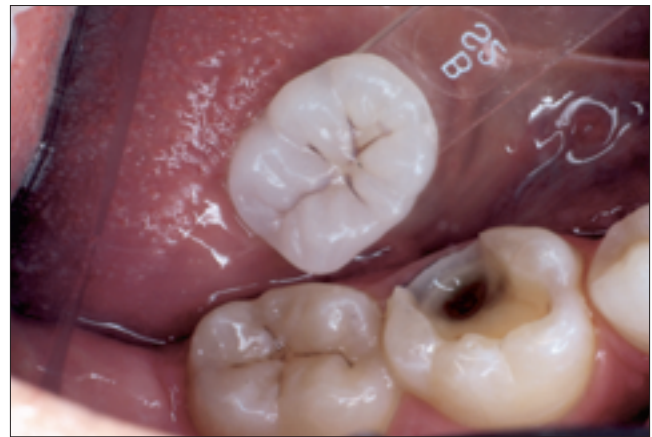

Figure 5: Mosaic shade tab for fissure stain.

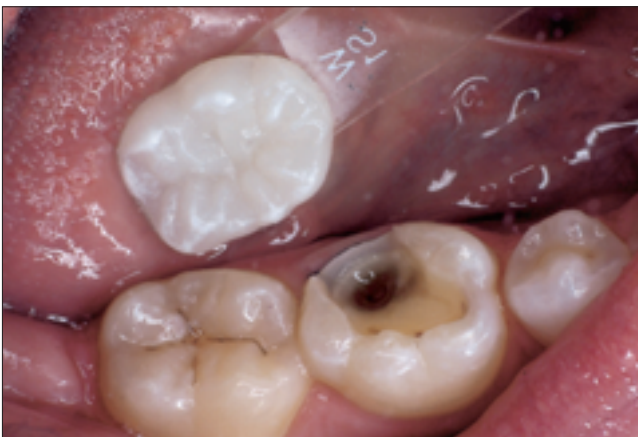

Figure 6: Mosaic shade tab for hypocalcification.

whom the same technique was used to esthetically restore 4 mandibular molars.

Conclusions

Patients expect and demand attractive, long-lasting restorations, and the materials and techniques available today make it possible to meet those expectations in most cases. However,

when many players are involved in creating a restoration, it is imperative that each person have all the necessary information to perform his or her part in meeting those expectations. In creating restorations, there is simply no such thing as too much information.

Colour slides are one method for providing the laboratory technician with vital information about a restoration. In addition, advances in technology indicate that the photographic process used for restorations will become completely digital, and that this will occur sooner rather than later. Digital cameras are improving month by month, and it will not be long before they can affordably provide the same colour quality currently achieved only with professional slide film. When that happens, dentists can simply send the photos to the laboratory by high-speed Internet connection, which will speed up the process. The key to use of the Internet for restoration work is for the dentist and ceramist to have matching colour-corrected monitors.

The goal of esthetic dentistry is to emulate the beauty of nature.⁸ By enabling the technician to see the patient's dentition, clinicians are better serving their patients and dentistry as a whole. ♦

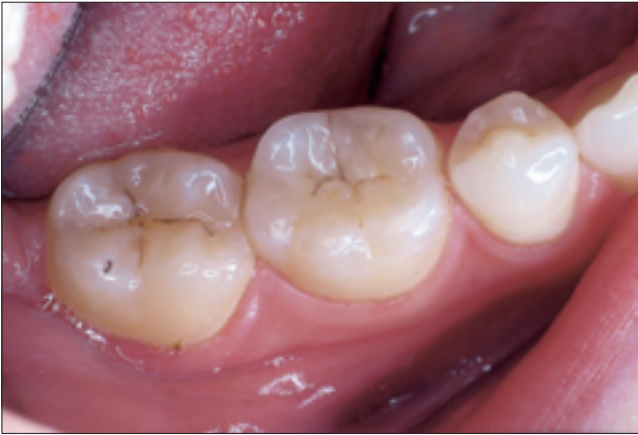

Figure 7: Tooth 36 after treatment.

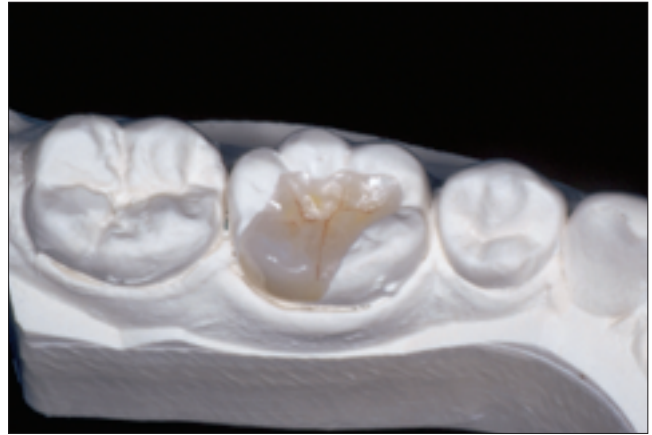


Figure 8: Completed restoration on solid model.

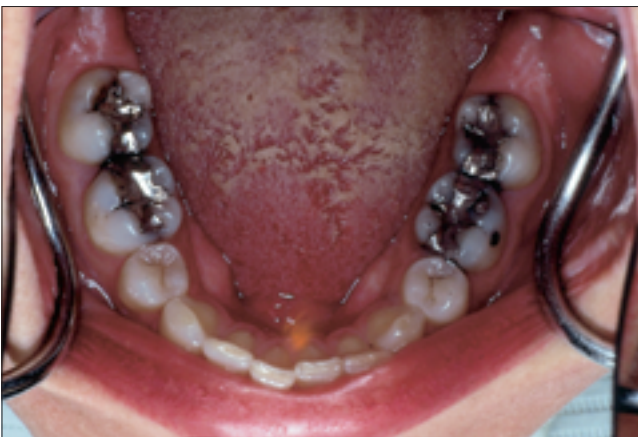

Figure 9: Lower arch before treatment in another patient.

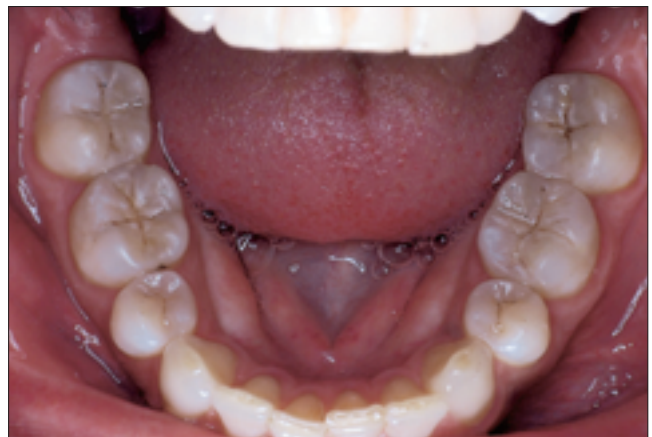

Figure 10: Lower arch after treatment in another patient.

Remerciements : L'auteur remercie vivement Dave Grin, BS, CDT, du Lone Mountain Dental Studio, LLC, pour son remarquable travail de laboratoire.

Le Dr Phelan exerce dans un cabinet privé à Oakville (Ontario).

Écrire au : Dr Stephen Phelan, 1500, ch. Heritage, Oakville (Ontario) L6M 3H4. Courriel : phelan@netcom.ca.

L'auteur n'a pas d'intérêt financier déclaré dans la ou les sociétés qui fabriquent les produits mentionnés dans cet article.

Références

1. Culpepper WD. A comparative study of shade-matching procedures. *J Prosthet Dent* 1970; 24(2):166-73.
2. Spear F. The art of intra-oral photography. The Seattle Institute of Advanced Dental Education. 1st ed. 1999. p. 29-32.
3. Touati B, Miara B, Nathanson D. Esthetic Dentistry and Ceramic

- Restorations. United Kingdom: Martin Dunitz Ltd.; 1999. p. 117-30.
4. Saleski CG. Color, light, and shade matching. *J Prosthet Dent* 1972; 27(3):263-8.
5. Chiche G, Pinault A. *Esthetics of Anterior Fixed Prosthodontics*. Carol Stream (IL): Quintessence Publishing; 1994. p. 115-41.
6. Jun S. Communication is vital to produce natural looking metal ceramic crowns. *J Dent Technol* 1997; 14(8):15-20.
7. Derbabian K, Mazola R, Donovan T, Arcidiacono A. The science of communicating the art of esthetic dentistry. Part III: Precise shade communication. *J Esthet Restor Dent* 2001; 13(3):154-62.
8. Soldano JL. Achieving natural looking restorations. *J Dent Technol* 1998; 15(10):13-7.
9. Miller LL. Shade matching. *J Esthet Dent* 1993; 5(4):143-53.
10. Yarovesky U, Meterdomini D. Taking posterior restorations to the next level: a new way to communicate occlusal color and characterization. *J Dent Technol* 1998; 15(2):19-22.
11. Preston JD. Current status of shade selection and color matching. *Quintessence Int* 1985; 16(1):47-58.