

# A Review of Impacted Permanent Maxillary Cuspids — Diagnosis and Prevention

• Grace Richardson, B.Sc., B.Ed. •  
• Kathy A. Russell, B.Sc., DDS, M.Sc. •

## A b s t r a c t

*As impacted permanent maxillary cuspids occur in 1-2% of the population, the general dentist should know the signs and symptoms of this condition and the interceptive treatment. Features of buccal or palatal cuspid impaction include lack of canine bulges in the buccal sulcus indicating a lingual eruption path and possible impaction; lack of symmetry between the exfoliation and eruption of cuspids that may indicate palatal or lingual impaction; and abnormal mesiodistal location and angulation of the developing maxillary permanent cuspids on radiographs. Diagnosis of impacted cuspid teeth at age 8-10 years can significantly reduce serious ramifications, including surgical exposure and orthodontic alignment as well as root resorption of the lateral incisors. In specific cases, extraction of the primary maxillary cuspids can prevent impaction of the permanent maxillary cuspids and additional sequelae.*

**MeSH Key Words:** cuspid; orthodontics, interceptive; tooth, impacted/diagnosis

© J Can Dent Assoc 2000; 66:497-501  
This article has been peer reviewed.

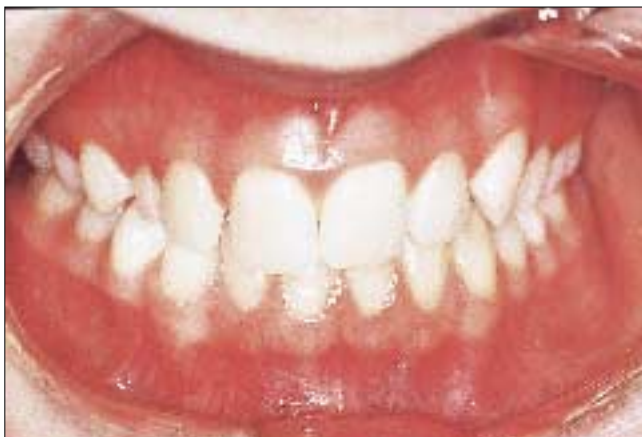**I**mpacted teeth are those with a delayed eruption time or that are not expected to erupt completely based on clinical and radiographic assessment.<sup>1</sup> Permanent maxillary canines are the second most frequently impacted teeth; the prevalence of their impaction is 1-2% in the general population.<sup>2,3</sup> This is most likely due to an extended development period and the long, tortuous path of eruption before the canine emerges into full occlusion.<sup>2-4</sup> Methods of diagnosis that may allow for early detection and prevention should include a family history, visual and tactile clinical examinations by the age of 9-10 years and a thorough radiographic assessment. Because there is a high probability that palatally impacted maxillary canines may occur with other dental anomalies, the clinician should be alert to this possibility.<sup>5</sup> When the condition is identified early, extraction of the maxillary deciduous canines may, in specific cases, allow the impacted canines to correct their paths of eruption and erupt into the mouth in relatively good alignment.<sup>5</sup> This interceptive treatment may further reduce complications associated with palatally impacted canines including root resorption of the lateral incisors and the need for more complex surgical and orthodontic intervention.<sup>6</sup>

### Prevalence and Etiology

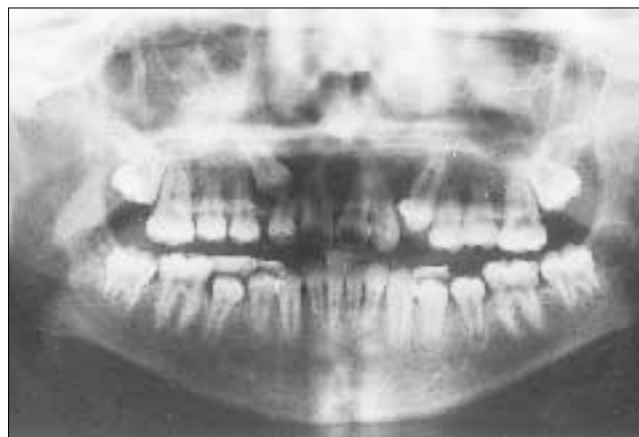Eighty-five per cent of impacted maxillary permanent cuspids are palatal impactions, and 15% are labial

impactions.<sup>1-3</sup> Inadequate arch space and a vertical developmental position are often associated with buccal canine impactions.<sup>2</sup> If buccally impacted cuspids erupt they do so vertically, buccally and higher in the alveolus.<sup>2</sup> Due to denser palatal bone and thicker palatal mucosa, as well as a more horizontal position, palatally displaced cuspids rarely erupt without requiring complex orthodontic treatment.<sup>7</sup> Palatally erupting or impacted maxillary canines occur twice as often in females than males, have a high family association and are 5 times more common in Caucasians than Asians.<sup>7,8</sup> It is not unusual for maxillary canine impaction to occur bilaterally, although unilateral ectopic eruptions are more frequent.<sup>9</sup>

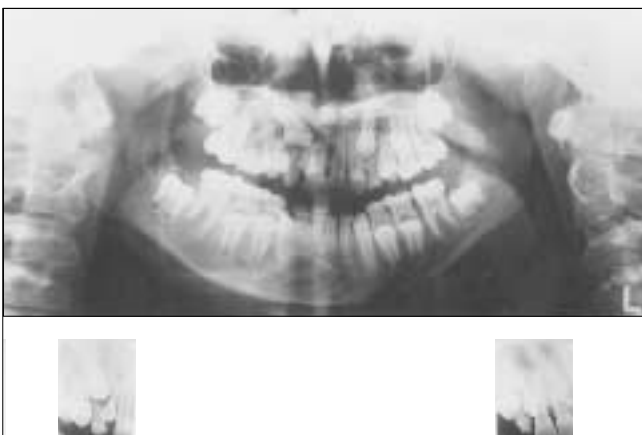The exact etiology of palatally impacted maxillary cuspids is unknown; however, 2 common theories may explain the phenomenon: the guidance theory and the genetic theory. The "guidance theory of palatal canine displacement" proposes that this anomaly is a result of local predisposing causes including congenitally missing lateral incisors, supernumerary teeth, odontomas, transposition of teeth and other mechanical determinants that all interfere with the path of eruption of the canine.<sup>1,4,10,11</sup> Maxillary canines develop high in the maxilla, are among the last teeth to develop and travel a long path before they erupt into the dental arch.<sup>12</sup> These factors increase



**Figure 1:** Clinical examination revealed asymmetry between right and left cuspids; the 53 was overretained and not mobile whereas the 63 had exfoliated naturally allowing the 23 to erupt into the arch. The 13 was palatally impacted and required surgical exposure and orthodontic alignment.



**Figure 2:** Significant asymmetry of the eruptive stages of maxillary permanent cuspids may be a sign of potential impaction. The 13 was palatally impacted and required surgical exposure and orthodontic alignment.



**Figure 3:** The degree of asymmetry of the eruption of the 13 and 23 and the overlap of the 13 with the 12 were signs of impaction. Panoramic and periapical radiographs were used to locate the 13 on the palate.

the potential for mechanical disturbances resulting in displacement and, thus, impaction.

The second theory focuses on a genetic cause for impacted cuspids.<sup>10,13,14</sup> Palatally impacted maxillary cuspids often present with other dental abnormalities, including tooth size, shape, number and structure, which Baccetti<sup>10</sup> reported to be linked genetically. Several abnormalities are believed to have a common hereditary link, manifested as a developmental disturbance during embryonic growth.<sup>6</sup> Research demonstrates that up to 33% of patients with palatally impacted cuspids also have congenitally missing teeth, a frequency that is 4-9 times that of the general population.<sup>8</sup> Studies also show that up to 47.7% of patients with palatally impacted cuspids have small, peg-shaped or missing lateral incisors.<sup>11</sup> In patients with congenitally absent maxillary lateral incisors, the co-occurrence of palatally impacted canines is 2.4 times that of the general population.<sup>7</sup> Palatally impacted maxillary canines are also associated with such anomalies as hypoplastic enamel,

infra-occluded primary molars and aplastic second bicuspsids.<sup>10</sup> However, it remains uncertain whether the anomalous lateral incisor is a local causal factor for palatally displaced canines or an associated genetic developmental influence.<sup>8</sup>

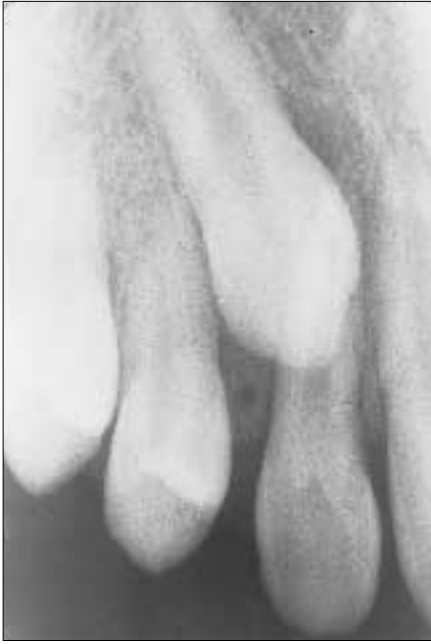### Diagnosis

Early detection of impacted maxillary canines may reduce treatment time, complexity, complications and cost. Ideally, patients should be examined by the age of 8 or 9 years to determine whether the canine is displaced from a normal position in the alveolus and assess the potential for impaction.<sup>9</sup> The clinician can investigate the presence and position of the cuspid using 3 simple methods: visual inspection, palpation and radiography.

### Visual Inspection

Clinical signs that may indicate ectopic or impacted succedaneous cuspids include lack of a canine bulge in the buccal sulcus by the age of 10 years, overretained primary cuspids, delayed eruption of their permanent successor and asymmetry in the exfoliation and eruption of the right and left canines<sup>9</sup> (Fig. 1). Primary cuspids that are retained beyond the age of 13 years and have no significant mobility strongly indicate displacement and impaction of permanent canines.<sup>9,15</sup> Although Power and Short<sup>15</sup> assert that the maxillary canine is late in its eruption sequence if it has not emerged by the age of 12.3 years in females and 13.1 years in males, correlation between chronological and dental ages is poor and overall dental development must be considered when investigating delayed canine eruption.

Although distal crown tip on the maxillary lateral incisors is common in the mixed dentition stage before eruption of the maxillary canines, an exaggerated distally tipped incisor should increase suspicion of a mesially deflected and palatally impacted canine.<sup>9</sup> In these cases, the lateral incisor crown may be tipped distally because the impacted cuspid is exerting force on the distal aspect of the lateral incisor root. Such palatal



**Figure 4:** Significant overlap of the maxillary cuspid and the lateral incisor makes recovery of the impacted canine following extraction of the primary cuspid less likely.

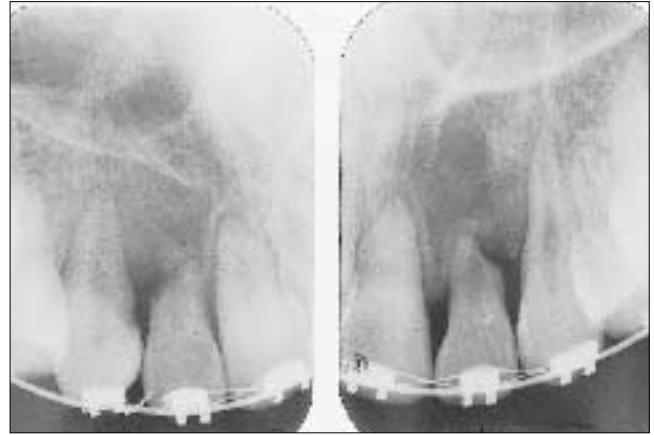
impactions can cause the lateral incisor to rotate as well.<sup>9</sup> Retroclined lateral incisors can also occur when buccally directed forces cause the root to tip labially and the crown to tip palatally.<sup>16</sup> In severe cases, the central incisor may also be affected, and its crown may become malpositioned.<sup>16</sup>

### **Palpation**

Palpation of the buccal and lingual mucosa, using the index fingers of both hands simultaneously, is recommended to assess the position of the erupting maxillary canines.<sup>9</sup> Eruption time of a maxillary canine varies from 9.3 to 13.1 years.<sup>12</sup> Because canines are palpable from 1 to 1.5 years before they emerge, the absence of the canine bulge after the age of 10 years is a good indication that the tooth is displaced from its normal position, and ectopic eruption or impaction of the maxillary cuspids is possible.<sup>12,17</sup> Asymmetries in the alveolar process are not considered significant in children younger than 10 years, and differences in bilateral palpation could be due to vertical differences in eruption rates at young ages.<sup>12,17</sup> However, in patients older than 10 years, an obvious palpable bilateral asymmetry could indicate that one of the permanent cuspids is impacted or erupting ectopically.<sup>17</sup>

### **Radiographs**

Radiographs are indicated when canine bulges are not present; right and left canine development and eruption is asymmetrical (**Fig. 2**); occlusal development is advanced and there are no palpable bulges indicating the presence of the cuspids in the alveolar process; and the lateral incisor is delayed in eruption, malpositioned, or has a pronounced labial or palatal inclination in relation to the adjacent central incisor.<sup>17-19</sup> Accurate radiographs are critical for determining the position of impacted canines and their relation to adjacent teeth, assessing



**Figure 5:** These periapical radiographs show severe lateral root resorption that resulted from palatally impacted cuspids that resorbed the adjacent roots.

the health of the neighbouring roots and determining the prognosis and best mode of treatment.<sup>20</sup> A panoramic radiograph taken in conjunction with 2 periapical views obtained using Clarke's Rule (Buccal Object Rule) or a 60% maxillary occlusal film (**Fig. 3**) allows the impacted teeth to be located either palatally or buccally relative to adjacent teeth.<sup>20</sup> Ericson and Kuroi<sup>19</sup> found that periapical radiographs allowed accurate location of the teeth in 92% of the cases they evaluated. Although periapical films are diagnostic for transverse position, occlusal radiographs are more accurate for determining the positions of the canines relative to the midline.<sup>16,21</sup> Lateral cephalometric radiographs are also helpful in assessing the anterior-posterior position of the displaced tooth, as well as its inclination and vertical location in the alveolus.<sup>20</sup>

Although conventional dental radiographs provide satisfactory diagnostic images, they lack the accuracy necessary for assessing palatal or buccal root resorption of the lateral incisor especially with mild or early resorption.<sup>21,22</sup> Computed tomography (CT) is more accurate in terms of locating the impacted cuspid in 3 dimensions and for diagnosing associated lesions such as root resorption of adjacent teeth.<sup>21</sup> However, although CT is an asset in cases where root resorption is suspected, cost, time and increased radiation exposure restrict its routine use.<sup>17</sup>

The association of palatally impacted maxillary cuspids with other dental anomalies — regardless of whether there is a true genetic relation — is clinically significant for the general practitioner. When an associated abnormality is suspected or diagnosed, further clinical and radiographic examinations are indicated to investigate the possibility of maxillary canine displacement.<sup>23</sup> If palatally displaced canines are identified early during mixed dentition, interceptive treatment may prevent future complications and more extensive orthodontic treatment.

### **Interceptive Treatment**

In Class I noncrowded situations where the permanent maxillary canine is impacted or erupting buccally or palatally, the preventive treatment of choice is extraction of the primary

cuspid when the patient is 10-13 years old.<sup>16,21</sup> However, if any root resorption is visible before this age and there is suspicion of impaction, the primary cuspid should be extracted and appropriate treatment implemented, i.e., monitoring the eruption path or orthodontic alignment. When canines are impacted buccally, overretained primary cuspids should be extracted to create a path and space for the permanent cuspids to erupt into the arch. This is especially important if both the permanent and primary cuspids are visible in the arch at the same time.

Power and Short<sup>15</sup> showed that interceptive extraction of the primary canine completely resolves permanent canine impaction in 62% of cases; another 17% show some improvement in terms of more favourable canine positioning. Ericson and Kurol<sup>24</sup> found that, in 78% of palatally erupting cuspids, the eruption paths normalize within 12 months. However, extraction of the primary cuspid does not *guarantee* correction or elimination of the problem. If there is no radiographic evidence of improvement one year after treatment, more aggressive treatment, such as surgical exposure and orthodontic eruption, is indicated.<sup>15</sup>

The success of early interceptive treatment for impacted maxillary cuspids is influenced by the degree of impaction and age at diagnosis.<sup>16</sup> As a general rule, when the degree of overlap between the permanent maxillary cuspid and the neighbouring lateral incisor exceeds half the width of the incisor root, the chances for complete recovery are poor<sup>15</sup> (Fig. 4). Clinical studies purport resolution of palatal impaction in 91% of cases in which the crown of the canine is distal to the midline of the lateral incisor when treatment is initiated.<sup>21</sup> The success rate drops to 64% if the cuspid crown is positioned mesial to the midline of the lateral incisor before interceptive treatment.<sup>21</sup>

Other factors influencing prognosis include canine angulation and crowding. The chance of successful eruption of an impacted canine following extraction of the primary canine is less than favourable as the angle from the vertical increases.<sup>15,25</sup> Power and Short<sup>15</sup> found that an angle exceeding 31% from the vertical significantly reduces the chance of normal eruption following an extraction. However, the degree of horizontal overlap with the adjacent lateral incisor has been found to have more influence on prognosis than angulation.<sup>15</sup> Ericson and Kurol<sup>25</sup> found that more mesially positioned canine cusp tips are associated with greater resorption of lateral incisor roots. Arch crowding can also have a significant influence; moderate to severe crowding indicates the need for complex orthodontic treatment to resolve the impaction and the malocclusion.<sup>15</sup>

### Sequelae from Maxillary Canine Impactions

The permanent canines are the foundation of an esthetic smile and functional occlusion,<sup>7</sup> and any factors that interfere with their development and eruption can have serious consequences. Although extraction of primary cuspids can be beneficial in specific cases, inappropriate extraction of primary maxillary cuspids must be avoided, due to the increased potential for arch collapse and arch crowding, which could lead to a buccal impaction. Abnormal eruption paths within the

dentoalveolar process may result in impactions and serious clinical ramifications. Unerupted or partly erupted cuspids may increase the risk of infection and cystic follicular lesions and compromise the lifespan of neighbouring lateral incisors due to root resorption<sup>2,15,20</sup> (Fig. 5). Clinical studies have determined that 12% of lateral incisors that are adjacent to ectopically erupted canines have some degree of external root resorption, while the prevalence of lateral incisor root resorption in 10-13 year olds is 0.7%.<sup>15,26</sup> Brin and others<sup>11</sup> found that there was an increased chance of lateral root resorption adjacent to an impacted cuspid when the lateral incisor was of normal size. A mesial-horizontal eruption path has also been shown to be more devastating to the adjacent lateral incisor, as is advanced root formation of the palatally displaced maxillary canine.<sup>26</sup> The lateral incisor often produces low-grade pain and has negligible mobility, although up to two-thirds of the root may be destroyed in affected teeth<sup>26</sup> (Fig. 5). This pathologic condition is often realized late (mean, 12.5 years of age) and after a significant degree of damage has occurred to adjacent teeth.<sup>26</sup>

### Conclusion

The prevalence of maxillary canine impaction is significant and the frequency increases with other genetically associated dental anomalies. The astute practitioner should be aware of dental anomalies that occur with palatally impacted maxillary canines so that early recognition and interceptive treatment is possible. More important, if signs of ectopic eruption are detected early, every effort should be made to prevent impaction and its consequences. Current protocol involves judicious extraction of the primary cuspid and radiographic follow-up for 12 months to monitor eruption. The need for complex orthodontic therapy and surgical intervention may be avoided if the deciduous canines are extracted appropriately. Early intervention can spare the patient time, expense, more complex treatment and injury to otherwise healthy teeth. ♦

---

*Ms. Richardson is a fourth-year dental student, Dalhousie University, Halifax.*

*Dr. Russell is assistant professor and head, division of orthodontics, Dalhousie University, Halifax. She is also staff orthodontist, IWK Grace Health Centre, Halifax.*

*Correspondence to: Dr. Kathy A. Russell, Division of Orthodontics, Room 5164, Faculty of Dentistry, Dalhousie University, 5981 University Avenue, Halifax NS B3H 3J5. E-mail: Kathy.Russell@Dal.ca.*

*The authors have no declared financial interest.*

---

### References

1. Thilander B, Jakobsson SO. Local factors in impaction of maxillary canines. *Acta Odontol Scand* 1968; 26:145-68.
2. Rayne J. The unerupted maxillary canine. *Dent Pract Dent Rec* 1969; 19:194-204.
3. Bass TB. Observations on the misplaced upper canine tooth. *Dent Pract Dent Rec* 1967; 18:25-33.
4. Hitchin AD. The impacted maxillary canine. *Br Dent J* 1956; 100:1-14.
5. Becker A, Zilberman Y, Tsur B. Root length of lateral incisors adjacent to palatally-displaced maxillary cuspids. *Angle Orthod* 1984; 54:218-25.

6. Bjerklind K, Kurol J, Valentin J. Ectopic eruption of maxillary first permanent molars and association with other tooth and developmental disturbances. *Eur J Orthod* 1992; 14:369-75.
7. Bishara SE. Impacted maxillary canines: a review. *Am J Orthod Dentofacial Orthop* 1992; 101:159-71.
8. Peck S, Peck L, Kataja M. The palatally displaced canine as a dental anomaly of genetic origin. *Angle Orthod* 1994; 64:249-56.
9. Shapira Y, Kuffinec MN. Early diagnosis and interception of potential maxillary canine impaction. *J Am Dent Assoc* 1998; 129:1450-4.
10. Baccetti T. A controlled study of associated dental anomalies. *Angle Orthod* 1998; 68:267-74.
11. Brin I, Becker A, Shalhav M. Position of the maxillary permanent canine in relation to anomalous or missing lateral incisors: a population study. *Eur J Orthod* 1986; 8:12-6.
12. Ericson S, Kurol J. Longitudinal study and analysis of clinical supervision of maxillary canine eruption. *Community Dent Oral Epidemiol* 1986; 14:172-6.
13. Lappin M. Practical management of the impacted maxillary cuspid. *Am J Orthod Dentofacial Orthop* 1951; 37:769-78.
14. Zilberman Y, Cohen B, Becker A. Familial trends in palatal canines, anomalous lateral incisors, and related phenomena. *Eur J Orthod* 1990; 12:135-9.
15. Power SM, Short MB. An investigation into the response of palatally displaced canines to the removal of deciduous canines and an assessment of factors contributing to favourable eruption. *Br J Orthod* 1993; 20:217-23.
16. Jacobs SG. Reducing the incidences of palatally impacted maxillary canines by extraction of deciduous canines: a useful preventive/interceptive orthodontic procedure. Case reports. *Aust Dent J* 1992; 37:6-11.
17. Jacoby H. The etiology of maxillary canine impactions. *Am J Orthod* 1983; 84:125-32.
18. Jacobs SG. Localization of the unerupted maxillary canine: how to and when to. *Am J Orthod Dentofacial Orthop* 1999; 115:314-22.
19. Ericson S, Kurol J. Radiographic examination of ectopically erupting maxillary canines. *Am J Orthod Dentofacial Orthop* 1987; 91:483-92.
20. Caminiti MF, Sandor GK, Giambattistini C, Tompson B. Outcomes of the surgical exposure, bonding, and eruption of 82 impacted maxillary canines. *J Can Dent Assoc* 1998; 64:572-4, 576-9.
21. Rohlin M, Rundquist L. Apical root anatomy of impacted maxillary canines. A clinical and radiographic study. *Oral Surg Oral Med Oral Pathol* 1984; 58:141-7.
22. Preda L, LaFianza A, DiMaggio EM, Dore R, Schifino MR, Campani R, and others. The use of spiral computed tomography in the localization of impacted maxillary canines. *Dentomaxillofac Radiol* 1997; 26:236-41.
23. Kotsomitis N, Freer TJ. Inherited dental anomalies and abnormalities. *ASDC J Dent Child* 1997; 64:405-8. Review.
24. Ericson S, Kurol J. Resorption of maxillary lateral incisors caused by ectopic eruption of the canines. A clinical and radiographic analysis of predisposing factors. *Am J Orthod Dentofacial Orthop* 1988; 94:503-13.
25. Ericson S, Kurol J. Early treatment of palatally erupting maxillary canines by extraction of the primary canines. *Eur J Orthod* 1988; 10:283-95.
26. Rimes RJ, Mitchell CN, Willmot DR. Maxillary incisor root resorption in relation to the ectopic canine: a review of 26 patients. *Eur J Orthod* 1997; 19:79-84.

A D V E R T I S E R S '   
 I N D E X

ACI Communications Inc. ....	491
Ash Temple Ltd. ....	466
CDSPI .....	472, 502, 512, 519
Cirrus Management Group .....	481
Concord Dental Seminars .....	485
DIS Booklets. ....	492-3
Dr. F. Oliveira. ....	501
Dynamic Seminars .....	491
Ivoclar North America Inc. ....	470
J.O. Butler Co. Ltd. ....	468
Maximum Separation Systems Inc. ....	485
Miami Winter Meeting .....	496
Nobel Biocare. ....	520
Oral-B Labs .....	469, 511
2001 Convention .....	482

C D A R E S O U R C E   
 C E N T R E

For additional articles on impacted permanent maxillary cuspids, CDA members can contact the Resource Centre, tel.: **1-800-267-6354** or **(613) 523-1770**, ext. 2223; fax: **(613) 523-6574**; e-mail: **info@cda-adc.ca**.