

# Splinting Teeth — A Review of Methodology and Clinical Case Reports

• **Izchak Barzilay**, DDS, Cert. Prostho., MS •

## A b s t r a c t

*Splinting teeth to each other allows weakened teeth to be supported by neighbouring teeth, although the procedure can make oral hygiene procedures difficult. Several methods for splinting teeth, both extracoronal and intracoronal, as well as the materials commonly used for splinting, are described and illustrated. Two case reports are used to demonstrate the situations in which splinting might be appropriate.*

**MeSH Key Words:** dental bonding; periodontal splints; tooth mobility/therapy

© J Can Dent Assoc 2000; 66:440-3  
This article has been peer reviewed.

Splinting teeth to each other allows weakened teeth to gain support from neighbouring ones. When used to connect periodontally compromised teeth, splinting can increase patient comfort during chewing. Connecting multiple teeth also increases support when the teeth are used as abutments for a precision attached partial denture. However, splinting makes oral hygiene procedures difficult. Therefore, to ensure the longevity of the connected teeth, special attention must be given to instructing the patient about enhanced measures for oral hygiene after placement of the prosthesis.

Several methods, both extracoronal and intracoronal, are available to splint teeth together.

### Extracoronal Splinting

The simplest way to connect teeth to each other is the classic bonding method. The enamel surface of the tooth is etched, most commonly with a 37% solution of phosphoric acid. Composite resin can then be bonded to the etched surface and used to rigidly connect the teeth to each other. The composite-resin splint can be strengthened by adding fibres to the splint or by using a fibre meshwork (e.g., Ribbond, Ribbond Inc., Seattle, WA) to reinforce the material.

Extracoronal resin-bonded retainers, which can be fabricated in the dental laboratory, serve to strengthen the overall bonded situation. The splints are usually cast from metals, usually non-noble alloys that can be electrolytically or chemically etched (Fig. 1). Recent innovations in materials allow these frameworks to be air abraded and then cemented in place with an adhesive resin cement, such as Metabond C&B (Parkell Inc.,

Farmingdale, NY), Panavia (J. Morita USA Inc., Irvine, CA) or All Bond (Bisco Inc., Schaumburg, IL). This type of splint has greater inherent strength than a composite-resin splint created intraorally. Extra features such as grooves, pins and parallel preparations increase the retentive capacity of these splints.

Newly developed laboratory-cured composite resins such as DiamondCrown (Biodent Inc., Mont-Saint-Hilaire, QC) claim improved diametric tensile strength and bonding capabilities. These materials may be considered for use in extracoronal applications (Figs. 2-4). No long-term clinical data are available for these materials; however, they seem promising at this time.

### Intracoronal Splinting

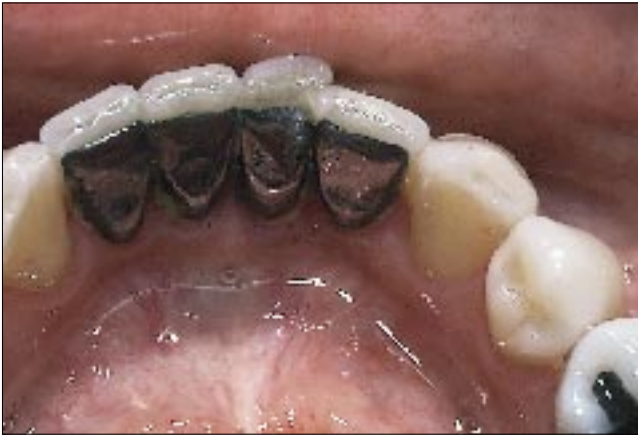Intracoronal methods are also available. Composite-resin restorations can be placed in adjoining teeth and cured to eliminate any interproximal separation. These restorations can be further reinforced with metal wires, glass-reinforced fibres or pins (Fig. 5). If restoration of the mouth includes crowns, the crowns can be splinted to each other by solder joints or precision attachments. The use of attachments affords the practitioner the ease of preparing nonparallel abutments yet achieves a splinted result.

### Case Reports

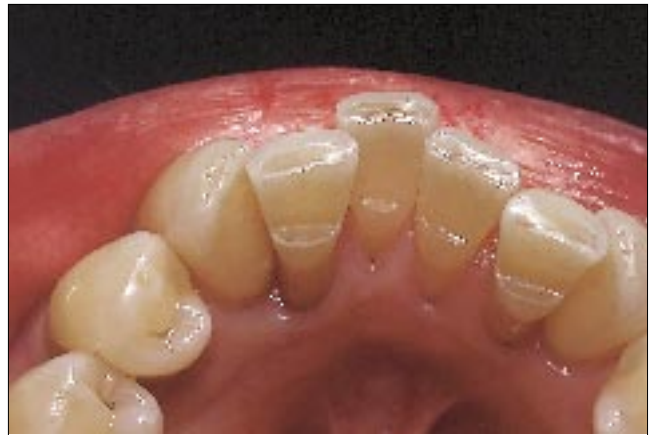This paper presents two clinical cases in which splinting was needed after crowns had already been placed.

#### Case 1

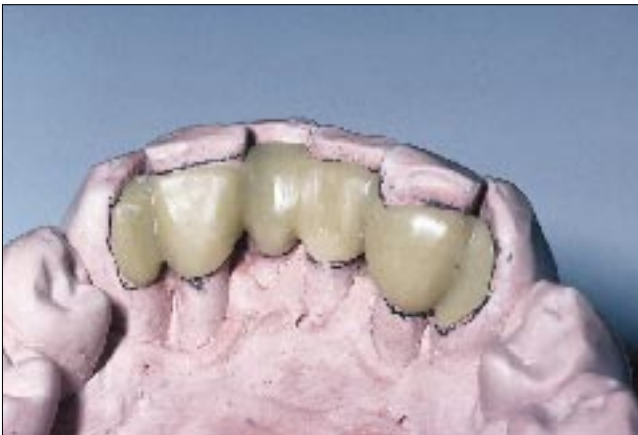A 60-year-old woman was involved in a motor vehicle accident. Prosthetic reconstruction involved placing crowns on



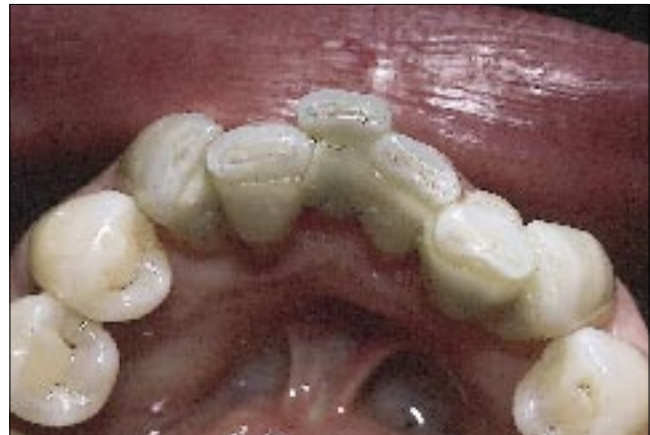**Figure 1:** Metal splint created from non-noble metal has been bonded with Metabond C&B cement and is being used to secure mobile teeth.



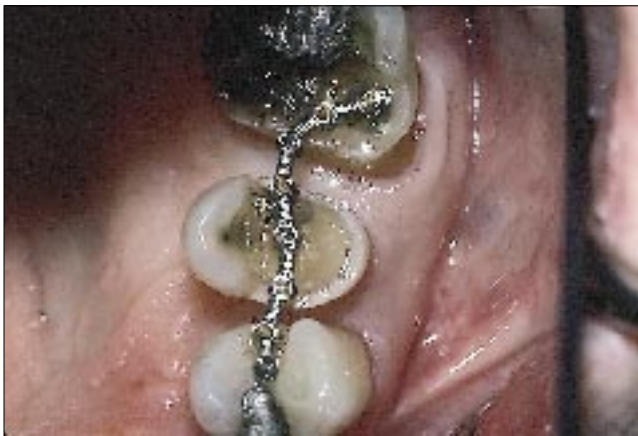**Figure 2:** Mobile teeth have been prepared with cingulum rests to help support an extracoronal composite-resin-based splint.



**Figure 3:** A composite-resin-based splint has been fabricated from DiamondCrown material. Once polished, it will be ready for cementation.



**Figure 4:** DiamondCrown splint has been cemented (bonded) under rubber dam isolation. This material exhibits superior flexural strength and may be useful in extracoronal splints.



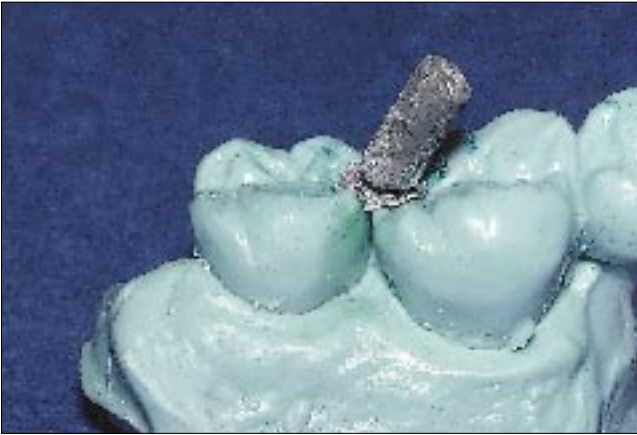**Figure 5:** Metal-based wire splint (Splint-Lock System, Whaledent Inc., New York, NY) is secured to mobile teeth with individual metal-based pins. The metal splint is then covered and bonded to the mobile teeth with composite resin.

most of the remaining teeth, as well as increasing support in the anterior region of the mouth with osseointegrated implants. Approximately one year after conclusion of the implant treatment, the contact region between the upper left

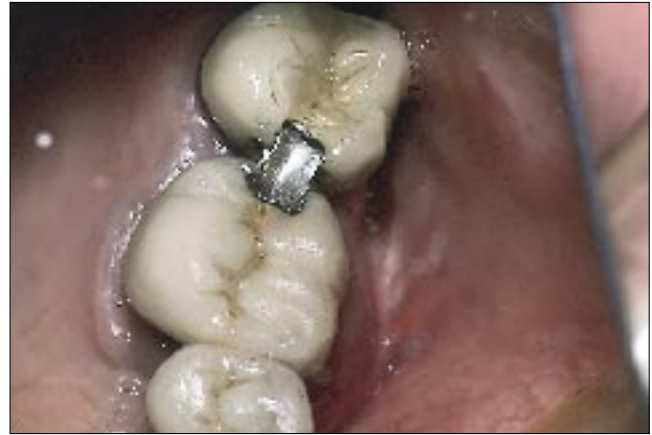first and second molars opened. Food was becoming trapped in this area, and inflammation ensued. In an attempt to remedy the problem, the crown on the second molar was replaced with a new crown, which had mesial contact. Approximately one year later the contact opened once again. Occlusion was deemed adequate; therefore, to close the contact area, splinting the 2 teeth together was attempted.

The crowns on teeth 26 and 27 consisted of porcelain fused to metal, so splinting would involve bonding to metal as well as porcelain. Back-to-back inlays with dovetail designs were prepared (MO in tooth 27 and DO in tooth 26). A polyether impression was made (Impregum, ESPE America Inc., Norristown, PA), and an epoxy die was poured. An inlay based on this die was waxed to extend from tooth 26 to tooth 27, across the interproximal area. The wax pattern was invested and cast in a nickel-chrome-beryllium alloy (Pisces, Ivoclar/Williams USA, Amherst, NY) (Fig. 6). The inlay was air abraded (microetched) with 25- $\mu$ m aluminum oxide and thermochemically etched (Assure-etch, Ivoclar/Williams USA, Amherst, NY) in preparation for cementation.

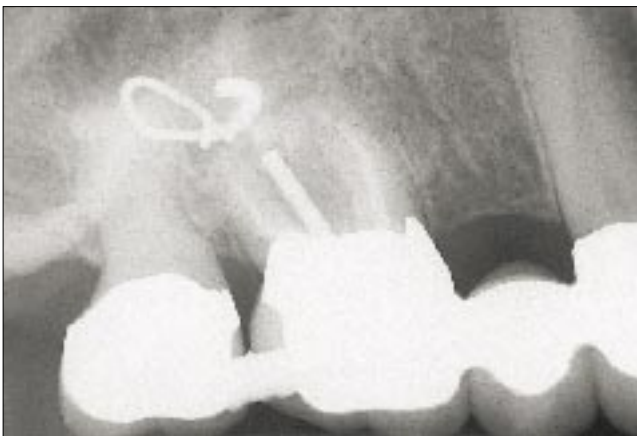
Cementation involved first treating the crowns to render them amenable to bonding. After isolation with a rubber dam,



**Figure 6:** Inlay made from non-noble metal has a handle and has been cast, fit to the master cast and etched; once the inlay is cemented in place, the handle is sectioned and removed.



**Figure 7:** The inlay has been cemented with Metabond C&B. The inlay remained secure after 4 years of service.



**Figure 8:** Periapical radiograph shows the splint bonded to the 2 crowns, which are made of porcelain fused to metal. The inlay appears suspended in the porcelain portion of the restoration.

the inlay surface was treated with a combination of air abrasion of the exposed metal surface and etching (with 10% hydrofluoric acid for 5 minutes) of the prepared porcelain surface. The etched porcelain surface was then primed with Etch Free (Parkell Inc., Farmingdale, NY), and the inlay was bonded in position with Metabond C&B cement. After a 10-minute set, the inlay was adjusted for occlusion and polished (Figs. 7 and 8).

The patient has been recalled yearly for the past 4 years, and there has been no change in the contact region. The inlay restoration has been secure, and there are no signs of deterioration in the material or the bond to the existing restorations.

### Case 2

A 50-year-old woman presented for restoration of the left mandibular second molar. Treatment was accomplished with a full metal crown. After 2 years in service, the mesial contact of the restoration opened up, which allowed food to impact between the teeth. This suggested that the second molar had drifted distally. Because the restoration on the second molar was relatively new and the crown in the first molar position


(porcelain fused to metal) was well made and had no clinical deficiency, a conservative approach to the open contact was needed. It was decided to splint the 2 existing restorations across the contact area with a cast restoration. Such an approach should effectively close the contact region and keep food from impacting.

A “double-dovetail” restoration was prepared in the disto-occlusal surface of tooth 36 and the mesio-occlusal surface of tooth 37. A polyether impression of the preparation was made, and an epoxy die was fabricated. A wax pattern was made and cast in non-noble alloy. A handle was left in the casting for easy manipulation (Fig. 9). After the fit of the casting had been verified, the casting underwent air abrasion and thermochemical etching. A rubber dam was applied, and the intraoral restorations were treated according to their material composition. The preparation in the gold crown (tooth 37) was air abraded, and the preparation in the porcelain-fused-to-metal crown (tooth 36) was etched with hydrofluoric acid (10%) for 5 minutes and treated with a silane coupling agent (Fig. 10). The restoration was then cemented with Metabond C&B. After complete setting of the cement, the handle was sectioned, the occlusion adjusted and the restoration polished. The contact has effectively been sealed for the past 3 years (Fig. 11).

### Discussion

Splinting is usually used to connect teeth to improve support. Splinting may also be used to close contact areas that have opened or that cannot be kept closed. If the teeth adjacent to the open contact area have not undergone any restoration, simple enamel bonding may be used to close the contact region. For teeth with intracoronal restorations, the restorations may be removed and replaced with new restorations connected across the contact area. Teeth with full-coverage restorations may also be connected by means of a restorative preparation across the contact region; in this case, the preparation is fabricated in the laboratory and then bonded in the mouth. The key to this method is the ability to bond to the existing restoration. With currently available

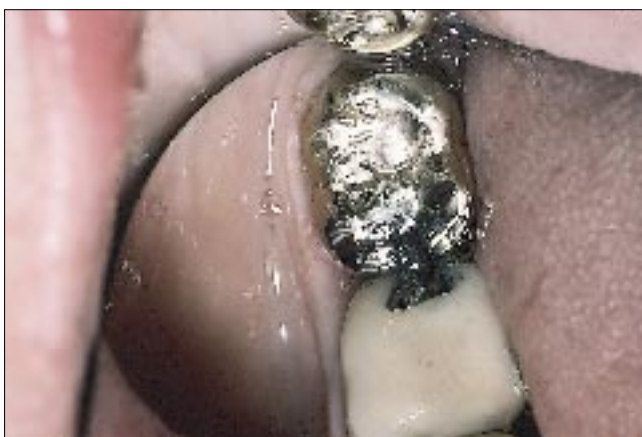



**Figure 9:** Inlay restoration is fabricated with a handle for easy intraoral manipulation. The handle will be sectioned once the restoration is bonded in position.



**Figure 10:** Teeth 36 and 37 have been isolated and treated on the basis of their respective materials. The metal surface (tooth 37) has been air abraded (microetching), and the porcelain surface (tooth 36) has been etched with hydrofluoric acid. The crowns are now ready for bonding.



**Figure 11:** The metal splint has been bonded in position. The splint has been functioning without complications for 3 years.

bonding cements and surface treatments, intraoral bonding is possible. Intraoral air abrasion (microetching) allows a metal surface to be roughened and cleaned. Etching porcelain with hydrofluoric acid roughens and cleans the surface. Applying a silane coupler and then a bonding agent to the porcelain and then using a bonding resin cement allows the complete restoration to be sealed and secured in place.

In case 1, Etch Free rather than a silane coupler was used to aid in bonding to porcelain. Etch Free is a silane-like material that does not require etching of porcelain for bonding to occur; it is designed to be used with Metabond C&B cement. The author felt that etching would increase the surface area and would only increase bond strength. In case 2 the standard silane coupler was used together with the bonding cement.

Metabond C&B is a cement that bonds to multiple metal surfaces, as well as to etched and primed porcelain. It cures in an aerobic environment and sets in approximately 10 minutes. This long setting time is somewhat of a disadvantage; however, this material was introduced to the North American market over 10 years ago and has proven itself under a variety of clinical applications. A non-noble metal was used because of

the strength of its bonding to Metabond C&B and because of its high strength in thin section.

The case reports presented here illustrate the use of bonding methods to connect existing restorations. Special consideration must be given to the individual materials that are being bonded, to allow selection of appropriate bonding methods and materials, and thus to assure success. ♦

---

*Dr. Barzilay is head of the division of prosthodontics and restorative dentistry, Mount Sinai Hospital, Toronto, Ont., and is an assistant professor, University of Toronto. He also maintains a private practice limited to prosthodontics and implant dentistry in Toronto.*

*Correspondence to: Dr. Izchak Barzilay, 905-2300 Yonge St., PO Box 2334, Toronto, ON M4P 1E4. E-mail: ibarzilay@tdc.on.ca*

*The author has no declared financial interest in any company manufacturing the types of products mentioned in this article.*

---