

# Tobacco-Associated Lesions of the Oral Cavity: Part II. Malignant Lesions

• Sayed M. Mirbod, DDS, M.Sc. •  
• Stephen I. Ahing, DDS, FRCD(C) •

## A b s t r a c t

*Nonmalignant tobacco-associated lesions of the oral cavity were discussed in the first part of this two-part article. Here, we describe malignant lesions associated with tobacco use, basic biopsy principles for such lesions and intervention strategies that dental professionals may use to reduce the chances of their patients developing precancerous lesions or primary malignancies.*

**MeSH Key Words:** mouth neoplasms; smoking/adverse effects; tobacco, smokeless/adverse effects

© J Can Dent Assoc 2000; 66:308-11  
This article has been peer reviewed.

Oral cancer accounts for about 3-4% of all cancers. Of all oral cancers, 96% are carcinomas and 4% are sarcomas. The most common type of oral cancer is squamous-cell carcinoma, constituting about 90% of oral malignancies.<sup>1</sup>

Tobacco smoke contains a number of hydrocarbons that are powerful carcinogens. Tobacco smoke and unburned tobacco, used in chewing or snuff dipping, also contain several potent nitrosamines. These chemicals are all DNA-toxic carcinogens that may play a key role in the initiation and promotion of specific types of cancer such as squamous-cell carcinoma and verrucous carcinoma<sup>2</sup> (Figs. 1 and 2).

Although the most common intraoral site for carcinoma is the posterior ventrolateral border of the tongue, the floor of the mouth is also frequently affected. Together with the retromolar region, these areas form a horseshoe-shaped zone of increased cancer susceptibility and the location of about 75-85% of all intraoral cancers<sup>3</sup> (Fig. 3).

Squamous-cell carcinoma of the tongue is the most common oral malignancy, accounting for 25-40% of all oral carcinomas. Characteristically, it appears as an indurated, nonhealing ulcer with elevated margins. Occasionally, the neoplasm may have a prominent exophytic as well as an endophytic growth pattern. Metastasis from the tongue to ipsilateral lymph nodes of the neck is relatively common.

The floor of the mouth is the second most common intraoral location for squamous-cell carcinomas, accounting for 15-20% of all cases. The usual appearance is a red or white, painless, nonhealing, indurated ulcer. Occasionally, the lesion

may widely infiltrate the soft tissues of the floor of the mouth, causing decreased mobility of the tongue, characterized clinically by alteration of speech. Altered speech, persistent hoarseness or chronic cough with or without bloody sputum (hemoptysis) may indicate laryngeal metastasis or malignancy.

Lip carcinomas account for 25-30% of all oral cancers. The slower growing, more common carcinoma of the lower lip has a better prognosis than upper-lip lesions. Lesions occur on the vermilion border and may appear as chronic nonhealing ulcers or exophytic lesions that are occasionally verrucous. Deeper invasion, clinically characterized by induration, occurs later in the course of the disease, and metastases to submental and submandibular lymph nodes are more likely with histologically less-differentiated lesions and more advanced lesions.

Any chronic nonhealing ulcer present for two or more weeks must be biopsied to rule out squamous-cell carcinoma. Fine-needle aspiration for suspected cervical nodes, plain radiographs of the jaw bones if bone involvement is suspected, bone scans and computed tomography can also be helpful in diagnosis.<sup>1</sup> In most cases, treatment of oral cancers is best achieved by surgery or radiation, or a combination of these two methods.<sup>4</sup> Current research into chemotherapy and photodynamic therapy may provide additional modalities in the future.

Verrucous carcinoma, a less common tumour, represents 4.5-9% of oral squamous-cell carcinomas. It typically presents as a slowly enlarging, gray or white, warty, exophytic growth on the buccal mucosa or gingiva of older men with an average age of 65 years at time of diagnosis.<sup>5</sup> The most common sites

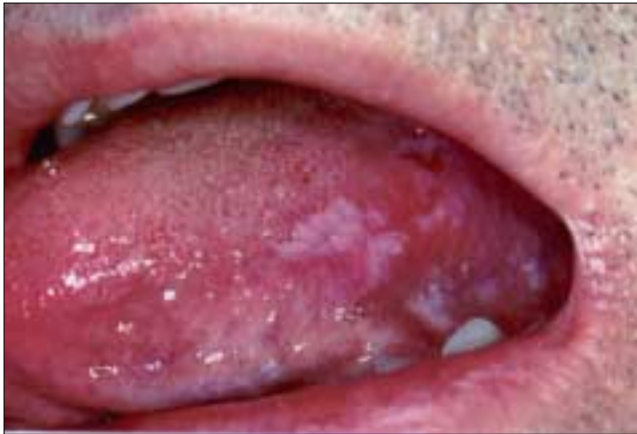

Figure 1: Squamous-cell carcinoma

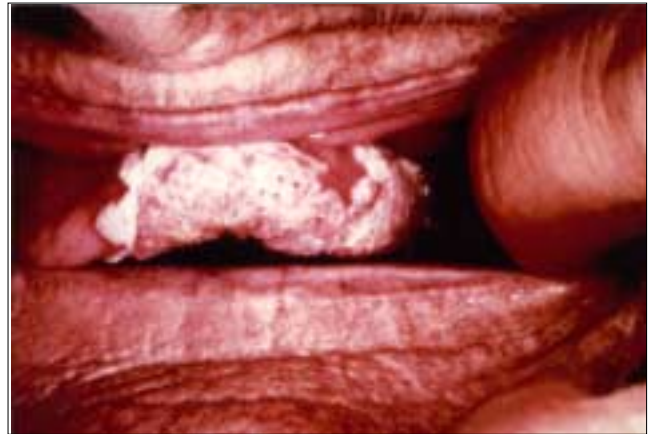

Figure 2: Verrucous carcinoma

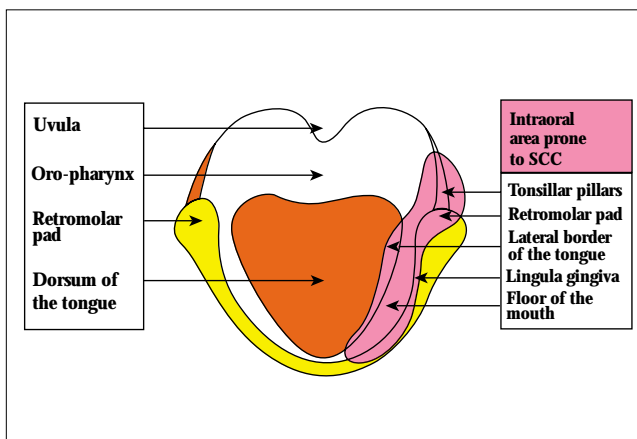


Figure 3: Diagram of an edentulous mandible showing the high-risk "horseshoe" area for squamous-cell carcinoma (half of the "horseshoe" is shown here). This area extends from tonsillar pillars to the trough of tissue formed by the lateral border of tongue, the floor of the mouth and the lingual gingiva.

of occurrence within the oral cavity are the buccal mucosa, gingiva and the alveolar ridge; other sites of involvement include the palate, floor of the mouth and lip. Microscopically, verrucous carcinoma appears as a papillary or verrucous low-grade (i.e., well-differentiated) squamous-cell carcinoma. There is overlying hyperortho- or parakeratosis, or both, and prominent well-polarized bulbous rete pegs that have a "pushing," rather than infiltrating quality at the base of the tumour. An intense mixed inflammatory infiltrate may surround and blend with the tumour and may contribute to the occasional misdiagnosis of verrucous carcinoma as pseudoepitheliomatous hyperplasia or chronic hyperplastic candidiasis. When a diagnosis of verrucous carcinoma is considered, a full-thickness biopsy down to the periosteum or submucosa must be performed to minimize the chances of misdiagnosis.<sup>6</sup> Because of its superficial, cohesive growth pattern and sharply demarcated margins, verrucous carcinoma is ideally suited for treatment by surgical excision or laser therapy.

As dentists are in a position to notice malignant transformations in the oral cavity of habitual tobacco users, it is important for them to be familiar with the clinical characteristics of

common oral carcinomas, which are summarized in Table 1. Table 2 provides a list of warning signs and symptoms for oral carcinomas that can be used by the general practitioner to determine the need for biopsy and referral to a specialist.

### Basic Principles of Biopsy

The standard procedure in the diagnosis of precancerous and cancerous lesions of the mouth is a biopsy. Certain principles are important to the successful procurement and submission of tissues for histologic examination:

- the site of the biopsy should be representative of the pathological process;
- the tissue must be removed as atraumatically as possible;
- an appropriate preservative should be used;
- relevant clinical information should be provided to the oral pathologist.

In general, sufficient tissue should be removed from areas that show a clinical abnormality. The surgeon should avoid undue distortion of the specimen by squeezing, traction sutures or direct injections of local anesthetic and submit the specimen to an oral pathology laboratory in 10% neutral buffered formalin. Reconstitution of formalin that has dried out must be avoided; specimens should not be sent in saline and, in extremely cold weather, the specimen container should not be mailed. The requisition sheet should include the patient's name, age, sex, location of the lesion, its morphologic description, its biological behaviour including signs and symptoms, any radiographic findings, any pertinent medical history and any previous pathologic diagnoses of the mouth.

### Prevention and Intervention

Dental professionals may adopt preventive strategies to reduce their patients' chances of developing precancerous lesions or primary malignancies, and to slow progression of established precancerous lesions. Excessive use of tobacco and alcohol are the major contributing factors in the etiology of oral squamous-cell carcinoma and, therefore, the major focus for prevention programs. In general, there has been a reluctance to use medication to treat these addictions because they are not viewed as medical disorders but as lifestyle choices; thus, psychological approaches have been emphasized.

**Table 1 Commonly encountered oral malignancies in habitual tobacco users**

Lesion	Site	Relative Frequency	Appearance
Squamous-cell carcinoma (SCC)	Tongue	25-40%	Indurated, nonhealing ulcer
SCC	Floor of the mouth	15-20%	Red or white painless, indurated nonhealing ulcer
SCC	Lip	25-30%	Chronic nonhealing ulcer at the vermilion border
SCC	Gingiva	10%	Mimics inflammatory changes
Verrucous carcinoma	Buccal mucosa, gingiva, alveolar ridge	4.5-9% of all SCC	White, papillary lesion greater than 1 cm

Combined psychological and pharmacological approaches are often synergistic. Physician advice to stop smoking increases cessation rates compared with the absence of such advice.<sup>7</sup> Furthermore, recent studies have shown that motivated dentists with staff support and access to information on tobacco cessation counselling are able to contribute to tobacco control measures at rates comparable to those reported in medical settings.<sup>8,9</sup>

Although treatment options for tobacco addiction are rapidly expanding, practice guidelines established in 1996 by the American Agency for Health Care Policy and Research still provide valuable information regarding actions and strategies that must be taken by the clinician to encourage tobacco cessation.<sup>7</sup> These guidelines should be carefully reviewed by anyone attempting to incorporate a tobacco cessation protocol into his or her dental practice.

Pharmacological approaches to tobacco addiction involve the use of nicotine chewing gum, nicotine patches or bupropion hydrochloride (Zyban). All currently available therapies appear to be equally efficacious, approximately doubling the quit rate achieved with placebo.<sup>10</sup> (Note: Hughes and others<sup>10</sup> provide appropriate dosage protocols.) Pharmacological approaches to alcohol addiction are relatively new, and the most efficacious appear to be acamprosate and naltrexone; although other drugs have been used, supporting evidence is suboptimal.<sup>11</sup>

Once clinically visible lesions such as leukoplakia or erythroplakia have developed, pharmacotherapeutic agents may be used. This strategy attempts to prevent further progression of potentially precancerous lesions and is, therefore, termed chemoprevention. The major chemopreventive agents are retinoids (vitamin A analogues), but nonretinoid agents (e.g., interferon and green tea) are being studied.<sup>12</sup>

It seems that only a small proportion of lesions actually regress permanently and these tend to be small and homogeneous. Most lesions appear to return once the chemopreventive agents are discontinued.<sup>13</sup> Nevertheless, chemopreventive

**Table 2 Warning signs and symptoms of oral cancer**

Mode of Detection	Appearance
Visual	Erythroplakia, erythroleukoplakia and leukoplakia, especially in the "horseshoe" area of the mouth
	White or red patches, especially with a firm feel
	Ulcers not healing after two weeks
	Dark-coloured lesions on the roof of the mouth, especially ones with an exophytic component
Palpation	Enlarged hemorrhagic gingiva in all parts of the mouth that may have a greenish tinge
	Nonhealing extraction sockets, especially with extrusion of tissue
	Swelling in neck, especially one that is fixed and not tender
Patient history	Loose teeth in the absence of odontogenic infection or periodontitis
	Change in speech or persistent, unproductive cough
	Difficulty swallowing
Radiographic	Onset of numbness in face in the absence of trauma or infection
	Symmetrically widened periodontal ligament ("floating in air" appearance), especially in absence of periodontitis or histiocytosis
	Radiolucency with ill-defined borders with spindled root resorption, especially in the absence of a source of infection
	Bay-within-a-bay type resorption pattern
	Granular, sunburst or onion-skin periosteal reactions
	Perforation of cortex or tunnelling through cortex

agents are undergoing clinical trials and may be useful in selected cases.<sup>14</sup> A major challenge in chemoprevention is to find the histologically detectable biochemical marker molecules that would best reflect neoplastic transformation or progression in terms of deranged-cell proliferation and oncogenes. This is necessary to determine whether the therapeutic intervention is effective at a molecular level by carrying out serial biopsies. Although clinical lesions may disappear, cellular changes may still be detectable microscopically and are reason for recurrence.

A more detailed description of preventive oncology is beyond the scope of this paper, but we highly recommend that tobacco and alcohol histories be a part of all initial and follow-up appointment protocols and that dentists become familiar with referral mechanisms to local or national foundations that treat addictions. Information on addiction foundations in Canada can be obtained from the Canadian Centre on Substance Abuse in Ottawa ((613) 235-4048) or from any provincial ministry of health. Currently, addiction counsellors

are not governed by a single regulatory body and, in most if not all provinces, there are no licensure requirements. Many provincial addiction foundations offer library resources as well as courses focused on specific addictions for any member of the public, including health professionals. ♦

*Acknowledgments:* The authors gratefully acknowledge the assistance of Drs. Shirley Gelskey and David Singer in reviewing the manuscript.

*Dr. Mirbod* is a second-year periodontics resident at the University of Manitoba.

*Dr. Ahing* is an oral pathologist and head of the section of oral diagnosis at the University of Manitoba.

*Correspondence to:* Dr. Sayed M. Mirbod, Periodontics Clinic, Faculty of Dentistry, University of Manitoba, 790 Bannatyne Ave., Winnipeg MB R3E 0W2. E-mail: ummirbod@cc.umanitoba.ca.

The authors have no declared financial interest.

## References

1. Silverman S Jr. *Oral cancer*. 4th ed. Hamilton: B.C. Decker; 1998. p. 25-33.
2. Chambers MS, Jacob RF. How carcinogens cause cancer. *Tex Dent J* 1994; 111:13-9.
3. McGaw WT, Pan JT. Cancer of the gingiva, buccal mucosa, and palate. *J Can Dent Assoc* 1996; 62:146-50.
4. Barasch A, Safford M, Eisenberg E. Oral cancer and oral effects of anti-cancer therapy. *Mt Sinai J Med* 1998; 65:370-7.
5. Spiro RH. Verrucous carcinoma, then and now. *Am J Surg* 1998; 176:393-7.
6. Florin EH, Kolbusz RV, Goldberg LH. Verrucous carcinoma of the oral cavity. *Int J Dermatol* 1994; 33:618-22.
7. Fiore MC, Baker DL. The Agency for Health Care Policy and Research Smoking Cessation Clinical Practice Guideline. *JAMA* 1996; 275:1270-80.
8. Smith SE, Warnakulasuriya KA, Feyerabend C, Belcher M, Cooper DJ, Johnson NW. A smoking cessation programme conducted through dental practices in the UK. *Br Dent J* 1998; 185:299-303.
9. Severson HH, Andrews JA, Lichtenstein E, Gordon JS, Barckley MF. Using the hygiene visit to deliver a tobacco cessation program: results of a randomized clinical trial. *JADA* 1998; 129:993-1006.
10. Hughes JR, Goldstein MG, Hurt RD, Shiffman S. Recent advances in the pharmacotherapy of smoking. *JAMA* 1999; 281:72-6.
11. Swift RM. Drug therapy for alcohol dependence. *New Engl J Med* 1999; 340:1482-90.
12. Lingen MW. Understanding the biology of oral cancer and chemoprevention. *CDS Rev* 1998; 91:24-8.
13. Evans TRJ, Kaye SB. Retinoids: present role and future potential. *Br J Cancer* 1999; 80:1-8.
14. de Vries N, van Zandwijk N, Pastorino U. Chemoprevention of head and neck and lung (pre)cancer. *Recent Results Cancer Res* 1999; 151:13-25.

## C D A R E S O U R C E C E N T R E

The CDA Resource Centre can provide members with additional information or help with Medline searches on the effects of tobacco use on the oral cavity. Please contact the Resource Centre for a list of fees and services at **1-800-267-6354** or **(613) 523-1770**, ext. 2223; fax: **(613) 523-6574**; e-mail: **info@cda-adc.ca**.