

Gingival Hyperplasia Complicating Acute Myelomonocytic Leukemia

- Curtis L. Cooper, MD, FRCP(C) •
- Ruth Loewen, RN •
- Tsiporah Shore, MD, FRCP(C) •

A b s t r a c t

Many systemic illnesses manifest clinical signs in the oral cavity. A remarkable case of gingival hyperplasia heralding the presence of acute myelomonocytic leukemia (AML FAB-M4) is described. The oral manifestations of acute leukemia are reviewed.

MeSH Key Words: case report; gingival diseases; leukemia; myelocytic, acute

© J Can Dent Assoc 2000; 66:78-9
This article has been peer reviewed.

Chemotherapy-induced mucositis and infection, including herpes simplex ulcers and oral candidiasis are commonly observed complications of leukemia in the oral cavity. Primary manifestations include mucosal pallor secondary to anemia, odontalgia, ulceration of the palate, gingival bleeding, gingivitis, petechiae and ecchymoses of the hard and soft palate, tongue and tonsils are also observed.¹⁻⁴ Gingival hyperplasia secondary to leukemia cell infiltration is another noteworthy manifestation.

Case Report

A remarkable example of gingival hyperplasia was observed in a 35-year-old dentate man referred to our oncology department with a one-month history of fatigue, anorexia and gingival enlargement initially identified by his dentist (Fig. 1). Fetor oris and gingival hemorrhage, two often co-existing findings with gingival hyperplasia related to leukemia cell infiltration, were not detected. Several carious lesions were noted on examination and widespread caries was observed on roentgenography. On palpation, the gingiva was found to be spongy and painless. The tongue, palate, pharynx and temporomandibular joints were normal on examination. A 5-mm-diameter, painless, firm nodule was observed 1 cm lateral to the right nostril. It was first noted by the patient one month before presentation.

Given our concern about possible acute leukemia, which was substantiated by a complete blood count with differential, a bone marrow biopsy was performed and the nodule was excised. Both the bone marrow and the nodule demonstrated leukemia cell infiltration, confirming the diagnosis of acute myelomonocytic leukemia (AML FAB-M4). As no other likely cause for gingival enlargement was identified from patient

examination and laboratory investigation, leukemia cell infiltration was presumed and the patient was spared a gingival biopsy.

Dental extraction was performed, as the consulting dentist concluded that the carious condition was beyond salvage (Fig. 2). The risk of bacteremia secondary to the carious condition also convinced us of the need for extraction. Induction therapy with cytarabine and idarubicin resulted in remission of the leukemia and partial resolution of the gingival enlargement. Our patient is currently receiving consolidation therapy in an effort to cure the leukemia. Gradual resolution of the gingival hyperplasia continues to be observed.

Discussion

Gingival hyperplasia is secondary to infiltration of the gingival tissue with leukemia cells and is well described in the literature.¹⁻⁴ In the most extensive review of the topic, gingival hyperplasia was observed in acute myelogenous leukemia (AML) with a frequency of 3% to 5% among 1,076 patients receiving anti-leukemia chemotherapy at a referral centre.⁵ Gingival hyperplasia is most commonly seen with the AML subtypes acute monocytic leukemia (M5) (66.7%), acute myelomonocytic leukemia (M4) (18.5%), and acute myelocytic leukemia (M1, M2) (3.7%).

Gingival hyperplasia is characterized by progressive enlargement of the interdental papillae as well as the marginal and attached gingiva. In the condition's most pronounced form, the crowns of the teeth may be covered. Gingiva appear swollen, devoid of stippling and pale red to deep purple in colour. Mucosal hemorrhages, ulcerative gingivitis, infectious gingivitis and odontalgia may be observed.^{2,3} Pallor, spontaneous hemorrhage, petechiae and ulceration have been described to occur more frequently in acute than chronic

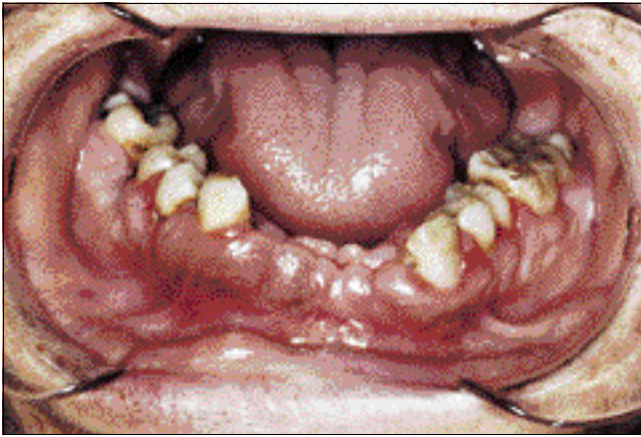


Figure 1: Pre-chemotherapy gingival hyperplasia.

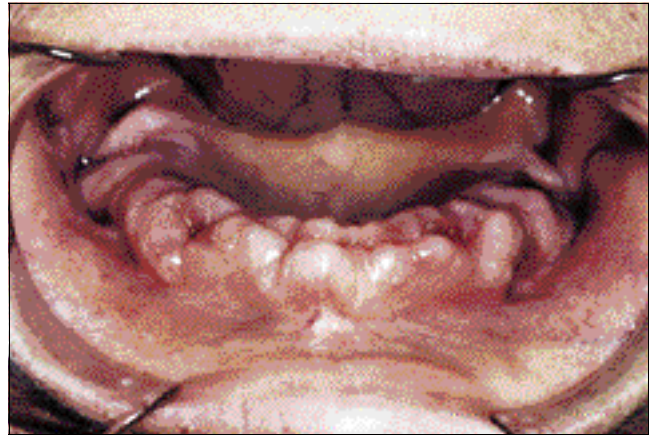

Figure 2: Pre-chemotherapy gingival hyperplasia following dental extraction.

leukemia.⁴ Histologic characteristics are similar for each subtype of leukemia aside from the morphologic form of the invading cells. These cells are characterized by abundant mitotic figures. Typically, the lamina propria is densely packed with leukemia cells extending from the basal cell layer of the epithelium into the gingiva, thereby altering the normal anatomy. Regional blood vessels are compressed by the infiltrate.

Gingival hyperplasia is more common in acute than chronic leukemia, in adults and in people with "aleukemia" or "subleukemic" forms of leukemia.^{1,5,6} Nonetheless, the development of gingival infiltration is unpredictable in any one patient. Gender has not been described as a risk factor for developing this manifestation. Leukemia cell gingival infiltrate is not observed in edentulous individuals, suggesting that local irritation and trauma associated with the presence of teeth may play a role in the pathogenesis of this abnormality.⁵ Dental caries and poor oral hygiene have not been described as risk factors for gingival hyperplasia. Additionally, an increased rate of dental caries as a complication of this abnormality has not been reported. However, poor oral hygiene and cavities predispose to superinfection, necrosis, pain and bleeding. The presence of caries in our patient was likely incidental. In general, surgery should be avoided in leukemia-afflicted patients with gingival hyperplasia.^{1,7} Our patient benefited from dental extraction of his many carious teeth prior to immunosuppressive therapy, as the risks of bacterial infection outweighed the risks associated with surgical procedures.

Generally, gingival hyperplasia resolves completely or at least partly with effective leukemia chemotherapy.¹ Of note, patients initially presenting with acute promyelocytic leukemia (M3) without gingival hyperplasia can develop this abnormality after all-transretinoic acid therapy.⁸ This manifestation is not considered to be predictive of poor outcome. New cutaneous lesions, oral or otherwise, are often the initial physical finding that leads to a diagnosis of leukemia. In a patient with known myeloproliferative disease, these findings often herald the development of a more aggressive disease with a poorer prognosis.^{9,10} This case reminds dentists and

physicians of the importance of recognizing mucocutaneous manifestations of systemic diseases. ♦

Dr. Cooper is an infectious diseases specialist at the Ottawa Hospital, Ottawa, Ont.

Mrs. Loewen is a clinical studies nurse investigator at the Health Sciences Centre, Winnipeg, Man.

Dr. Shore was a hematology and oncology specialist at the Health Sciences Centre, Winnipeg, Man.

Correspondence to: Dr. Curtis Cooper, Room G12, Ottawa Hospital, 501 Smyth Rd., Ottawa ON K1H 8L6

The authors have no declared financial interest.

References

1. Weckx LL, Tabacow LB, Marcucci G. Oral manifestations of leukemia. *Ear Nose Throat J* 1990; 69:341-2.
2. Barrett AP. Long term prospective clinical study of neutropenic ulceration in leukemia. *J Oral Med* 1987; 42:102-5.
3. Ishikawa G, Waldron CA. Diseases of the oral mucosa. In: Ishikawa CA, editor. *Color atlas of oral pathology*. St. Louis (MO): Ishiyaku EuroAmerica 1987; p. 71-102.
4. Bressman E, Decter JA, Chasens AI, Sackler RS. Acute myeloblastic leukemia with oral manifestations. Report of a case. *Oral Surg Oral Med Oral Pathol* 1982; 54:401-3.
5. Dreizen S, McCredie KB, Keating MJ, Luna MA. Malignant gingival and skin "infiltrates" in adult leukemia. *Oral Surg Oral Med Oral Pathol* 1983; 55:572-9.
6. Bluefarb SM. *Leukemia cutis* Springfield (IL): Charles C Thomas, Publisher; 1960.
7. Anil S, Smaranayake LP, Nair RG, Beena VT. Gingival enlargement as a diagnostic indicator in leukaemia. Case report. *Austr Dent J* 1996; 41:235-7.
8. Ruiz-Arguelles G, Garces-Eisele J, Ruiz-Arguelles A. ATRA-induced gingival infiltration: report of a case [letter]. *Am J Hematol* 1995; 49:364-5.
9. Duguid JK, Mackie MJ, McVerry BA. Skin infiltration associated with chronic myelomonocytic leukaemia. *Br J Haematol* 1983; 53:257-64.
10. Epstein JB, Priddy RW, Sparling T, Wadsworth L. Oral manifestations in myelodysplastic syndrome. Review of the literature and report of a case. *Oral Surg Oral Med Oral Pathol* 1998; 61:466-70.