

Use of Distal Implants to Support and Increase Retention of a Removable Partial Denture: A Case Report

Ilsler Turkyilmaz, DDS, PhD

Auteur-ressource

Dr Turkyilmaz

*Courriel :
turkyilmaz@uthscsa.edu*



SOMMAIRE

Le manque de support adéquat (dents/tissus mous) mène à un déplacement des prothèses partielles amovibles à extension distale bilatérale ou unilatérale. La mise en place d'implants est une option qui s'offre pour corriger ce problème. Ce rapport décrit la fabrication d'une prothèse partielle amovible inférieure soutenue par 2 implants distaux unilatéraux avec attachements de type locator. Le patient était un homme de 70 ans chez qui les prémolaires et molaires inférieures droites étaient absentes. Après une période de guérison de 3 mois sans incident, les attachements de type locator ont été insérés et vissés sur les implants. Au moment de la visite de rappel, 18 mois plus tard, les 2 implants étaient toujours en place mais une certaine perte osseuse marginale (moyenne de 0,3 mm; écart-type de 0,1 mm) a été observée. Le patient n'a signalé aucun déplacement de l'extension distale de la prothèse partielle amovible. Cette étude de cas laisse croire que des implants distaux peuvent aider à prévenir le déplacement des prothèses partielles amovibles à extension distale et qu'ils pourraient être particulièrement indiqués pour les patients qui n'ont pas les moyens de s'offrir des prothèses implanto-portées.

Pour les citations, la version définitive de cet article est la version électronique : www.cda-adc.ca/jcda/vol-75/issue-9/655.html

The design and maintenance of bilateral and unilateral distal extension partial dentures (Kennedy Class I and II) present challenges for clinicians,¹ as these dentures require support from the teeth, the mucosa and the underlying residual alveolar ridges. In particular, the distal extension removable partial denture (RPD) is subjected to vertical, horizontal and torsional forces that may have adverse effects during functional and parafunctional activities. Variations in the design of the framework and denture base can be used to compensate, at least to some extent, for these forces, which may affect retention, stability and support of the denture. Nonetheless, displacement of the denture, especially in the area of the distal extension, is likely.¹

To prevent displacement of the denture, precision attachments or conventional clasps have been widely used.^{2,3} In addition, denture bases are usually fitted to the surrounding tissue as accurately as possible. However, the rotational tendency of the RPD after long-term use cannot be eliminated completely, regardless of design and fit of the denture.⁴ To overcome this clinical challenge, single implants may be placed bilaterally at the distal extension of the denture base to minimize the potential for dislodgement of the denture.⁵⁻⁷ The chief goal of placing an implant under the posterior-most molar of the distal extension denture base is to stabilize the RPD in a vertical direction. Distal implants effectively convert a Kennedy Class I or II denture

to a Kennedy Class III denture. Therefore, a tooth- and implant-supported RPD is cheaper (because fewer implants are needed) and more stable, and may therefore be a better option for patients with limited financial resources than an implant-supported fixed partial denture.^{7,8} A few clinical reports have described partially edentulous patients with missing mandibular premolars and molars who have undergone rehabilitation with implant-supported RPDs.⁷⁻⁹

The current case report describes the fabrication of a mandibular RPD supported by existing anterior teeth and 2 distal single implants with locator abutments, which effectively prevented displacement of the distal extension of the partial denture.

Case Report

A 70-year-old partially edentulous man, who was missing the mandibular right lateral incisor, canine, premolars and molars (**Fig. 1**), was referred to the implant clinic of the department of restorative and prosthetic dentistry, College of Dentistry, Ohio State University. The patient's primary complaints were poor retention and esthetics of the existing denture and reduced function of his remaining teeth because of gradual wear. Three treatment options were presented: unilateral implant-supported fixed partial denture, tooth- and implant-supported RPD and conventional RPD. The patient chose the second option because of financial limitations and provided written informed consent before placement of the implants.

The patient's medical history revealed no major systemic problems except hypertension, which was controlled with β -blockers. The patient had edentulous areas in both arches, and physiologic abutment support was compromised. Because of severe wear of the mandibular anterior teeth, including loss of incisal enamel, ceramometal restorations with extracoronary precision attachments were not considered. Periodontal examination revealed generalized gingivitis, with localized bleeding on probing, generalized calculus and localized gingival recession.

The initial treatment consisted of scaling, root planing and oral hygiene instruction. The patient's existing conventional RPD was duplicated with self-curing acrylic resin (Ortho-jet, Lang Dental, Wheeling, IL) to fabricate a surgical stent. The surgical procedure consisted of local anesthesia and crestal incision, followed by elevation of

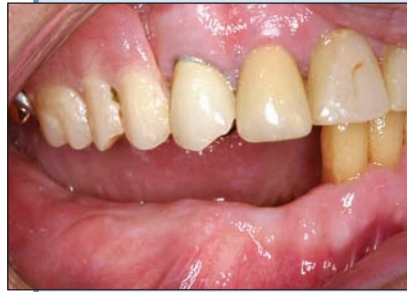

Figure 1: Intraoral view of the right mandible. The right lateral incisor, canine, premolars and molars are missing.

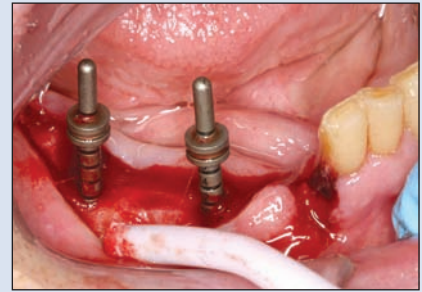


Figure 2: Two implant sockets were prepared after elevation of a flap.

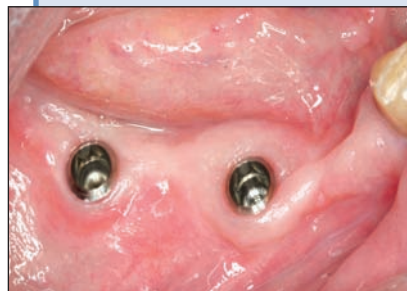

Figure 3: Three months after placement of the implants, the healing abutments were removed.

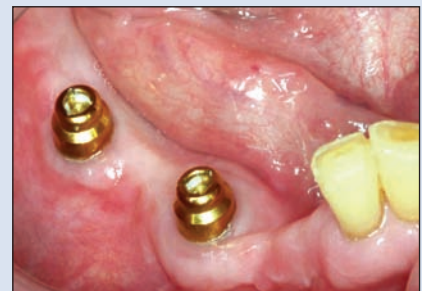

Figure 4: The locator abutments were tightened on the implants.

a full-thickness mucoperiosteal flap. After the implant sockets had been prepared (**Fig. 2**), 2 implants (4.1 mm in diameter, 12 mm in length; Straumann AG, Waldenburg, Switzerland) were placed without complication in the areas of the mandibular right second premolar and the right second molar using a one-stage surgical approach and a torque controller. The final insertion torque values recorded during placement of the implants were 35 and 40 Ncm, respectively. The mucosa was sutured after placement of the implants, with the healing abutments exposed. The placement of these 2 distal implants effectively changed the Kennedy classification of the partially edentulous arch from Class I (supported by tooth and tissue) to Class III (supported by tooth and implant). The patient's existing mandibular RPD was lined with soft-reline material after sufficient room had been established between the healing abutments and the interior acrylic surface of the denture, and the patient used the modified RPD during the osseointegration period.

Three months after placement of the implants, the healing abutments were removed (**Fig. 3**) and the locator abutments were tightened on the implants (**Fig. 4**). Preliminary impressions (Kromopan 100, Lascod, Des Plaines, IL) were made, and custom acrylic trays for

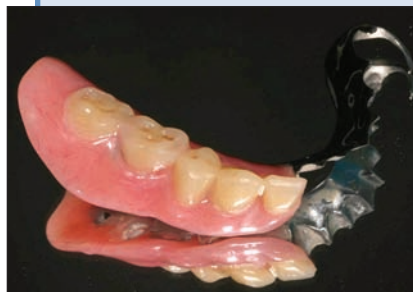

Figure 5a: Occlusal surface of the implant-supported removable partial denture (RPD).

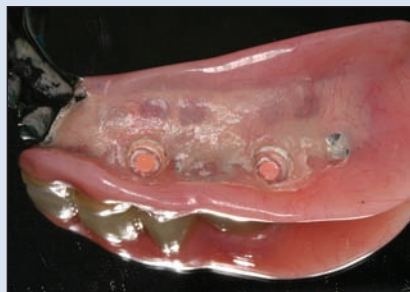

Figure 5b: Intaglio surface of the implant-supported RPD.

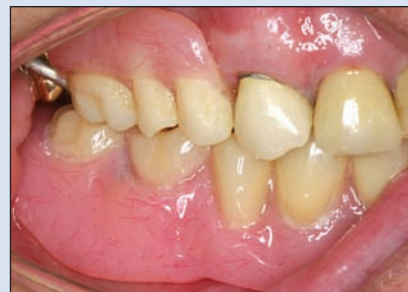

Figure 6: Intraoral view of the implant-supported RPD.

both maxilla and mandible were fabricated. The final impressions were made with silicone impression material, and then the definitive maxillary and mandibular casts with 2 locator analogues were poured and mounted on a semiadjustable articulator (Whip Mix Co., Louisville, KY), using a facebow and a centric relation record. After the occlusal wax rims had been tried in on the record bases, the tooth arrangement was completed and heat-curing acrylic resin was processed in the laboratory (Fig. 5). The maxillary conventional RPD and the mandibular implant-supported RPD, with 2 plastic retentive parts seated on the locator abutments, were delivered the same day (Fig. 6).

The patient was recalled 1 week and 1, 3, 6, 12 and 18 months after delivery of both dentures. At each of these follow-up appointments, the implants were stable; a mean of 0.3 mm (standard deviation 0.1 mm) of marginal bone loss was observed around the implants at the last appointment. The plastic retentive parts became worn and were replaced at the 18-month recall appointment. This was the only maintenance required, and the patient reported satisfaction with his implant-supported RPD.

Discussion

In this case, 2 implants were placed in the posterior mandible to support a mandibular RPD with distal extension for a patient with financial constraints, who could not afford an implant-supported fixed prosthesis. The implants and the mandibular RPD have been followed for 18 months. Only a few clinical reports describing similar treatments are available in the dental literature.⁶⁻⁸

Giffin⁷ treated a single patient by placing 1 implant on the left side of the posterior mandible. After 6 months, an overdenture abutment was seated on the implant, and a plastic overdenture retentive part was attached to the RPD after a relining impression had been made. The patient

claimed that the implant-supported side of the prosthesis felt more natural and was preferred for mastication over the tooth-supported side.

Kuzmanovic and colleagues⁸ treated a 66-year-old partially edentulous patient with an implant-supported RPD. In this patient, the mandibular premolars and molars were missing on both sides, and the anterior teeth were worn. They placed bilateral single molar implants to eliminate displacement of the distal extensions, a common problem with conventional RPDs. At the 2-year recall appointment, no prosthodontic maintenance was needed, except for simple activation of the gold matrices of the mandibular RPD to re-establish retention on the patrices.

Uludag and Celik⁶ pointed out that unilateral RPDs have the advantage of being more comfortable for patients, because there is less bulk in the mouth (no major connector), but they also have the disadvantage of easy dislodgement, which may cause some complications. Another major complication is the possibility that the patient may swallow a unilateral RPD of this type, since they are much smaller than conventional RPDs. Therefore, Uludag and Celik⁶ suggested using a distal single implant, which converts the Kennedy classification from Class II to Class III, to provide extra support and retention and to prevent major complications such as swallowing or aspiration.

Conclusion

In the patient described here, distal implants with locator abutments provided extra support and retention and prevented dislodgement of the patient's distal extension RPD. Randomized controlled trials with large samples are needed to better understand the efficacy of this treatment modality. ♦

THE AUTHOR



Dr. Turkyilmaz is assistant professor in the department of prosthodontics, Dental School, University of Texas Health Science Center at San Antonio, Texas.

Correspondence to: Dr. Ilser Turkyilmaz, Department of prosthodontics, Dental School, University of Texas, Health Science Center at San Antonio, 7703 Floyd Curl Dr., MSC 7912, San Antonio, TX 78229-3900, USA.

The author has no declared financial interests in any company manufacturing the types of products mentioned in this article.

This article has been peer reviewed.

References

1. Starr NL. The distal extension case: an alternative restorative design for implant prosthetics. *Int J Periodontics Restorative Dent.* 2001;21(1):61-7.
2. Ganz SD. Combination natural tooth and implant-borne removable partial denture: a clinical report. *J Prosthet Dent.* 1991;66(1):1-5.
3. Keltjens HM, Kayser AF, Hertel R, Battistuzzi PG. Distal extension removable partial dentures supported by implants and residual teeth: considerations and case reports. *Int J Oral Maxillofac Implants.* 1993;8(2):208-13.
4. Battistuzzi PG, van Slooten H, Kayser AF. Management of an anterior defect with a removable partial denture supported by implants and residual teeth: case report. *Int J Oral Maxillofac Implants.* 1992;7(1):112-5.
5. Jang Y, Emtiaz S, Tarnow DP. Single implant-supported crown used as an abutment for a removable cast partial denture: a case report. *Implant Dent.* 1998;7(3):199-204.
6. Uludag B, Celik G. Technical tips for improved retention and stabilization of a unilateral removable partial denture. *J Oral Implantol.* 2007;33(6):344-6.
7. Giffin KM. Solving the distal extension removable partial denture base movement dilemma: a clinical report. *J Prosthet Dent.* 1996;76(4):347-9.
8. Kuzmanovic DV, Payne AG, Purton DG. Distal implants to modify the Kennedy classification of a removable partial denture: a clinical report. *J Prosthet Dent.* 2004;92(1):8-11.
9. Pellecchia M, Pellecchia R, Emtiaz S. Distal extension mandibular removable partial denture connected to an anterior fixed implant-supported prosthesis: a clinical report. *J Prosthet Dent.* 2000;83(6):607-12.