

Oral Herpes Simplex Virus Infection in Pregnancy: What Are the Concerns?

Giuseppe Ficarra, MD; Catalena Birek, DDS, PhD, FRCD(C)

Auteure-ressource

Dre Birek
Courriel : birek@cc.umanitoba.ca



SOMMAIRE

Alors qu'il existe de nombreux rapports faisant état des données épidémiologiques sur la transmission de l'herpès *génital* de la mère à l'enfant durant l'accouchement et des effets potentiellement graves de cette transmission, les rapports publiés sur l'herpès *buccal* durant la grossesse demeurent limités et aucune directive précise n'a été publiée sur la prise en charge de cette infection. Des questions concernant l'acquisition, la transmission et l'issue de l'infection restent donc toujours sans réponse, notamment en ce qui a trait à la gingivo-stomatite aiguë durant la grossesse. Afin de fournir des réponses à ces questions, nous présentons un résumé de précédents rapports sur l'infection buccale par l'herpès simplex virus de type 1 (HSV-1) durant la grossesse et exposons brièvement 2 cas de gingivo-stomatite primaire durant le premier trimestre de la grossesse, dont l'issue a été favorable à la fois pour la mère et l'enfant. Nous présentons également les plus récentes données sur de rares, mais potentiellement graves, infections primaires du système nerveux central par le HSV-1 qui peuvent être traitées durant les stades plus avancés de la grossesse. Enfin, nous proposons une démarche multidisciplinaire pour la prise en charge des infections buccales par le HSV durant la grossesse, avec la participation du dentiste au diagnostic et au traitement.

Pour les citations, la version définitive de cet article est la version électronique : www.cda-adc.ca/jcda/vol-75/issue-7/523.html

Herpes simplex virus (HSV) types 1 and 2 are among the most ubiquitous viruses in the adult population, in the form of overt or latent infections. In immunocompetent people, the most common manifestations of HSV infections are uncomplicated and localized to the oral¹ or genital² area. HSV-2 is known as the primary cause of genital herpes, while HSV-1 is the main cause of oral herpes, including acute herpetic gingivostomatitis (mostly as primary infection) and herpes labialis (recurrent or secondary infection). However, HSV-1 has emerged increasingly frequently as an agent in genital herpes in some populations, and this may have an impact on acquisition of HSV infection in pregnancy.³⁻⁵

Both primary and secondary genital HSV infections may develop during pregnancy, with potentially severe consequences to the fetus or neonate. If transmitted to the embryo or fetus, these infectious agents may cause, albeit rarely, early embryonic or fetal damage, with or without miscarriage, or major congenital or developmental anomalies.⁶ If acquired intrapartum (during the passage through the birth canal), neonatal HSV infection often develops, usually between the first and fourth weeks of age. Without prompt effective treatment, the infected neonate progresses to potentially fatal disseminated multi-organ involvement, often with central nervous system (CNS) involvement, such as fulminant encephalitis.^{7,8}

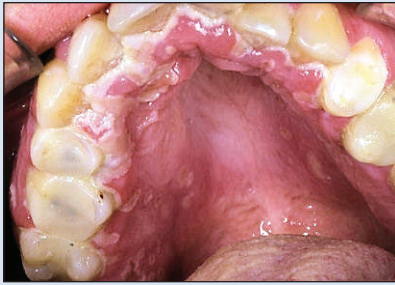


Figure 1: Multiple oral ulcers on gingiva and palate, as seen in primary herpetic gingivostomatitis in a woman in the eighth week of pregnancy.

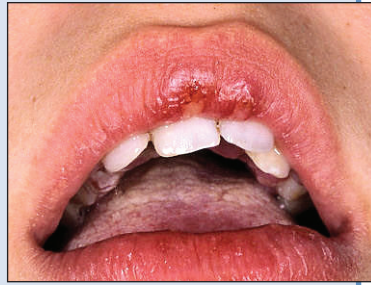

Figure 2: Lip lesions in primary herpetic gingivostomatitis in a woman in the 13th week of pregnancy.

In spite of the knowledge that herpes virus infections are extremely contagious, among all the files of this busy urban reference centre for oral diseases within this time span, we were able to find only 2 cases of acute herpetic gingivostomatitis during pregnancy. This would be consistent with an assumed low incidence of HSV-1 infection in pregnancy.

The diagnosis of herpetic gingivostomatitis was based on clinical manifestations (typical ulcerations on any oral mucosal surface, accompanied by lymphadenopathy and systemic symptoms) and laboratory findings.

Literature on the subject of oral HSV infections is particularly scarce, probably not because of a lack of interest in the problem, but more likely because of the relative rarity of overt oral HSV infection in pregnancy.

All the cases described in an earlier series⁹⁻¹² indicate that HSV-1 gingivostomatitis in the first, second and third trimester of pregnancy is not associated with adverse fetal effects. With respect to recurrent herpes labialis (RHL) before and during pregnancy, one study even showed a lower than average proportion of preterm births among affected mothers,¹³ and another allowed the conclusion that pregnant women with a history of RHL report a reduced incidence of RHL during pregnancy.¹⁴ Further, according to a recently published large, population-based study, self-reported maternal herpes labialis during pregnancy is not associated with a substantially increased risk of neural tube defects in infants.¹⁵

HSV Gingivostomatitis in the First Trimester of Pregnancy

Below we describe 2 previously unpublished cases of HSV-induced primary herpetic gingivostomatitis in women who acquired the disease during the first trimester of gestation. The documentation, oral clinical presentation, laboratory results and outcome were similar in the 2 cases. Observations support the assertion that with primary HSV-1 gingivostomatitis, at least during the first trimester, it is reasonable to expect a normal gestational course with a normal delivery and a good neonatal outcome.

To identify other cases of primary herpetic gingivostomatitis associated with pregnancy, we reviewed the files of the Reference Centre for the Study of Oral Diseases in Florence, Italy. The wide range of oral diseases seen at this centre includes oral cancer and precancer, infections and related conditions including those of HIV-associated immunosuppression, as well as salivary gland dysfunction, autoimmune dermatoses and bone diseases. Each year 2,300–2,500 new patients are seen. For the current study, we had access to records for 8 years, from 1988 to 2006.

Case 1

In September 1998, a 33-year-old woman was referred to our centre in week 8 of her first pregnancy because of multiple oral ulcers associated with fever of 3 days duration, nausea and anorexia. Oral examination revealed multiple ulcerations on the fixed gingiva, dorsum of tongue, vestibular and palatal mucosa (**Fig. 1**) in addition to cervical lymphadenopathy. HSV was isolated from the oral ulcers by viral culture. Microscopic examination of the cytological smears showed features typically seen in herpes infection, such as ballooning degeneration, margination of chromatin and multinucleation. The patient had no previous history of oral or genital herpes infection.

In consultation with the obstetrician, oral acyclovir (400 mg 5 times a day for 7 days) was offered to the patient. After 7–8 days, her oral condition returned to normal, and she was able to eat and drink without pain. The patient underwent a program of fetal monitoring until term and gave birth to a healthy boy in week 39 of pregnancy. At a follow-up interview in June 2007, she reported that the child was in perfect physical and mental health.

Case 2

In December 2005, a 26-year-old woman in week 13 of her pregnancy presented to our hospital with complaints of high fever, sore throat and eating and drinking difficulties that had started 4 days earlier. Oral examination showed multiple ulcerations on the attached gingiva, palatal mucosa and vermilion border of both lips (**Fig. 2**) in addition to enlarged cervical and submandibular lymph nodes. HSV-1, but not HSV-2, was isolated from the oral ulcers by polymerase chain reaction (PCR) investigation. Cytology revealed typical features of herpes infection, although the patient had no previous history of oral or genital herpes infection. She was treated with oral acyclovir, 800 mg 5 times a day for 7 days. The oral ulcers healed completely after 6–7 days of treatment. The patient was placed on a strict follow-up schedule by her obstetrician with periodic ultrasound evaluation. There was no

ultrasonographic evidence of fetal abnormalities. At gestational week 38, the patient gave birth to a healthy boy. At follow-up in June 2007, the child was in excellent physical and mental health.

Herpetic Encephalitis in Late Pregnancy

In a recent case study and review, Sellner and colleagues¹⁶ point out that the most common infectious agent of acute, sporadic encephalitis is HSV-1 (10%–20% of all cases in the United States) as either primary infection or reactivation of the virus. Although herpetic encephalitis in pregnancy is rare, it is most likely to occur in the late second and early third trimester of pregnancy. The triad signs of viral encephalitis have been described as fever, headache and altered mental state. Other common manifestations are seizures, hemiparesis and aphasia. Empirical treatment with antibacterial and antiviral agents is often required before a specific diagnosis is made by viral culture and PCR from cerebrospinal fluid. Before the era of antiviral therapies, the prognosis for the mother and fetus was poor, but intravenous acyclovir therapy improved diagnosis and critical care have reduced mortality significantly. However, even with treatment, the long-term neurological sequelae of CNS disease in survivors remain a problem.^{16,17}

Conclusions

In spite of the probably favourable outcome of oral HSV-1 infection, at least in the first trimester, and the rarity of potentially severe CNS HSV-1 infection, the following concerns should be kept in mind in relation to pregnancy:

- the risk of acquisition and development of fulminant HSV-1 disease, which is higher than in the general population, because of physiological immunosuppression in pregnancy^{16,18}
- the risk of misdiagnosis, without prompt recognition of symptoms as those of HSV infection, and immediate initiation of treatment
- the possibility of non-peripartum modes of HSV-1 transmission to the infant, from oral lesions by direct contact with health personnel¹⁹

In view of these issues, understanding the significance of maternal oral herpes infection during pregnancy remains critically important. The primary responsibilities of the dentist with respect to oral HSV infection in general and HSV infection in pregnancy in particular, remain as follows:

- maintain strict infection control in the dental office
- be familiar with and promptly recognize manifestations
- be prepared to collect samples of oral lesions promptly for viral culture and type-specific laboratory diagnosis
- be prepared to refer the patient and participate in the treatment, management and monitoring of oral manifestations, in close consultation with the family physician, infectious disease specialist and obstetrician

- make patient education (as reviewed earlier)¹ an integral part of prevention as well as management

Although reactivation of oral HSV infection with routine dental treatment is common, previous research by Miller and colleagues²⁰ has shown that human herpes viruses, including HSV-1, are present in the saliva of healthy adults at levels that could facilitate transmission. Their data indicate that prophylactic treatment with valacyclovir (2 g taken twice on the day of dental treatment and 1 g taken twice the next day) significantly reduces the percentage of patients who develop recurrences and shed HSV-1 in saliva 72 hours after dental procedures and reduces the mean time to pain cessation.²¹ Based on these findings, the authors recommend that clinicians consider prophylactic antiviral therapy for patients at risk, to minimize recurrences as well transmission of the disease.

With respect to efficacy and safety of antiviral prophylaxis for preventing HSV primary infection or recurrence in the third trimester, the concerns of clinical trials to date have been limited largely to the problem of genital herpes,^{3,22,23} but it appears that treatment with acyclovir and valacyclovir is reasonably safe and effective. In view of this, it would be reasonable to extend the recommendations of Miller and colleagues to pregnant women with a history of oral recurrent HSV infections. Clearly, postponing dental treatment should be considered first. ♦

THE AUTHORS



Dr. Ficarra is the director of the Reference Centre for the Study of Oral Diseases and an adjunct professor at the University of Florence, Florence, Italy.



Dr. Birek is a professor in the department of oral biology, University of Manitoba, Winnipeg, Manitoba.

Correspondence to : Dr. Catalena Birek, University of Manitoba, Faculty of dentistry, Department of oral biology, 780 Bannatyne Avenue, Winnipeg MB R3E 0W2.

The authors have no declared financial interests.

This article has been peer reviewed.

References

1. Birek C, Ficarra G. The diagnosis and management of oral herpes simplex infection. *Curr Infect Dis Rep.* 2006;8(3):181-8.
2. Sen P, Barton SE. Genital herpes and its management. *BMJ.* 2007; 334(7602):1048-52.
3. Baker DA. Consequences of herpes simplex virus in pregnancy and their prevention. *Curr Opin Infect Dis.* 2007;20(1):73-6.
4. Kriebs JM. Understanding herpes simplex virus: transmission, diagnosis, and considerations in pregnancy management. *J Midwifery Womens Health.* 2008;53(3):202-8.
5. Brown EL, Gardella C, Malm G, Prober CG, Forsgren M, Krantz EM, et al. Effect of maternal herpes simplex virus (HSV) serostatus and HSV type on risk of neonatal herpes. *Acta Obstet Gynecol Scand.* 2007;86(5):523-9.

6. Avgil M, Ornoy A. Herpes simplex virus and Epstein-Barr virus infections in pregnancy: consequences of neonatal or intrauterine infection. *Reprod Toxicol*. 2006;21(4):436-45. Epub 2005 Jan 8.
7. Kimberlin DW. Herpes simplex virus infections in neonates and early childhood. *Semin Pediatr Infect Dis*. 2005;16(4):271-81.
8. Kimberlin DW. Herpes simplex virus infections of the newborn. *Semin Perinatol*. 2007;31(1):19-25.
9. Landthaler M, Eberth-Willershausen W. [Treatment of a herpetic gingivostomatitis with acyclovir (Zovirax) in a female patient in the last trimester of pregnancy.] *Hautarzt*. 1985;36(8):478-80. Article in German.
10. Granat M, Morag A, Margalioth EJ, Leviner E, Ornoy A. Fetal outcome following primary herpetic gingivostomatitis in early pregnancy. Morphological study and update appraisal. *Isr J Med Sci*. 1986;22(6):455-9.
11. Brown ZA, Selke S, Zeh J, Kopelman J, Maslow A, Ashley RL, et al. The acquisition of herpes simplex virus during pregnancy. *N Engl J Med*. 1997;337(8):509-15.
12. Pardo J, Yogev Y, Ben-Haroush A, Hod M, Amir J. Primary herpes simplex virus type 1 gingivostomatitis during the second and third trimester of pregnancy: foetal and pregnancy outcome. *Scand J Infect Dis*. 2004;36(3):179-81.
13. Bánhidly F, Puhó E, Acs N, Czeizel AE. Possible association between maternal recurrent orofacial herpes in pregnancy and a lower rate of preterm birth. *J Matern Fetal Neonatal Med*. 2006;19(9):537-42.
14. Scott D, Moore S, Ide M, Coward P, Baylis R, Borkowska E. Recrudescence of herpes labialis during and prior to early pregnancy. *Int J Gynaecol Obstet*. 2003;80(3):263-9.
15. Nørgård B, Nørgaard M, Czeizel AE, Puhó E, Sørensen HT. Maternal herpes labialis in pregnancy and neural tube defects. *Dev Med Child Neurol*. 2006;48(8):674-6.
16. Sellner J, Buonomano R, Nedeltchev K, Findling O, Schroth G, Surbek DV, et al. A case of maternal herpes simplex virus encephalitis during late pregnancy. *Nat Clin Pract Neurol*. 2009;5(1):51-6.
17. Kimberlin DW. Management of HSV encephalitis in adults and neonates: diagnosis, prognosis and treatment. *Herpes*. 2007;14(1):11-6.
18. Sridama V, Pacini F, Yang SL, Moawad A, Reilly M, DeGroot LJ. Decreased levels of helper T cells: a possible cause of immunodeficiency in pregnancy. *N Engl J Med*. 1982;307(6):352-6.
19. Hammerberg O, Watts J, Chernesky M, Luchsinger I, Rawls W. An outbreak of herpes simplex virus type 1 in an intensive care nursery. *Pediatr Infect Dis*. 1983;2(4):290-4.
20. Miller CS, Avdiushko SA, Kryscio RJ, Danaher RJ, Jacob RJ. Effect of prophylactic valacyclovir on the presence of human herpesvirus DNA in saliva of healthy individuals after dental treatment. *J Clin Microbiol*. 2005;43(5):2173-80.
21. Miller CS, Cunningham LL, Lindroth JE, Avdiushko SA. The efficacy of valacyclovir in preventing recurrent herpes simplex virus infections associated with dental procedures. *J Am Dent Assoc*. 2004;135(9):1311-8.
22. Sauerbrei A, Wutzler P. Herpes simplex and varicella-zoster virus infections during pregnancy: current concepts of prevention, diagnosis and therapy. Part 1: herpes simplex virus infections. *Med Microbiol Immunol*. 2007;196(2):89-94. Epub 2006 Dec 13.
23. Hollier LM, Wendel GD. Third trimester antiviral prophylaxis for preventing maternal genital herpes simplex virus (HSV) recurrences and neonatal infection. *Cochrane Database Syst Rev*. 2008;23(1):CD004946.