

# Dental Pulp Neurophysiology: Part 1. Clinical and Diagnostic Implications

Ashraf Abd-Elmeguid, BDS, MDSc; Donald C. Yu, DMD, CAGS, MScD, FRCD(C)

## Auteur-ressource

Dr Yu

Courriel : [donaldyu@ualberta.ca](mailto:donaldyu@ualberta.ca)



## SOMMAIRE

L'établissement d'un diagnostic en endodontie nécessite une compréhension de l'histologie, de la neurologie et de la physiologie de la pulpe, ainsi que du lien avec les divers outils diagnostiques couramment utilisés dans l'exercice de la dentisterie. Les variations thermiques dans le milieu buccal entraînent un déplacement rapide du contenu des tubules dentinaires qui provoque de la douleur. Cet effet, dit hydrodynamique, sert de fondement à l'évaluation de la sensibilité à la douleur durant les tests thermiques de vitalité pulpaire. L'innervation sensorielle de la dent est assurée par des centaines d'axones qui pénètrent dans la dent au niveau du foramen apical. L'innervation du complexe dentine-pulpe est assurée par les fibres A (delta et bêta) et les fibres C, qui sont classées en fonction de leur diamètre et de leur vitesse de conduction. Les fibres A sont principalement stimulées par l'application de froid qui provoque une douleur vive, alors que la stimulation des fibres C cause une douleur permanente sourde. En raison de leur emplacement et de leur disposition, les fibres C sont à l'origine de l'irradiation de la douleur. Cette première partie d'une étude en 2 volets examine le lien entre la sensibilité clinique observée durant la visite de diagnostic et la neurophysiologie de la pulpe dentaire afin d'évaluer le lien entre l'art (diagnostic clinique) et la science (neurophysiologie) de l'endodontie.

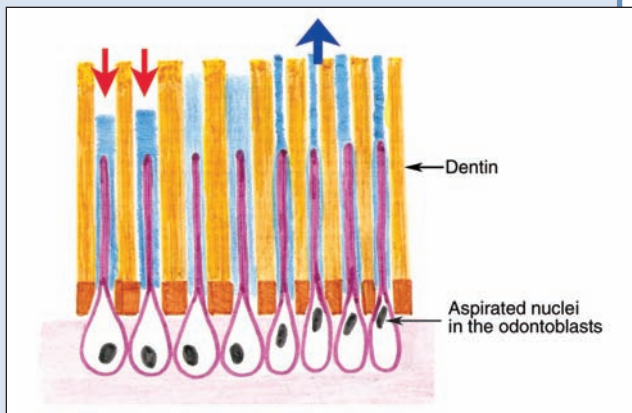
Pour les citations, la version définitive de cet article est la version électronique : [www.cda-adc.ca/jcda/vol-75/issue-1/55.html](http://www.cda-adc.ca/jcda/vol-75/issue-1/55.html)

The purpose of diagnosis in endodontics is to assess the condition of a tooth — the object of the patient's complaint — and to identify the cause of the pain or discomfort. Diagnosis is the art of identifying the problem and using scientific knowledge to determine the cause of the problem. Knowledge of the physiology of pain and methods of interpreting it with available clinical diagnostic devices is essential to reach a proper diagnosis.

The patient's history, or more specifically, the history of the patient's pain, is the first clinical data that the dentist must collect and consider. The dentist should pay careful attention to the patient's answers about the pain, such as the

type, duration, frequency, aggravating factors, effect of analgesics and tenderness when biting.

Once a preliminary or differential diagnosis is reached, further clinical examination is needed to confirm the diagnosis, such as inspection of the extraoral soft tissues, examination of regional lymph nodes and an intraoral examination that includes looking for signs of a sinus tract, swelling of the soft tissues, a mobile tooth or teeth, the condition of the gingiva, and the number of decayed and restored teeth. A transillumination test<sup>1</sup> may reveal hidden decay or a fractured tooth and may result in the diagnosis of a necrotic tooth if enamel translucency is lost. In this simple test, a strong light is placed behind



**Figure 1:** Illustration of the movement of dentinal fluid inside dentinal tubules in response to a hot stimulus (red arrow) and a cold stimulus (blue arrow).

the tooth. A vital tooth transmits light well because of its translucency, hence the term *transillumination*. A necrotic tooth appears dull and dark because of its compromised blood supply and the degeneration of the pigments inside its dentinal tubules. Radiographs, along with these data, can localize the offending tooth; then more specific tests can be done to assess the vitality of the tooth pulp.

Assessment of pulp vitality is especially critical in diagnosing cases where a periapical radiograph does not show any obvious pathosis. This includes evaluating cases of traumatized teeth or bridge abutments where a delay in diagnosing a dead pulp or a poor evaluation before bridge preparation may lead to inflammatory root resorption<sup>2</sup> or apical periodontitis<sup>3</sup> respectively.

Pain is produced when a stimulus strong enough to trigger a nervous response is applied to a tooth. The intensity, location and quality of pain will differ, depending on the type of stimulus, as well as the type of nerve fibres excited in the process. Pain is the main complaint for which dental treatment is mostly sought. One study<sup>4</sup> found that the most common orofacial pain is dental.

In this first part of our 2-part review, we discuss the types and interpretation of pulpal pain induced by various sensory fibres, using different clinical diagnostic methods. We do not discuss the different stages of pulpal inflammation, namely reversible and irreversible pulpitis, and pulp necrosis as they are beyond the scope of this review.

### Types of Nerve Fibres and Their Distribution Inside the Dental Pulp

Teeth are supplied by the alveolar branches of the fifth cranial nerve, namely the trigeminal nerve (the maxillary branch in the upper jaw and the mandibular in the lower jaw). Dental pulp is a highly innervated tissue that contains sensory trigeminal afferent axons.<sup>5,6</sup> Sympathetic efferent

fibres regulate the blood flow; no consensus about the role of parasympathetic fibres exists.<sup>7</sup>

The cell bodies of the sensory neurons of the pulp are located in the trigeminal ganglion. Hundreds, perhaps thousands, of axons found in the canines and premolars<sup>5,8</sup> enter the pulp through the apical foramen where they branch following the distribution of the blood supply all over the pulp. The majority of the nerve bundles reach the coronal dentin where they fan out to form the nerve plexus of Raschkow. There, they anastomose and terminate as free nerve endings that synapse onto and into the odontoblast cell layer (approximately 100–200  $\mu\text{m}$  deep in the dentinal tubules) and the odontoblastic cell processes.<sup>7,9</sup>

The 2 types of sensory nerve fibres in the pulp are myelinated A fibres (A-delta and A-beta fibres) and unmyelinated C fibres. Ninety percent of the A fibres are A-delta fibres, which are mainly located at the pulp–dentin border in the coronal portion of the pulp and concentrated in the pulp horns. The C fibres are located in the core of the pulp, or the pulp proper, and extend into the cell-free zone underneath the odontoblastic layer.<sup>10,11</sup>

The ratio of myelinated to unmyelinated fibres is difficult to ascertain because the nerve fibres in recently erupted teeth with open apices may not yet have acquired the myelin sheath.<sup>8,12</sup>

### Clinical Implications for Intrapulpal Sensory Nerve Fibres

The A-delta fibres have a small diameter and therefore a slower conduction velocity than other types of A fibres, but are faster than C fibres. The A fibres transmit pain directly to the thalamus, generating a fast, sharp pain that is easily localized. The C fibres are influenced by many modulating interneurons before reaching the thalamus, resulting in a slow pain, which is characterized as dull and aching.<sup>10</sup>

The A fibres respond to various stimuli such as probing, drilling and hypertonic solutions through the hydrodynamic effect.<sup>13–16</sup> This effect depends on the movement of the dentinal fluid in the dentinal tubules in response to a stimulus. Although the normally slow capillary outward movement does not stimulate the nerve endings and cause pain,<sup>17–19</sup> rapid fluid flow, as in the case of desiccating or drying dentin, is more intense and is likely to activate the pulpal nociceptors.<sup>13</sup> Heat or cold stimuli cause fluid movement through the dentinal tubules, resulting in a painful sensation in a tooth with a viable sensory pulp<sup>20,21</sup> (Fig. 1). This response is due to the rapid temperature change that causes a sudden fluid flow within the tubules and deforms the cell membranes of the free nerve endings. A gradual change in temperature, however, does not cause an immediate pain response because rapid fluid movement excites the A-delta fibres. The C fibres elicit a response to a gradual temperature change.<sup>10,22,23</sup>

A recent study<sup>24</sup> attributed the pain caused by thermal changes to the mechanical deformation of the enamel and

dentin that causes the outward movement of the fluid inside the dentinal tubules, triggering the nerve impulse (indirect effect). The authors explained their findings by the fact that fluid movement occurred before any change in temperature reached the dentinoenamel junction. More investigation is needed, however, to verify their results.

Application of cold decreases the blood flow because of its vasoconstrictive effect on the blood vessels. If this application is continued, anoxia results and the A fibres cease to function. With continuous application of heat, the C fibres are affected: vasodilation temporarily increases intrapulpal pressure and causes intense pain.<sup>10</sup>

Hypertonic solutions activate the intradental nerves through osmotic pressure,<sup>16,19,25,26</sup> manifested clinically by the pain that results when saturated sucrose solutions come into constant contact with sensitive dentin. The patent dentinal tubules are an important factor in the induction of pain in sensitive dentin. This sensitivity is a direct response to the stimulation of the A fibres. Another example is the use of an etchant on the dentinal surface. The osmotic pressure of the acid used for etching the dentin is as important as the acid's chemical composition in the induction of pain because this osmotic pressure causes the outward fluid flow in the tubules, together with aspiration of the odontoblastic nucleus.<sup>26-28</sup> The ionic concentration of the material also affects the reduction of pain in sensitive dentin. A normally irritant substance such as potassium chloride temporarily relieves pain because the high concentration of potassium temporarily blocks the conduction of nerve impulses, causing a hyperpolarization that decreases the excitability of the nerve fibres. This hyperpolarization is the basis for the addition of potassium ions to dentifrices.

In addition to pain from sensitive or exposed dentinal tubules, persistent pain may decrease the threshold of the nociceptors, usually during pulpal inflammation in which the A and C fibres respond differently.<sup>15,16</sup> This explains the varying degrees of pain in pulpitis. These nociceptors, when stimulated, may induce pulpal inflammation by producing neuropeptides such as CGRP and substance P. These molecules, when released inside the pulp, begin the inflammatory reaction by dilating the blood vessels and increasing their permeability, thus inducing the release of histamine, which results in neurogenic inflammation.<sup>30</sup>

Injury sensitizes the intradental nerves. This sensitivity is mediated by prostaglandins, as indicated by the lack of symptoms after anti-inflammatory drugs are administered.<sup>31</sup> Serotonin sensitizes the A fibres,<sup>16,32</sup> whereas histamine and bradykinin activate the C fibres of the pulp.<sup>15,16</sup> The response of the A and C fibres to different inflammatory mediators is regulated by the pulpal blood flow.<sup>33,34</sup>

The location of the C fibres within the nerve bundles in the core or central region of the pulp may explain the diffuse pain, called *referred pain*, from a specific tooth because nerve fibres innervate multiple teeth with multiple pulps.<sup>35</sup> These fibres have less excitability than the A fibres

and a higher threshold, so they need more intense stimuli to be activated. The C fibres may survive in the presence of hypoxia,<sup>33,36</sup> which may explain pain sensed during preparation for the root canal of a necrotic pulp.<sup>37</sup> The dentist should tell the patient that the pain will not be completely resolved after the dental visit, and that this pain may be caused by deafferentiation, or the interruption of the afferent input into the central nervous system.<sup>38</sup>

All functional changes to the nociceptors are reversible on removal of the cause. For example, in the case of dentin hypersensitivity, the tubules are treated by blocking, which directly affects the A fibres (hydrodynamic cessation) and resolves the neural changes in the pulp, causing the pain to subside.<sup>39</sup>

In contrast to these morphologic and functional changes in pulpal nerve endings, the pulp, through its defensive mechanism, responds by secreting endogenous opioids, noradrenalin, somatostatin and specific chemical mediators in response to the toxins secreted by carious lesions to regulate the activity of nociceptors.<sup>6,40,41</sup> Some of these mediators are excitatory; others, such as morphine, have an inhibitory effect. The neuroinflammatory and the neuropulpal interactions (nerve-odontoblast interactions) still need to be clarified.<sup>35</sup>

Based on this discussion of fibres and their responses, we can relate the type of fibres to clinical pulp testing methods:

- Thermal pulp testing depends on the outward and inward movement of the dentinal fluid, whereas electric pulp testing depends on ionic movement.<sup>10</sup>
- Because of their distribution, larger diameter than that of C fibres, their conduction speed and their myelin sheath, A-delta fibres are those stimulated in electric pulp testing.<sup>10,36</sup>
- C fibres do not respond to electric pulp testing. Because of their high threshold, a stronger electric current is needed to stimulate them.<sup>36</sup>
- Based on the hydrodynamic effect, outward movement of dentinal fluid caused by the application of cold (contraction of fluid) produces a stronger response in A-delta fibres than inward movement of the fluid caused by the application of heat.<sup>16,42,43</sup>
- Repeated application of cold will reduce the displacement rate of the fluids inside the dentinal tubules, causing a less painful response from the pulp for a short time, which is why the cold test is sometimes refractory.<sup>10</sup>
- The A-delta fibres are more affected by the reduction of pulpal blood flow than the C fibres because the A-delta fibres cannot function in case of anoxia.<sup>33,34</sup>
- An uncontrolled heat test can injure the pulp and release mediators that affect the C fibres.<sup>44,45</sup>
- A positive percussion test indicates that the inflammation has moved from the pulp to the periodontium, which is rich in proprioceptors, causing this type of localized response.

## Conclusions

The dental clinician should not rely solely on the type of pain to determine a diagnosis. Other nonodontogenic types of pain, as well as psychological pain, may obfuscate the correct diagnosis. Type of pain has not been correlated with the histopathologic condition of the pulp.<sup>46,47</sup> The A and C fibres are activated by different stimuli and different inflammatory mediators, producing changes in the quality of pain that range from a sharp shooting pain to a dull and prolonged pain. Mechanical stimulation such as probing causes a sharp pain by stimulating the A-delta fibres, whereas prolonged pain manifests after the removal of a thermal stimulus (mainly heat) activates the C fibres. The stimulus itself may indicate the type of pain, but does not indicate the changes occurring in the pulp tissue or the stage of inflammation occurring. ✦

## THE AUTHORS



**Dr. Abd-Elmequid** is a PhD student, medical sciences and dentistry, department of dentistry, University of Alberta, Edmonton, Alberta.



**Dr. Yu** is a clinical professor and head of the endodontic division, department of dentistry, University of Alberta, Edmonton, Alberta.

**Correspondence to:** Dr. Donald Yu, Room 4021, Dentistry/Pharmacy Centre, Department of dentistry, University of Alberta, Edmonton, AB T6G 2N8.

The authors have no declared financial interests.

This article has been peer reviewed.

## References

- Hill CM. The efficacy of transillumination in vitality tests. *Int Endod J* 1986; 19(4):198–201.
- Tronstad L. Root resorption—etiology, terminology and clinical manifestations. *Endod Dent Traumatol* 1988; 4(6):241–52.
- Petersson K, Soderstrom C, Kiani-Anaraki M, Levy G. Evaluation of the ability of thermal and electrical tests to register pulp vitality. *Endod Dent Traumatol* 1999; 15(3):127–31.
- Lipton JA, Ship JA, Larach-Robinson D. Estimated prevalence and distribution of reported orofacial pain in the United States. *J Am Dent Assoc* 1993; 124(10):115–21.
- Byers MR. Dental sensory receptors. *Int Rev Neurobiol* 1984; 25:39–94.
- Byers MR, Narhi MV. Dental injury models: experimental tools for understanding neuroinflammatory interactions and polymodal nociceptor functions. *Crit Rev Oral Biol Med* 1999; 10(1):4–39.
- Bergenholtz G, Hörsted-Bindslev P, Reit C. Textbook of endodontology. Oxford, UK: Blackwell Munksgaard; 2003.
- Johnsen DC, Harshbarger J, Rymer HD. Quantitative assessment of neural development in human premolars. *Anat Rec* 1983; 205(4):421–9.
- Nanci A, Ten Cate AR. Ten Cate's oral histology: development, structure, and function. 6th ed. St. Louis: Mosby; 2003.
- Bender IB. Pulpal pain diagnosis—a review. *J Endod* 2000; 26 (3):175–9.
- Byers MR, Dong WK. Autoradiographic location of sensory nerve endings in dentin of monkey teeth. *Anat Rec* 1983; 205(4):441–54.
- Johnsen D, Johns S. Quantitation of nerve fibres in the primary and permanent canine and incisor teeth in man. *Arch Oral Biol* 1978; 23(9):825–9.
- Braennstroem M, Astroem A. A study on the mechanism of pain elicited from the dentin. *J Dent Res* 1964; 43:619–25.
- Andrew D, Matthews B. Displacement of the contents of dentinal tubules and sensory transduction in intradental nerves of the cat. *J Physiol* 2000; 529 Pt 3:791–802.
- Narhi MV. Dentin sensitivity: a review. *J Biol Buccale* 1985; 13(2):75–96.
- Narhi M, Jyvasjarvi E, Virtanen A, Huopaniemi T, Ngassapa D, Hirvonen T. Role of intradental A- and C-type nerve fibres in dental pain mechanisms. *Proc Finn Dent Soc* 1992; 88 Suppl 1:507–16.
- Matthews B, Vongsavan N. Interactions between neural and hydrodynamic mechanisms in dentine and pulp. *Arch Oral Biol* 1994; 39 Suppl:875–955.
- Pashley DH. Mechanisms of dentin sensitivity. *Dent Clin North Am* 1990; 34(3):449–73.
- Vongsavan N, Matthews B. The relationship between the discharge of interdental nerves and the rate of fluid flow through dentine in the cat. *Arch Oral Biol* 2007; 52(7):640–7. Epub 2007 Feb 15.
- Trowbridge HO. Pulp biology: progress during the past 25 years. *Aust Endod J* 2003; 29(1):5–12.
- Trowbridge HO. Intradental sensory units: physiological and clinical aspects. *J Endod* 1985; 11(11):489–98.
- Trowbridge HO, Franks M, Korostoff E, Emling R. Sensory response to thermal stimulation in human teeth. *J Endod* 1980; 6(1):405–12.
- Narhi M, Jyvasjarvi E, Hirvonen T, Huopaniemi T. Activation of heat-sensitive nerve fibres in the dental pulp of the cat. *Pain* 1982; 14(4):317–26.
- Linsuwanont P, Versluis A, Palamara JE, Messer HH. Thermal stimulation causes tooth deformation: a possible alternative to the hydrodynamic theory? *Arch Oral Biol* 2008; 53(3):261–72.
- Pashley DH. Sensitivity of dentin to chemical stimuli. *Endod Dent Traumatol* 1986; 2(4):130–7.
- Anderson DJ, Matthews B, Shelton LE. Variations in the sensitivity to osmotic stimulation of human dentine. *Arch Oral Biol* 1967; 12(1):43–7.
- Narhi M, Kontturi-Narhi V, Hirvonen T, Ngassapa D. Neurophysiological mechanisms of dentin hypersensitivity. *Proc Finn Dent Soc* 1992; 88 Suppl 1:15–22.
- Narhi MV, Hirvonen T. The response of dog intradental nerves to hypertonic solutions of CaCl<sub>2</sub> and NaCl, and other stimuli, applied to exposed dentine. *Arch Oral Biol* 1987; 32(11):781–6.
- Ajcharanukul O, Kraivaphan P, Wanachantararak S, Vongsavan N, Matthews B. Effects of potassium ions on dentine sensitivity in man. *Arch Oral Biol* 2007; 52(7):632–9.
- Olgart L. Neural control of pulpal blood flow. *Crit Rev Oral Biol Med* 1996; 7(2):159–71.
- Ahlberg KF. Dose-dependent inhibition of sensory nerve activity in the feline dental pulp by anti-inflammatory drugs. *Acta Physiol Scand* 1978; 102(4):434–40.
- Olgart L, Haegerstam G, Edwall L. The effect of extracellular calcium on thermal excitability of the sensory units in the tooth of the cat. *Acta Physiol Scand* 1974; 91(1):116–22.
- Torebjork HE, Hallin RG. Perceptual changes accompanying controlled preferential blocking of A and C fibre responses in intact human skin nerves. *Exp Brain Res* 1973; 16(3):321–32.
- Edwall L, Kindlova M. The effect of sympathetic nerve stimulation on the rate of disappearance of tracers from various oral tissues. *Acta Odontol Scand* 1971; 29(4):387–400.
- Hargreaves KM, Goodis HE, Seltzer S. Seltzer and Bender's dental pulp. Chicago: Quintessence Pub. Co. Inc; June 2002.
- Narhi M, Virtanen A, Kuhta J, Huopaniemi T. Electrical stimulation of teeth with a pulp tester in the cat. *Scand J Dent Res* 1979; 87(1):32–8.
- Mullaney TP, Howell RM, Petrich JD. Resistance of nerve fibres to pulpal necrosis. *Oral Surg Oral Med Oral Pathol* 1970; 30(5):690–3.
- Cohen S, Hargreaves KM. Pathways of the pulp. 9th ed. Mosby; 2006.
- Byers MR. Effects of inflammation on dental sensory nerves and vice versa. *Proc Finn Dent Soc* 1992; 88 Suppl 1:499–506.
- Stein C. Peripheral mechanisms of opioid analgesia. *Anesth Analg* 1993; 76(1):182–91.
- Olgart LM. The role of local factors in dentin and pulp in intradental pain mechanisms. *J Dent Res* 1985; 64 Spec No:572–8.
- Ngassapa D, Narhi M, Hirvonen T. Effect of serotonin (5-HT) and calcitonin gene-related peptide (CGRP) on the function of intradental nerves in the dog. *Proc Finn Dent Soc* 1992; 88 Suppl 1:143–8.

43. Charoenlarp P, Wanachantararak S, Vongsavan N, Matthews B. Pain and the rate of dentinal fluid flow produced by hydrostatic pressure stimulation of exposed dentine in man. *Arch Oral Biol* 2007; 52(7):625–31.
44. Narhi M. Activation of dental pulp nerves of the cat and the dog with hydrostatic pressure. *Proc Finn Dent Soc* 1978; 74 Suppl 5-7:1–63.
45. Narhi M, Yamamoto H, Ngassapa D, Hirvonen T. The neurophysiological basis and the role of inflammatory reactions in dentine hypersensitivity. *Arch Oral Biol* 1994; 39 Suppl:23S–30S.
46. Seltzer S, Bender IB, Ziontz M. The dynamics of pulp inflammation: correlations between diagnostic data and actual histologic findings in the pulp. *Oral Surg Oral Med Oral Pathol* 1963; 16:969–77.
47. Baume LJ. Diagnosis of diseases of the pulp. *Oral Surg Oral Med Oral Pathol* 1970; 29(1):102–16.