

Juvenile Idiopathic Arthritis: A Chronic Pediatric Musculoskeletal Condition with Significant Orofacial Manifestations

Torin Barr, BSc, DDS; Nicole M. Carmichael, PhD;
George K.B. Sándor, MD, DDS, PhD, FRCD(C), FRCSC, FACS

Auteur-ressource

Dr Sándor
Courriel : george.sandor@utoronto.ca



SOMMAIRE

«Arthrite idiopathique juvénile» (AIJ) est une expression générale, utilisée pour décrire un groupe cliniquement hétérogène d'arthrites de cause inconnue se manifestant avant l'âge de 16 ans. Bien que l'AIJ se caractérise principalement par une inflammation chronique des articulations, cette expression englobe plusieurs catégories de maladies. L'étiologie de l'AIJ demeure mal comprise, et aucun des médicaments actuellement disponibles ne peut guérir la maladie. Le pronostic s'est toutefois grandement amélioré grâce aux progrès réalisés dans la classification et la prise en charge de la maladie. Les dentistes devraient se familiariser avec les symptômes et les manifestations buccales de l'AIJ pour aider à son traitement.

Pour les citations, la version définitive de cet article est la version électronique : www.cda-adc.ca/jcda/vol-74/issue-9/813.html

Juvenile idiopathic arthritis (JIA) is the most common chronic rheumatic disease of childhood and an important cause of short- and long-term disability.¹ Patients with JIA experience a myriad of symptoms, including lethargy, reduced physical activity, poor appetite and flu-like symptoms. Although the initial manifestation of JIA is variable, the cardinal clinical features include persistent swelling of one or more joints, limited range of motion in the joints and pain during movement lasting at least 6 weeks. The age at onset of JIA is under 16 years of age.¹ In the worst expression of JIA in the face, these patients may exhibit severe retrognathia, open bite, microgenia and “bird-like” facies (Figs. 1a and 1b).

Like other forms of arthritis, JIA is characterized by inflammation of the synovium of one or more joints. However, the term JIA has

replaced previous terms such as *juvenile chronic arthritis* or *juvenile rheumatoid arthritis* to more accurately identify homogenous groups of children with distinct clinical features. The International League of Associations for Rheumatology (ILAR), which has provided the most recent classification, identifies 7 subtypes of JIA with specific exclusion and inclusion criteria² (Tables 1 and 2). Females are much more frequently affected with almost all types of JIA than males.^{1,3,4} The worldwide prevalence of JIA varies between 16 and 150 per 100,000; the frequency of different subtypes of JIA vary with location and ethnicity.

Pathogenesis

Inflammation of the synovium is a key pathological feature of JIA. However, the exact trigger and factors that allow the inflammation

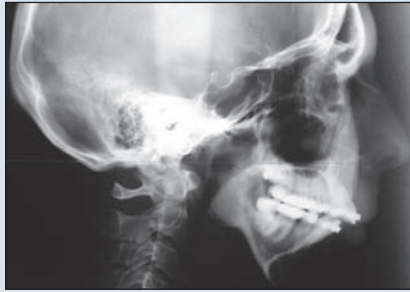

Figure 1a: Lateral cephalogram showing that severe juvenile idiopathic arthritis (JIA) can result in striking facial deformities with “bird-like” facies due to severe retrognathia and loss of posterior vertical dimension from condylar resorption.

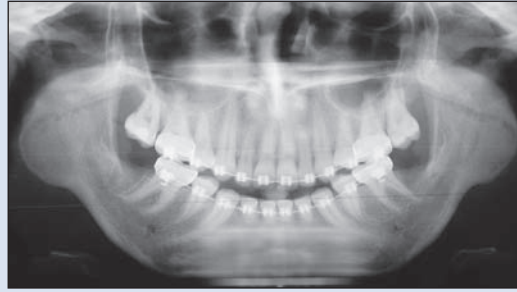

Figure 1b: Panoramic radiograph showing severe condylar resorption and accentuated bilateral antegonial notching.

Table 1 ILAR classification, inclusion and exclusion criteria, frequency and sex distribution of JIA^a

Classification	Inclusion criteria	Exclusion criteria	Frequency (%)	Sex ratio
Systemic arthritis	Onset age: throughout childhood Number of joints affected: variable Systemic features: quotidian fever + ≥ 1 of the following: erythematous rash, myalgias, lymphadenopathy, hepatosplenomegaly or serositis.	N/A	4–17	F = M
Oligoarthritis	Onset age: early childhood, peak 2–4 years Number of joints affected: persistent: ≤ 4; extended: ≥ 4 joints after the first 6 months	Psoriasis/family history HLA B27 RF-positive Males > 6 years	27–56	Three times greater in F than M
RF-positive polyarthritis	Onset age: late childhood, adolescence Number of joints affected: ≥ 5 joints Serological test: IgM RF-positive	IgM RF-negative	2–7	Twice as great in F than M
RF-negative polyarthritis	Onset age: biphasic distribution, early peak 2–4 years, later peak 6–12 years Number of joints affected: ≥ 5 joints Serological test: IgM RF-negative	IgM RF-positive	11–28	Twice as great in F than M
Enthesitis-related arthritis	Onset age: late childhood or adolescence Number of joints affected: variable, usually ≤ 4 Other diagnoses: enthesitis	N/A	3–11	Twice as great in F than M
Psoriatic arthritis	Onset age: biphasic distribution, early peak at 2–4 years, late peak at 9–11 years Number of joints affected: variable, usually ≤ 4 Other diagnoses: psoriatic rash, family history of psoriasis, dactylitis or nail pitting	N/A	2–11	Greater in F than M
Undifferentiated arthritis	Onset age: N/A Patients who do not satisfy inclusion criteria for any other category	N/A	11–21	No known sex predilection

ILAR = International League of Associations for Rheumatology; JIA = juvenile idiopathic arthritis; N/A = not applicable; F = female; M = male; HLA = human histocompatibility leukocyte antigen; RF = rheumatoid factor.

^aA child is diagnosed with a specific subtype of juvenile idiopathic arthritis if he or she falls into one of the categories listed here. Adapted from Ravelli and Martini.⁴

Table 2 Common clinical and laboratory features that are not included in the official ILAR classification or inclusion criteria, but are frequently observed in different subtypes of JIA

Classification	Serological findings	Other clinical manifestations
Systemic arthritis	High levels of ESR, CRP, IL-6	Leucocytosis Neutrophilia Thrombocytosis Anemia Macrophage activation syndrome
Oligoarthritis	ANA usually positive High levels of APR proteins and ISR proteins	Iridocyclitis
RF-positive polyarthritis	Rheumatoid factor-positive	Rheumatoid nodules and, rarely, aortic regurgitation
RF-negative polyarthritis	ANA-positive High ESR levels	Iridocyclitis
Enthesitis-related arthritis	HLA-B27 positive	Possibly leading to ankylosing spondylitis
Psoriatic arthritis	ANA-positive	Iridocyclitis
Undifferentiated arthritis	—	—

ILAR = International League of Associations for Rheumatology; JIA = juvenile idiopathic arthritis; ESR = erythrocyte sedimentation rate; CRP = C-reactive protein; ANA = antinuclear antibody; APR = acute phase reactant proteins; ISR = intermediate stage reactant proteins; RF = rheumatoid factor; HLA = human histocompatibility leukocyte antigen; — = data unavailable.

to become chronic are not clearly understood. The prevailing view is that both inherited and environmental factors are important and that an autoimmune reaction precipitates a cascade of inflammatory changes.⁴ Once an immune response is initiated and inflammation in the joint is triggered, B lymphocytes produce immunoglobulins; in some subsets of JIA, rheumatoid factors of the IgG and IgM classes are deposited in the sublining layer of the synovium. This response subsequently activates the serum complement cascade and recruits the phagocytic arm of the immune response, which further exacerbates the inflammation of the synovium, leading to edema, vasodilation and infiltration of activated T cells.^{5,6}

Early and intermediate molecular mediators of inflammation have been identified in the synovium of some patients with JIA and include tumour necrosis factor alpha; interleukins IL-1, IL-6, IL-8 and IL-15; transforming growth-factor beta; fibroblast growth factor; and platelet-derived growth factor^{7,8} — all of which contribute to the breakdown of collagen and the proteoglycan matrix of articular cartilage. Once the inflammation is established, the synovium thickens, the cartilage and the underlying bone begins to disintegrate, and evidence of joint destruction occurs.⁹⁻¹¹

Genetic factors and specific gene loci are important in the pathogenesis of JIA.¹² Several genes, including at least 1 gene in the human histocompatibility leukocyte antigen (HLA) region, affects susceptibility to JIA. However, different subsets of JIA are associated with different HLA and

non-HLA regions, which likely accounts for the heterogeneity of the disease. In predisposed children, environmental triggers, such as exposure to sunlight or cigarette smoke, drugs or infection may precipitate the development of JIA.⁴

Clinical Presentation

The diagnosis of JIA, according to the ILAR classification, requires specific clinical features, including distinct methods of presentation such as systemic, polyarticular involving many joints, oligoarticular involving 4 or fewer joints, the age of onset and the results of serological testing.⁴ **Table 1** outlines the ILAR's diagnostic criteria for each subtype of JIA.

Differential Diagnosis

Several diseases mimic the initial course of JIA, thus making its differentiation from other conditions difficult. Differential diagnosis of systemic JIA includes infection, malignancy, rheumatic fever, connective-tissue diseases, inflammatory bowel disease, Castleman's disease and autoinflammatory syndromes⁴ (**Table 3**).

Treatment

Management of JIA is based on a combination of pharmacological interventions (**Table 4**), physical and occupational therapy, and psychosocial support.¹²⁻¹⁴ The aim of the treatment is to control the disease, and prevent further progression and any long-term effects related to the disease or treatment.

Table 3 Common differential diagnoses of systemic JIA

Infection
Septicemia
Bacterial endocarditis
Brucellosis
Typhoid fever
Leishmaniasis
Viral infections
Malignancy
Leukemia
Lymphoma
Neuroblastoma
Rheumatic fever
Connective tissue disease
Systemic lupus erythematosus
Kawasaki syndrome
Polyarthritis
Inflammatory bowel disease
Castleman's disease
Autoinflammatory syndromes

JIA = juvenile idiopathic arthritis.

Nonsteroidal anti-inflammatory drugs (NSAIDs) have been the mainstay of the treatment of this disease for decades. Most children with JIA are started on NSAIDs; however, only a few NSAIDs are approved for use with children. The most common include naproxen, ibuprofen and indomethacin. They are generally well tolerated and have few side effects.⁴

Intra-articular steroid injections with triamcinolone hexacetonide are frequently needed at the onset and during the course of the disease. For monoarticular or oligoarticular arthritis, they may be used with or without NSAIDs. These steroids are effective rapidly and help prevent deformities.⁴

Patients whose disease is not well controlled by these approaches or by physical therapy are candidates for more aggressive interventions. Moderate- or high-dose systemic corticosteroid therapy is reserved for patients with systemic JIA whose disease is not controlled by NSAIDs. Corticosteroids are used very selectively because of their potential toxic effects (**Box 1**), including growth arrest and retardation, and osteopenia.⁴ Bisphosphonates may be given to these children to try to combat the osteopenic effects of chronic treatment with systemic corticosteroids.¹⁵

Methotrexate has become the second line treatment of choice for persistent active arthritis because of its effectiveness and acceptable toxic effects.^{16,17} Improvements are usually seen after 6 to 12 weeks, and supplementation with folic acid can help prevent the occurrence of liver-enzyme abnormalities that can occur as a result of methotrexate treatment.^{18,19} The use of methotrexate in pediatric rheumatology practice is very different from the treatment regimens

Table 4 Pharmacological treatments used in patients with JIA

Nonsteroidal anti-inflammatory drugs
Naproxen
Ibuprofen
Indometacin
Intra-articular steroids
Triamcinolone hexacetonide
Systemic steroids
Prednisone
Methotrexate
Etanercept
Anti-IL-1 or anti-IL-6 drugs

JIA = juvenile idiopathic arthritis.

Box 1 Side effects of long-term corticosteroid intake^{10,11}

- Compromised immunity
- Atherosclerosis
- Hypercholesterolemia
- Hyperglycemia
- Cushingoid appearance
- Acne
- Cataracts
- Avascular necrosis of the hip
- Severe osteoporosis
- Pharmacologically induced adrenal insufficiency

of other specialties such as oncology. Doses are smaller in pediatric rheumatology, but regimens are longer-term. As a result, oral ulceration, mucositis and bone-marrow suppression are rare, and the risk of opportunistic infection is lower for patients with JIA than for oncology patients.

The introduction of biological medications has also provided an important new therapeutic option for the treatment of patients with JIA who are resistant to antirheumatic agents. Etanercept (0.4 mg/kg, given subcutaneously twice weekly) is very effective for patients who have polyarticular disease and are resistant or intolerant to methotrexate.²⁰ Etanercept is generally well tolerated, but patients should be monitored for potential side effects related to its long-term use.²¹⁻²⁴ For those patients with systemic arthritis who are unresponsive to NSAIDs, methotrexate or etanercept, or a combination of anti-interleukin-1,6 therapies have been very successful in recent clinical trials.²¹

These children, who may be taking combinations of potent immunosuppressives, including methotrexate, biologics and steroids, are at constant risk of potential infection and bacteremia.²² Systemic features of sepsis may be altered by the immunosuppression, especially by the biologics. A child with well-controlled JIA whose condition flares up for no

Box 2 Orofacial findings for JIA

- Temporomandibular joint: limited opening with progressive open bite
- Effect on mandibular growth: retrognathia
- Effect on upper limb function with swollen joints in the hands: difficulty with fine-motor movements required for tooth brushing and flossing
- Medications:
 - oral medications associated with increased caries risk because of sugar content of elixir formulations
 - methotrexate possibly resulting in stomatitis or oral ulceration
 - cyclosporine, although infrequently used, possibly causing gingival hyperplasia, blood dyscrasia, renal impairment and hypertension
- Salivary abnormalities: lower levels of Ca⁺⁺, PO₄, K⁺, lysozyme and IgA than those of healthy controls

JIA = juvenile idiopathic arthritis.

apparent reason may well have occult dental sepsis, including abscess.

Physiotherapy and occupational therapy are important components of the therapeutic approach to any patient with JIA. Arthroscopic synovectomy or soft-tissue release can be helpful in select cases. Total arthroplasty of the hip and knee, a successful option if the patient is severely functionally impaired, is usually delayed until growth has stopped.⁴

Prognosis and Outcome

Many of the reports of poor outcome and disability reflect the treatment of decades ago. Current changes in the management of JIA, such as early and aggressive use of methotrexate and other immunosuppressives, result in improved outcomes. For many children, the expectation is complete remission, although patients may have several years of complex potent immunosuppressive treatments.

Systemic JIA has the most variable course.^{25–29} In 50% of patients, systemic symptoms resolve and the patient develops chronic arthritis as the major long-term complaint. Chronic arthritis in children has a negative effect on bone and joint development.^{25,26} Local growth disturbances take place at the sites of inflammation and result in either overgrowth, possibly related to inflammation-induced increased vascularization and growth-factor release; or undergrowth, secondary to growth-centre damage or premature fusion of epiphyseal plates of the juxta-articular bone extremities. Anomalies in the growth and morphogenesis of skeletal segments also result from irregular traction on growing structures.^{4,5} Micrognathia, unequal leg length and developmental anomalies of the hip are examples of possible results of these processes.^{30,31} In

severe cases of systemic JIA, the disease and its treatment with steroids can cause severe growth retardation and osteoporosis.^{32–34} As a consequence, these patients may also receive bisphosphonate therapy to prevent steroid-induced osteoporosis.

Oral Manifestations of JIA

Patients with JIA may have a variety of dentofacial complications related to the disease or disease treatment (**Box 2**). The possible dentofacial manifestations of JIA have been grouped into oral and dentoskeletal findings.

Oral manifestations associated with JIA include increased dental caries, poor oral hygiene and malocclusion. Patients with JIA have a higher caries index, and more decayed, filled and missing teeth than age-matched groups,^{35,36} as well as increased frequency of decayed teeth in all major age groups. Oral hygiene is poor across all age groups.³⁵ Poor oral hygiene may be a result of upper-limb involvement, which may affect the patient's ability to do the fine-motor movements required for efficient tooth brushing and flossing.

A second factor affecting the increased incidence of caries may be the medications patients use to control inflammation. The primary medical treatments involve the use of NSAIDs and disease-modifying antirheumatic drugs (DMARDs). Use of NSAIDs, which is advocated as a first-line therapy, results in improvement in 50% of patients within 2 weeks and in the remainder within 8 weeks.^{1,2} Given the young age of many of these patients, pill or tablet formulations are often not well tolerated. As a result, practitioners use elixir forms, a large percentage (59%–65%) of which are sugar-based.³⁷ The repeated exposure to a high dose of sugars, combined with a limited ability to attain proper oral hygiene, contributes to the overall increased incidence of caries seen in this patient group. Some sugar-free forms of medication are available and should be recommended to the patients' physicians when possible.

DMARDs, the second line of treatment, are safe and effective alternatives to NSAIDs. The most popular agent is methotrexate. It seems to cause fewer side effects in children than in adults and is effective for 60% to 70% of patients.⁴ The once weekly dosing regimen makes it especially appealing for pediatric patients because noncompliance is less of an issue. However, methotrexate is not without side effects: it may result in painful stomatitis and oral ulcerations in some patients, which may be minimized with folic-acid supplementation. Cyclosporine, infrequently used for treatment of JIA, is limited by its significant side effects, including hirsutism and gingival hyperplasia.

Patients with JIA who have decreased levels of Ca⁺⁺, PO₄, K⁺, lysozyme and IgA have more salivary abnormalities than healthy controls.³⁵ Patients with JIA often have malocclusion because of the effects of the disease on the temporomandibular joint (TMJ) and facial growth. These patients often have Class II molar and canine relationships, and many also have an anterior open bite because of the

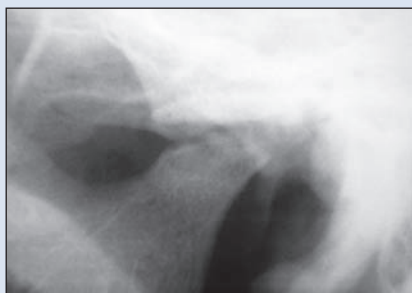


Figure 2a: Close-up of a panoramic radiograph shows the variable pattern of condylar appearances here with flattening and irregular resorption of the condylar head.

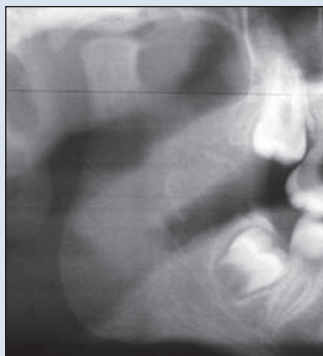


Figure 2b: In this close-up of a panoramic radiograph, resorption has left a condylar head that resembles a mushroom.

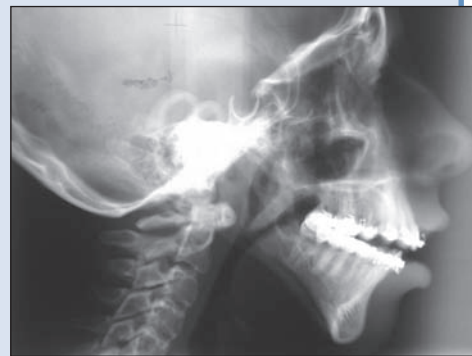

Figure 3a: Lateral cephalogram of a more representative case of JIA showing retrognathia, anterior open bite and lip incompetence.

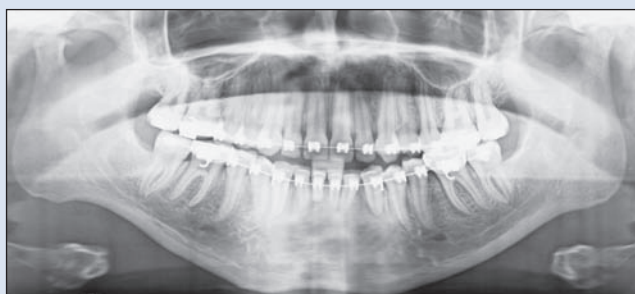

Figure 3b: Panoramic radiograph of patient in Fig. 3a with bilateral condylar resorption.

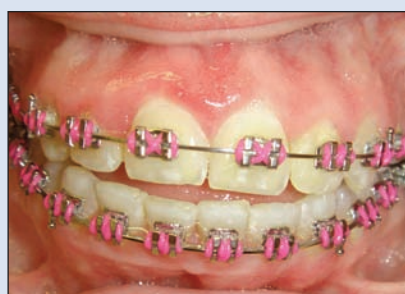

Figure 3c: Frontal view of malocclusion with anterior open bite.

progressive loss of the posterior vertical dimension from progressive condylar resorption (Figs. 2a and 2b).

Dentofacial Consequences of JIA

The dentofacial consequences of JIA are based on changes within the structures of the TMJ and their resultant effects on mandibular growth (Figs. 1a to 2b). Reports of TMJ involvement in JIA range from 17% to 87%.³⁸ About 45% of cases may be diagnosed from radiographic changes on an orthopantomogram.^{38,39} The incidence of TMJ joint involvement is variable, depending on the age of the study, the source of the patients and the methods used to define the involvement. TMJ involvement is not uncommon, and though it is often identified with ultrasound and MRI, it may be subclinical. Micrognathia and retrognathia, which are less common because of their current management with methotrexate and biologicals, usually manifest in children with severe refractory disease or those who received pediatric rheumatology care late in the course of their disease.⁴⁰ Such radiographic changes, if present, include shortening of the mandibular body and ramus, flattening of the condyles and increased antegonial notching³⁸ (Figs. 3a to 3c).

As with their other joints, patients with JIA and involvement of the TMJ may complain of morning stiffness of the joint, along with trismus, reduced interincisal opening, reduced ability to translate and possible clicking or crepitation.³⁹ Pathologic changes within the condylar head are thought to adversely affect the growth potential of the region, which results in the characteristic changes associated with JIA.

Patients with JIA typically present with posterior or downwards mandibular rotation, a steep mandibular plane and mandibular retrognathia.^{36-39,41,42} Associated with the mandibular changes are an increased vertical growth of the anterior face and possible anterior open bite.⁴³ As a result, in the most severe cases, some authors described these patients as having a “bird-face” deformity (Figs. 1a and 1b).¹ The frequency and severity of facial changes are correlated with the JIA type; polyarticular forms have the greatest impact on facial growth and the final form of the face.^{38,42,44} These patients often require even more complex surgical management (Figs. 4a to 4e).

Sedation and general anesthesia must be administered to these patients with caution because some may have neck

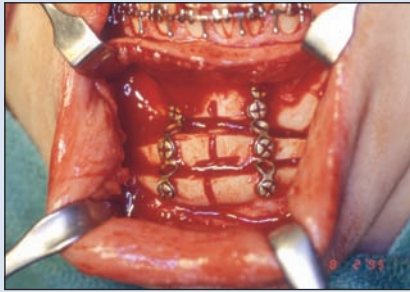


Figure 4a: Intraoperative photograph showing a stairstep genioplasty which maximizes the effects of mandibular advancement in patients with severe microgenia.

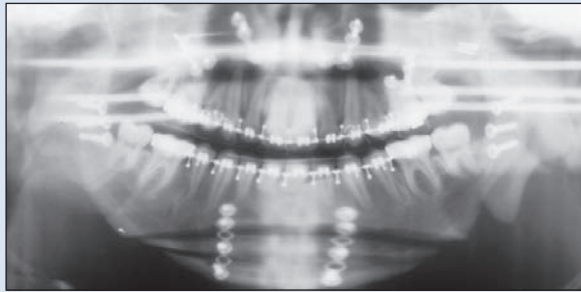


Figure 4b: Immediate postoperative panoramic radiograph of the patient in Fig. 4a who underwent a maxillary LeFort I level intrusion osteotomy, a bilateral sagittal split osteotomy to advance the mandible and a stairstep genioplasty.

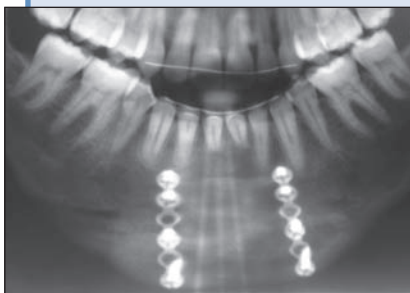


Figure 4c: Panoramic radiograph taken 12 years after the stairstep genioplasty.

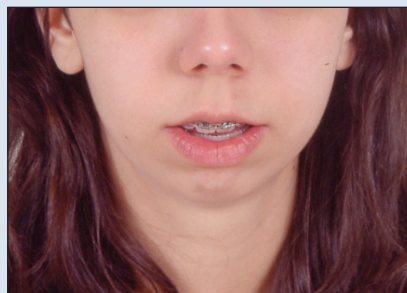


Figure 4d: Preoperative frontal photograph of the patient from Fig. 4a who had JIA, severe retrognathia, open bite, microgenia and lip incompetence.

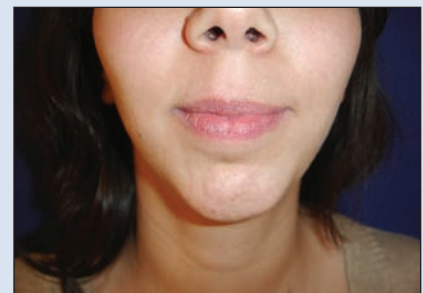


Figure 4e: Postoperative frontal photograph taken 12 years after stairstep genioplasty with lip competence at rest.

involvement and cervical-spine instability. The cervical spine must therefore be assessed in the workup of these patients.

Dental Management of JIA Patients

Dental management of patients with JIA is based on prevention of dental disease. Regular dental checkups that include extensive instruction about oral hygiene play an important role. For patients with upper-limb involvement, electric toothbrushes are recommended to help promote better debridement. Fluoride treatments, dietary changes and sealants should be used as needed. Sugar-free formulations of patient medications should be used whenever possible. Opening exercises to ensure adequate range of motion of the TMJ have also been suggested.³⁶ Orthodontic appliances, applied during the prepubertal growth spurt may help minimize changes in occlusion and aid mandibular growth.³⁶ The role of the dentist in optimizing the dental care of these unique patients and in increasing pediatricians' and pediatric specialists' awareness about their oral health cannot be overstressed.

Orthodontic treatment may help manage these patients' malocclusions, up to a point. In those cases of JIA in which

the facial deformity is severe, orthognathic surgery may be considered. However, jaw surgery is not advocated until the systemic aspects of the disease have been fully controlled. These patients have a high potential for skeletal relapse. Orthognathic surgery should be undertaken only once the TMJ and occlusal findings have stabilized. The interincisal opening can be measured serially at recall visits over time. The continued progressive worsening of an open bite in patients with JIA is a contraindication to orthognathic surgery, especially if the condyles are actively undergoing a lytic phase. The risk for these patients is similar to the risks that patients with idiopathic condylar resorption face when they have orthognathic surgery.

Conclusions

Patients with JIA face long-term, if not lifelong, consequences of their disease that may involve more than their musculoskeletal system. They may also have significant dental morbidity, which is preventable. These patients require close supervision to guard against dental caries. They frequently require orthodontic intervention and, in selected cases, may eventually benefit from orthognathic surgery. ♦

THE AUTHORS



Dr. Barr is senior resident in the division of oral and maxillofacial surgery and anesthesia, University of Toronto, Toronto, Ontario.



Dr. Carmichael is research fellow in the department of anesthesia, Sunnybrook Health Sciences Centre, University of Toronto, Toronto, Ontario.



Dr. Sándor is professor and head of oral and maxillofacial surgery, University of Toronto, Toronto, Ontario; coordinator, pediatric oral and maxillofacial surgery, The Hospital for Sick Children and Bloorview Kid's Rehab, Toronto; professor, Rega Institute for Regenerative Medicine, University of Tampere, Tampere, Finland; and docent in oral and maxillofacial surgery, University of Oulu, Oulu, Finland.

Correspondence to: Professor George K.B. Sándor, The Hospital for Sick Children, S-525, 555 University Avenue, Toronto, ON M5G 1X8.

The authors have no declared financial interests.

This article has been peer reviewed.

References

- Jordan A, McDonagh JE. Juvenile idiopathic arthritis: the paediatric perspective. *Pediatr Radiol* 2006; 36(8):734–42. Epub 2006 May 4.
- Hashkes PJ, Laxer RM. Medical treatment of juvenile idiopathic arthritis. *JAMA* 2005; 294(13):1671–84.
- Johnson K, Gardner-Medwin J. Childhood arthritis: classification and radiology. *Clin Radiol* 2002; 57(1):47–58.
- Ravelli A, Martini A. Juvenile idiopathic arthritis. *Lancet* 2007; 369(9563):767–78.
- Murray KJ, Luyrink L, Grom AA, Passo MH, Emery H, Witte D, and others. Immunohistological characteristics of T cell infiltrates in different forms of childhood onset chronic arthritis. *J Rheumatol* 1996; 23(12):2116–24.
- Gattorno M, Prigione I, Morandi F, Gregorio A, Chiesa S, Ferlito F, and others. Phenotypic and functional characterization of CCR7+ and CCR7-CD4+ memory T cells homing to the joints in juvenile idiopathic arthritis. *Arthritis Res Ther* 2005; 7(2):R256–67. Epub 2005 Jan 12.
- Murray KJ, Grom AA, Thompson SD, Lieuwen D, Passo MH, Glass DN. Contrasting cytokine profiles in the synovium of different forms of juvenile rheumatoid arthritis and juvenile spondyloarthritis: prominence of interleukin 4 in restricted disease. *J Rheumatol* 1998; 25(7):1388–98.
- De Benedetti F, Ravelli A, Martini A. Cytokines in juvenile rheumatoid arthritis. *Curr Opin Rheumatol* 1997; 9(5):428–33.
- Scola MP, Imagawa T, Boivin GP, Giannini EH, Glass DN, Hirsch R, and other. Expression of angiogenic factors in juvenile rheumatoid arthritis: correlation with revascularization of human synovium engrafted into SCID mice. *Arthritis Rheum* 2001; 44(4):794–801.
- Gattorno M, Gregorio A, Ferlito F, Gerloni V, Parafioriti A, Felici E, and other. Synovial expression of osteopontin correlates with angiogenesis in juvenile idiopathic arthritis. *Rheumatology (Oxford)* 2004; 43(9):1091–6. Epub 2004 Jun 15.
- Gattorno M, Gerloni V, Morando A, Comanducci F, Buoncompagni A, Picco P, and others. Synovial membrane expression of matrix metalloproteinases and tissue inhibitor 1 in juvenile idiopathic arthritides. *J Rheumatol* 2002; 29(8):1774–9.
- Ilowite NT. Current treatment of juvenile rheumatoid arthritis. *Pediatrics* 2002; 109(1):109–15.
- Hashkes PJ, Laxer RM. Medical treatment of juvenile idiopathic arthritis. *JAMA* 2005; 294(13):1671–84.
- Wallace CA. Current management of juvenile idiopathic arthritis. *Best Pract Res Clin Rheumatol* 2006; 20(2):279–300.
- Lam DK, Sándor GK, Holmes HI, Evans AW, Clokie CM. A review of bisphosphonate-associated osteonecrosis of the jaws and its management. *J Can Dent Assoc* 2007; 73(5):417–22.
- Wallace CA. The use of methotrexate in childhood rheumatic diseases. *Arthritis Rheum* 1998; 41(3):381–91.
- Ravelli A, Martini A. Methotrexate in juvenile idiopathic arthritis: answers and questions. *J Rheumatol* 2000; 27(8):1830–3.
- Hunt PG, Rose CD, McIlvain-Simpson G, Tejani S. The effects of daily intake of folic acid on the efficacy of methotrexate therapy in children with juvenile rheumatoid arthritis. A controlled study. *J Rheumatol* 1997; 24(11):2230–2.
- Ravelli A, Migliavacca D, Viola S, Ruperto N, Pistorio A, Martini A. Efficacy of folic acid in reducing methotrexate toxicity in juvenile idiopathic arthritis. *Clin Exp Rheumatol* 1999; 17(5):625–7.
- Lovell DJ, Giannini EH, Reiff A, Cawkwell GD, Silverman ED, Nocton JJ, and others. Etanercept in children with polyarticular juvenile rheumatoid arthritis. Pediatric Rheumatology Collaborative Study Group. *N Engl J Med* 2000; 342(11):763–9.
- Dekker L, Armbrust W, Rademaker CM, Prakken B, Kuis W, Wulfraat NM. Safety of anti-TNF alpha therapy in children with juvenile idiopathic arthritis. *Clin Exp Rheumatol* 2004; 22(2):252–8.
- Armbrust W, Kamphuis SS, Wolfs TW, Fiselier TJ, Nikkels PG, Kuis W, and other. Tuberculosis in a nine-year old girl treated with infliximab for systemic juvenile idiopathic arthritis. *Rheumatology (Oxford)* 2004; 43(4):527–9.
- Mouy R, Stephan JL, Pillet P, Haddad E, Hubert P, Prieur AM. Efficacy of cyclosporine A in the treatment of macrophage activation syndrome in juvenile arthritis: report of five cases. *J Pediatr* 1996; 129(5):750–4.
- Ravelli A, De Benedetti F, Viola S, Martini A. Macrophage activation syndrome in systemic juvenile rheumatoid arthritis successfully treated with cyclosporine. *J Pediatr* 1996; 128(2):275–8.
- Cassidy JT, Petty RE, Laxer RM. Systemic connective tissue disease. In: Textbook of pediatric rheumatology, 5th edition. Philadelphia: Elsevier; 2005. p. 414–21.
- Szer IS, Kimura Y, Malleson PN. Disease evaluation. In: Arthritis in children and adolescents. New York: Oxford University Press; 2006. p. 342–57.
- Ravelli A, Martini A. Early predictors of outcome in juvenile idiopathic arthritis. *Clin Exp Rheumatol* 2003; 21(5 Suppl 31):S89–S93.
- Lomater C, Gerloni V, Gattinara M, Mazzotti J, Cimaz R, Fantini F. Systemic onset juvenile idiopathic arthritis: a retrospective study of 80 consecutive patients followed for 10 years. *J Rheumatol* 2000; 27(2):491–6.
- Singh-Grewal D, Schneider R, Bayer N, Feldman BM. Predictors of disease course and remission in systemic juvenile idiopathic arthritis: significance of early clinical and laboratory features. *Arthritis Rheum* 2006; 54(5):1595–601.
- Guillaume S, Prieur AM, Caste J, Job-Deslandre C. Long-term outcome and prognosis in oligoarticular-onset juvenile idiopathic arthritis. *Arthritis Rheum* 2000; 43(8):1858–65.
- Oen K, Malleson PN, Cabral DA, Rosenberg AM, Petty RE, Cheang M. Disease course and outcome of juvenile rheumatoid arthritis in a multicentre cohort. *J Rheumatol* 2002; 29(9):1989–99.
- Simon D, Fernando C, Czernichow P, Prieur AM. Linear growth and final height in patients with systemic juvenile idiopathic arthritis treated with long-term glucocorticoids. *J Rheumatol* 2002; 29(6):1296–300.
- Liem JJ, Rosenberg AM. Growth patterns in juvenile rheumatoid arthritis. *Clin Exp Rheumatol* 2003; 21(5):663–8.
- Lien G, Flatø B, Haugen M, Vinje O, Sørskaar D, Dale K, and others. Frequency of osteopenia in adolescents with early-onset juvenile idiopathic arthritis: a long-term outcome study of one hundred five patients. *Arthritis Rheum* 2003; 48(8):2214–23.
- Welbury RR, Thomason JM, Fitzgerald JL, Steen IN, Marshall NJ, Foster HE. Increased prevalence of dental caries and poor oral hygiene in juvenile idiopathic arthritis. *Rheumatology (Oxford)* 2003; 42(12):1445–51. Epub 2003 Jun 16.
- Walton AG, Welbury RR, Thomason JM, Foster HE. Oral health and juvenile idiopathic arthritis: a review. *Rheumatology (Oxford)* 2000; 39(5):550–5.
- Maguire A, Rugg-Gunn AJ. Consumption of prescribed and over-the-counter (OTC) liquid oral medicines (LOMs) in Great Britain and the northern region of England, with special regard to sugar content. *Public Health* 1994; 108(2):121–30.
- Twilt M, Schulten AJ, Nicolaas P, Dülger A, van Suijlekom-Smit LW. Facioskeletal changes in children with juvenile idiopathic arthritis. *Ann Rheum Dis* 2006; 65(6):823–5.
- Arabshahi B, Cron RQ. Temporomandibular joint arthritis in juvenile idiopathic arthritis: the forgotten joint. *Curr Opin Rheumatol* 2006; 18(5):490–5.

40. Foster HE, Eltringham MS, Kay LJ, Friswell M, Abinun M, Myers A. Delay in access to appropriate care for children presenting with musculoskeletal symptoms and ultimately diagnosed with juvenile idiopathic arthritis. *Arthritis Rheum* 2007; 57(6):921–7.
41. Ince DO, Ince A, Moore TL. Effect of methotrexate on the temporomandibular joint and facial morphology in juvenile rheumatoid arthritis patients. *Am J Orthod Dentofacial Orthop* 2000; 118(1):75–83.
42. Sidiropoulou-Chatzigianni S, Papadopoulos MA, Kolokithas G. Dentoskeletal morphology in children with juvenile idiopathic arthritis compared with healthy children. *J Orthod* 2001; 28(1):53–8.
43. Ueek BA, Mahmud NA, Myall RW. Dealing with the effects of juvenile rheumatoid arthritis in growing children. *Oral Maxillofac Surg Clin North Am* 2005; 17(4):467–73.
44. Pedersen TK, Gronhøj J, Melsen B, Herlin T. Condylar condition and mandibular growth during early functional treatment of children with juvenile chronic arthritis. *Eur J Orthod* 1995; 17(5):385–94.