

# Repair of Furcal Perforation with Mineral Trioxide Aggregate: Long-Term Follow-Up of 2 Cases

**Camila M.M. Silveira, DDS, MSc; Alfonso Sánchez-Ayala, DDS, MSc; Manuel O. Lagravère, DDS, MSc; Gibson L. Pilatti, DDS, MSc, PhD; Osnara M.M. Gomes, DDS, MSc, PhD**

## Auteur-ressource

**Dr Sánchez-Ayala**  
Courriel : [snzcd@fop.unicamp.br](mailto:snzcd@fop.unicamp.br)



## SOMMAIRE

Des études précédentes ont démontré l'efficacité de l'agrégat minéral de trioxyde (MTA) pour la réparation d'une perforation dans la zone de furcation. Nous décrivons dans cet article l'utilisation du MTA pour le traitement de 2 perforations de cette nature (une accidentelle et l'autre causée par la carie), ainsi que le suivi à long terme du traitement.

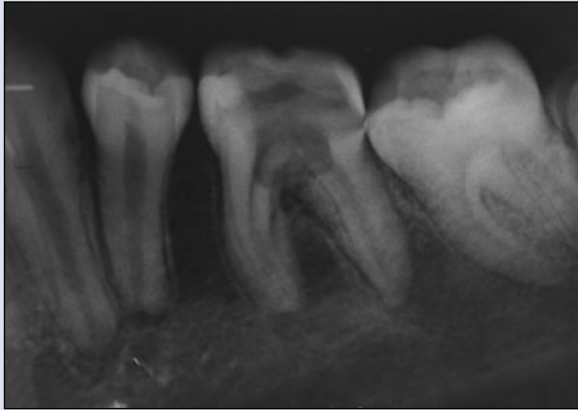
Pour les citations, la version définitive de cet article est la version électronique : [www.cda-adc.ca/jcda/vol-74/issue-8/729.html](http://www.cda-adc.ca/jcda/vol-74/issue-8/729.html)

A major complication of endodontic and restorative treatments is accidental perforation of the roots or the pulp chamber floor. Such perforation may occur during nonsurgical root canal treatment or during preparation for a variety of restorative procedures.<sup>1</sup> The result is a chronic inflammatory reaction of the periodontium (characterized by the formation of granulation tissue) that can lead to irreversible loss of attachment or loss of the tooth.<sup>2</sup> Such perforations are managed surgically or nonsurgically, depending on the particular characteristics of the case.<sup>3</sup> The prognosis may be questionable if treatment involves a lesion occurring at the level of the radicular furcation, but the prognosis is usually good if the problem is diagnosed correctly and treated with a material having suitable sealing ability and biocompatibility.<sup>1</sup> The prognosis also depends on the location, size and time of contamination of the lesion.<sup>4</sup>

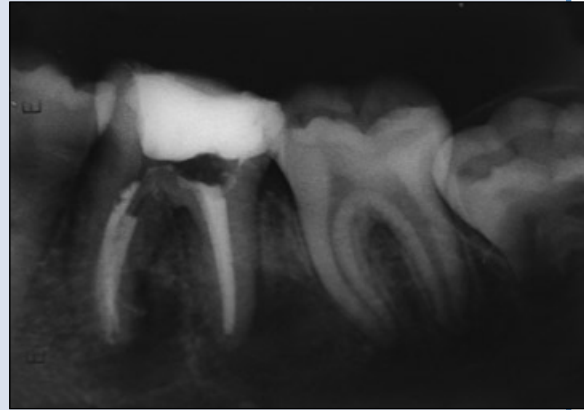Various materials have been used in managing perforations, including zinc oxide-eugenol, amalgam, calcium hydroxide, composite resin, glass ionomer and resin-modified glass ionomer.<sup>1,4</sup> The ideal material for treating radicular

perforations should be nontoxic, nonabsorbable, radiopaque, and bacteriostatic or bactericidal; it should also provide a seal against microleakage from the perforation.<sup>5</sup> Mineral trioxide aggregate (MTA) has all of these characteristics and has been applied with good outcomes in root-end surgery, direct pulpal coverage, apexification, radicular resorption, and repair of lateral radicular and furcal perforation.<sup>6</sup> Its suitability for managing all of these problems can be attributed to its biocompatibility, its low induction of inflammation, its solubility, its capacity for creating a seal between the pulpal chamber and periodontal tissues and its repair capacity. The last of these features can in turn be attributed to the antimicrobial properties and high pH (12.5) of MTA, which promote growth of the cementum and formation of bone, which in turn allow regeneration of the periodontal ligament around the site of injury.<sup>7</sup>

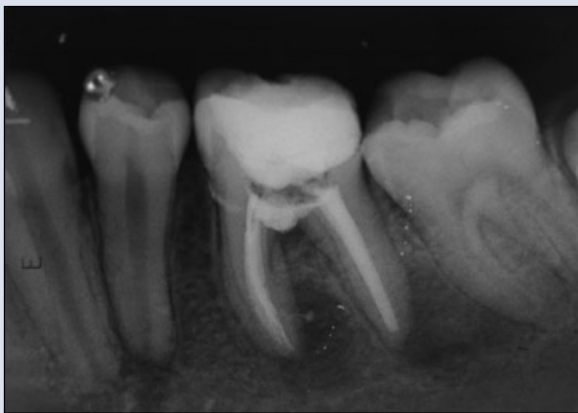In this article, 2 cases are described in which MTA was used to repair furcation perforation. These cases illustrate the potential benefits of MTA and its relative ease of use for management of perforation at easily accessed sites.



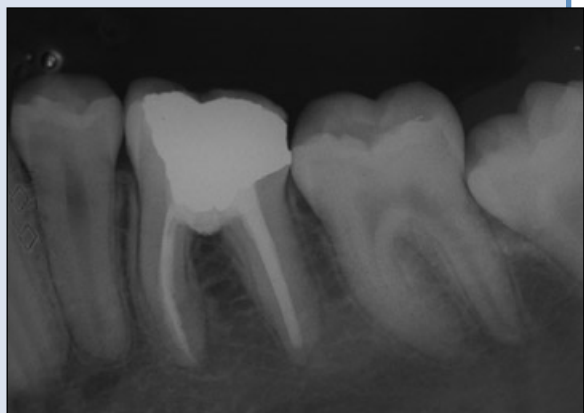**Figure 1a:** Case 1. Periapical image of tooth 36 showing caries-related furcal perforation.



**Figure 1b:** Mineral trioxide aggregate (MTA) placed with temporary restoration.



**Figure 1c:** MTA seal and new root canal treatment at 3-month follow-up.



**Figure 1d:** At 2-year follow-up, there is complete osseous healing at the apex and the furcation.

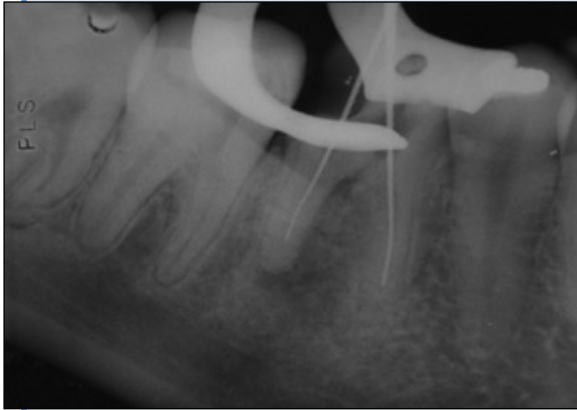
### Case 1

A 27-year-old woman presented with buccal radicular caries, a sinus tract, suppuration, pain on palpation and periodontal breakdown in the furcal region of tooth 36 (**Fig. 1a**). The patient did not recall when the problem first appeared and stated that the pain had started unexpectedly. The diagnosis was pulpal necrosis with acute periradicular periodontitis and furcation perforation due to dental caries. Treatment options included extraction, bicuspidization and nonsurgical repair of the perforation with MTA. After discussion with the patient, MTA treatment was chosen. A rubber dam was used for isolation, the caries was removed, and the perforation site was irrigated with 1% sodium hypochloride to control hemorrhage and allow visualization of the perforation. Cotton pellets moistened in saline were placed in the root canals, and the perforation was sealed with grey MTA (Angelus, Londrina, Brazil) mixed with sterile saline, as suggested by the manufacturer. The MTA was covered with a cotton pellet moistened with distilled water and Cavit temporary restoration material (3M ESPE, St. Paul, Minn.)

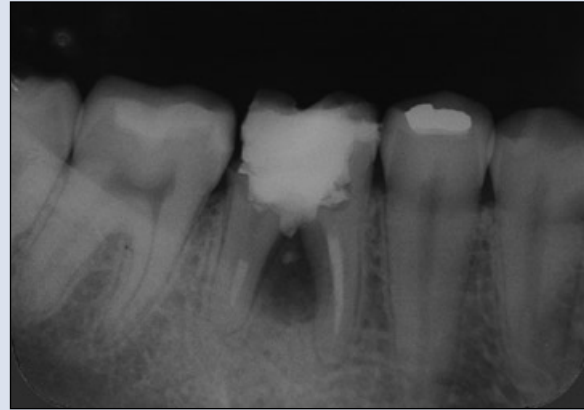
(**Fig. 1b**). Two days after repair of the perforation, the patient underwent nonsurgical root canal treatment without complications. At the 15-day follow-up, the patient was asymptomatic. Three months after the treatment, there was radiographic evidence of bone formation adjacent to the MTA; there was slight extrusion of the material along with the seal of the defect (**Fig. 1c**). At the last check-up, 2 years after treatment, radiography showed complete osseous healing at the apex and the furcation (**Fig. 1d**).

### Case 2

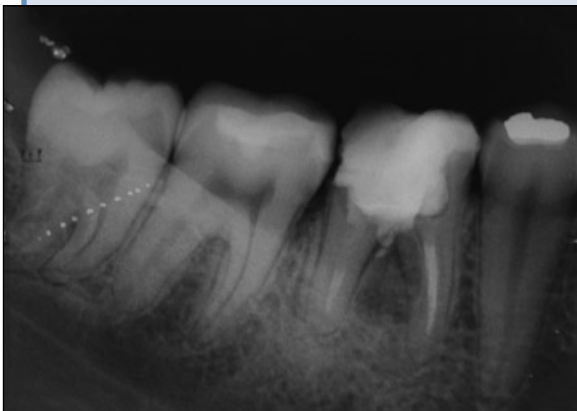A 30-year-old woman presented with accidental furcal perforation, which had occurred during access preparation for root canal treatment of tooth 46. Several treatment options were discussed with the patient, who opted for root canal treatment along with repair of the perforation with MTA. The furcal perforation was confirmed by periapical radiography of tooth 46, which revealed osseous breakdown at the furcation (**Fig. 2a**). The root canal treatment was completed, and the pulpal chamber was then irrigated with 1%



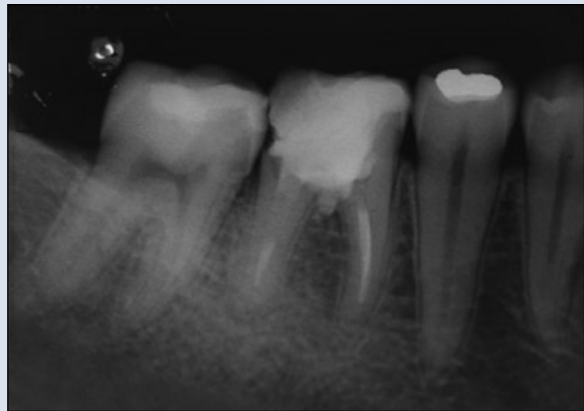
**Figure 2a:** Case 2. Periapical image of tooth 46 showing inadvertent furcal perforation, caused by drilling during access preparation for root canal treatment.



**Figure 2b:** MTA placed with temporary restoration.



**Figure 2c:** Bone formation is visible at 6-month follow-up.



**Figure 2d:** Osseous repair can still be seen at the 5-year follow-up.

sodium hypochloride to control hemorrhage and to allow visualization of the perforation. White MTA-Angelus was applied in a manner similar to that described for case 1. The final radiograph obtained at the time of treatment showed evidence that the perforation had been sealed (**Fig. 2b**). Ten days later, the patient was asymptomatic. At the 6-month follow-up, bone formation was evident on radiography (**Fig. 2c**). A radiograph obtained 5 years after treatment showed that the osseous repair had persisted (**Fig. 2d**).

### Discussion

Furcal perforation is an undesirable problem that may occur during root canal treatment or post preparation. Similarly, a risk of perforation may arise during removal of affected tissue in a patient with caries involving the pulpal chamber. In either case, the situation can be quickly addressed, which is important, as immediate treatment will help ensure a positive prognosis.<sup>4</sup> In the 2 cases presented here, the problem was resolved promptly by application of MTA.

Two major brands of MTA are available on the market: MTA-Angelus (used in the cases described here) and Pro-Root MTA (Maillefer, Dentsply, Switzerland). Both products are available in grey or white. According to the manufacturer's material safety data sheet, Pro-Root MTA is composed of 75% Portland cement, 20% bismuth oxide and 5% dehydrated calcium sulfate. MTA-Angelus is composed of 80% Portland cement and 20% bismuth oxide, with no calcium sulfate.<sup>8</sup> The dominant compounds in both types of Pro-Root MTA are calcium oxide, silica and bismuth. However, the grey version has greater concentrations of aluminum oxide (122% higher), magnesium (130% higher) and iron (1000% increase).<sup>9</sup> Although both the grey and the white versions of Pro-Root MTA perform similarly in terms of furcal sealing<sup>10</sup> and antimicrobial effectiveness,<sup>11</sup> the grey version has a more favourable behaviour in vitro in terms of development of odontoblasts,<sup>12</sup> whereas the white version is associated with development of cementoblasts and keratinocytes.<sup>13</sup> The white version gives a better final appearance than the original grey MTA, which can

create a shadow under thin tissue.<sup>10</sup> Both the grey and the white versions of MTA-Angelus and Pro-Root MTA have numerous similarities: pH 9 after 168 hours,<sup>14</sup> success in dog pulpotomy,<sup>15</sup> minimal concentration of arsenic (0.0002 ppm),<sup>16</sup> overall composition,<sup>8</sup> biocompatibility,<sup>17</sup> inflammatory response,<sup>18</sup> sealant ability,<sup>5</sup> in vitro fibroblastic stimulation<sup>19</sup> and antimicrobial activity.<sup>20</sup> However, MTA-Angelus has greater release of calcium in the first 24 hours of activation<sup>14</sup> and a lower concentration of bismuth (grey version only).<sup>21</sup> In the current report, white MTA-Angelus was used in one case and grey in the other, with similar results.

MTA is difficult to manipulate because of its granular consistency, slow setting time and looseness.<sup>22</sup> Pro-Root MTA contains fewer large particles and fewer small particles than MTA-Angelus. Generally speaking, white MTA contains smaller particles than grey MTA, with a narrower distribution of sizes. MTA-Angelus particles have relatively low sphericity and a wide size distribution, and they are less homogeneous than Pro-Root MTA.<sup>23</sup> The main disadvantage of Pro-Root MTA may be its long setting time. MTA-Angelus contains no calcium sulphate, which reduces its setting time to 10 minutes.<sup>8</sup>

Contamination of the blood should be avoided when using this type of material, as such contamination can reduce the retention capacity of the MTA.<sup>24</sup> Previous authors have stated that contact with adjacent tissues may increase the sealant capacity of MTA, since an acidic environment (such as tissue) may increase this property.<sup>25</sup> In the cases presented here, sealing of the lesions could be observed, with some extrusion of the material. To prevent overfilling or underfilling, a resorbable collagen matrix can be applied before placing the MTA,<sup>24</sup> but use of a matrix depends on the size of the lesion. Success has been reported both with<sup>26</sup> and without<sup>27</sup> the matrix. At present, there is no size classification for furcal lesions to determine appropriate treatment and prognosis; therefore, all options are considered to have a guarded prognosis.<sup>17</sup> In the 2 cases presented here, the lesions were of different sizes. In case 1, the lesion was larger, with irregular limits, characteristic of a V-shaped caries. As shown in **Fig. 1a**, the lesion affected almost the complete dimension of the furcal region, but did not affect the internal walls of the roots; this limited the lesion overall and indicated a lateral boundary against which to place the material. If the lesion had been larger, it would have been necessary to apply a matrix base before placing the MTA. **Figure 1d** shows mild extrusion of the MTA adjacent to the newly formed osseous crest. In case 2, the lesion was more circumscribed and had a vertical entrance, characteristic of accidental perforation with a diamond bur (**Fig. 2a**); osseous destruction was also greater (**Fig. 2b**). Nevertheless, the use of white MTA in case 2 yielded results similar to those achieved with grey MTA in case 1.

Although use of MTA has been reported for several different endodontic treatments, the literature on its success in cases of furcal perforation is limited. Two common clinical presentations of furcal perforation (related to caries and to accidental drilling) have been described here. Although the prognosis is typically better for smaller lesions (as in case 2), and although the location of these perforations at the level of the epithelial attachment and crestal bone suggested a guarded prognosis,<sup>1,4</sup> MTA treatment was successful, as indicated by imaging at 2 and 5 years, respectively. ♦

## THE AUTHORS



*Dr. Silveira is a professor in the endodontic specialization program, University of Ponta Grossa, Ponta Grossa, Brazil.*



*Dr. Sánchez-Ayala is a PhD student in the prosthodontic postgraduate program, faculty of dentistry, University of Campinas, Campinas, Brazil.*



*Dr. Lagravère is a PhD resident in the orthodontic graduate program, faculty of medicine and dentistry, University of Alberta, Edmonton, Alberta.*



*Dr. Pilatti is an associate professor in the integrated clinic postgraduate program, department of dentistry, University State of Ponta Grossa, Ponta Grossa, Brazil.*



*Dr. Gomes is an associate professor in the dentistry post-graduate program, department of dentistry, University State of Ponta Grossa, Ponta Grossa, Brazil.*

**Correspondence to:** Dr. Alfonso Sánchez-Ayala, Limeira 901, Areao, Box 52, CEP: 13414903, Piracicaba – Sao Paulo, Brazil.

*The authors have no declared financial interests in any company manufacturing the types of products mentioned in this article.*

*This article has been peer reviewed.*

## References

1. Tsesis I, Fuss Z. Diagnosis and treatment of accidental root perforations. *Endod Top* 2006; 13:95–107.
2. Al-Daafas A, Al-Nazhan S. Histological evaluation of contaminated furcal perforation in dogs' teeth repaired by MTA with or without internal matrix. *Oral Surg Oral Med Oral Pathol Oral Radiol Endod* 2007; 103(3):e92–9.
3. Roda RS. Root perforation repair: surgical and nonsurgical management. *Pract Proced Aesthet Dent* 2001; 13(6):467–72.
4. Fuss Z, Trope M. Root perforations: classification and treatment choices based on prognostic factors. *Endod Dent Traumatol* 1996; 12(6):255–64.
5. De-Deus G, Reis C, Brandão C, Fidel S, Fidel RA. The ability of Portland cement, MTA, and MTA Bio to prevent through-and-through fluid movement in repaired furcal perforations. *J Endod* 2007; 33(11):1374–7.
6. Torabinejad M, Chivian N. Clinical application of mineral trioxide aggregate. *J Endod* 1999; 25(3):197–205.
7. Roberts HW, Toth JM, Berzins DW, Charlton DG. Mineral trioxide aggregate material use in endodontic treatment: a review of the literature. *Dent Mater* 2008; 24(2):149–64.

8. Oliveira MG, Xavier CB, Demarco FF, Pinheiro AL, Costa AT, Pozza DH. Comparative chemical study of MTA and Portland cements. *Braz Dent J* 2007; 18(1):3–7.
9. Asgary S, Parirokh M, Eghbal MJ, Brink F. Chemical differences between white and gray mineral trioxide aggregate. *J Endod* 2005; 31(2):101–3.
10. Hamad HA, Tordik PA, McClanahan SB. Furcation perforation repair comparing gray and white MTA: a dye extraction study. *J Endod* 2006; 32(4):337–40.
11. Ribeiro CS, Kuteken FA, Hirata Junior R, Scelza MFZ. Comparative evaluation of antimicrobial action of MTA, calcium hydroxide and portland cement. *J Appl Oral Sci* 2006; 14(5):330–3.
12. Perez AL, Spears R, Gutmann JL, Opperman LA. Osteoblasts and MG-63 osteosarcoma cells behave differently when in contact with ProRoot MTA and White MTA. *Int Endod J* 2003; 36(8):564–70.
13. Oviir T, Pagoria D, Ibarra G, Geurtsen W. Effects of gray and white mineral trioxide aggregate on the proliferation of oral keratinocytes and cementoblasts. *J Endod* 2006; 32(3):210–3.
14. Duarte MA, Demarchi AC, Yamashita JC, Kuga MC, Fraga Sde C. pH and calcium ion release of 2 root-end filling materials. *Oral Surg Oral Med Oral Pathol Oral Radiol Endod* 2003; 95(3):345–7.
15. Menezes R, Bramante CM, Letra A, Carvalho VG, Garcia RB. Histologic evaluation of pulpotomies in dog using two types of mineral trioxide aggregate and regular and white Portland cements as wound dressings. *Oral Surg Oral Med Oral Pathol Oral Radiol Endod* 2004; 98(3):376–9.
16. Duarte MA, De Oliveira Demarchi AC, Yamashita JC, Kuga MC, De Campos Fraga S. Arsenic release provided by MTA and Portland cement. *Oral Surg Oral Med Oral Pathol Oral Radiol Endod* 2005; 99(5):648–50.
17. De Deus G, Ximenes R, Gurgel-Filho ED, Plotkowski MC, Coutinho-Filho T. Cytotoxicity of MTA and Portland cement on human ECV 304 endothelial cells. *Int Endod J* 2005; 38(9):604–9.
18. Rezende TM, Vargas DL, Cardoso FP, Sobrinho AP, Vieira LQ. Effect of mineral trioxide aggregate on cytokine production by peritoneal macrophages. *Int Endod J* 2005; 38(12):896–903.
19. Guven G, Cehreli ZC, Ural A, Serdar MA, Basak F. Effect of mineral trioxide aggregate cements on transforming growth factor beta1 and bone morphogenetic protein production by human fibroblasts in vitro. *J Endod* 2007; 33(4):447–50.
20. Tanomaru-Filho M, Tanomaru JM, Barros DB, Watanabe E, Ito IY. In vitro antimicrobial activity of endodontic sealers, MTA-based cements and Portland cement. *J Oral Sci* 2007; 49(1):41–5.
21. Song JS, Mante FK, Romanow WJ, Kim S. Chemical analysis of powder and set forms of Portland cement, gray ProRoot MTA, white ProRoot MTA, and gray MTA-Angelus. *Oral Surg Oral Med Oral Pathol Oral Radiol Endod* 2006; 102(6):809–15.
22. Ber BS, Hatton JF, Stewart GP. Chemical modification of ProRoot MTA to improve handling characteristics and decrease setting time. *J Endod* 2007; 33(10):1231–4.
23. Komabayashi T, Spångberg LS. Comparative analysis of the particle size and shape of commercially available mineral trioxide aggregates and Portland cement: a study with a flow particle image analyzer. *J Endod* 2008; 34(1):94–8.
24. Vanderweele RA, Schwartz SA, Beeson TJ. Effect of blood contamination on retention characteristics of MTA when mixed with different liquids. *J Endod* 2006; 32(5):421–4.
25. Roy CO, Jeansonne BG, Gerrets TF. Effect of an acid environment on leakage of root-end filling materials. *J Endod* 2001; 27(1):7–8.
26. Bargholz C. Perforation repair with mineral trioxide aggregate: a modified matrix concept. *Int Endod J* 2005; 38(1):59–69.
27. Schwartz RS, Mauger M, Clement DJ, Walker WA 3rd. Mineral trioxide aggregate: a new material for endodontics. *J Am Dent Assoc* 1999; 130(7):967–75.