

# Simple Preservation of a Maxillary Extraction Socket Using Beta-tricalcium Phosphate with Type I Collagen: Preliminary Clinical and Histomorphometric Observations

**Bozidar M.B. Brkovic**, DDS, MSc, PhD; **Hari S. Prasad**, BS, MDT;  
**George Konandreas**, DDS; **Radulovic Milan**, DDS, MSc; **Dragana Antunovic**, DDS;  
**George K.B. Sándor**, MD, DDS, PhD, FRCD(C), FRCSC, FACS;  
**Michael D. Rohrer**, DDS, MS

## Auteur-ressource

**Dr Sándor**  
Courriel : [george.sandor@utoronto.ca](mailto:george.sandor@utoronto.ca)



## SOMMAIRE

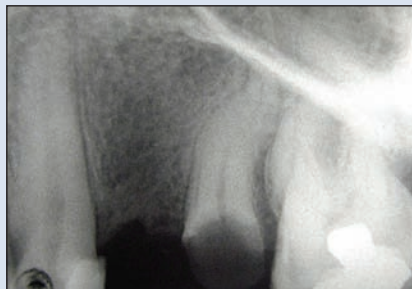L'atrophie alvéolaire consécutive à l'extraction demeure un problème lorsqu'on envisage la mise en place future d'un implant dentaire. La mise en place immédiate de l'implant et la préservation de l'alvéole après l'extraction sont 2 méthodes qui sont utilisées pour prévenir une importante perte osseuse post-extraction. Cet article traite de la prise en charge de l'alvéole après l'extraction d'une dent supérieure par une technique de préservation alvéolaire qui consiste en l'application d'un cône de phosphate tricalcique bêta (β-TCP) combiné à du collagène de type I, sans recourir à des membranes barrières ou à l'élévation de lambeaux. L'examen clinique a révélé une bonne formation osseuse, 9 mois après la procédure. Selon l'analyse histomorphométrique de l'os biopsié réalisée au moment de l'implantation, l'os était constitué de 62,6 % d'os minéralisé, de 21,1 % de moelle osseuse et de 16,3 % de β-TCP résiduel. L'os guéri a pu soutenir la mise en place et la mise en charge subséquentes de l'implant.

Pour les citations, la version définitive de cet article est la version électronique : [www.cda-adc.ca/jcda/vol-74/issue-6/523.html](http://www.cda-adc.ca/jcda/vol-74/issue-6/523.html)

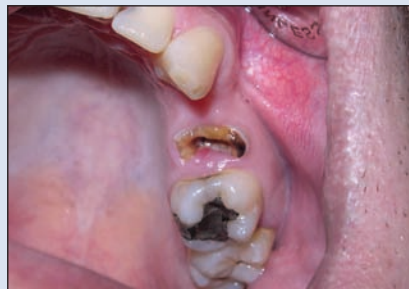After tooth extraction, the residual alveolar ridge generally provides limited bone volume because of ongoing, progressive bone resorption.<sup>1</sup> Healing events within postextraction sockets reduce the dimensions of the socket over time.<sup>2</sup> A reduction of about 50% in both horizontal and vertical directions has been observed over 12 months, with two-thirds of the reduction occurring in the first 3 months.<sup>3</sup> The rate and pattern of bone resorption may be altered if pathologic and traumatic processes

have damaged 1 or more of the bony walls of the socket. In these circumstances, fibrous tissue will likely occupy part of the socket, preventing normal healing and osseous regeneration.<sup>3</sup> These morphologic changes may affect the successful placement and osseointegration of dental implants.

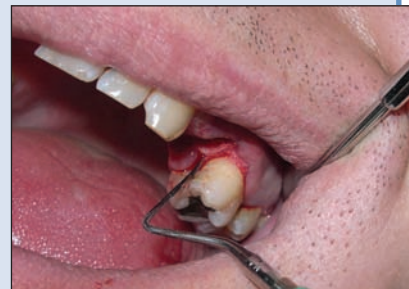When considering ways to preserve adequate bone volume, clinicians frequently ask whether filling bone defects, such as alveolar postextraction sockets, with resorbable osteoconductive



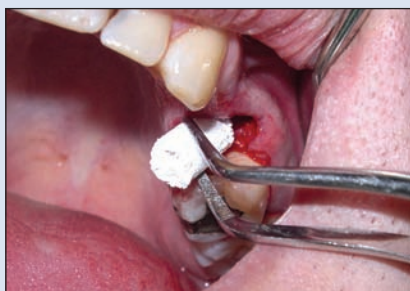**Figure 1a:** Periapical radiograph of deteriorated left maxillary second premolar before extraction.



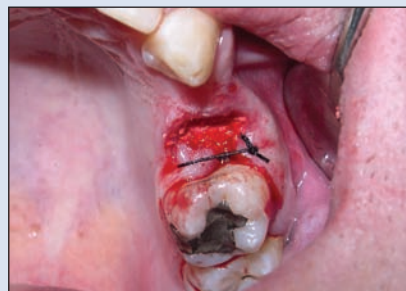**Figure 1b:** Remnant of the maxillary second premolar structure with extensive coronal destruction.



**Figure 1c:** Determination of the crestal alveolar bone level before socket preservation.



**Figure 1d:** Placement of  $\beta$ -TCP combined with type I collagen (RTR Cone) at the extraction site.



**Figure 1e:**  $\beta$ -TCP combined with type I collagen implant secured with a single suture without a barrier membrane or mucoperiosteal flap.

materials is warranted.<sup>4-6</sup> Although autogenous bone is still considered the gold standard for grafting procedures, limitations, such as donor site morbidity from bone graft harvesting techniques,<sup>7</sup> have stimulated the search for suitable synthetic grafting materials. Although barrier membranes may be used to guide bone regeneration, wound dehiscence may lead to early exposure and infection of the membrane followed by reduction in the volume and quality of bone.<sup>8,9</sup>

Beta-tricalcium phosphate ( $\beta$ -TCP), a synthetic alloplastic material, has been used for bone regeneration in a variety of surgical procedures with satisfactory clinical and histologic results in both animal models<sup>10,11</sup> and human trials.<sup>12,13</sup>  $\beta$ -TCP may be a suitable bone substitute that will biodegrade and be replaced by newly mineralizing bone tissue without fibrous tissue proliferation.<sup>12</sup> Bony regeneration has been reported in cases where  $\beta$ -TCP was used without a barrier membrane in patients undergoing sinus floor elevation and mandibular cyst removal.<sup>12</sup> It is also possible to combine  $\beta$ -TCP with platelet-rich plasma, other growth factors or collagen to potentially accelerate the process of bone regeneration.<sup>14,15</sup>

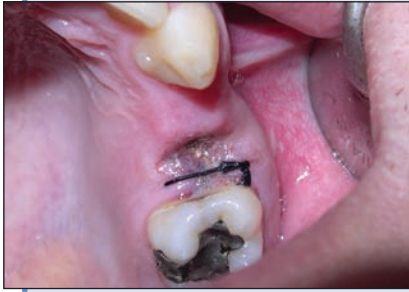There have been no reports on the use of  $\beta$ -TCP combined with type I collagen for postextraction socket preservation without the use of a barrier membrane or mucoperiosteal flap to cover the implanted material. The purpose of this article is to present clinical, radiographic, histologic and

histomorphometric results for a patient treated with  $\beta$ -TCP in combination with type I collagen for alveolar preservation before dental implant placement.

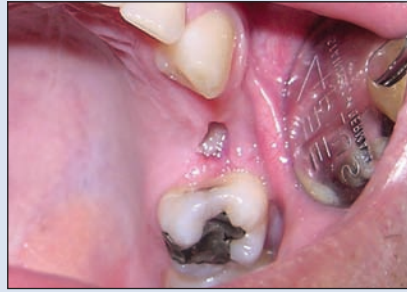### Case Report

A 28-year-old healthy male non-smoker with good oral hygiene required the extraction of a left maxillary second premolar (tooth 25) before placement of a dental implant for prosthodontic rehabilitation (**Fig. 1a**). The tooth had to be extracted as it was severely broken down (**Fig. 1b**). The alveolar preservation protocol was approved by the institution's ethical review board and written informed consent was obtained from the patient after the risks and benefits were explained to him.

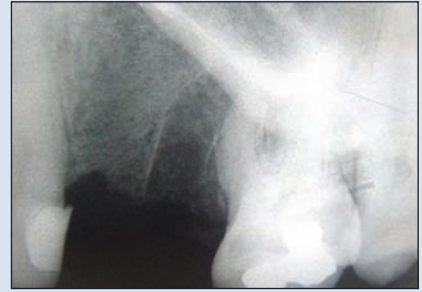After administration of local anesthesia, an intrasulcular incision was made to raise a distal papilla and marginal gingiva. This exposed the marginal bone to allow visualization and measurement of the alveolar bone level (**Fig. 1c**). Extraction of the tooth was performed using a straight elevator and forceps without the elevation of flaps. After extraction of the tooth, the socket was thoroughly curetted.  $\beta$ -TCP with type I collagen (RTR Cone, Septodont, Saint-Maur-des-Fossés, France) was placed in the alveolar socket occupying the space from the crest of the alveolus to the apex of the socket (**Fig. 1d**). The socket was filled with the alloplastic material, but not covered with any



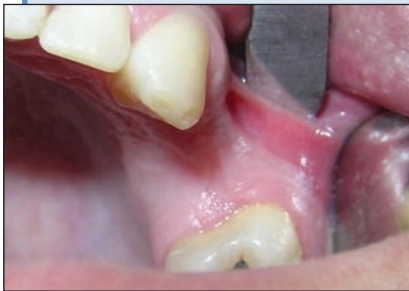**Figure 2a:** At 5 days following placement of  $\beta$ -TCP combined with type I collagen in the alveolar socket, the socket opening is covered with fibrin.



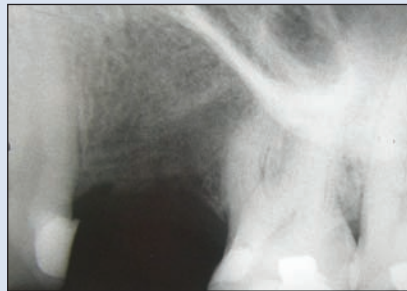**Figure 2b:** At 7 days, the extraction socket is covered with healing gingival tissue.



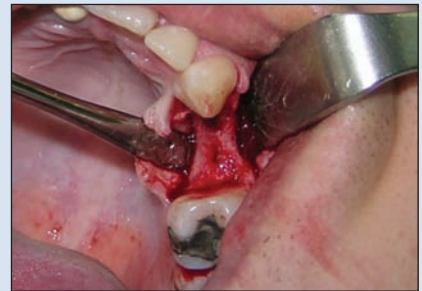**Figure 2c:** Periapical radiograph taken 7 days after insertion of  $\beta$ -TCP combined with type I collagen.



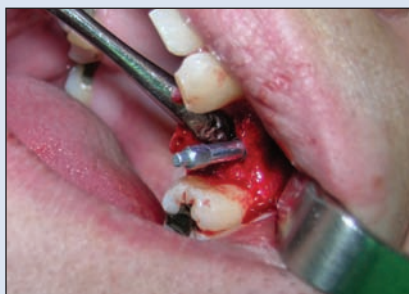**Figure 2d:** The postextraction healed gingival wound 4 months after alveolar socket preservation.



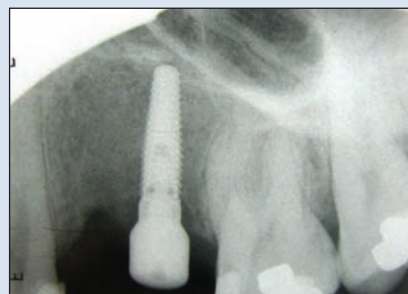**Figure 2e:** Periapical radiograph taken 9 months following socket preservation showing complete bone fill of the socket.



**Figure 2f:** Exposure of the alveolar bone for dental implant placement 9 months after alveolar socket preservation. Newly formed bone is solid and there are no visible signs of particles.



**Figure 2g:** Test of implant position in the preservation area. No reduction in vertical bone height was recorded when the 9-month measurements were made and subsequently compared with baseline measurements at tooth extraction.



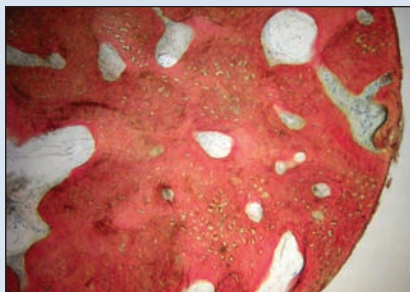
**Figure 2h:** Titanium implant immediately after placement, positioned within the bone of the healed socket 9 months postextraction.

barrier membrane or mucoperiosteal flap. The distobuccal and palatal papillae and attached gingiva at the extraction site were stabilized with a single interrupted suture to reduce the opening of the socket and the amount of exposed material (Fig. 1e). The patient was prescribed a course of antibiotic and pain medications with postoperative instructions for 7 days, at which point the suture was removed.

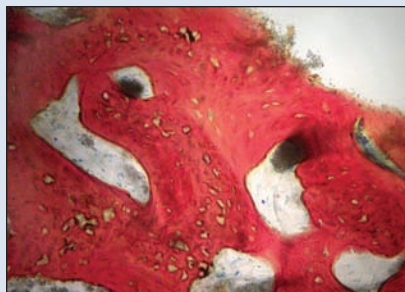The patient was examined at 3, 5 and 7 days, then at 4 and 9 months postoperatively; radiographs were taken

at 1 week, 4 months and 9 months following placement of the alloplastic material (Figs. 2a–2e). After 9 months, a trephine, 2 mm in diameter and 6 mm in length, was used to collect a bone sample from the treated extraction socket during dental implant placement (Figs. 2f to 2h).

The bone biopsy specimen was prepared for non-decalcified histologic and histomorphometric analysis. It was cut and polished to a thickness of 45  $\mu$ m using a cutting–grinding system (Exakt Technologies, Oklahoma City,



**Figure 3a:** Photomicrograph of a biopsy core taken 9 months after placement of  $\beta$ -TCP combined with type I collagen (RTR Cone) without a barrier membrane. Good trabecular connectivity with large, irregular lacunae of the young mineralized bone and bone marrow can be seen.  $\times 40$  magnification. Stevenel's blue and Van Gieson's picro fuchsin staining.



**Figure 3b:** High-power image of a biopsy core taken 9 months after socket preservation. Residual  $\beta$ -TCP and various sizes of dispersed particles are being incorporated into new bone. Large irregular lacunae appear to include  $\beta$ -TCP.  $\times 200$  magnification. Stevenel's blue and Van Gieson's picro fuchsin stain.

Okla.) and stained with Stevenel's blue and Van Gieson's picro fuchsin. The parameters evaluated included the total area of the core, the percentage of new bone formation, the percentage of residual graft and the percentage of fibrous tissue. All parameters were evaluated by analyzing digital images in the NIH Image Program (National Institutes of Health, Bethesda, Md).

Clinically, healing was uneventful. By the seventh day, the socket was completely covered with gingiva. During the 9 months of observation, no loss of material, no signs of infection, exudation or fistula formation at the area of the extraction and ridge preservation wound were noted. Measurement of the alveolar ridge on the day of implant placement revealed slight horizontal bone resorption, but no change in the vertical dimension of the alveolar ridge. The buccopalatal dimension of the alveolar socket was 12 mm before RTR Cone placement and 10 mm after 9 months. The alveolar crestal bone level was 3 mm below the cemento-enamel junction of the mesial aspect of the left first molar before RTR Cone placement and 9 months following the placement. Clinically, no particles of material were visible and the bone was found to be smooth and solid when prepared for implant insertion (**Fig. 2f**).

Radiographically, by the fourth month of follow-up, the alveolar socket appeared to be filled with radiodense bone tissue except for the most cervical portion of the alveolus. By 9 months postextraction, the cervical radiolucency had disappeared and uniform radiodense bone was found throughout the healing extraction socket (**Fig. 2e**).

Histologically, a great deal of active new bone formation was noted (**Fig. 3a**). This was apparent throughout the biopsy core (**Fig. 3b**) as large, irregular lacunae with active osteoblastic rimming. In some areas, new bone deposition

was associated with residual  $\beta$ -TCP particles. It appeared that resorbing  $\beta$ -TCP was present as dispersed particles. No residual collagen was noted in proximity to the  $\beta$ -TCP, and no fibrous tissue or inflammatory cellular infiltration was observed. Histomorphometric analysis showed the composition of the sample to be 62.6% mineralized new bone, 21.1% bone marrow and 16.3% residual  $\beta$ -TCP graft.

Implant placement and postoperative healing were uneventful. At follow-up 18 months after prosthodontic treatment and loading, the implant was stable and surrounded with healthy tissue. There were no complaints or complications during this period of observation.

## Discussion

There are several reasons to consider preservation of the alveolar socket immediately following tooth extraction. One reason for placing a graft of a synthetic biomaterial is to stabilize the coagulum within the socket and avoid possible reduction of the hard tissue volume required for bone regeneration. Although vertical bone resorption can be expected as part of the physiologic pattern of bone healing after tooth extraction,<sup>3</sup> in our patient no reduction in the vertical dimension of the alveolar ridge had occurred 9 months after tooth extraction. The ridge width (12 mm) did not change either.

Another reason for placing a graft into an extraction socket is to provide a scaffold for the in-growth of cellular and vascular components to form new bone of acceptable quality and quantity. In our patient, the total volume of newly formed bone was 83.67% including both mineralized bone and bone marrow when  $\beta$ -TCP with type I collagen was used without a barrier membrane or mucoperiosteal flap.

The results in this case show that  $\beta$ -TCP particles in the extraction socket are osteoconductive. When particles of  $\beta$ -TCP are mixed with the blood clot and surrounded by the bony walls of the alveolar socket, osteogenic cells, including undifferentiated mesenchymal stem cells, start migrating from the existing bone surface between and over the surface of the particles, stimulated mostly by an adhesive glycoprotein, fibronectine, a component of the forming blood clot.<sup>12,13</sup> In addition, type I collagen combined with  $\beta$ -TCP promotes osteogenesis by supporting osteoblastic differentiation and proliferation.<sup>16,17</sup> Type I collagen has been shown to accelerate the healing process in bone defects in animals.<sup>16</sup> Complete bone healing was noted in animals after 3 months, whereas defects in the control group took 5 months to fill with new bone. The combination of  $\beta$ -TCP and type I collagen in an integrated structure, such as an RTR Cone as used in our study, has demonstrated osteoconductivity, which facilitates bone formation.<sup>15</sup>

Significant resorption of the  $\beta$ -TCP particles is expected 3–6 months after placement.<sup>10</sup> At 9 months after alveolar socket preservation, the small residual amount of  $\beta$ -TCP graft did not compromise placement of the osseointegrated dental implant. Moreover,  $\beta$ -TCP particles become well incorporated into new bone formation creating a dense cancellous network. This may improve the biologic ability to withstand loading forces transmitted by implants placed in that site. Biodegradation of  $\beta$ -TCP occurs by both osteoclastic activity and chemical dissolution by tissue fluids.<sup>18</sup>  $\beta$ -TCP is a highly porous material and dissolved  $\beta$ -TCP particles can be incorporated into the newly mineralized bone and the lacunar–canalicular system of osteocytes<sup>19</sup> as well as into the bone marrow or marginal osteoid.

An important factor in this case is that neither a barrier membrane nor a mucoperiosteal flap was used to cover the alveolar postextraction socket filled with synthetic material. Instead, the  $\beta$ -TCP in combination with type I collagen was left uncovered to heal spontaneously. At 7 days, the process of epithelialization was complete and the socket was covered without clinical complications. Several possible mechanisms may explain the apparent blockade of fibrous tissue ingrowth into the porous structure of the  $\beta$ -TCP granules: inhibition of fibroblastic proliferation by  $\beta$ -TCP and its metabolites during dissolution of  $\beta$ -TCP particles<sup>20</sup>; a local decrease in pH during dissolution of material<sup>13</sup>; or direct chemical bonding of  $\beta$ -TCP with bone through a reaction between calcium ions in the  $\beta$ -TCP particle and carboxyl groups in the collagen polypeptide chains.<sup>15,19</sup>

This case report suggests that a cone of biomaterial, composed of  $\beta$ -TCP combined with type I collagen, can prevent alveolar crest resorption following tooth extraction without the use of a barrier membrane or a mucoperiosteal flap. Formation of new bone of acceptable quality and quan-

tity permitted the placement of an osseointegrated dental implant. Further study of this material and this protocol is needed and a case series is currently underway. ♦

## THE AUTHORS



**Dr. Brkovic** is an assistant professor in the Clinic of Oral Surgery, School of Dentistry, University of Belgrade, Belgrade, Serbia, and Stoneman Fellow in Pediatric Oral and Maxillofacial Surgery, The Hospital for Sick Children, University of Toronto, Toronto, Ontario.



**Mr. Prasad** is an assistant professor in the Hard Tissue Research Laboratory, School of Dentistry, University of Minnesota, Minneapolis, Minnesota.



**Dr. Konandreas** maintains a private practice in Athens, Greece.



**Dr. Milan** is an assistant professor in the department of oral surgery, faculty of dentistry, University of Pancevo, Pancevo, Serbia.



**Dr. Antunovic** maintains a private practice in Belgrade, Serbia.



**Dr. Sándor** is a professor and head of oral and maxillofacial surgery, University of Toronto, Toronto, Ontario; professor at the Regea Institute for Regenerative Medicine, University of Tampere, Tampere, Finland; and docent in oral and maxillofacial surgery, University of Oulu, Oulu, Finland.



**Dr. Rohrer** is a professor in the Hard Tissue Research Laboratory, School of Dentistry, University of Minnesota, Minneapolis, Minnesota.

**Correspondence to:** Professor George K.B. Sándor, The Hospital for Sick Children, S-525, 555 University Avenue, Toronto ON M5G 1X8.

**Acknowledgments:** The authors wish to thank Septodont, France, for financial assistance and for donating the clinical material used in this study.

The authors have no declared financial interests in any company manufacturing the types of products mentioned in this article.

This article has been peer reviewed.

## References

1. Tallgren A. The continuing reduction of the residual alveolar ridges in complete denture wearers: a mixed-longitudinal study covering 25 years. 1972. *J Prosthet Dent* 2003; 89(5):427–35.
2. Araújo MG, Sukekava F, Wennström JL, Lindhe J. Ridge alterations following implant placement in fresh extraction sockets: an experimental study in the dog. *J Clin Periodontol* 2005; 32(6):645–52.
3. Chen ST, Wilson TG Jr, Hämmerle CH. Immediate or early placement of implants following tooth extraction: review of biologic basis, clinical procedures, and outcomes. *Int J Oral Maxillofac Implants* 2004; 19 Suppl:12–25.

4. Nair Pn PR, Schug J. Observation on healing of human tooth extraction sockets implanted with bioabsorbable polylactic-polyglycolic acids (PLGA) copolymer root replicas: a clinical, radiographic, and histologic follow-up report of 8 cases. *Oral Surg Oral Med Oral Pathol Oral Radiol Endod* 2004; 97(5):559–69.
5. Cardaropoli G, Araújo M, Hayacibara R, Sukekava F, Lindhe J. Healing of extraction sockets and surgically produced — augmented and non-augmented — defects in the alveolar ridge. An experimental study in the dog. *J Clin Periodontol* 2005; 32(5):435–40.
6. Boix D, Weiss P, Gauthier O, Guicheux J, Bouler JM, Pilet P, and others. Injectable bone substitute to preserve alveolar ridge resorption after tooth extraction: a study in dog. *J Mater Sci Mater Med* 2006; 17(11):1145–52. Epub 2006 Nov 22.
7. Clavero J, Lundgren S. Ramus or chin grafts for maxillary sinus inlay and local onlay augmentation: comparison of donor site morbidity and complications. *Clin Implant Dent Relat Res* 2003; 5(3):154–60.
8. Malchiodi L, Scarano A, Quaranta M, Piattelli A. Rigid fixation by means of titanium mesh in edentulous ridge expansion for horizontal ridge augmentation in the maxilla. *Int J Oral Maxillofac Implants* 1998; 13(5):701–5.
9. Artzi Z, Dayan D, Alpern Y, Nemcovsky CE. Vertical ridge augmentation using xenogenic material supported by a configured titanium mesh: clinico-histopathologic and histochemical study. *Int J Oral Maxillofac Implants* 2003; 18(3):440–6.
10. Artzi Z, Weinreb M, Givol N, Rohrer MD, Nemcovsky CE, Prasad HS, and other. Biomaterial resorption rate and healing site morphology of inorganic bovine bone and beta-tricalcium phosphate in the canine: a 24-month longitudinal histologic study and morphometric analysis. *Int J Oral Maxillofac Implants* 2004; 19(3):357–68.
11. Haddad AJ, Peel SA, Clokie CM, Sándor GK. Closure of rabbit calvarial critical-sized defects using protective composite allogeneic and alloplastic bone substitutes. *J Craniofac Surg* 2006; 17(5):926–34.
12. Zerbo IR, Bronckers AL, de Lange GL, van Beek GJ, Burger EH. Histology of human alveolar bone regeneration with a porous tricalcium phosphate. A report of two cases. *Clin Oral Implants Res* 2001; 12(4):379–84. [Article in English, French, German]
13. Zerbo IR, Bronckers AL, de Lange G, Burger EH. Localisation of osteogenic cells and osteoplastic cells in porous beta-tricalcium phosphate particles used for human maxillary sinus floor elevation. *Biomaterials* 2005; 26(12):1445–51.
14. Wiltfang J, Schlegel KA, Schultze-Mosgau S, Nkenke E, Zimmermann R, Kessler P. Sinus floor augmentation with beta-tricalciumphosphate (beta-TCP): does platelet-rich plasma promote its osseous integration and degradation? *Clin Oral Implants Res* 2003; 14(2):213–8.
15. Zou C, Weng W, Deng X, Cheng K, Liu X, Du P, and others. Preparation and characterization of porous beta-tricalcium phosphate/collagen composites with an integrated structure. *Biomaterials* 2005; 26(6):5276–84.
16. Güngörmüş M, Kaya O. Evaluation of the effect of heterologous type I collagen on healing of bone defects. *J Oral Maxillofac Surg* 2002; 60(5):541–5.
17. Ignatius A, Blessing H, Liedert A, Schmidt C, Neidlinger-Wilke C, Kaspar D, and others. Tissue engineering of bone: effects of mechanical strain on osteoblastic cells in type I collagen matrices. *Biomaterials* 2005; 26(3):311–8.
18. Lu JX, Gallur A, Flautre B, Anselme K, Descamps M, Thierry B, and other. Comparative study of tissue reactions to calcium phosphate ceramics among cancellous, cortical, and medullar bone sites in rabbits. *J Biomed Mater Res* 1998; 42(3):357–67.
19. Fujita R, Yokoyama A, Nodasaka Y, Kohgo T, Kawasaki T. Ultrastructure of ceramic-bone interface using hydroxyapatite and beta-tricalcium phosphate ceramics and replacement mechanism of beta-tricalcium phosphate in bone. *Tissue Cell* 2003; 35(6):427–40.
20. Pioletti DP, Takei H, Lin T, van Landuyt P, Ma QJ, Kwon SY, and others. The effects of calcium phosphate cement particles on osteoblast functions. *Biomaterials* 2000; 21(11):1103–14.