

Evaluation of a Suspicious Oral Mucosal Lesion

P. Michele Williams, BSN, DMD, FRCD(C); Catherine F. Poh, DDS, PhD, FRCD(C); Allan J. Hovan, DMD, MSD, FRCD(C); Samson Ng, DDS, MSc, FRCD(C); Miriam P. Rosin, BSc, PhD

Auteure-ressource

Dre Williams

Courriel :

mwill@bccancer.bc.ca



SOMMAIRE

Les dentistes qui sont confrontés à un changement dans la muqueuse buccale d'un patient doivent décider si cette anomalie nécessite une investigation plus poussée. Dans le présent article, nous décrivons une approche systématique à l'évaluation des conditions de la muqueuse buccale qui sont considérées comme étant des lésions pré-malignes ou un début de cancer. Cette approche, comprenant une anamnèse complète, un examen clinique progressif (y compris l'utilisation d'outils de visualisation auxiliaires), des tests de diagnostic et la pose du diagnostic, est employée systématiquement dans les cliniques affiliées au Programme de prévention du cancer de la bouche de la Colombie-Britannique (BC OPP) et elle est recommandée aux dentistes dans leur pratique quotidienne.

Pour les citations, la version définitive de cet article est la version électronique : www.cda-adc.ca/jcda/vol-74/issue-3/275.html

Over the course of a typical practice day, a dentist will examine the mouths of many patients. On occasion, a change in the oral mucosa will be detected. The challenge is to decide whether the abnormality requires further investigation. If the answer is yes, the British Columbia Oral Cancer Prevention Program (BC OCPP) team recommends a systematic approach to the evaluation of the lesion that includes methodical gathering of background information and a step-by-step clinical examination (**Box 1**). A methodical process is important given that many mucosal conditions have a similar appearance. A “quick look” provides insufficient information and may result in misdiagnosis and improper care. Although the recommended approach is appropriate for use in evaluating any mucosal condition, the focus of this article will be limited to one that can be used to evaluate the lesions that are more likely to be premalignant or an early cancer.

Approach

The diagnostic process begins with a history that includes a review of the patient's chief complaint followed by completion of a thorough medical history. Once this has been obtained, a comprehensive clinical examination including extraoral, intraoral and mucosal lesion assessments should be completed. Only then can a diagnosis or a decision about the need for further investigation be rendered and appropriate decisions made regarding patient care.

History of the Current Illness

When inquiring about the condition of concern, the dentist needs to have an appreciation of the symptom profile. In some situations, the patient will have no complaints. If symptoms are present, then information about onset, location, intensity, frequency and duration should be obtained. If the condition has been present for any length of time, inquire about changes

Box 1 A systematic approach to the assessment of a suspicious oral mucosal lesion

1.	History of current illness <ul style="list-style-type: none"> onset, location, intensity, frequency, duration aggravating and/or relieving variables better, unchanged or worse over time
2.	Medical, tobacco and alcohol history <ul style="list-style-type: none"> medical conditions medications and allergies tobacco and alcohol (type, frequency, duration)
3.	Clinical examination <ul style="list-style-type: none"> extraoral examination intraoral examination lesion inspection (adjunctive visual tools such as toluidine blue and direct fluorescence)
4.	Differential diagnosis
5.	Diagnostic tests <ul style="list-style-type: none"> biopsy
6.	Definitive diagnosis
7.	Suggested management

that might have occurred — has the symptom improved, remained unchanged or worsened over time? Identifying significant aggravating or relieving variables may also be helpful. It is important to remember that most oral premalignant lesions or early cancers have few if any symptoms. Persistent oral sensitivity or a sense of mucosal “roughness” may be warning signs. If a lesion has persisted over time or if it has become larger or more symptomatic, it is of concern and warrants prompt and thorough investigation.

Medical, Tobacco and Alcohol History

A comprehensive medical history that includes attention to tobacco and alcohol use should be obtained at the time of all new patient examinations and updated at general dental recall. Remember that 75% of oral cancer patients are regular users of tobacco or alcohol, which are conventional risk factors. Information to be collected should include habit type, frequency and duration. More detailed information about these risk factors is included elsewhere in this special issue.¹

Review of the medical history should include a list of current medications, as certain drugs may cause oral tissue changes with characteristics similar to premalignant or early cancer changes. (For a detailed list of medication-associated mucosal changes, see Neville and others.²) Notable examples of such drugs include immunosuppressive, anti-inflammatory and antihypertensive medications. Also, steroids delivered in inhaler, topical or oral form and other

medications that dry the mouth increase risk of development of oral candidiasis, which often appears as whitish, nonadherent plaques.

Finally, information regarding previous cancer history (type and associated treatment) and any known dermatologic conditions should be gathered. Certain dermatologic conditions, such as lichen planus, can manifest cutaneously and as white lesions intraorally.

Clinical Examination

The clinical examination should always include extraoral and intraoral components.³ If a mucosal lesion is identified, a systematic approach to lesion assessment is recommended.

Extraoral Examination

Complete the extraoral examination first. This includes inspection of the head and neck region for asymmetry or swelling. Palpate the submental, submandibular, cervical and supraclavicular regions paying particular attention to size, number, tenderness and mobility of lymph nodes. A bimanual approach is recommended as it enhances the examiner’s ability to appreciate the characteristics of any mass and to make comparisons with the contralateral side. This is of particular importance in the neck where some lymph nodes lie under the muscles. In patients who have had a prior dental infection or surgical procedure in the head and neck region, it is common to find small, painless, freely mobile residual lymph nodes. However, if a lymph node is enlarged (i.e., > 1 cm in diameter) and palpably firm or fixed to adjacent structures, referral or further investigation is indicated. To complete the extraoral examination, inspect and palpate the lips and perioral tissues for abnormalities.

Intraoral Examination

Systematically inspect and palpate all oral soft tissues, as oral cancer can develop at any anatomical site. Particular attention should be given to high-risk sites, which include the lateral and ventral aspects of the tongue, floor of mouth and the soft palate complex.

Lesion Inspection

If a mucosal lesion is identified, additional attention to its characteristics is recommended. Oral premalignant lesions and early oral cancers are quite varied in appearance (Fig. 1); clinical characteristics can be used to help raise the level of suspicion that a lesion may be premalignant or an early cancer. However, remember that a biopsy of the lesion is required to establish a definitive diagnosis, as seemingly benign lesions may still pose a risk. Mucosal lesions can be predominantly white or red and have variable thickness and texture. A speckled red and white appearance, nonhealing ulceration or induration should signal a priority need for biopsy or referral.

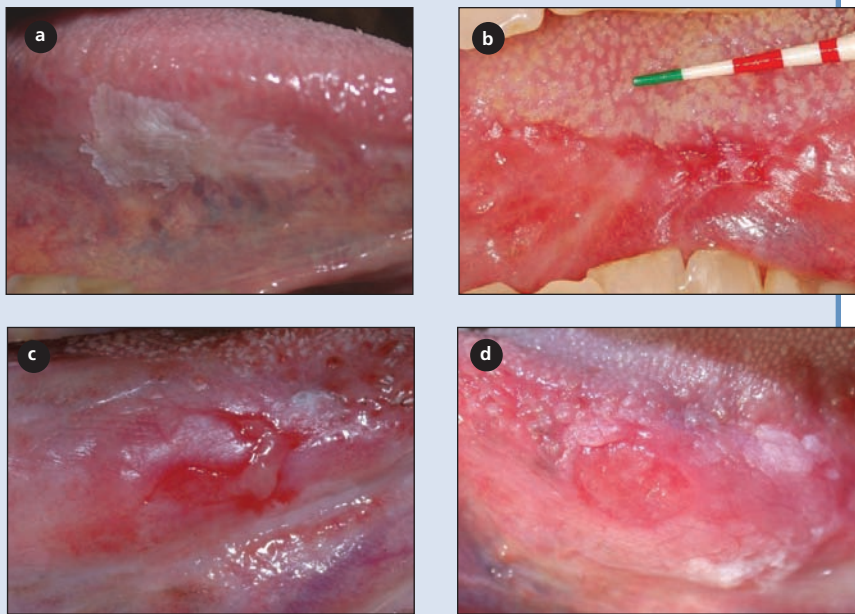


Figure 1: The varied appearance of oral premalignant lesions and early oral cancer on the lateral aspect of the tongue. Images **a** to **d** represent lesions of increasing risk based on clinical features: **(a)** a smooth, white, discrete, homogeneous lesion; **(b)** a predominantly red, diffuse, granular lesion; **(c)** a diffuse, red ulcerated lesion; **(d)** a diffuse, raised, speckled, indurated lesion. At biopsy, these lesions were found to be mild dysplasia, moderate to severe dysplasia, carcinoma in situ and squamous cell carcinoma, respectively.

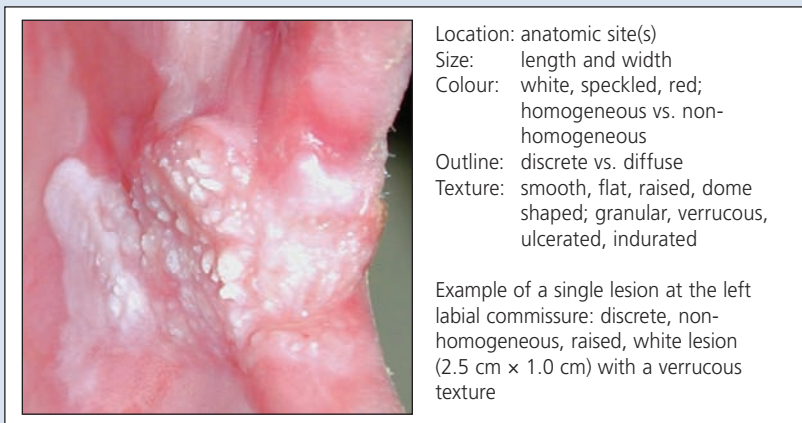


Figure 2 summarizes the terminology and characteristics commonly used to describe lesions suspected of being premalignant or early cancer: location, size, colour, outline and texture. A leukoplakia is a white patch that cannot be rubbed off and cannot be characterized clinically or histologically as any other lesion.⁴ Leukoplakias can be classified as homogeneous or nonhomogeneous. Homogeneous leukoplakias are white lesions that are uniform in both colour and texture. They are predominantly white and have a smooth, thin or slightly wrinkled texture. Nonhomogeneous leukoplakias usually have a rough (leathery or granular) or

speckled surface. If a nonhomogeneous leukoplakia contains a red component, it is called an erythroleukoplakia. In general, homogeneous leukoplakias are believed to carry a lower risk of transforming into cancer than non-homogeneous leukoplakias. Erythroplakias, which are predominantly red lesions of the oral mucosa, carry the highest risk.

The outline or borders of the lesion should also be considered. Diffuse lesions, with irregular or ill-defined edges are more worrisome than discrete lesions. The presence of multiple lesions is considered more worrisome than a solitary lesion. As mentioned, the presence of a mucosal lesion at selected anatomic sites (lateral and ventral aspects of the tongue, floor of mouth and the soft palate complex) is of greater concern. Finally, leukoplakia size is also correlated with cancer risk, although the cutoff size for risk level remains speculative. Most oral lesions are < 2 cm and have a low cancer risk. **Figure 3** summarizes the key clinical features of high-risk and low-risk mucosal lesions.

The details of a clinical lesion can be best captured in a high-resolution clinical photo. In BC OCPP-affiliated clinics, these images are obtained at each patient visit. Such documentation allows the dentist to note changes in the clinical appearance of the lesion over time, an important determinant of risk. **Figure 4** shows changes in a premalignant lesion that progressed to cancer over time. Completion of a lesion-tracking sheet⁵ is a simple way to enter this information into the patient's chart, where it is then readily accessible to all care providers.

Differential Diagnosis

Oral mucosal lesions can usually be simply grouped into 5 categories, known as the 5 Is: inherent (congenital or hereditary, e.g., white sponge nevus), inflammation (e.g., oral lichen planus, some variants of geographic tongue), infection (e.g., oral candidiasis), iatrogenic (e.g., drug-induced lichenoid reaction, frictional hyperkeratosis) and idiopathic (e.g., oral premalignant lesion or neoplasm). The first 4 categories must be ruled out before classifying a lesion as a leukoplakia or an erythroplakia. An atlas of clinical lesions is a useful office reference.

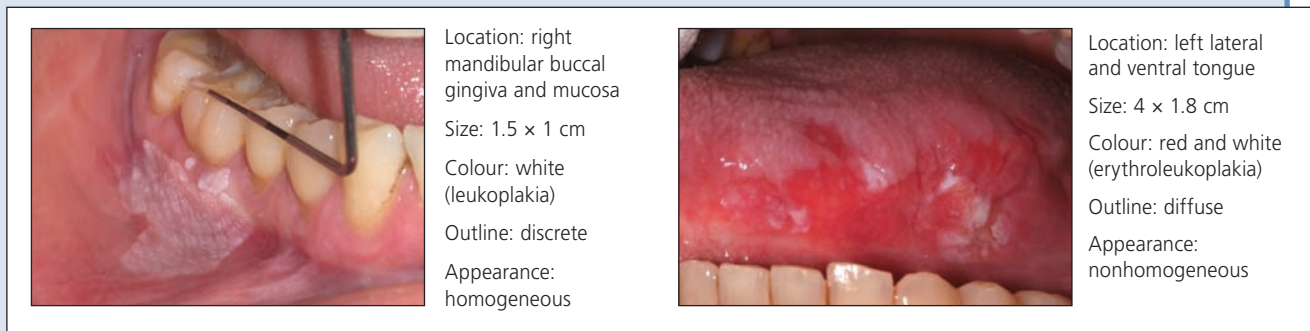


Figure 3: Key clinical features that differentiate low-risk oral premalignant lesions (left) and high-risk premalignant lesions (right). The lesion on the right is especially worrisome; however, both lesions require biopsy as clinical assessment is not definitive.

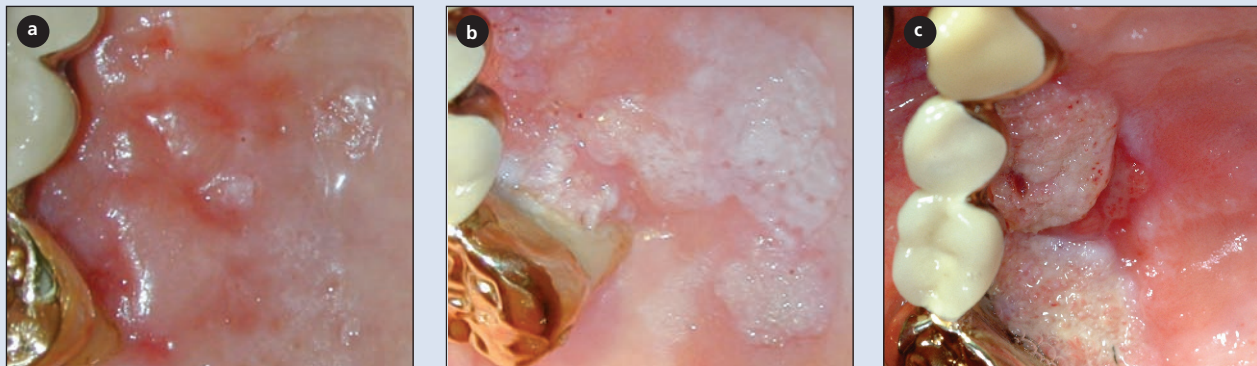


Figure 4: Changes in a clinical lesion on the right hard palate over 4 years. At the time of biopsy (November 1999), diagnosis was mild dysplasia (a); in July 2001, moderate dysplasia (b); and in March 2003, verrucous carcinoma (c).

Adjunctive Visual Tools

Adjunctive visual tools can enhance contrast between the lesion and the adjacent normal oral tissue. The BC OCPP team is currently using 2 approaches to lesion visualization: assessment of toluidine blue stain retention and, more recently, direct fluorescence visualization. The latter technique relies on tissue optics to assess mucosal lesions using a simple hand-held device. In contrast to toluidine blue (which stains nucleophilic tissue components, primarily DNA), tissue fluorescence visualization detects a complex interplay of alteration to tissue structure and biochemistry that has been associated with premalignant disease and cancer at several sites. The BC OCPP clinical team routinely uses these approaches in tandem at its affiliated referral clinics. Use in community settings is being evaluated.

Although toluidine blue has an established validity in the detection of oral cancers, its value in identifying oral premalignant lesions is less well defined. In BC OCPP-affiliated clinics, virtually all oral premalignant lesions with high-grade dysplasia (severe dysplasia, carcinoma in situ) show positive retention of the stain. Of equal importance,

data from an ongoing longitudinal study demonstrate a strong correlation between retention of the stain by leukoplakias and the presence of molecular clones associated with high cancer risk. Staining of an oral premalignant lesion is associated with a 6-fold elevation in risk of the lesion progressing to cancer.⁶

Tissue optics using direct fluorescence visualization reveals valuable additional information. Fluorescence visualization detects virtually all high-grade oral premalignant lesions and cancers and may play a critical role in the delineation of surgical margins and follow-up after treatment.⁷⁻⁹

Figure 5 illustrates the potential value of combining these approaches to visualize oral lesions. Alone, these techniques are not diagnostic; however, in BC OCPP-affiliated clinics, they have been shown to enhance lesion characteristics, identify satellite or clinically nonapparent lesion sites and assist in biopsy site selection and timing of the biopsy. These techniques are complementary to and do not replace the comprehensive history and conventional visual and manual head, neck and oral examination. Good clinical judgment remains key in all circumstances.^{10,11}

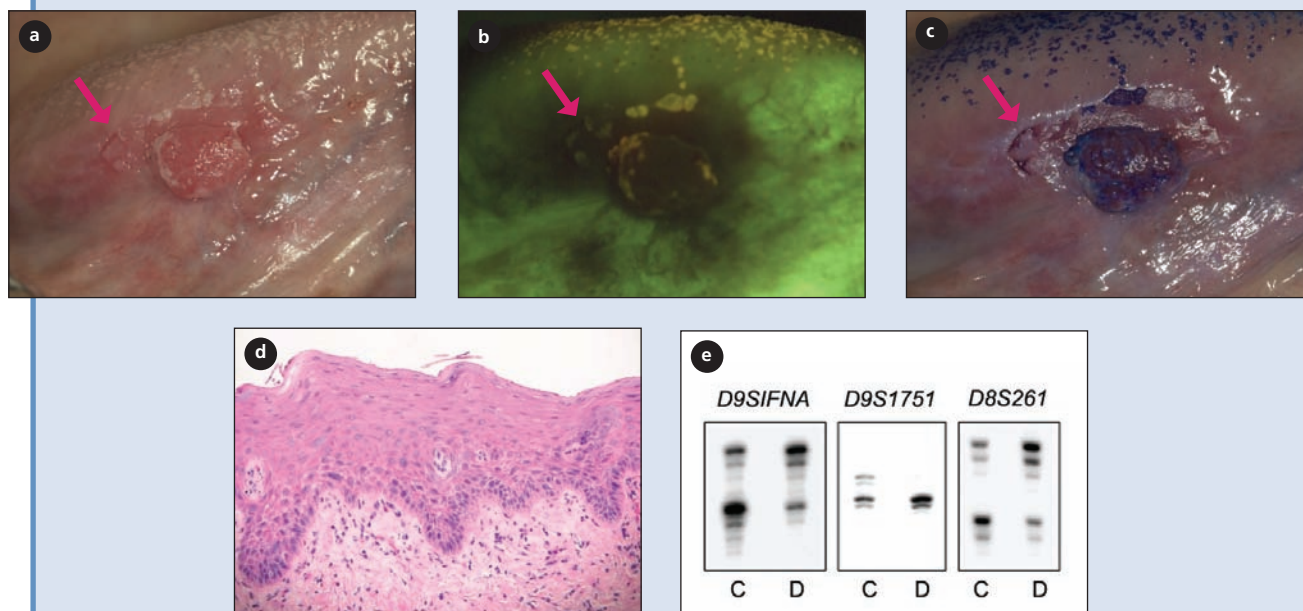


Figure 5: Visualization of a diffuse, nodular erythroleukoplakia at the right lateral ventral tongue in a 52-year-old former smoker. **(a)** The arrow indicates a clinically undifferentiated area posterior to the nodule. **(b)** Direct fluorescence visualization (dark brown area within the normal green autofluorescent background) shows a wider region of change. **(c)** Toluidine blue staining identifies an ill-defined area in addition to the posterior nodular area. **(d)** Histological preparation of biopsy sample from the area marked with the arrow reveals moderate to severe dysplasia. **(e)** Microsatellite analysis shows high-risk molecular pattern of alteration within the biopsy area.

Diagnostic Biopsy for Definitive Diagnosis

Once the dentist has completed a thorough history and comprehensive clinical examination, he or she will need to decide which mucosal lesions can appropriately be monitored and which require biopsy. We do our patients a great disservice and burden the health care system unnecessarily if we order a biopsy on every mucosal abnormality seen.

During an oral cancer screening examination, if a suspicious mucosal lesion persists for more than 3 weeks following removal of local irritants, such as trauma, infection or inflammation, diagnostic biopsy(ies) or referral to an oral health care provider with expertise in the evaluation and management of premalignant or potentially malignant conditions is recommended. Tissue biopsy remains the gold standard for diagnosing an oral premalignant lesion or oral cancer. A carefully selected, performed and interpreted biopsy is critical in rendering an accurate diagnosis. Additional information on the biopsy procedure and interpretation of results is available in this special issue.¹²

Appropriate management decisions are made through the described approach to the evaluation of any mucosal lesion. A definitive diagnosis is an opinion based on critical analysis of all pertinent information obtained. Once the practitioner arrives at this conclusion, a decision about optimum patient care can be made.

Conclusion

In this paper, we describe a methodical approach to the assessment of oral mucosal conditions that are thought likely to be premalignant or an early cancer. This approach has been standardized throughout all BC OCPP-affiliated clinics. Members meet regularly to exchange ideas, update protocols, solve problems and discuss new program developments. Teamwork, including the integration of various disciplines and institutes, has been critical in the evolution of the oral cancer screening program. It ensures seamless patient management from the mildest premalignant change to frank malignancy. We hope that you will consider our resources and approach and adapt then for use in your practice. Together we can make a difference! ♦

THE AUTHORS

Acknowledgments: The authors would like to thank the following people for their long-term support of the BC OCPP team: Ms. Alisa Kami, Dr. Pam Gardner, Dr. Chris Zed, Ms. Denise Laronde, the certified dental assistants of the BC Cancer Agency and, most important, the valued patients who participate in the clinical program.

Dr. Williams is an oral medicine specialist and clinical professor, dentistry, University of British Columbia and oral medicine leader, BC Oral Cancer Prevention Program and department of oral oncology, BC Cancer Agency/Cancer Research Centre, Vancouver, British Columbia.

Dr. Poh is an oral pathologist and assistant professor, dentistry, University of British Columbia, an oral pathologist at BC Oral Biopsy Service, and

outreach leader, BC Oral Cancer Prevention Program, BC Cancer Agency/Cancer Research Centre, Vancouver, British Columbia.

Dr. Hovan is an oral medicine specialist, clinical assistant professor, dentistry, University of British Columbia and provincial practice leader, department of oral oncology, BC Cancer Agency, Vancouver, British Columbia.

Dr. Ng is a specialist in oral medicine/pathology and clinical assistant professor, dentistry, University of British Columbia and director, Oral Care for Medically Complex Patients, Dentistry, Vancouver General Hospital, Vancouver, British Columbia.

Dr. Rosin is a translational scientist and professor, applied science, Simon Fraser University, medicine, University of British Columbia and director, BC Oral Cancer Prevention Program, BC Cancer Agency/Cancer Research Centre, Vancouver, British Columbia.

Correspondence to: Dr. P. Michele Williams, Division of Oral Oncology, BC Cancer Agency, 600 West 10th Ave., Vancouver BC V5Z 4E6

The authors have no declared financial interests.

This article has been peer reviewed.

References

1. Laronde DM, Hislop TG, Elwood JM, Rosin MP. Oral cancer: just the facts. *J Can Dent Assoc* 2008; 74(3):269–72.
2. Neville BW, Damm DD, Allen CM, Bouquout JE. Allergic mucosal reactions to systemic drug administration. In: Oral and maxillofacial pathology. Philadelphia: WB Saunders; 2002. p. 300–2.
3. Poh CF, Williams PM, Zhang L, Rosin MP. Heads up! A call for dentists to screen for oral cancer. *J Can Dent Assoc* 2006; 72(5):413–6.
4. Axell T, Pindborg JJ, Smith CJ, Waal van der I. Oral white lesion with special reference to precancerous and tobacco-related lesions: conclusions of an international symposium held in Uppsala, Sweden, May 18–21 1994. International Collaborative Group on Oral White Lesions. *J Oral Pathol Med* 1986; 25(2):49–54.
5. Lesion-tracking sheet. Vancouver: BC Cancer Agency; 2008. Available: www.orcanet.ca/clinical (click Clinical Services, then Downloadable Forms).
6. Zhang L, Williams M, Poh CF, Laronde D, Epstein JB, Durham S, and others. Toluidine blue staining identifies high-risk primary oral premalignant lesions with poor outcome. *Cancer Res* 2005; 65(17):8017–21.
7. Lane PM, Gilhuly T, Whitehead PD, Zeng H, Poh CF, Ng S, and others. Simple device for the direct visualization of oral-cavity tissue fluorescence. *J Biomed Optics* 2006; 11(2):024006.
8. Poh CF, Zhang L, Anderson DW, Durham JS, Williams PM, Priddy RW, and others. Fluorescence visualization detection of field alterations in tumor margins of oral cancer patients. *Clin Cancer Res* 2006; 15(22):6716–22.
9. Poh CF, Ng SP, Williams PM, Zhang L, Laronde DM, Lane P, and others. Direct fluorescence visualization of clinically occult high-risk oral premalignant disease using a simple hand-held device. *Head Neck* 2007; 29(1):71–6.
10. Rosin MP, Poh CF, Elwood JM, Williams PM, Gallagher R, MacAulay C, and others. New hope for an oral cancer solution: together we can make a difference. *J Can Dent Assoc* 2008; 74(3):261–6.
11. The Early Detection of Oral Cancer Working Group. Guideline for the early detection of oral cancer in British Columbia 2008. BC Oral Cancer Prevention Program of the BC Cancer Agency. March 2008. Available: www.cdsbc.org/pdf/OC_Guideline_Final_2008.pdf.
12. Poh CF, Ng S, Berean KW, Williams PM, Rosin MP, Zhang L. Biopsy and histopathologic diagnosis of oral premalignant and malignant lesions. *J Can Dent Assoc* 2008; 74(3):283–8.