

Reconstruction of 10 Major Mandibular Defects Using Bioimplants Containing BMP-7

Cameron M.L. Clokie, DDS, PhD, FRCD(C);
George K.B. Sándor, MD, DDS, PhD, FRCD(C), FRCSC, FACS

Auteur-ressource

Dr Clokie
Courriel : c.clokie@dentistry.utoronto.ca



SOMMAIRE

Objectif : Les limites et la morbidité associées aux greffes osseuses autogènes ont stimulé les recherches sur des substituts osseux et des bioimplants donnant des résultats prévisibles. Une nouvelle méthode de reconstruction a été testée dans cette série de cas.

Matériel et méthodologie : Cette étude a porté sur 10 patients qui présentaient des défauts mandibulaires importants, consécutifs à la résection d'améloblastomes confirmés par biopsie ou d'une ostéomyélite dans le corps ou la branche montante du maxillaire inférieur. Des plaques de reconstruction rigides ont été utilisées pour tenir en place et maintenir en bonne position les segments mandibulaires restants. Les défauts ont été comblés avec un bioimplant contenant la protéine morphogénétique osseuse 7 (BMP-7, bone morphogenic protein-7) dans une matrice osseuse déminéralisée (DBM, demineralized bone matrix) en suspension dans un milieu en phase inversée, de manière à favoriser la libération continue de BMP.

Résultats : Chez les 10 patients, les suites opératoires ont été sans incidents. Dans tous les cas, la radiographie a confirmé la formation d'os mandibulaire. Après un an, la reconstruction fonctionnelle et esthétique du maxillaire inférieur était complète.

Conclusion : Les bioimplants contenant la BMP-7 dans une DBM en suspension dans un milieu en phase inversée ont permis de restaurer avec succès d'importantes anomalies mandibulaires dans des zones non irradiées, chez ce groupe de 10 patients.

Pour les citations, la version définitive de cet article est la version électronique : www.cda-adc.ca/jcda/vol-74/issue-1/67.html

Autogenous bone grafting is considered to be the gold standard for repair of most osseous defects,^{1,2} including those in the maxillofacial region. However, there are limits to the amount of bone that can be harvested from a patient's skeleton. Autogenous bone grafts may also increase the risk of morbidity — such as infection, pain and length of hospital stay — associated with the second harvest site.^{3,4} As a result, there has been recent interest in the development of new grafting materials using allogeneic, xenogeneic and synthetic bioimplants for reconstructive bony procedures. Numerous studies have compared the effectiveness of these alternatives as potential replacements for autogenous bone grafts.⁵⁻⁹

Allogeneic bone, such as demineralized bone matrix (DBM), harvested from one individual and transferred to another of the same species was first used to reconstruct skull defects in dogs more than 100 years ago.^{10,11} It was not until Dr. Marshall Urist, a University of California clinical-scientist, reported the results of years of research in his 1965 landmark article that researchers and clinicians seriously considered demineralized allogeneic bone as a potential bioimplant for osseous repair.^{12,13} However, because allogeneic bone is harvested from an individual other than the patient, concerns exist about the potential for disease transmission. As a result, allogeneic bone is less than ideal as a grafting material.

Table 1 Mandibular defects reconstructed using a combination of BMP-7 and DBM putty

Patient's age (years)	Sex	Description of lesion	Size of lesion (cm)	Site of resection	IA nerve
40	Male	Ameloblastoma	9	Ramus and body of the mandible	Spared
44	Female	Ameloblastoma	5	Body of the mandible	Resected
55	Female	Ameloblastoma	3	Body of the mandible	Resected
18	Male	Ameloblastoma	3	Ramus of the mandible	Spared
61	Female	Ameloblastoma	7	Ramus and body of the mandible	Resected
37	Female	Ameloblastoma	6	Anterior mandible	N/A
53	Male	Osteomyelitis	5	Body of the mandible	Spared
28	Female	Ameloblastoma	5	Body of the mandible	Spared
73	Male	Ameloblastoma	5	Body of the mandible	Spared
22	Female	Ameloblastoma	7	Ramus and body of the mandible	Resected

BMP-7 = bone morphogenetic protein-7; DBM = demineralized bone matrix; IA nerve = inferior alveolar nerve; N/A = not applicable.

Bone Morphogenetic Protein

With the constraints associated with both autogenous and allogeneic bone, scientists began to focus on the fabrication of completely synthetic bioimplants. By the late 1980s, the active factor responsible for the induction of bone was identified: bone morphogenetic protein (BMP). BMP replicates the embryonic induction of bone formation.¹⁴ It can induce pluripotent mesenchymal stem cells to differentiate into bone-forming osteoblasts. BMP-2, -4 and -7 have been shown to stimulate *de novo*, *in vitro* and *in vivo* bone formation in various animal models. Many other BMPs have been isolated and, with the exception of BMP-1, they are all members of the transforming growth factor β (TGF- β) superfamily.¹⁵ In the early 1990s, it became possible to fabricate these proteins synthetically using recombinant technology and, by 2006, this finally led to the development of OP-1 (BMP-7; Stryker Biotech, Hopkinton, Mass.) and Infuse (BMP-2; Medtronic, Fridley, Minn.), both of which are now available for clinical use.¹⁶

One of the greatest challenges in the clinical application of BMP has been the identification of an acceptable carrier. Investigation of various delivery agents has identified those that are more effective for the optimal clinical application of BMP.¹⁷⁻²¹ Over the past decade, our group has explored the use of a reverse-phase medium as a carrier for BMP. While others have struggled to achieve acceptable clinical results, we achieved our first successful BMP bioimplant in 1999.²² Since then, we have reconstructed 10 human mandibular defects using bioimplants consisting of OP-1 (BMP-7) and DynaGraft Putty (DBM in a reverse-phase medium; IsoTis, Irvine, Calif.). In this article, we describe the technique used to reconstruct major mandibular defects in these patients, explore the outcomes and discuss future directions.

Materials and Methods

All 10 patients in our case series were diagnosed with a biopsy-proven ameloblastoma or osteomyelitis in the body or ramus of their mandible (**Table 1**). There were 6 females and 4 males. Ages ranged from 18 to 73 years with a mean of 43.1 years. In 3 of these patients, an intraoral approach was used to gain access to the lesion. For these patients, the inferior alveolar nerve was preserved intact by carefully dissecting it from the mandible before the lesion was excised and the peripheral resection was performed, preserving the inferior border of the mandible. For the remaining 7 patients, a traditional extraoral submandibular approach was used to expose the body and ramus of the mandible (**Figs. 1a-d**). A 2.4-mm locking reconstruction plate (Biomet Microfixation Inc., Jacksonville, Fla.) was adapted to the affected hemimandible (**Figs. 2a, b**), ensuring that at least 3 fixation holes were available at each end of the lesion to attach the plate. The lesion was then carefully excised from the mandible ensuring that margins of at least 1 cm of normal tissue were achieved. This was confirmed by examining postoperative frozen sections of the bone marrow and adjacent soft tissue.

In all cases, the BMP bioimplant was created by manually mixing BMP-7 (OP-1) with 10 mL of DBM in a reverse-phase medium (DynaGraft Putty), then molding it to the shape of the resected segment of mandible (**Figs. 3a-d**). The implant was inserted into the mandibular defect and the muscular sling surrounding the mandible was re-approximated to ensure complete coverage of the bioimplant (**Figs. 4a-d**). The superficial tissues were then closed in a traditional fashion. Patients were carefully followed, both clinically and radiographically, to ensure proper integration of the bioimplant with the mandible.

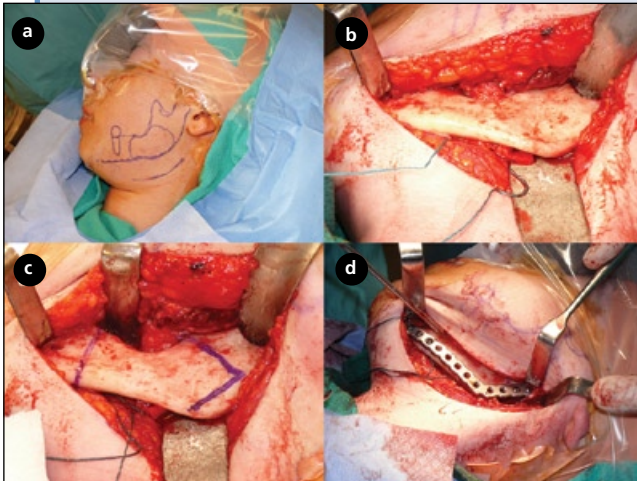


Figure 1: (a) Left lateral facial view of the patient prepared for the surgical procedure. The outline of the mandible including the lesion is marked on the patient's cheek. The proposed incision is outlined immediately below the inferior border of the mandible. (b) Using the submandibular approach, the entire left hemimandible is exposed. (c) A surgical marker is used to identify the proposed mandibular resection margins. (d) The mandibular reconstruction plate is adapted to the left lateral aspect of the mandible before mandibular resection.

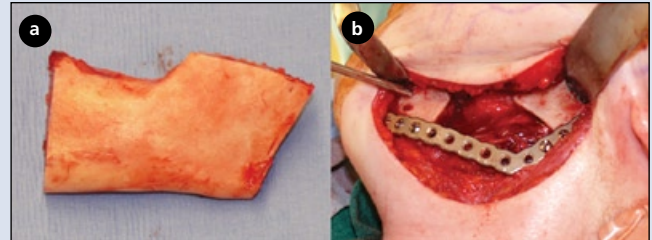


Figure 2: (a) The resected aspect of the left mandibular body and mandible containing the lesion. (b) The resultant mandibular defect following resection of the lesion. The reconstruction plate restores the posterior and inferior border of the mandible.

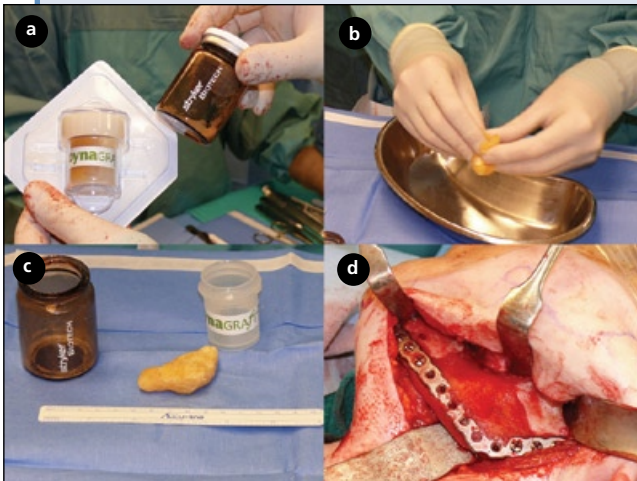


Figure 3: (a) The 2 commercially available materials required to fabricate the bone morphogenetic protein (BMP) bioimplant. (b) The 2 products are manually mixed to create the BMP bioimplant. (c) The BMP bioimplant is molded to the form of the mandibular defect. (d) The mandibular defect reconstructed with the BMP bioimplant.

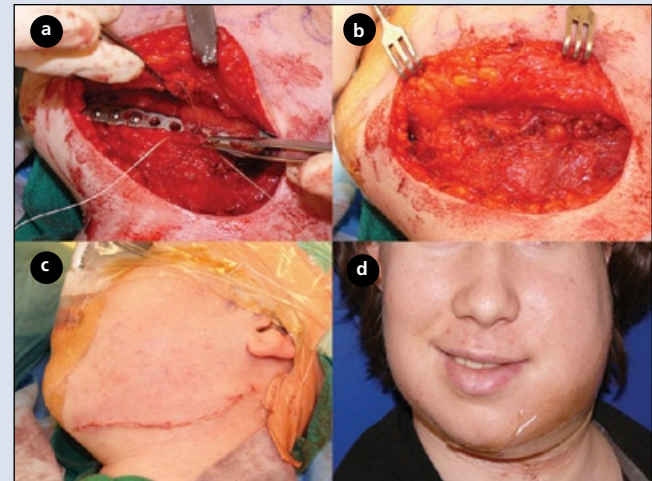


Figure 4: (a) The muscular sling, rich in satellite stem cells, is carefully re-approximated around the BMP bioimplant. (b) The muscular sling completely encompasses the bioimplant. (c) The incision is closed to restore the form of the lateral face. (d) One week after surgery, swelling on the left lateral face is indurated and, for patients receiving BMP bioimplants, does not resolve for > 4 weeks postoperatively.

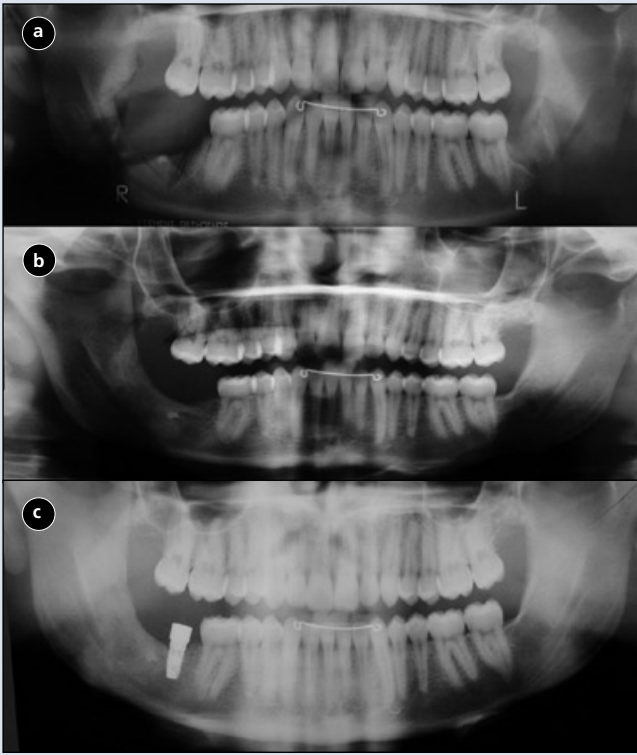


Figure 5: (a) Panoramic radiograph demonstrating a defect in the right posterior mandible of a 19-year-old man whose ameloblastoma was removed using an intraoral approach in the right retromolar region. (b) A year after reconstruction of the right posterior mandible using a BMP bioimplant, complete restoration of the region of the defect is seen. (c) Four months following placement of a dental implant into a reconstructed region of the right posterior mandible, the implant has successfully integrated into the newly regenerated bone.

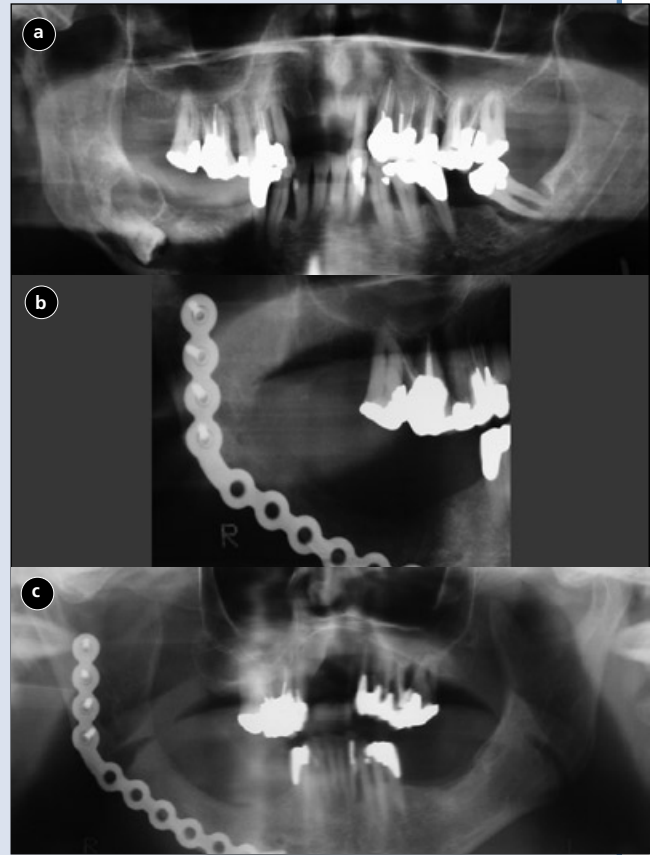


Figure 6: (a) Panoramic radiograph of a 62-year-old man demonstrating an impacted tooth 48 with an associated multi-locular, radiolucent lesion (ameloblastoma). (b) Panoramic radiograph 9 months following mandibular resection and reconstruction with a BMP bioimplant shows limited evidence of bone formation. (c) One year following reconstruction of the mandibular defect, this panorex revealed complete regeneration of the mandible.

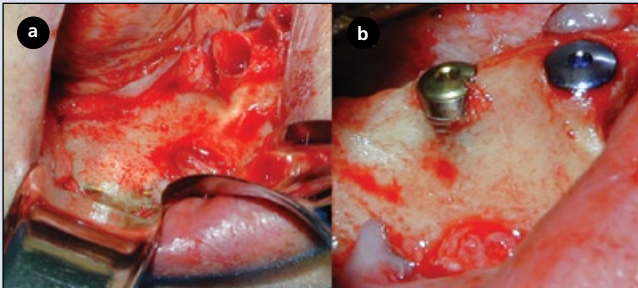


Figure 7: (a) During dental implant placement, BMP-regenerated bone was exposed distal to the mental nerve. It was difficult to differentiate between newly regenerated bone and unresected bone anterior to the mental nerve. (b) A dental implant placed into bone that was regenerated by the BMP bioimplant.

Results

All patients were followed for a minimum of 9 months and all have demonstrated clinical and radiographic evidence of restoration of mandibular continuity (Figs. 5a–c and 6a) with no complications. Of the 10 patients, 4 have had dental implants placed in their reconstructed mandibles (Figs. 5a–c). In 1 case, the implants were placed 8 years following the reconstructive surgery. It is important to note that, in all 10 patients, bone formation was consistently first appreciated on clinical examination during manual manipulation of the reconstructed segment; radiographic evidence of bone formation was not fully evident until 1 year after the reconstructive procedure (Figs. 6b and 6c). However, at 1 year following reconstruction, it was difficult to differentiate between bone that was formed from the BMP bioimplant and native preexisting bone (Figs. 7a, b).

Discussion

Successful reconstruction of large mandibular defects must ensure the restoration of mandibular height and width, which are essential for functional prosthetic rehabilitation. Proper reconstruction will also ensure that appropriate facial form is recreated. For the patients presented in this case series, we were able to meet these objectives. Just as important, patient morbidity and overall cost to the health care system, including length of hospital stay, were significantly reduced.

Although autogenous bone grafting remains the “gold standard” for these clinical scenarios, it has several limitations. Because the number of donor sites available in the human skeleton is limited, only a finite quantity of bone can be harvested.³ Furthermore, the surgical morbidity (8%–10%), including pain, paresthesia, anesthesia and infection, associated with autogenous bone harvesting may be greater than that experienced at the primary surgical site. In addition, the quality of harvested bone may also vary depending on the patient and the site of procurement.²³

The synthetic bone used for these patients overcomes the problems associated with autogenous bone grafting. Ideally, a bone substitute should mimic the healing of autogenous bone and ultimately be resorbed and completely replaced by host bone. This was seen with the BMP bioimplants presented in this case series. Successful reconstruction of 10 major mandibular defects was achieved using a BMP bioimplant consisting of recombinant BMP-7 delivered by DBM suspended in a reverse-phase medium. Both functional and esthetic results were comparable if not superior to those achieved with autogenous bone grafting. In addition, the procedure saved health care system costs as a result of decreased operating room time and length of hospital stay.

The future of bone reconstruction for oral and maxillofacial rehabilitation has significantly advanced over the past decade with our improved understanding of bone healing and the discovery of growth-inducing factors, such as BMP. As we develop technologies that will facilitate the delivery of

these agents, making them more clinically manageable and cost effective, we expect them to have a significant impact on the future of reconstructive dentistry. ♦

THE AUTHORS



Dr. Clokie is professor and head, discipline of oral and maxillofacial surgery, faculty of dentistry, and director, Orthobiologics Research Laboratory, University of Toronto, Toronto, Ontario.



Dr. Sándor is clinical director, graduate program in oral and maxillofacial surgery and anesthesia, Mount Sinai Hospital; coordinator, pediatric oral and maxillofacial surgery, The Hospital for Sick Children and Bloorview Kids Rehab; professor of oral and maxillofacial surgery, University of Toronto, Toronto, Ontario; professor, Regea Institute for Regenerative Medicine, University of Tampere, Tampere, Finland; and docent in oral and maxillofacial surgery, University of Oulu, Oulu, Finland.

Correspondence to: Dr. C.M.L. Clokie, Faculty of Dentistry, 124 Edward St., Toronto, ON M5G 1G6.

The authors have no declared financial interests in any company manufacturing the types of products mentioned in this article.

This article has been peer reviewed.

References

- Jensen OT, Shulman LB, Block MS, Iacono VJ. Report of the Sinus Consensus Conference of 1996. *Int J Oral Maxillofac Implants* 1998; 13 Suppl:11–45.
- Marx RE. Clinical application of bone biology to mandibular and maxillary reconstruction. *Clin Plast Surg* 1994; 21(3):377–92.
- Lane JM, Yasko AW, Tomin E, Cole BJ, Browne M, Turek T, and other. Bone marrow and recombinant human bone morphogenetic protein-2 in osseous repair. *Clin Orthop Relat Res* 1999; 361:216–27.
- Sándor GK, Rittenberg BN, Clokie CM, Caminiti MF. Clinical success in harvesting autogenous bone using a minimally invasive trephine. *J Oral Maxillofac Surg* 2003; 61(2):164–8.
- Burchardt H. The biology of bone graft repair. *Clin Orthop Relat Res* 1983; 174:28–42.
- Connolly J, Guse R, Lippiello L, Dehne R. Development of an osteogenic bone-marrow preparation. *J Bone Joint Surg Am* 1989; 71(5):684–91.
- Burwell RG. Studies in the transplantation of bone. VII. The fresh composite homograft-autograft of cancellous bone; an analysis of factors leading to osteogenesis in marrow transplants and in marrow-containing bone grafts. *J Bone Joint Surg Br* 1964; 46:110–40.
- Bolander ME, Balian G. The use of demineralized bone matrix in the repair of segmental defects. Augmentation with extracted matrix proteins and a comparison with autologous grafts. *J Bone Joint Surg Am* 1986; 68(8):1264–74.
- Sándor GK, Kainulainen VT, Queiroz JO, Carmichael RP, Oikarinen KS. Preservation of ridge dimensions following grafting with coral granules of 48 post-traumatic and post-extraction dento-alveolar defects. *Dent Traumatol* 2003; 19(4):221–7.
- Senn N. Senn on the healing of aseptic bone cavities by implantation of aseptic decalcified bone. *Am J Med Sci* 1889; 98:219–43.
- Huggins C. The formation of bone under the influence of epithelium of the urinary tract. *Arch Surg* 1931; 22:377–408.
- Urist MR. Bone: formation by autoinduction. *Science* 1965; 150(698):893–9.
- Huggins C, Wiseman S, Reddi AH. Transformation of fibroblasts by allogeneic and xenogeneic transplants of demineralized tooth and bone. *J Exp Med* 1970; 132(6):1250–8.
- Mikulski AJ, Urist MR. Collagenase-released non-collagenous proteins of cortical bone matrix. *Prep Biochem* 1977; 7(5):357–81.
- Celeste AJ, Iannazzi JA, Taylor RC, Hewick RM, Rosen V, Wang EA, and other. Identification of transforming growth factor beta family

- members present in bone-inductive protein purified from bovine bone. *Proc Natl Acad Sci U S A* 1990; 87(24):9843–7.
16. Urist MR, DeLange RJ, Finerman GA. Bone cell differentiation and growth factors. *Science* 1983; 220(4598):680–6.
17. Clokie CM, Moghadam H, Jackson MT, Sándor GK. Closure of critical sized defects with allogenic and alloplastic bone substitutes. *J Craniofac Surg* 2002; 13(1):111–21.
18. Moghadam HG, Sándor GK, Holmes HH, Clokie CM. Histomorphometric evaluation of bone regeneration using allogenic and alloplastic bone substitutes. *J Oral Maxillofac Surg* 2004; 62(2):202–13.
19. Haddad AJ, Peel SA, Clokie CM, Sándor GK. Closure of rabbit calvarial critical-sized defects using protective composite allogenic and alloplastic bone substitutes. *J Craniofacial Surg* 2006; 17(5):926–34.
20. Jan AM, Sándor GK, Iera D, Mhawi A, Peel SA, Evans AW, and other. Hyperbaric oxygen results in an increase in rabbit calvarial critical sized defects. *Oral Surg Oral Med Oral Pathol Oral Radiol Endod* 2006; 101(2):144–9.
21. Clokie CM, Urist MR. Bone morphogenetic protein excipients: comparative observations on poloxamer. *Plast Reconstr Surg* 2000; 105(2):628–37.
22. Moghadam HG, Urist MR, Sándor GK, Clokie CM. Successful mandibular reconstruction using a BMP bioimplant. *J Craniofac Surg* 2001; 12(2):119–27.
23. Younger EM, Chapman MW. Morbidity at bone graft donor sites. *J Orthop Trauma* 1989; 3(3):192–5.