

Systemic Lupus Erythematosus: A Review for Dentists

*Jonathan B. Albilis, DMD; David K. Lam, DDS;
Cameron M.L. Clokie, DDS, PhD, FRCD(C);
George K.B. Sándor, MD, DDS, PhD, FRCD(C), FRCSC, FACS*

Auteur-ressource

Dr Sándor
Courriel :
george.sandor@utoronto.ca



SOMMAIRE

Le lupus érythémateux disséminé (LED) est une maladie chronique qui a des effets systémiques très importants. L'inflammation chronique est le signe révélateur du LED et peut toucher la peau, les articulations, les reins, les poumons, le système nerveux, les membranes séreuses comme la plèvre et le péricarde, les muqueuses et d'autres organes. Il est impératif que les dentistes connaissent les nombreux effets systémiques et buccaux du LED, y compris ses manifestations cliniques et biochimiques. Cet article de synthèse présente une vue d'ensemble des multiples systèmes organiques qui sont atteints par ce processus morbide hétérogène complexe et qui sont les plus pertinents pour les dentistes généralistes et spécialisés. On y propose notamment des moyens de reconnaître et de traiter les manifestations buccales et dentaires de cette maladie systémique.

Pour les citations, la version définitive de cet article est la version électronique : www.cda-adc.ca/jcda/vol-73/issue-9/823.html

Patients with systemic lupus erythematosus (SLE) experience a myriad of symptoms. The most common pattern is a mixture of constitutional complaints of skin, musculoskeletal, hematologic and serologic involvement.¹

The clinical course of SLE is variable and may be characterized by episodes of recurrent acute or chronic inflammation, and intervening periods of remission. Women, especially those in their 30s and 40s, are affected more frequently than men (average ratio 10:1).¹ The worldwide prevalence of SLE ranges between 12 and 50 per 100,000, depending on location and ethnicity.¹ Knowledge of this condition facilitates understanding of most other autoimmune rheumatic diseases. Many of the early features of SLE may overlap with those of other autoimmune conditions, but SLE has an impact on most organ systems.

In rheumatic diseases, chronic inflammation affects the heart, lungs, bones, joints, kidneys, skin and, frequently, other organs. Some examples include rheumatoid arthritis, rheumatic fever, SLE, Sjögren's syndrome, scleroderma, CREST syndrome, polymyositis, fibromyalgia, ankylosing spondylitis, psoriatic arthritis, polymyalgia rheumatica, vasculitis, temporal arteritis, Henoch-Schonlein purpura, Wegener's granulomatosis and midline granuloma. Immunologic abnormalities are another important feature of rheumatic conditions.

Pathogenesis

In the presence of appropriate antigens, SLE develops as a result of the formation of soluble immune complexes that are mainly composed of IgG and IgM.² The pattern is

Table 1 Hypersensitivity reactions

Type	Antibodies involved	Mechanism	Clinical examples
I	IgE	IgE bind to basophils and mast cells, releasing histamine, trypsin, arachidonic acid. Manifestations are local and systemic.	Conjunctivitis Asthma Anaphylaxis
II	IgG, IgM	Antibodies bind to cell surfaces, triggering immune response by complement activation.	Transfusion reaction Hashimoto's thyroiditis
III	Soluble IgG and IgM aggregates	Antibody complexes are deposited in various tissues such as skin, kidneys or joints, triggering immune response by complement activation.	Serum sickness Arthus reaction Systemic lupus erythematosus
IV	Cell-mediated immunity (delayed hypersensitivity)	Cytotoxic T cells (CD ₈) and helper cells (CD ₄) recognize antigen in a major histocompatibility complex, resulting in further macrophage-mediated proliferation of helper cells.	Contact dermatitis Temporal arteritis Transplant rejection

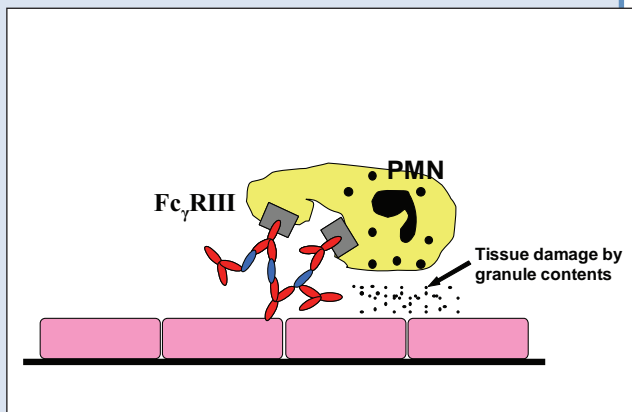


Figure 1: Schematic representation of type III hypersensitivity reaction. Only preformed antigen-antibody complexes can bind to the IgG constant fragment receptor (Fc gamma RIII) located on immune cells (PMN-polymorphonuclear leukocyte) and activate them, causing degranulation and tissue destruction. (Reproduced with permission from Nick Holmes, Cambridge University, United Kingdom, <http://www-immuno.path.cam.ac.uk>.)

that of a type III hypersensitivity reaction triggered by an endogenous antigen that may be generalized or organ-specific³ (Table 1). Because of the affinity of the antibody and the size of the immune complexes, the kidneys, lungs and joints are frequently targeted in persons with SLE.

Tissue damage is caused by platelets and neutrophils. The lesions contain primarily neutrophils and deposits of immune complexes and complement, namely C3a, C4a and C5a.³ Macrophages infiltrating in later stages are involved in the healing process (Fig. 1).

Genetic factors and specific gene loci are important in the pathogenesis of SLE.² In predisposed persons, environmental triggers, including exposure to sunlight (pho-

tosensitivity), drugs (pharmacogenetics) and infections (particularly with Epstein-Barr virus), are thought to precipitate the development of SLE.⁴

Clinical Presentation

The diagnosis of SLE requires several compatible clinical features and supportive laboratory studies.^{1,3-6} Table 2 outlines the 1997 American College of Rheumatology diagnostic criteria for SLE, which has been modified since Tan and others⁷ revised it in 1982.

Constitutional symptoms of SLE, such as complaints of fatigue, malaise, arthralgia, myalgia and mucocutaneous lesions, are common.⁷

Musculoskeletal signs and symptoms predominate in SLE. Arthralgia, asymmetric and migratory, is usually present and is often the earliest manifestation. The joints of the hands are most often affected. The arthritis is moderately painful and nondestructive. Deformities observed are usually due to tendon inflammation (Jaccoud-type arthropathy), rather than degeneration.

Generalized sun-induced skin rashes, and discoid lesions secondary to epithelial atrophy and subsequent scarring, are quite common. Of these, the classic malar or butterfly rash, that spares the nasolabial crease, is a highly common occurrence.⁴ Hair loss caused by hair follicles plugged with keratin is also reported.

Oral lesions such as desquamative gingivitis, marginal gingivitis or erosive mucosal lesions have been reported in up to 40% of patients. Patients with advanced cases of SLE may have features of Sjögren's syndrome, such as dry eyes, mouth and skin.⁴

Renal disease or lupus nephritis is a grave complication of SLE that affects 30% of patients.^{5,8} Renal tests (Table 2) may unmask lupus nephritis and its severity.⁸ Chronic renal failure because of SLE will influence the choice or dosage of medications prescribed by dentists (Table 3). Patients with

Table 2 A person has systemic lupus erythematosus if he or she meets any 4 of the 11 criteria simultaneously or in succession

SLE criterion	Definition or examples
Malar (butterfly) rash	Fixed erythema over the malar eminences
Discoid rash	Erythematosus raised patches, may scar
Photosensitivity	Skin rash as a result of unusual reaction to sunlight
Oral ulcers	Often painless sores
Arthritis	Nonerosive: Jaccoud's arthropathy
Serositis	Pleuritis — pleuritic pain, pleural rub, pleural effusion Pericarditis — ECG changes, pericardial rub, pericardial effusion
Renal disorder	Proteinuria (with 3+ or more protein noted in urinalysis specimen or 0.5 g of protein/day) Cellular casts in urine
Neurological disorder	Seizures Psychosis
Hematological disorder	Hemolytic anemia Leukopenia Lymphopenia Thrombocytopenia
Immunological disorder	Anti-DNA antibodies Anti-Sm antibodies Antiphospholipid antibodies
Antinuclear antibody	Antibodies to nuclear constituents

ECG = electrocardiogram

end-stage renal disease may become candidates for renal transplantation.

Changes in the central nervous system from cerebral lupus are quite variable. Headache, depression, seizures and psychosis have been documented, as well as peripheral neuropathies.⁵ Migraines seem to be more prevalent in patients with SLE than in the general population.⁵ The dentist's role in such cases is paramount to rule out odontogenic, temporomandibular joint and associated myofascial sources of pain (**Box 1**).

Generalized chest pain aggravated by deep inspiration (pleuritic pain), cough and rapid shallow breathing may be apparent during episodes of active lung disease. Pleural effusions and parenchymal damage often lead to pneumonitis. Subsequently, a hospitalized patient with SLE would be at great risk of acquiring pneumonia.⁵ Chest pain warrants a

Table 3 Drugs commonly prescribed by dentists with predominantly kidney-dependent elimination

Drugs with predominantly kidney-dependent elimination
Nonsteroidal anti-inflammatory drugs Acetylsalicylic acid Penicillins Cephalosporins Tetracycline Antifungals
Suggested adjustments
Consider increasing dose intervals and decreasing dosage Consider contacting physician if renal function is unknown
Suggested alternatives
Acetaminophen Narcotics Clindamycin

Box 1 Possible oral and dental manifestations in patients with systemic lupus erythematosus

- Mucocutaneous lesions (desquamative gingivitis, marginal gingivitis or erosive mucosal lesions)
- Indwelling odontogenic and other head and neck infections with no obvious symptoms, because of a reduced immune response
- Temporomandibular joint disorders (arthralgia, arthritis)
- Sjögren's syndrome (keratoconjunctivitis sicca, xerostomia and generalized hypohidrosis)
- Suboptimal oral hygiene because of painful oral lesions
- Caries in patients with Sjögren's-like syndrome

detailed workup to rule out pulmonary embolism and myocardial infarction, especially in those who test positive for antiphospholipid antibodies.⁴

Two well-known cardiac features of SLE are pericarditis and endocarditis. Pericarditis, which sounds like a rub, is audible with a stethoscope. Endocarditis has an autoimmune basis. Resulting rheumatic valvular damage takes the form of sterile vegetations that are susceptible to bacterial colonization.⁶ Antibiotic prophylaxis before bacteremia-associated dental and oral surgical interventions is required to prevent infectious endocarditis in SLE patients with valvular damage.

Advanced SLE-induced vasculitis can lead to multiorgan dysfunction (**Fig. 2**). However, cold- or stress-induced triphasic colour changes of the hands and feet, re-

Table 4 Autoantibodies found in patients with SLE^{3,4}

Antibody	Significance
Antinuclear antibody	Indicative of rheumatic diseases Not specific for systemic lupus erythematosus
Antibody to double-stranded DNA	Suggestive of systemic lupus erythematosus Predictive for renal involvement
Anti-Smith antibody	Predictive for renal involvement
Anti-Ro antibody	Suggestive of secondary Sjögren's syndrome
Antiphospholipid antibody	Increased risk of thromboembolism

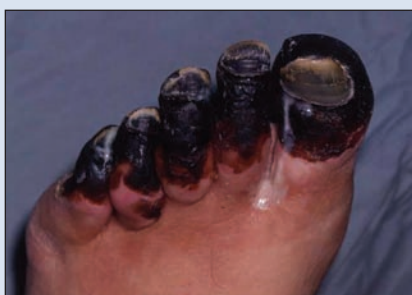

Figure 2: Gangrene caused by vasculitis. Vasculitis can lead to severe peripheral circulatory compromise and ultimately to gangrene, as seen in these toes.

ferred to as Raynaud's phenomenon, are a far more common occurrence.⁵

Other less severe forms of lupus exist. Chronic cutaneous (discoid) lupus erythematosus is a mild form of lupus in which integumentary changes prevail, with or without mucosal changes. Subacute cutaneous lupus erythematosus is an intermediate form of lupus in which skin lesions are mild, without discoid appearance, do not scar, and are usually accompanied with some degree of musculoskeletal involvement.⁴ Renal, cardiac and cerebral disease is usually not present in these mild and intermediate forms of lupus.⁵

Serologic Tests

If a diagnosis of SLE is suspected, then the most useful preliminary testing includes a complete blood count with differential white blood cell counts. This count will reveal chronic anemia that is normocytic-normochromic with thrombocytopenia and lymphocytopenia.^{3,4}

Other disease-specific tests for autoantibodies and the information yielded are outlined in **Table 4**.

Histopathology of Oral Lesions

Microscopic features of lupus mucosal lesions are quite similar to those of lichen planus and erythema multi-

forme. A common microscopic feature of these lesions is the band-like subepithelial inflammation. However, in patients with SLE and erythema multiforme, the inflammatory infiltrate extends deeper into the underlying connective tissue and shows a perivascular pattern.³ Deep submucosal vesicles may also be apparent. Lupus lesions will exhibit periodic acid-Schiff staining in the basement membrane zone. Direct immunofluorescent testing will show immunoglobulin and complement deposition along the basement membrane zone in a granular pattern that is characteristic of type III hypersensitivity reactions.

Differential Diagnosis

Several diseases mimic the initial course of SLE and make its differentiation from other conditions difficult. The onset of symptoms of many rheumatic disorders often overlap.

Lupus-related mucocutaneous lesions can mimic those of erythema multiforme, lichen planus and other vesiculobullous lesions. Histologic and immunohistochemical confirmation of intact tissue adjacent to a given lesion remain the criterion standards for definitive diagnosis.³

Medications implicated in the cause of drug-induced lupus are hydralazine, procainamide, phenytoin and isoniazid.⁴ Withdrawal of these medications, after appropriate medical workup, should reverse an apparent lupus-like syndrome. In addition, patients with drug-induced lupus do not show seropositivity for antinuclear antibody.

Treatment

The goals of SLE management are based on prevention, reversal of inflammation, maintaining states of remission and alleviation of symptoms.^{4,9} Avoidance of flare-ups of lupus and skin lesions consists of protection from ultraviolet sunlight.

Various medicinal therapies exist for the management of persons with SLE. Nonsteroidal anti-inflammatory drugs, cyclooxygenase-2 selective inhibitors and antimalarials are generally effective for musculoskeletal complaints and mild serositis.¹⁰⁻¹² Patients exhibiting skin

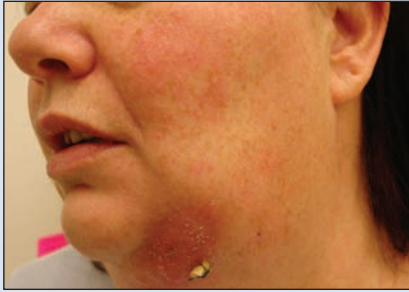

Figure 3a: Forty-year-old woman with systemic lupus erythematosus who has a faint malar rash limited anteroinferiorly by the nasolabial fold. This patient developed a silent odontogenic infection for many weeks that ultimately resulted in a submental abscess and required drainage.

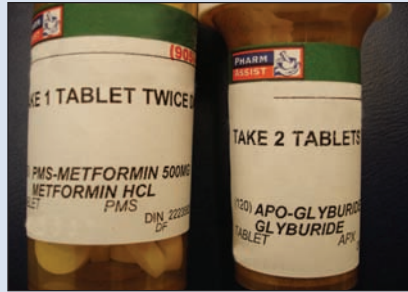


Figure 3b: The patient developed hyperglycemia as a result of long-term treatment with corticosteroids. The combination of corticosteroid-induced hyperglycemia and immunosuppression makes the management of head and neck infections even more difficult for the very complex group of patients with systemic lupus erythematosus.

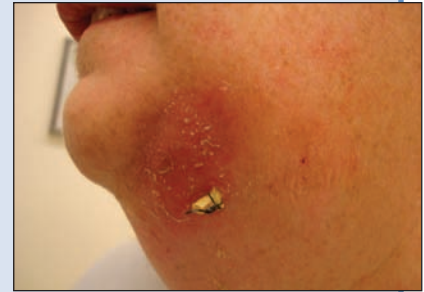

Figure 3c: Significant odontogenic infection. Note the presence of the submental drain and the minimal reaction in the area, despite the presence of significant odontogenic infection.

Box 2 Side-effects of long-term corticosteroid intake^{10,11}

- Compromised immunity
- Atherosclerosis
- Hypertension
- Hypercholesterolemia
- Hyperglycemia
- Cushingoid appearance
- Acne
- Cataracts
- Avascular necrosis of the hip
- Severe osteoporosis
- Pharmacologically induced adrenal insufficiency

manifestations often benefit from antimalarials, such as hydroxychloroquine.

Systemic corticosteroids, such as prednisone, are reserved for patients with morbid symptoms associated with significant organ involvement, particularly renal, central nervous system and systemic vascular diseases.^{4,10} The dosage of corticosteroid is progressively tapered as signs and symptoms resolve. However, some patients may require a maintenance dose to remain in remission.¹⁰ The side effects of chronic corticosteroid intake are listed in **Box 2**. A discussion of these side effects is beyond the scope of this article.

Other immunosuppressive agents such as cyclo-phosphamide, methotrexate and azathioprine are reserved for severe organ disease such as advanced lupus nephritis.^{5,10}

Perioperative Management by the Dentist

Dentists must enforce preventive dental care and monitor patients with SLE closely for head and neck infections because they are predisposed to severe infections. These infections are often silent and difficult to detect because of a

paucity of pain and swelling (**Figs. 3a–3c**). Thorough clinical examination is required to avoid overlooking infections. Infections can progress rapidly in patients with SLE because of disease or therapy-related immunosuppression.

To further complicate matters, patients with SLE can have a superimposed antiphospholipid antibody syndrome that predisposes them to thromboembolic events, such as arterial and venous thrombosis, pulmonary embolism, stroke and myocardial infarction.⁵ It is therefore important to document whether these patients are managed with anticoagulation therapy, aspirin or warfarin before dental surgery. Recent laboratory tests may be indicated preoperatively to determine platelet count, prothrombin time and the international normalized ratio (INR) for blood clotting time. Local measures for maintaining hemostasis may also be required.

Patients suffering from chronic renal failure are often on dialysis. Dental surgery should be planned one day after dialysis treatment to ensure elimination of administered medications and their by-products.

Patients on long-term corticosteroids may require supplemental dosing on the day of a potentially stressful dental surgery.

A multidisciplinary approach to medical consultation and appropriate referrals ensures comprehensive medical and dental management of patients with SLE.

Prognosis

Although a potentially debilitating disease, survival rates for SLE have doubled since the 1950s.¹³ Death due to SLE was more than 5 times higher in women than in men, and more than 3 times higher in black than white women.¹⁴ The major cause of death in the first few years of the onset of SLE is active disease that involves multiorgan systems or infection from drug-induced or lupus-related immunosuppression.^{4,5,10} Delayed deaths are caused by SLE, or associated

Box 3 Oral and dental considerations in patients with systemic lupus erythematosus

- Subacute bacterial endocarditis prophylaxis for patients with valvular damage because of Libman-Sacks endocarditis
- Alteration of drug dosages for patients with systemic lupus erythematosus who have severe renal involvement
- Attention to the possibility of drug interactions because this patient group may be taking many different medications
- Management of mucocutaneous lesions
- Aggressive workup and definitive treatment of infections involving the head and neck

with end-stage renal disease or complications of treatment, including infection, coronary disease and malignancy.^{5,15}

Poor prognostic factors are being young at onset, being male, having a poor socioeconomic status and having positive titres of antiphospholipid antibodies.^{9,15}


Conclusion

SLE can run a varied clinical course, ranging from a relatively benign illness to a rapidly progressive disease with fulminant organ failure and death. Most patients have an episodic relapsing and remitting course that may be managed with high-dose steroids during severe flare-ups. SLE is probably the most difficult of all autoimmune rheumatic disorders to control, putting prevention of infections at the forefront of disease management. For patients with SLE, emphasis is therefore placed on the dental team's continuous reinforcement of good oral hygiene, provision of close monitoring for and aggressive treatment of dental and oral infections, and assistance with the diagnosis of mucocutaneous lesions of the head and neck (**Box 3**). ♦

THE AUTHORS



Dr. Albilta is a resident, division of oral and maxillofacial surgery and anesthesia, Mount Sinai Hospital, University of Toronto, Toronto, Ontario.



Dr. Lam is senior resident, division of oral and maxillofacial surgery and anesthesia, Mount Sinai Hospital, PhD Harron Scholar, Collaborative Program in Neuroscience, and clinician-scientist fellow, Centre for the Study of Pain, University of Toronto, Toronto, Ontario.



Dr. Clokie is professor and head, oral and maxillofacial surgery and anesthesia, University of Toronto, Toronto, Ontario.



Dr. Sándor is clinical director, graduate program in oral and maxillofacial surgery and anesthesia, Mount Sinai Hospital; coordinator, pediatric oral and maxillofacial surgery, The Hospital for Sick Children and Bloorview Kids Rehab; professor of oral and maxillofacial surgery, University of Toronto, Toronto, Ontario; professor, Regea Institute for Regenerative Medicine, University of Tampere, Tampere, Finland; and docent in oral and maxillofacial surgery, University of Oulu, Oulu, Finland.

Correspondence to: Dr. George K.B. Sándor, The Hospital for Sick Children, S-525, 555 University Ave., Toronto ON M5G 1X8.

The authors have no declared financial interests.

This article has been peer reviewed.

References

1. Von Feldt JM. Systemic lupus erythematosus. Recognizing its various presentations. *Postgrad Med* 1995; 97(4):79, 83, 86 passim.
2. Nath SK, Kilpatrick J, Harley JB. Genetics of human systemic lupus erythematosus: the emerging picture. *Curr Opin Immunol* 2004; 16(6):794–800.
3. Cervera R, Khamashta MA, Font J, Sebastiani GD, Gil A, Lavilla P, and others. Systemic lupus erythematosus: clinical and immunologic patterns of disease expression in a cohort of 1,000 patients. The European Working Party and Systemic Lupus Erythematosus. *Medicine (Baltimore)* 1993; 72(2):113–24.
4. Estes D, Christian CL. The natural history of systemic lupus erythematosus by prospective analysis. *Medicine (Baltimore)* 1971; 50(2):85–95.
5. Fessler BJ, Boumpas DT. Severe major organ involvement in systemic lupus erythematosus. Diagnosis and management. *Rheum Dis Clin North Am* 1995; 21(1):81–98.
6. Nakamura RM, Bylund DJ. Contemporary concepts for the clinical and laboratory evaluation of systemic lupus erythematosus and "lupus-like" syndromes. *J Clin Lab Anal* 1994; 8(6):347–59.
7. Tan EM, Cohen AS, Fries JF, Masi AT, McShane DJ, Rothfield NF, and others. The 1982 revised criteria for the classification of systemic lupus erythematosus. *Arthritis Rheum* 1982; 25(11):1271–7.
8. Weening JJ, D'Agati VD, Schwartz MM, Seshan SV, Alpers CE, Appel GB, and others. The classification of glomerulonephritis in systemic lupus erythematosus revisited. *J Am Soc Nephrol* 2004; 15(3):241–50.
9. Cervera R, Khamashta MA, Font J, Sebastiani GD, Gil A, Lavilla P, and others. Morbidity and mortality in systemic lupus erythematosus during a 10-year period: a comparison of early and late manifestations in a cohort of 1,000 patients. *Medicine (Baltimore)* 2003; 82(5):299–308.
10. Fessler BJ, Alarcon GS, McGwin G Jr, Roseman J, Bastian HM, Friedman AW, and others. Systemic lupus erythematosus in three ethnic groups: XVI. Association of hydroxychloroquine use with reduced risk of damage accrual. *Arthritis Rheum* 2005; 52(5):1473–80.
11. Ozcelik O, Haytac MC, Seydaoglu G. The effects of anabolic androgenic steroid abuse on gingival tissues. *J Periodontol* 2006; 77(7):1104–9.
12. Lander SA, Wallace DJ, Weisman MH. Celecoxib for systemic lupus erythematosus: case series and literature review of the use of NSAIDs in SLE. *Lupus* 2002; 11(6):340–7.
13. Yumura W, Suganuma S, Uchida K, Moriyama T, Otsubo S, Takei T, and others. Effects of long-term treatment with mizoribine in patients with proliferative lupus nephritis. *Clin Nephrol* 2005; 64(1):28–34.
14. Centers for Disease Control and Prevention (CDC). Trends in deaths from systemic lupus erythematosus — United States, 1979-1998. *MMWR Morb Mortal Wkly Rep* 2002; 51(17):371–4.
15. Kasitanon N, Magder LS, Petri M. Predictors of survival in systemic lupus erythematosus. *Medicine (Baltimore)* 2006; 85(3):147–56.