

# Chondrosarcoma of the Mandible: A Case Report

**Rajan Saini**, BDS, MDS; **Noor Hayati Abd Razak**, BDS, M Clin Dent;  
**Shiafulizan Ab Rahman**, BDS, M Clin Dent; **Abdul Rani Samsudin**, BDS, FDSRCS, AM

## Auteur-ressource

**Dr Saini**  
 Courriel : [rajan@kb.usm.my](mailto:rajan@kb.usm.my)



## SOMMAIRE

Les chondrosarcomes sont des tumeurs malignes d'origine cartilagineuse, qui varient de tumeurs bien différenciées ressemblant à une tumeur bénigne du cartilage à des tumeurs de haut grade de malignité affichant un comportement local agressif et un potentiel métastatique. De 5 % à 10 % seulement des chondrosarcomes se manifestent dans la région de la tête et du cou. Nous présentons le cas d'un chondrosarcome siégeant dans la partie antérieure de la mandibule, et passons en revue la littérature pertinente.

**Mots clés MeSH** : chondrosarcoma/pathology; female; mandibular neoplasms/pathology

Pour les citations, la version définitive de cet article est la version électronique : [www.cda-adc.ca/jcda/vol-73/issue-2/175.html](http://www.cda-adc.ca/jcda/vol-73/issue-2/175.html)

Chondrosarcomas are malignant mesenchymal tumours with cartilaginous differentiation that only rarely affect the maxillofacial region.<sup>1</sup> Most chondrosarcomas of the head and neck region arise from the maxilla, with relatively few arising from the mandible.<sup>2</sup> Although chondrosarcoma occurs in patients of all ages, most of those affected are over 50 years of age.<sup>3</sup> In most cases, the tumour presents as a painless mass or swelling associated with loosening of the associated teeth. This article describes a patient with chondrosarcoma of the anterior mandibular region. The clinical, radiographic, surgical and pathological aspects of this lesion are presented, and the relevant literature is reviewed.

### Case Report

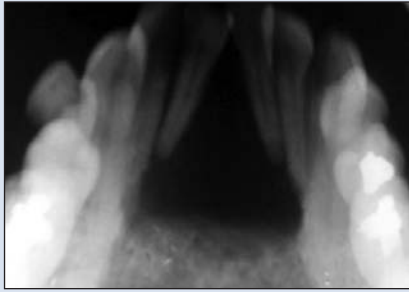
A 43-year-old woman was referred to a university-based dental clinic with swelling over the lingual aspect of the anterior mandible. The swelling had been present for 2 years and had increased gradually in size over that period. The patient denied any trauma or pain but reported difficulty with swallowing solid foods. She had

asthma but was not taking any medication for this condition.

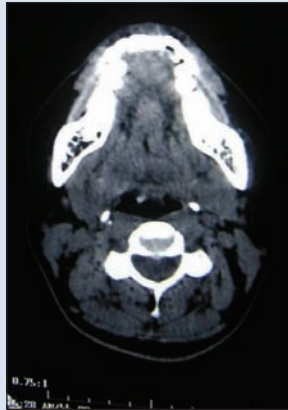
Extraoral examination did not reveal any obvious facial swelling or asymmetry. There was no cervical lymphadenopathy, and all of the cranial nerves were intact. Intraoral examination revealed an indurated, painless, discoid swelling about 2.5 cm × 2 cm in the midline of the anterior mandible between the lower incisors and the opening of the sublingual ducts. The overlying mucosa was pink and appeared normal. The anterior margin of the swelling was confluent with the lower alveolus.

Intraoral, occlusal (**Fig. 1**) and panoramic radiographs revealed a radiolucent lesion with diffuse margins, which had displaced the roots of the central incisors. Computed tomography showed an expansile lytic lesion involving the symphysis menti and the body of the mandible (**Fig. 2**). Thinning of the cortex was observed, and there was evidence of a cortical break. Three-dimensional imaging showed destruction of bone at the mid-mandibular region (**Fig. 3**).

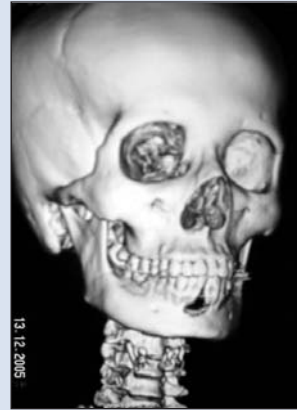
Histopathological examination revealed chondrocytes in lacunae that were arranged



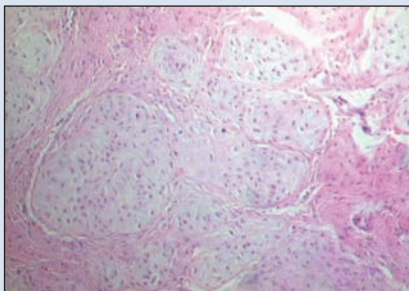
**Figure 1:** Occlusal radiograph showing radiolucent area in the mid-mandibular region, which has caused displacement of the roots of the central incisors.



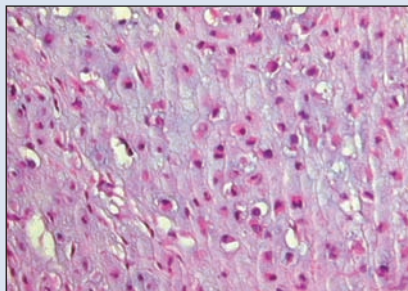
**Figure 2:** Computed tomography scan showing an expansile lytic lesion involving the symphysis menti and the body of the mandible.



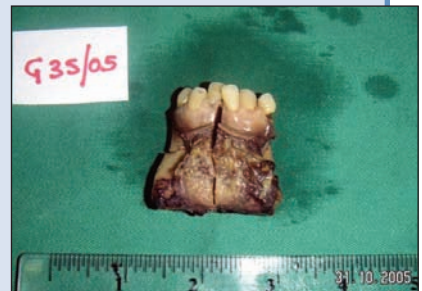**Figure 3:** Three-dimensional image showing bone resorption at the mid-mandibular region.



**Figure 4:** Photomicrograph showing chondrocytes in lacunae arranged in lobular patterns (hematoxylin and eosin; original magnification 5x).



**Figure 5:** Higher-magnification photomicrograph showing mitosis in a few cells (hematoxylin and eosin; original magnification 40x).



**Figure 6:** Photograph showing tumour resected by segmental mandibulectomy from the right first premolar to the left first premolar.

in lobular patterns (**Fig. 4**). Infiltration into the overlying mesenchymal tissue was visible in a few areas. Mitosis was visible in a few cells (**Fig. 5**). The tumour was diagnosed as low-grade chondrosarcoma.

The patient was advised to undergo surgery, and the tumour was resected by segmental mandibulectomy from the right first premolar to the left first premolar (**Fig. 6**). The breach in the continuity of the anterior mandible was reconstructed with a free vascularized fibula flap. The patient's postoperative period was uneventful.

Postoperative histopathological examination confirmed the diagnosis of chondrosarcoma, and further examination revealed that the left mandibular margin was positive for tumour. The patient underwent a course of radiotherapy (56 Gy over 6 weeks). There was no evidence of recurrence of the tumour 12 months after the surgery, and the patient was continuing to receive routine follow-up at the time of writing.

### Discussion

Chondrosarcomas are slow-growing, malignant mesenchymal tumours characterized by the formation of car-

tilage by the tumour cells. Primary chondrosarcomas arise de novo, whereas secondary chondrosarcomas arise from pre-existing enchondroma or osteochondroma. Benign cartilage-producing tumours within the jaws are extremely uncommon, but most ultimately prove to represent low-grade chondrosarcomas. Therefore, even apparently benign chondrogenic tumours of the jaws should be considered malignant until proven otherwise. In one study, 32% of patients with an initial diagnosis of benign chordoma, chondroma or osteochondroma had a final diagnosis of chondrosarcoma; the median interval before correct diagnosis was 12 months.<sup>2</sup>

Only 5% to 10% of chondrosarcomas occur in the head and neck, with the larynx and the nasal cavity being the most common sites.<sup>1,4</sup> Chondrosarcoma of the jaw occurs primarily in the anterior maxilla, where pre-existing nasal cartilage is present. Chondrosarcoma of the mandible is rare and occurs mostly in the mandibular symphyseal region.<sup>5,6</sup> Clinically, the tumour presents as a swelling, which may be painful and cause loosening of the involved teeth, with widening of the periodontal ligament space.<sup>3</sup> Chondrosarcomas of the jaw

may mimic periodontal lesions, with associated bone loss.<sup>6</sup> Clinical features, including loss of nerve sensation and dysesthesia, are used to distinguish a malignant neoplasm from osteomyelitis.

There are no radiographic findings that are pathognomonic for chondrosarcoma, although single or multiple radiolucent areas with poorly defined borders can be seen on plain films. Evidence of bone destruction is often present, and mottled densities caused by calcification are occasionally seen.<sup>7</sup> In the case described here, the differential diagnosis for radiolucency with displacement of teeth might include lateral periodontal cyst, the early stages of cemento-osseous dysplasia, central giant-cell granuloma, cemento-ossifying fibroma, odontogenic cysts (e.g., radicular or odontogenic keratocyst), odontogenic tumours and other nonodontogenic tumours (e.g., fibrosarcoma). Painful lesions with similar radiological findings include osteomyelitis, periapical lesions, osteosarcoma and Langerhans' cell disease.

Dentists play an important role not only in the recognition of symptoms and avoidance of misdiagnosis, but also in the multidisciplinary management of complicated jaw lesions.

Histopathologically, chondrosarcomas have a wide range of presentations, from well-differentiated growths resembling benign cartilage tumours to high-grade malignant lesions with aggressive local behaviour and metastatic potential.<sup>8</sup> Histological grading is an important determinant of prognosis, and Evans and others<sup>9</sup> were the first to propose a histological grading system for chondrosarcoma. Grade I lesions resemble benign cartilage, having a relatively uniform, lobular histologic appearance and no metastasis. Grade II lesions, which recur more often than grade I lesions, exhibit occasional mitotic figures. The rate of metastasis is approximately 10%. Grade III lesions are more cellular and pleomorphic in appearance, with a marked increase in the number of mitotic figures. The rate of metastasis in grade III lesions is more than 70%. The 5-year survival for chondrosarcomas is approximately 90% for grade I lesions, 81% for grade II lesions and 43% for grade III lesions.<sup>9</sup> Because of similar histological features, chondrosarcoma may be misdiagnosed as chondroblastic osteosarcoma or even Ewing's sarcoma.<sup>10</sup>

The treatment of choice for these lesions is wide surgical excision of all the involved structures with negative margins and preservation of function if possible.<sup>2</sup> These lesions may be invasive but they typically grow slowly; lymph node metastasis of jaw chondrosarcomas is therefore rare, and elective neck dissection is not necessarily required.<sup>7,11,12</sup> Distant metastasis is also rare and usually occurs in more advanced or recurrent disease. Distant metastasis to the lungs, sternum and vertebrae has been reported.<sup>2,12</sup>

For more advanced and higher-grade lesions, radical surgery may be required. Achievement of tumour-free margins is essential because the lesion is easily implanted in soft tissue, which can lead to rapid growth and further invasion.<sup>1</sup>

There is some controversy about the radiosensitivity of these tumours. Chondrosarcoma was traditionally regarded as a radioresistant tumour, and radiotherapy was therefore generally reserved for high-grade lesions (as a postoperative adjuvant therapy) and for surgically unresectable lesions.<sup>13</sup> However, Harwood and others reported that chondrosarcoma was radiosensitive and potentially radiocurable.<sup>14</sup> Krochak and others reported survival at 5 years for 38 patients who underwent radical radiotherapy.<sup>15</sup> Thirteen of 25 patients with favourable features were progression-free at 4-year follow-up, which led the authors to conclude that chondrosarcoma might not be radioresistant. In situations where surgery cannot be performed, such as chondrosarcoma arising in the base of the skull, precision radiotherapy using protons has resulted in rates of local control of 78% to 100%,<sup>16,17</sup> which supports the concept that chondrosarcoma can be radioresponsive.

Tumour grade and resectability are the most important prognostic factors for head and neck chondrosarcomas. Tumour site is another important prognostic determinant.<sup>1</sup> Factors indicating poorer prognosis include histologically positive margins and high-grade tumour differentiation (Grades II and III).<sup>2</sup>

Given that chondrosarcoma occurs only rarely in the jaws and given that this lesion has similar histological features to other tumours, diagnosis is always a challenge for pathologists. The lesions most commonly appear as a hard mass that may be associated with pain and displacement of teeth. Since chondrosarcoma is locally aggressive, better prognosis is achieved with early recognition and diagnosis and wide surgical resection performed as soon as possible. A long-term study of combined treatment with surgery and adjuvant radiation therapy or chemotherapy is needed to confirm the best approach in the management of these lesions. ♦

## THE AUTHORS



*Dr. Saini is a lecturer in oral pathology and medicine, School of Dental Sciences, Health Campus, Universiti Sains Malaysia, Kelantan, Malaysia.*



*Dr. Razak is a lecturer in oral maxillofacial surgery, School of Dental Sciences, Health Campus, Universiti Sains Malaysia, Kelantan, Malaysia.*



*Dr. Rahman is a lecturer in oral maxillofacial surgery, School of Dental Sciences, Health Campus, Universiti Sains Malaysia, Kelantan, Malaysia.*



*Dr. Samsudin is dean and professor of oral maxillofacial surgery, School of Dental Sciences, Health Campus, Universiti Sains Malaysia, Kelantan, Malaysia.*

**Correspondence to:** Dr. Rajan Saini, School of Dental Sciences, Universiti Sains Malaysia, Health Campus, 16150, Kubang Kerian, Kelantan, Malaysia.

The authors have no declared financial interests.

This article has been peer reviewed.

## References

1. Burkey BB, Hoffman HT, Baker SR, Thornton AF, McClatchey KD. Chondrosarcoma of the head and neck. *Laryngoscope* 1990; 100(12):1301–5.
2. Ruark DS, Schlehaider UK, Shah JP. Chondrosarcomas of the head and neck. *World J Surg* 1992; 16(5):1010–5.
3. Garrington GE, Collett WK. Chondrosarcoma. II. Chondrosarcoma of the jaws: analysis of 37 cases. *J Oral Pathol* 1988; 17(1):12–20.
4. Mark RJ, Tran LM, Sercarz J, Fu YS, Calcaterra TC, Parker RG. Chondrosarcoma of the head and neck. The UCLA experience, 1955–1988. *Am J Clin Oncol* 1993; 16(3):232–7.
5. Izadi K, Lazow SK, Solomon MP, Berger JR. Chondrosarcoma of the anterior mandible. A case report. *N Y State Dent J* 2000; 66(7):32–4.
6. Ormiston IW, Piette E, Tideman H, Wu PC. Chondrosarcoma of the mandible presenting as periodontal lesions: report of 2 cases. *J Craniomaxillofac Surg* 1994; 22(4):231–5.
7. Weiss WW Jr, Bennett JA. Chondrosarcoma: a rare tumor of the jaws. *J Oral Maxillofac Surg* 1986; 44(1):73–9.
8. Batsakis JG, Solomon AR, Rice DH. The pathology of head and neck tumors: neoplasms of cartilage, bone, and the notochord, part 7. *Head Neck Surg* 1980; 3(1):43–57.
9. Evans HL, Ayala AG, Romsdahl MM. Prognostic factors in chondrosarcoma of bone: a clinicopathologic analysis with emphasis on histologic grading. *Cancer* 1977; 40(2):818–31.
10. Finn DG, Goepfert H, Batsakis JG. Chondrosarcoma of the head and neck. *Laryngoscope* 1984; 94(12 Pt 1):1539–44.
11. Arlen M, Tollefsen HR, Huvos AG, Marcove RC. Chondrosarcoma of the head and neck. *Am J Surg* 1970; 120(4):456–60.
12. Murayama S, Suzuki I, Nagase M, Shingaki S, Kawasaki T, Nakajima T, and others. Chondrosarcoma of the mandible. Report of case and a survey of 23 cases in the Japanese literature. *J Craniomaxillofac Surg* 1988; 16(6):287–92.
13. McNaney D, Lindberg RD, Ayala AG, Barkley HT Jr, Hussey DH. Fifteen year radiotherapy experience with chondrosarcoma of bone. *Int J Radiat Oncol Biol Phys* 1982; 8(2):187–90.
14. Harwood AR, Krajbich JI, Fornasier VL. Radiotherapy of chondrosarcoma of bone. *Cancer* 1980; 45(11):2769–77.
15. Krochak R, Harwood AR, Cummings BJ, Quirt IC. Results of radical radiation for chondrosarcoma of bone. *Radiother Oncol* 1983; 1(2):109–15.
16. Schulz-Ertner D, Nikoghosyan A, Thilmann C, Haberer T, Jakel O, Karger C, and others. Carbon ion radiotherapy for chordomas and low-grade chondrosarcomas of the skull base. Results in 67 patients. *Strahlenther Onkol* 2003; 179(9):598–605.
17. Noel G, Habrand JL, Jauffret E, de Crevoisier R, Dederke S, Mammar H, and others. Radiation therapy for chordoma and chondrosarcoma of the skull base and the cervical spine. Prognostic factors and patterns of failure. *Strahlenther Onkol* 2003; 179(4):241–8.