

Large Erupting Complex Odontoma: A Case Report

*Manoj Vengal, MDS; Honey Arora, BDS; Sujoy Ghosh, BDS;
Keerthilatha M. Pai, MDS*

Auteur-ressource

Dr Vengal
Courriel : omr@manipal.edu



SOMMAIRE

L'odontome est le type de tumeur odontogène le plus répandu. Il est habituellement asymptomatique et est souvent découvert durant les radiographies de routine. La présente étude de cas traite d'un odontome vaste et complexe causant de la douleur, de l'infection et une asymétrie faciale. Il s'agit d'un cas important, car peu de rapports portent sur des odontomes complexes dans la cavité buccale.

Mots clés MeSH : mandibular neoplasms/diagnosis; odontoma/pathology; odontoma/radiography

Pour les citations, la version définitive de cet article est la version électronique : www.cda-adc.ca/jcda/vol-73/issue-2/169.html

Odontomas are hamartomas composed of various dental tissues, i.e., enamel, dentin, cementum and sometimes pulp. They are slow-growing, benign tumours showing nonaggressive behaviour.¹ They are classified as complex, when the calcified tissues present simply as an irregular mass composed mainly of mature tubular dentin, or compound, if there is superficial anatomic similarity to even rudimentary teeth.² Complex odontomas are less common than the compound variety in the ratio 1:2.³ Eruption of an odontoma in the oral cavity is rare. We present a case of complex odontoma, in which apparent eruption has occurred in the area of the right mandibular third molar.

Case Report

A 23-year-old, apparently healthy man reported to the department of oral medicine and radiology, Manipal College of Dental Sciences, with painful swelling on the right side of the lower jaw of 2 weeks duration. His medical history was unremarkable. Clinically, there was

gross facial asymmetry with diffuse smooth swelling in the right mandibular angle region. Mouth opening was adequate. Intraoral examination of the region revealed the apparent absence of the right mandibular third molar and a breach in the corresponding alveolar mucosa through which pus extruded. The buccal and lingual cortices were expanded and hard. There was no evidence of any abnormality in other teeth in the right mandibular region. The differential diagnosis included pericoronary abscess and infected odontogenic cyst (dentigerous cyst) associated with impacted third molar. The patient was asked to return for an intraoral periapical radiograph and a panoramic radiograph; however, he did not return for imaging.

After 8 months, the patient revisited the department complaining of pain in the same region. The swelling had not increased in size (**Fig. 1**). Intraoral examination showed a whitish-yellow hard mass resembling dentin; it measured about 3 cm in its mesio-distal dimension and 2 cm buccolingually (**Fig. 2**).

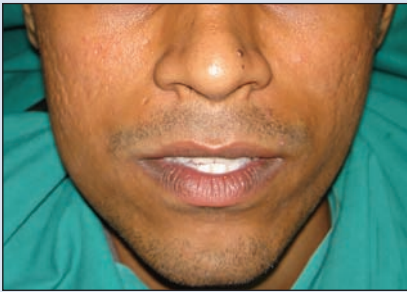


Figure 1: Clinical photograph showing gross facial asymmetry in the patient.

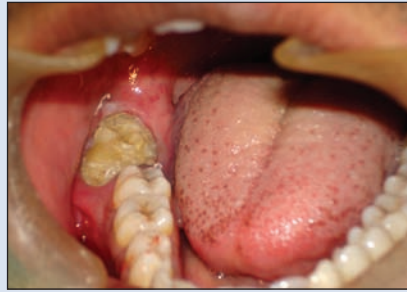

Figure 2: Clinical photograph showing the odontoma erupting in the oral cavity and impaction of the third molar.

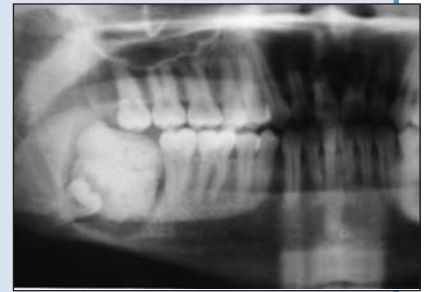

Figure 3: Panoramic radiograph showing the erupting odontoma and the impacted third molar, which was displaced to the disto-inferior region of the angle of the mandible.

A panoramic radiograph showed a uniformly dense rounded radiopacity (about 3.5 × 3.3 cm), distal to the mandibular right second molar and overlying the coronal portion of the mandibular right third molar, which was displaced disto-inferiorly (**Fig. 3**). A uniform, well-defined radiolucent halo surrounded the radiopacity except in the superior area where it erupted into the oral cavity. The right mandibular canal was displaced inferiorly. There was no evidence of any root resorption in the right mandibular second molar. Considering the clinical and radiologic presentations, a diagnosis of infected erupting complex odontoma was determined. Under general anesthesia, access to the mass was achieved via an intraoral approach and it was excised along with the impacted tooth, i.e., the mandibular right third molar (**Figs. 4a** and **4b**). Histopathologic examination (**Fig. 5**) of the excised mass confirmed the diagnosis of complex odontoma.

Discussion

Odontoma is the most common type of odontogenic tumour, although some authors prefer to refer to it as hamartoma, not a true tumour.³ Complex odontomas tend to occur in the posterior region of the jaw and compound odontomas are more common in the anterior maxilla.^{1,3} They may be discovered at any age, although less than 10% are found in patients over 40 years of age. Although they are commonly asymptomatic, clinical indicators of odontoma may include retention of deciduous teeth, noneruption of permanent teeth, pain, expansion of the cortical bone and tooth displacement. Other symptoms include anesthesia in the lower lip and swelling in the affected area. In the present case, pain was the first symptom, probably due to secondary infection,⁴ which can occur because of replacement of bone by a large amount of avascular hard tissue. Eruption of an

odontoma through the mucosa could also allow invasion of oral microorganisms into the bone due to lack of adequate adhesion between bone and odontoma because of the absence of periodontal ligament. Odontomas can measure anywhere from a few millimetres to many centimetres in their greatest dimension. The largest found in a human weighed 0.3 kg.^{2,5}

Clinically, odontomas⁶ are either complex or compound, and are classified as:

- Intraosseous — these odontomas occur inside the bone and may erupt (erupted odontoma) into the oral cavity. To date, 12 cases of the erupted variety have been described in the literature.⁶
- Extraosseous or peripheral — odontomas occurring in the soft tissue covering the tooth-bearing portions of the jaws.

The odontoma presents as a well-defined radiopacity situated in bone, but with a density that is greater than bone and equal to or greater than that of a tooth. It contains foci of variable density. A radiolucent halo, typically surrounded by a thin sclerotic line, surrounds the radiopacity. The radiolucent zone is the connective tissue capsule of a normal tooth follicle. The thin sclerotic line resembles the corticated border seen in a normal tooth crypt. The developmental stages can be identified based on radiologic features and the degree of calcification of the lesion at the time of diagnosis.^{6,7} The first stage is characterized by radiolucency due to the absence of dental tissue calcification, the second or intermediate stage shows partial calcification and the third or classically radiopaque stage exhibits predominant tissue calcification with the surrounding radiolucent halo described above.^{5,8}

In our case study, we present a mature complex odontoma, which should be differentiated from cementoblas-

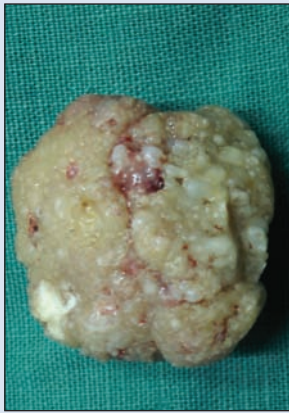


Figure 4a: The excised odontoma.

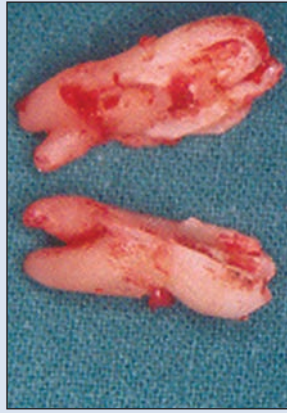

Figure 4b: The impacted third molar.

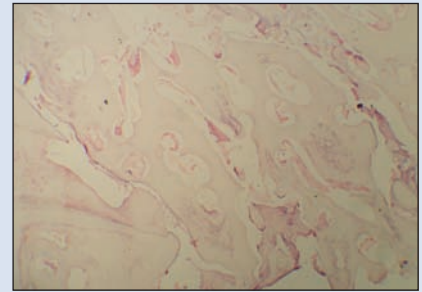


Figure 5: Photomicrograph (x 4) showing decalcified dentin and empty spaces of decalcified enamel intermixed with haphazardly arranged areas containing remnants of immature enamel matrix.

toma, osteoid osteoma and fibro-osseous lesions, such as cemento-ossifying fibroma. A cementoblastoma presents as a well-defined radiopaque mass attached to the tooth root and surrounded by a radiolucent rim.^{2,5,9} Osteoid osteomas are characterized by a small ovoid or round radiolucent area surrounded by a rim of sclerotic bone; the central radiolucency exhibits some calcification. Cemento-ossifying fibroma presents as a well-defined radiolucency with increasing flecks of calcification as it matures; it is not surrounded by a radiolucent rim and it is diffuse with normal bone.^{2,5,9} Also, none of these is associated with an impacted tooth.

The mechanism of odontoma eruption appears to be different from tooth eruption because of the lack of periodontal ligament in odontoma. Therefore, the force required to move the odontoma is not linked to the contractility of fibroblasts, as is the case for teeth. Although there is no root formation in odontoma, its increasing size may lead to the sequestration of the overlying bone and, hence, occlusal movement or eruption. The increase in the size of the odontoma over time produces a force sufficient to cause bone resorption.

Another reason for odontoma eruption could be the bony remodelling of the jaws. However, for this to occur dental follicle is required, although indirectly, as it provides both the conductance and chemoattraction for the osteoclasts necessary for tooth eruption. Immunocytochemical investigations have indicated that a pattern of cellular activity involving both reduced dental epithelium and the follicles is associated with tooth eruption. The reduced dental epithelium initiates a cascade of intercellular signals by expressing epidermal growth factor β and transforming growth factor. These factors, in turn, stimulate the follicular cells to produce colony-stimulating factor, which recruits osteoclasts to the follicle. The reduced dental epithelium

also secretes proteases, which assist in the breakdown of the follicle to produce a path of least resistance.¹⁰

This epithelial signalling could explain the remarkable consistency of eruption times, as it is likely that the dental epithelium is programmed as part of its functional life cycle.¹⁰ However, in the case of odontomas erupting into the oral cavity, the mechanism behind the eruption times remains uncertain as some odontomas erupt at a young age and others at an older age.

Erupted odontomas are most often seen in older people. Thus, it is likely that resorption of the edentulous part of the alveolar process plays a role, but it is also possible that reactive growth of the capsule contributes to this phenomenon.¹¹ Eruption at a young age is possible through bone remodelling that might have resulted from the presence of dental follicles.

Odontomas have been associated with trauma during primary dentition, as well as with inflammatory and infectious processes, hereditary anomalies (Gardner syndrome, Hermann's syndrome), odontoblastic hyperactivity and alterations in the genetic components responsible for controlling dental development.¹¹

Hitchin¹² suggested that odontomas are inherited through a mutant gene or interference, possibly postnatal, with genetic control of tooth development. In humans, there is a tendency for the lamina between the tooth germs to disintegrate into clumps of cells. The persistence of a portion of lamina may be an important factor in the etiology of complex or compound odontomas and either of these may occur instead of a tooth. In either case, a mutation in the epithelial cells of the persistent lamina or of the tooth germ itself may change the inherent capacity of the odontogenic epithelium to go through the cap and bell stages necessary for tooth formation and still retain its ability to stimulate mesenchymal differentiation necessary for dentin formation

and to form functional ameloblasts and odontoblasts leading to a composite odontoma. Comparative investigations of odontogenic cells in normally forming teeth and tumours showed that differentiation of both normal and abnormal odontogenic cells is accompanied by the expression of some common molecules. Furthermore, the gene products present in normal mesenchymal cells were also found in odontogenic tumour epithelium. A plausible explanation for this is that the odontogenic tumour epithelial cells are recapitulating genetic programs expressed during normal odontogenesis, but the tumour cells demonstrate abnormal expression of these genes.¹³

Surgical removal of odontomas is indicated in the absence of any contraindications. Clinical and radiographic follow-up is prudent where surgical treatment is deferred.

Conclusion

An infected erupting complex odontoma in the mandibular third molar region is reported. Such cases may confuse diagnosis during clinical examination. Radiographically, such odontomas may be mistaken for various other lesions. This case is also unusual in that eruption took place over a relatively short time. A possible explanation for such a phenomenon could be bone remodelling and increased force from the expanding odontoma. ✦

THE AUTHORS

Acknowledgement: We would like to acknowledge Dr. Nirmala Rao, professor and head of the department of oral pathology, Manipal College of Dental Sciences, for her help in providing us with the histopathology slides.



Dr. Vengal is Reader in the department of oral medicine and radiology, Manipal College of Dental Sciences, Manipal, Karnataka, India.



Dr. Arora is a postgraduate student in the department of oral medicine and radiology, Manipal College of Dental Sciences, Manipal, Karnataka, India.



Dr. Ghosh is a postgraduate student in the department of oral medicine and radiology, Manipal College of Dental Sciences, Manipal, Karnataka, India.



Dr. Pai is professor and head, department of oral medicine and radiology, Manipal College of Dental Sciences, Manipal, Karnataka, India.

Correspondence to: Dr. Manoj Vengal, Department of Oral Medicine and Radiology, Manipal College of Dental Sciences, Manipal, Karnataka – 576104, India.

The authors have no declared financial interests.

This article has been peer reviewed.

References

1. Neville BW, Damm DD, Allen CM, Bouquot JF. Odontogenic cysts and tumors. In: Oral and maxillofacial pathology. 2nd ed. Philadelphia (PA): WB Saunders; 2002. p. 631–2.
2. Mupparapu M, Singer SR, Rinaggio J. Complex odontoma of unusual size involving the maxillary sinus: report of a case and review of CT and histopathologic features. *Quintessence Int* 2004; 35(8):641–5.
3. Cohen DM, Bhattacharyya I. Ameloblastic fibroma, ameloblastic fibro-odontoma, and odontoma. *Oral Maxillofac Surg Clin North Am* 2004; 16(3):375–84.
4. Tuzum MS. Orofacial pain associated with an infected complex odontoma. Case report. *Aust Dent J* 1990; 35(4):352–4.
5. Wood NK, Goaz PW, Lehnert J. Mixed radiolucent–radiopaque lesions associated with teeth. In: Wood NK, Goaz PW, editors. Differential diagnosis of oral and maxillofacial lesions. Singapore: Harcourt Brace & Company Asia Pte Ltd; 1998. p. 289–314.
6. Junquera L, de Vincente JC, Roig P, Olay S, Rodriguez-Recio O. Intraosseous odontoma erupted into the oral cavity: an unusual pathology. *Med Oral Patol Oral Cir Bucal* 2005; 10(3):248–51.
7. Worth HM, editor. Odontomes and cysts of the jaws. In: Principles and practice of oral radiographic interpretation. Chicago: Year Book Medical; 1963. p. 420–4.
8. Guinta JL, Kaplan MA. Peripheral soft tissue odontomas. *Oral Surg Oral Med Oral Pathol* 1990; 69(3):406–11.
9. Amado Cuesta S, Gargallo Albiol J, Berini Aytés L, Gay Escoda C. Review of 61 cases of odontoma. Presentation of an erupted complex odontoma. *Med Oral* 2003; 8(5):366–73.
10. Ten Cate AR, Nanci A. Physiologic tooth movements: eruption and shedding. In: Nanci A, editor. Ten Cate's oral histology: development, structure and function. St. Louis (MO): Mosby; 2003. p. 275–98.
11. Ragalli CC, Ferreria JL, Blasco F. Large erupting complex odontoma. *Int J Oral Maxillofac Surg* 2000; 29(5):373–4.
12. Hitchin AD. The aetiology of the calcified composite odontomes. *Brit Dent J* 1971; 130(11):475–82.
13. Papageraki P, Peuchmaur M, Hotton D, Ferkdadjji L, Delmas P, Sasaki S, and other. Aberrant gene expression in epithelial cells of mixed odontogenic tumors. *J Dent Res* 1999; 78(1):20–30.