

# Conservative Management of Regional Odontodysplasia: Case Report

Shiu-yin Cho, BDS, MDS, FRACDS

## Auteur-ressource

Dr. Cho

Courriel : [rony\\_cho@dh.gov.hk](mailto:rony_cho@dh.gov.hk)



## SOMMAIRE

L'odontodysplasie régionale est une anomalie de croissance rare qui affecte une partie localisée de la dentition. Les dents touchées présentent en général une malformation grossière et développent des abcès peu de temps après leur éruption. Même si l'extraction est souvent requise, dans les cas les plus légers il est possible de conserver les dents plus longtemps. Le plan de traitement doit se baser sur l'importance de l'atteinte ainsi que les besoins fonctionnels et esthétiques de chaque cas. Cet article présente une approche de traitement conservateur pour un jeune garçon de 10 ans qui présente une odontodysplasie régionale.

**Mots clés MeSH :** bicuspid/abnormalities; incisor/abnormalities; molar/abnormalities; odontodysplasia/therapy

© J Can Dent Assoc 2006; 72(8):735-8  
Cet article a été révisé par des pairs.

**R**egional odontodysplasia (RO) is an uncommon, nonhereditary developmental anomaly affecting dental tissues derived from both the mesoderm and ectoderm.<sup>1</sup> The prevalence of this condition is not known, as reports have mainly been of cases. It has been suggested that RO is slightly more common in females, but its incidence does not tend to be higher in any particular ethnic group.<sup>2</sup>

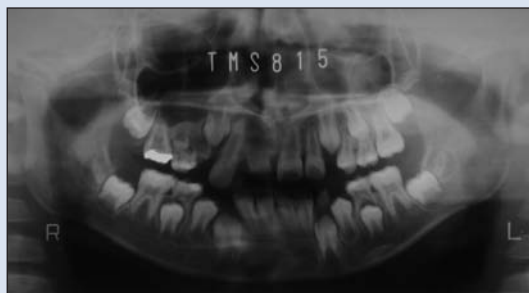The criteria for diagnosis are mainly clinical and radiographic, sometimes supplemented by histologic findings.<sup>2</sup> Clinical examination reveals affected teeth that are atypically shaped with surface pits and grooves and yellowish or brownish discoloration.<sup>1</sup> The condition is usually unilateral,<sup>2-5</sup> although exceptions can be found.<sup>6-8</sup> The anomaly is usually localized in one arch, with incidence higher in the maxilla.<sup>1</sup> Rarely, almost all teeth of the same arch are affected.<sup>9</sup> In cases where both arches are involved, the presentation is usually unilateral.<sup>10</sup> The affected teeth most often occur as a continuous series, although occasionally the anomaly will "skip" a tooth

or group of teeth.<sup>11</sup> Eruption of the affected teeth is often delayed or failed.<sup>3</sup>

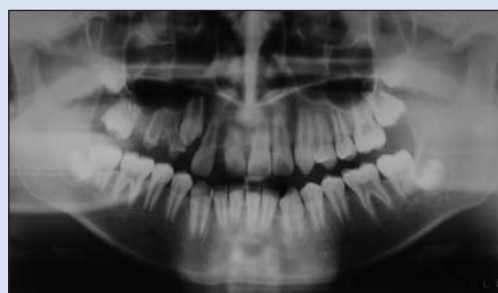
Radiographically, the anomalous teeth appear less opaque than unaffected teeth, and the demarcation between enamel and dentin is not distinct.<sup>1</sup> The pulp chambers and root canals are wide, giving the appearance of "ghost teeth."

Histologically, areas of hypocalcified enamel are visible and enamel prisms appear irregular in direction.<sup>7</sup> Coronal dentin is fibrous, consisting of clefts and a reduced number of dentinal tubules; radicular dentin is generally more normal in structure and calcification.<sup>7</sup> Pulpal calcification of various degrees is also commonly seen.<sup>12</sup> The mineral content of the affected enamel has been found to be higher than that of dentin in microradiographic studies.<sup>12</sup> The greater density of the enamel is not evident in conventional radiographs, probably because of the thinness of the enamel layer in affected teeth.

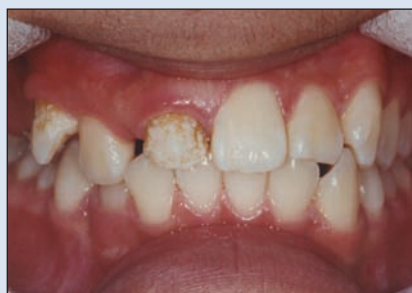The management of RO is somewhat controversial and revolves around the question of whether to remove the affected teeth.<sup>2-5</sup>



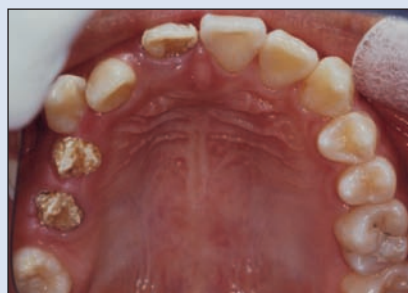**Figure 1:** Orthopantomogram of the patient taken at 10 years of age, showing the “ghost tooth” appearance of teeth 11, 14 and 15.



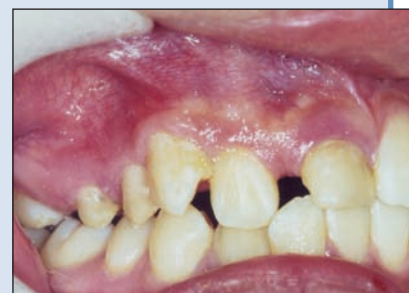**Figure 2:** Orthopantomogram taken at age 11.5 years, showing very thin radicular dentin in teeth 11, 14 and 15. The roots of teeth 12 and 13 appear normal.



**Figure 3:** Frontal view of the patient at age 12.5 years, showing tooth 11 with hypoplastic, short crown. Mild hypoplasia is also seen on tooth 13.



**Figure 4:** Occlusal view of the patient's maxillary arch, showing hypoplastic, discoloured right premolars.



**Figure 5:** Buccal view of the patient taken 6 months after placement of the composite restorations on teeth 11, 13, 14 and 15.

Although many clinicians prefer to extract the anomalous teeth as soon a diagnosis of RO is made,<sup>6,7,10</sup> some prefer to retain them until skeletal growth is complete as long as they are free of infection.<sup>4,13</sup> In this article, a case of RO managed by a conservative approach is described.

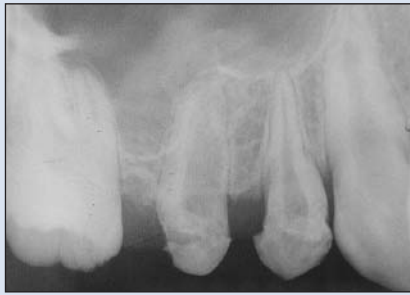### Case Report

A 10-year-old boy attended the author's clinic for a routine checkup. His prenatal, birth, medical and family history were unremarkable. Extraoral examination revealed nothing of note. The boy was at the late mixed dentition stage, with all primary second molars retained. The maxillary right permanent first and primary second molars were grossly hypoplastic and heavily restored. The maxillary right permanent central incisor was also grossly hypoplastic and discoloured and had a short crown. The maxillary right permanent lateral incisor was distally tilted but its coronal structure appeared normal. No dental abscess was seen clinically.

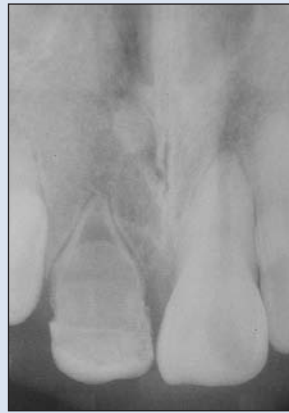An orthopantomogram revealed enlarged pulp chambers and short roots in the maxillary right permanent central incisor and first molar (**Fig. 1**). Development of the maxillary right premolars was delayed and they showed

ill-defined enamel and dentin. A diagnosis of RO was made. The maxillary right permanent first molar was subsequently extracted because of its poor prognosis. Timely extraction would also facilitate mesial drift of the adjacent permanent second molar. The boy was then seen regularly to monitor the eruption of the maxillary right premolars and to watch for signs or symptoms of infection in the maxillary right central incisor.

The maxillary right premolars erupted when the boy was 11 years of age, but the teeth had grossly hypoplastic and discoloured crowns as well as thin radicular dentin (**Fig. 2**). The maxillary right permanent canine erupted at 12.5 years of age, and was only mildly affected, with localized enamel hypoplasia on the buccal surface. The maxillary right central incisor remained infection free (**Figs. 3** and **4**). The labial-buccal surfaces of these teeth were restored with composite resin to improve their appearance (**Fig. 5**). Supragingival margins were placed to avoid jeopardizing periodontal health. All teeth remained sound when the boy was seen at 14.5 years of age, and the apical half of the maxillary right first premolar appeared well developed (**Fig. 6**). The adjacent second premolar had also attained a root length similar to that of the first premolar,



**Figure 6:** Periapical radiograph taken at age 14.5 years, showing continued root development in tooth 14.



**Figure 7:** Periapical radiograph of tooth 11 showing amorphous calcification in the coronal half of the pulp chamber.

but its pulp chamber remained enlarged and radicular dentin was very thin on the mesial side. Some amorphous calcification was also seen in the pulp chamber of the maxillary right central incisor (Fig. 7).

## Discussion

The etiology of RO is still unknown and such conditions as viral infections, local trauma, vascular defects, irradiation, metabolic disturbance, rhesus incompatibility and medications during pregnancy have been suggested as possible causes.<sup>1</sup> Some patients may also present with systemic anomalies, such as facial asymmetry.<sup>8</sup> In the current case, etiologic factors could not be identified and no systemic involvement was seen. Although dentinal dysplasia, amelogenesis and dentinogenesis imperfecta show some similarities to RO, these conditions affect the entire dentition in contrast to the segmental involvement seen in RO.

Treatment of RO has given rise to controversy, the main concern being whether to remove the affected teeth. The rationale for early extraction is that many of the anomalous teeth are not restorable and would develop dental abscess soon after eruption.<sup>12</sup> On the other hand, retaining noninfected teeth helps maintain the alveolar bone, averts the need for a removable prosthesis and eliminates the psychological effects of premature tooth loss.<sup>2,4,13,14</sup>

As there is no general agreement on the best treatment for these patients, dentists should consider such factors as the patient's age, medical history, degree of involvement, the presence or absence of pathosis and the attitude and expectations of the child and parents.<sup>1,2,14</sup> The aims of treatment should include improving function and esthetics, reducing the psychological impact of early tooth loss and facilitating normal jaw growth.<sup>1,2</sup> If a decision is made to retain the anomalous teeth, regular review is mandatory.

In the present case, the patient was managed conservatively, as the anomalous teeth remained free from infection. The aim was to retain those teeth until skeletal growth was complete; at that time, the patient could be reassessed for dental implants and other rehabilitation methods. The anomalous teeth were localized in a single quadrant, had hypoplastic and discoloured crowns and were delayed in eruption — all of which are typical features of RO.<sup>1</sup> The pulpal calcification seen in the central incisor is also a common finding.<sup>12</sup> One interesting feature of the present case was the apparent “gradient of seriousness” in the buccal segment, ranging from localized enamel hypoplasia in the canine to malformed crown and root in the second premolar. The continued root development, as seen in the maxillary right first premolar, was an atypical finding that has been reported only occasionally.<sup>4,5,11,13</sup> The reason why the anomaly “skipped” the maxillary right lateral incisor was not clear, but this feature has also been reported occasionally.<sup>11</sup>

Although the patient and parents were satisfied with the results, the restorative treatment carried out in this case cannot be considered optimal because the esthetics and function of the patient's dentition were not fully restored. Patients and parents whose demand for esthetics is higher may find this option inadequate. Indirect composite veneers, which can be used without enamel reduction, might produce better esthetic results. However, extensive restorative work on anomalous teeth may not be practical, in view of the large coronal pulp chambers and thin enamel and dentin.<sup>4</sup>


In cases where parents and patients prefer not to retain anomalous teeth, extraction and replacement with a removable prosthesis would be required.<sup>11</sup> Autotransplantation with sound teeth from unaffected quadrants could also be a viable option,<sup>2,5</sup> but this is limited by the availability of suitable donor teeth.

The long-term prognosis for the anomalous central incisor and second premolar is poor because of the poorly developed coronal and radicular structures. Extraction of these teeth will be necessary when the patient's skeletal growth is completed. The first premolar, despite having a malformed crown, has developed a relatively well-formed root. Extracoronal restoration could probably be attempted after elective endodontic treatment and core buildup.<sup>13</sup> Should this be unsuccessful, the area could be incorporated into the final rehabilitation plan. Definitive rehabilitation may consist of dental implants, fixed or removable prostheses or a combination of these.<sup>2</sup>

## Conclusions

A case of conservative management of RO is presented. As seen in this case, affected teeth might show different degrees of malformation. Although those with gross hypoplasia and infection should be extracted, others that are free from infection can be retained. The treatment plan should be based on degree of involvement as well as functional and esthetic needs in individual cases. ♦

## THE AUTHOR



*Dr. Cho is senior dental officer in the school dental care service, department of health, Hong Kong.*

**Correspondence to:** Dr. Shiu-yin Cho, Fanling School Dental Clinic, 2/F Fanling Health Center, 2 Pik Fung Road, Fanling, NT, Hong Kong.

*The author has no declared financial interests.*

## References

1. Hamdan MA, Sawair FA, Rajab LD, Hamdan AM, Al-Omari IK. Regional odontodysplasia: a review of the literature and report of a case. *Int J Paediatr Dent* 2004; 14(5):363–70.
2. Cahuana A, Gonzalez Y, Palma C. Clinical management of regional odontodysplasia. *Pediatr Dent* 2005; 27(1):34–9.
3. Ansari G, Reid JS, Fung DE, Creanor SL. Regional odontodysplasia: report of four cases. *Int J Paediatr Dent* 1997; 7(2):107–13.
4. Marques AC, Castro WH, do Carmo MA. Regional odontodysplasia: an unusual case with a conservative approach. *Br Dent J* 1999; 186(10):522–4.
5. von Arx T. Autotransplantation for treatment of regional odontodysplasia. Case report with 6-year follow-up. *Oral Surg Oral Med Oral Pathol Oral Radiol Endod* 1998; 85(3):304–7.
6. Ozer L, Cetiner S, Ersoy E. Regional odontodysplasia: report of a case. *J Clin Pediatr Dent* 2004; 29(1):45–8.
7. Courson F, Bdeoui F, Danan M, Degrange M, Gogly B. Regional odontodysplasia: expression of matrix metalloproteinases and their natural inhibitors. *Oral Surg Oral Med Oral Pathol Oral Radiol Endod* 2003; 95(1):60–6.
8. Guzman R, Elliott MA, Rossie KM. Odontodysplasia in a pediatric patient: literature review and case report. *Pediatr Dent* 1990; 12(1):45–8.
9. Yuan SH, Liu PR, Childers NK. An alternative restorative method for regional odontodysplasia: case report. *Pediatr Dent* 1997; 19(6):421–4.
10. Gomes MP, Modesto A, Cardoso AS, Hespanhol W. Regional odontodysplasia: report of a case involving two separate affected areas. *ASDC J Dent Child* 1999; 66(3):203–7.
11. Gerlach RF, Jorge J Jr, de Almeida OP, Coletta RD, Zaia AA. Regional odontodysplasia. Report of two cases. *Oral Surg Oral Med Oral Pathol Oral Radiol Endod* 1998; 85(3):308–13.
12. Kinirons MJ, O'Brien FV, Gregg TA. Regional odontodysplasia: an evaluation of three cases based on clinical, microradiographic and histopathological findings. *Br Dent J* 1988; 165(4):136–9.
13. Melamed Y, Harnik J, Becker A, Shapira J. Conservative multidisciplinary treatment approach in an unusual odontodysplasia. *ASDC J Dent Child* 1994; 61(2):119–24.
14. Hanks PA, Williams B. Odontodysplasia: report of two cases. *Pediatr Dent* 1998; 20(3):199–203.