

# Twenty-year Follow-up of an Unconventional Intentional Replantation

R. Viswa Chandra, MDS; K. Mahalinga Bhat, BSc, MDS

## Auteur-ressource

Dr Chandra  
Courriel : [viswachandra@hotmail.com](mailto:viswachandra@hotmail.com)



## SOMMAIRE

Pendant de nombreuses années, la réimplantation intentionnelle a servi d'option thérapeutique pour les dents sans pulpe et de stratégie efficace pour les dents qui autrement seraient difficiles, sinon impossibles, à traiter en utilisant le traitement de canal classique. La préservation de la vitalité des cellules dans le ligament parodontal, le nettoyage de tous les débris tissulaires et de toutes les substances irritantes de la surface radulaire, la réalisation d'un bon scellement apical et le renforcement de la structure coronaire sont tous des actes indispensables qui assureront le fonctionnement normal de la dent réimplantée. Dans le présent article, nous faisons rapport sur une réimplantation intentionnelle peu courante d'une deuxième molaire inférieure pour soulager des symptômes persistants. Des obturations rétrogrades ont été placées dans la deuxième molaire, et la chambre pulpaire coronaire a été scellée avec de l'amalgame. Aucune endothérapie n'a été effectuée que ce soit pendant ou après la procédure. Après 20 ans, le patient était asymptomatique, la dent était encore fonctionnelle et une radiographie périapicale intrabuccale de rappel révélait un ligament parodontal intact. De plus, la lamina dura ne montrait aucune récession radulaire microscopiquement visible ni aucune ankylose.

**Mots clés MeSH :** root canal therapy/methods; tooth replantation/methods; treatment outcome

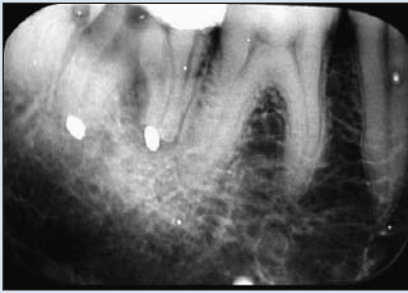© J Can Dent Assoc 2006; 72(7):639-42  
Cet article a été révisé par des pairs.

Intentional replantation is an accepted procedure in which a tooth is extracted and treated outside the oral cavity, then reinserted into its socket to correct an obvious radiographic or clinical endodontic failure.<sup>1</sup> Although traditional root canal therapy (RCT) is preferred and has always been a mainstay of endodontic therapy, intentional replantation has been used for many years to treat pulpless teeth and is considered to be an effective strategy when traditional RCT would be difficult, if not impossible.<sup>2</sup>

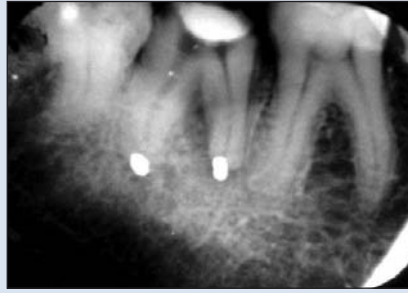Intentional replantation has undergone a sort of revival in recent years. In the field of endodontics, serious questions are being raised as to whether it should be considered a treatment of "last resort," when intracanal or surgical endodontic treatments are not recommended, or as a conventional treatment procedure.<sup>2</sup> It has

also been used in the treatment of vertical fractures,<sup>3</sup> endodontic-periodontic lesions,<sup>4</sup> periodontally involved teeth with a hopeless prognosis<sup>5</sup> and certain anatomical malformations, such as radicular groove.<sup>6</sup>

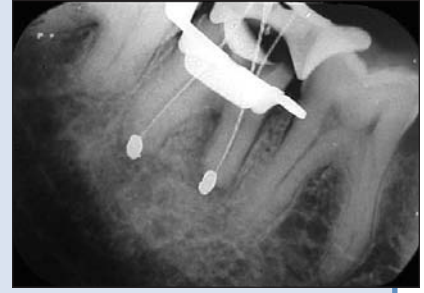The critical event in any reimplantation following avulsion or extraction of a tooth is the preservation of cellular vitality in the periodontal ligament under aseptic conditions.<sup>1,5,7</sup> Regeneration of the periodontal ligament is vital to the survival of the tooth, and ankylosis can result if the tooth is outside the oral environment for more than 1 hour.<sup>1,7</sup> The removal of all tissue debris and irritating substances from the root surface, achievement of a good apical seal and reinforcement of the crown structure are mandatory for normal function.<sup>1,7</sup>



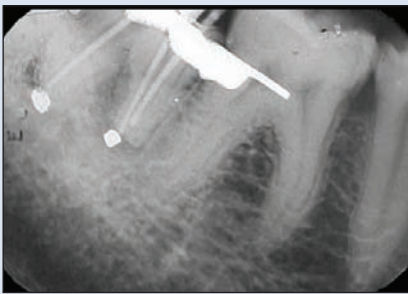
**Figure 1:** Intraoral periapical (IOPA) radiograph taken at the patient's first visit in 2004. Root resorption is distinct but the periodontal ligament space seems to be intact, with slight radiolucency around the mesial root. There is no evidence of ankylosis.



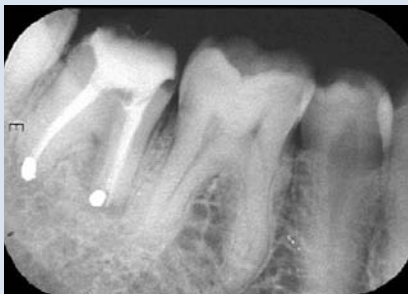**Figure 2:** IOPA radiograph taken in 1984, 6 months after the intentional replantation, shows slight resorption of the mesial root. Retrograde amalgam fillings were placed and the coronal pulp chamber was sealed with amalgam. No biomechanical preparation was done.



**Figure 3:** IOPA radiograph taken during endodontic treatment. A reduction in the radiolucency and the uniform periodontal ligament space can be observed. The lamina dura is distinct around the distal root and on the mesial aspect of the mesial root.



**Figure 4:** IOPA radiograph taken during master cone selection.



**Figure 5:** Postobturation IOPA view showing a healthy periapical area.

## Case Report

In April 2004, a 60-year-old man was referred to the university clinic with the chief complaint of swollen gums and food impaction in the mandibular right molar region. Probing revealed a Grade I furcation in relation to tooth 47 with a 3-mm shallow pocket between teeth 46 and 47. Occlusal analysis revealed a plunger cusp in relation to tooth 17 and a traumatic occlusal relation between teeth 17 and 47. The man's oral hygiene was good and he complained of no other problems. A routine intraoral periapical (IOPA) radiograph showed an all-metal crown with 2 radiopacities that were probably retrograde amalgam fillings (Fig. 1). Slight external resorption of the mesial root was evident, but the distal root did not exhibit any pathology. The patient's dental records revealed an unconventional intentional replantation.

In May 1984, the patient had reported severe pain in the region of tooth 47, which showed a large carious lesion. The tooth was tender on percussion, showed suppuration and was slightly mobile and extruded. The patient was also suffering from low-grade fever at that time and wanted his tooth extracted. A conventional treatment, such as RCT, was not attempted, and the reason is unknown. Intentional replantation was planned, probably to treat the periapical

lesions. The tooth was extracted and pulpal extirpation was carried out. It is unclear whether biomechanical preparation was done, and there is no record of placement of any intracanal medicament or obturation material. The coronal end was sealed with amalgam and retrograde fillings were placed at the root apices. A good apical seal was probably obtained, which was probably crucial in maintaining tooth function and lack of symptoms. The length of the extraoral period is not clear. The tooth was replaced in its socket, no attempt was made to splint the tooth and an IOPA film taken after 6 weeks showed no periapical radiolucency and a normal periodontal ligament space (Fig. 2). An all-metal crown was then placed without obturation of the root canals.

After 20 years, the patient did not have an endodontic problem, but complained of food impaction in relation to teeth 46 and 47. After coronoplasty of tooth 17, thorough supragingival scaling, root planing and curettage in relation to tooth 17 were done. He was then referred for endodontic therapy and RCT was carried out in tooth 47, retaining the retrograde fillings to prevent "flare-ups," which might occur because the root canals were never obturated apart from 2 retrograde fillings and a coronal amalgam seal; these might have contributed to the survivability of the tooth,

but were not considered to provide an ideal endodontic environment<sup>1,7</sup> (Figs. 3 and 4). Although the possibility of the tooth developing an endodontic problem was remote, considering the fact that the tooth was asymptomatic for 20 years, the patient “did not want to have any problems” with the tooth. Recall radiograph approximately 6 months after the RCT showed no periapical radiolucency, normal periodontal ligament space and an intact lamina dura (Fig. 5). A periodontal examination at this time showed normal sulcular depth and normal gingiva. The patient was advised to use floss, and a mouthwash (0.2% chlorhexidine gluconate) was prescribed.

## Discussion

Intentional replantation is an accepted endodontic procedure in cases in which intracanal and surgical endodontic treatments are not recommended.<sup>8</sup> Although not frequently used, intentional replantation is a treatment option that dentists should consider under these conditions. If the standard protocols during intentional replantation are not followed, root resorption and ankylosis may be observed within 1 month and 1–2 months, respectively.<sup>7,8</sup> Most resorptive processes are diagnosed within the first 2–3 years. However, although rare, new resorptive processes could occur even after 5 or 10 years.<sup>7</sup>

As various investigators report varying success rates, it is difficult to predict the outcome for intentional replantation. Bender and Rossman<sup>9</sup> evaluated 31 cases with an overall success rate of 80.6% (6 recorded failures). Replanted teeth survived from 1 day to 22 years. A second mandibular molar that failed after 3 weeks was replanted successfully a second time with no signs of failure after 46 months of follow-up.

Aqrabawi<sup>8</sup> evaluated 2 cases of intentional replantation and retrograde filling of mandibular second molars. At the 5-year recall visit, radiographs showed no evidence of pathologic changes.

Araujo and others<sup>10</sup> demonstrated that processes — including root resorption, ankylosis and new attachment formation — characterized healing of a re-implanted root that had been extracted and deprived of vital cementoblasts. It was also demonstrated that Emdogain (Straumann, Basel, Switzerland) treatment, i.e., conditioning with ethylenediaminetetraacetic acid (EDTA) and placement of enamel matrix proteins on the detached root surface, did not interfere with the healing process.

Nuzzolese and others<sup>11</sup> state that the success rate of intentional replantation at 5 years reported in the literature ranges from 70% to 91%.

Yu and others<sup>4</sup> reported a case where a combined endodontic–periodontic lesion on a mandibular first molar was treated by intentional replantation and application of hydroxyapatite. Four months after the surgery, a porcelain–metal full-crown restoration was completed. At the 15-month follow-up examination, the tooth was clinically and radiographically healthy and functioned well.

Benenati<sup>12</sup> reported a case of nonsurgical endodontic treatment and intentional replantation of a mandibular second molar to relieve continuing symptoms. A 15.5-year follow-up clinical examination found the patient to be asymptomatic, the tooth to be still functional, and a recall film showed no evidence of root resorption.

Peer<sup>2</sup> reviewed 9 cases of intentional replantation that illustrated the feasibility of the procedure for a variety of indications. Only 1 case of replantation showed evidence of pathosis, reflected by root resorption or ankylosis. His report suggests that intentional replantation is a reliable and predictable procedure and should be considered more often as a treatment method to maintain the natural dentition.

Demiralp and others<sup>5</sup> evaluated the clinical and radiographic results of intentional replantation of periodontally involved teeth after conditioning root surfaces with tetracycline-HCl. Thirteen patients (7 women and 6 men; age range: 35–52 years) with 15 periodontally involved “hopeless” teeth were included in this study. During the replantation procedure, the affected teeth were gently extracted and granulation tissues, calculus, remaining periodontal ligament and necrotic cementum on the root surfaces were removed. Tetracycline-HCl, at a concentration of 100 mg/mL, was applied to the root surfaces for 5 minutes. The teeth were then replaced in their sockets and splinted. After 6 months, no root resorption or ankylosis was observed radiographically. Although the period of evaluation was short, the authors suggest that intentional replantation can be an alternative approach to extraction in cases where advanced periodontal destruction is present and no other treatment can be considered.

Majorana and others<sup>13</sup> followed 45 cases of dental trauma for 5 years, recording complications and responses to treatment. Root resorption was observed in 45 cases (17.24%); of these, 9 were associated with luxation injury (20%) and 36 (80%) with avulsion. The authors identified 30 cases of inflammatory root resorption (18 transient and 12 progressive) and 15 cases of ankylosis and osseous replacement.

Shintani and others<sup>14</sup> performed an intentional replantation of an immature lower incisor that had a refractory periapical lesion. The incisor was extracted and the periapical lesion was removed by curettage. The root canal of the tooth was then rapidly irrigated, and filled with a calcium hydroxide and iodoform paste, after which the tooth was fixed with an arch wire splint. Five years later, no clinical or radiographic abnormalities were found, and the root apex was obturated by an apical bridge formation.

Al-Hezaimi and others<sup>6</sup> treated a radicular groove, which predisposed a 15-year-old girl to a severe periodontal defect, with a combination of endodontic, intentional replantation and Emdogain therapy. At 1-year follow-up, the patient was comfortable and active healing was evident.

## Conclusions

In this article, we described a case of an unconventional intentional replantation that showed no evidence of pathosis after 20 years. The initial treatment did not include proper obturation or placement of an intracanal medicament, and such information as extra-alveolar time and the reason for intentional replantation is unknown. The procedure did not seem to cause any damage to the underlying structures, probably because a good apical and coronal seal were obtained, resulting in a healthy periapical–periodontal environment.<sup>1,7</sup> This case is a reminder of the fact that any treatment method has advantages and disadvantages that affect the prognosis for the tooth, and intentional replantation need not negatively influence periodontal healing. ❖

12. Benenati FW. Intentional replantation of a mandibular second molar with long-term follow-up: report of a case. *Dent Traumatol* 2003; 19(4):233–6.
13. Majorana A, Bardellini E, Conti G, Keller E, Pasini S. Root resorption in dental trauma: 45 cases followed for 5 years. *Dent Traumatol* 2003; 19(5):262–5.
14. Shintani S, Tsuji M, Toyosawa S, Ooshima T. Intentional replantation of an immature permanent lower incisor because of a refractory peri-apical lesion: case report and 5-year follow-up. *Int J Paediatr Dent* 2004; 14(3):218–22.

## THE AUTHORS



*Dr. Chandra is a postgraduate student in the department of periodontics, Manipal College of Dental Sciences, Karnataka, India.*



*Dr. Bhat is professor and head of the department of periodontics, Manipal College of Dental Sciences, Karnataka, India.*

**Correspondence to:** Dr. R. Viswa Chandra, Department of Periodontics, Manipal College of Dental Sciences, Manipal-576104, Karnataka, India.

*The authors have no declared financial interests in any company manufacturing the types of products mentioned in this article.*

## References

1. Bakland LK. Endodontic considerations in dental trauma. In: Ingle J, Bakland LK, editors. *Endodontics*. 5th ed. Hamilton: BC Decker Inc.; 2002. p. 795–843.
2. Peer M. Intentional replantation — a ‘last resort’ treatment or a conventional treatment procedure? Nine case reports. *Dent Traumatol* 2004; 20(1):48–55.
3. Hayashi M, Kinomoto Y, Takeshige F, Ebisu S. Prognosis of intentional replantation of vertically fractured roots reconstructed with dentin-bonded resin. *J Endod* 2004; 30(3):145–8.
4. Yu L, Xu B, Wu B. Treatment of combined endodontic-periodontic lesions by intentional replantation and by the application of hydroxyapatites. *Dent Traumatol* 2003; 19(1):60–3.
5. Demiralp B, Nohutcu RM, Tepe DI, Eratalay K. Intentional replantation for periodontally involved hopeless teeth. *Dent Traumatol* 2003; 19(1):45–51.
6. Al-Hezaimi K, Naghshbandi J, Simon JH, Oglesby S, Rotstein I. Successful treatment of a radicular groove by intentional replantation and Emdogain therapy. *Dent Traumatol* 2004; 20(4):226–8.
7. Andreasen JO, Borum MK, Jacobsen HL, Andreasen FM. Replantation of 400 avulsed permanent incisors. 4. Factors related to periodontal ligament healing. *Endod Dent Traumatol* 1995; 11(2):76–89.
8. Aqrabawi J. Five-year follow-up of successful intentional replantation. *Dent Update* 1999; 26(9):388–90.
9. Bender IB, Rossman LE. Intentional replantation of endodontically treated teeth. *Oral Surg Oral Med Oral Pathol* 1993; 76(5):623–30.
10. Araujo M, Hayacibara R, Sonohara M, Cardaropoli G, Lindhe J. Effect of enamel matrix proteins (‘Emdogain’) on healing after the re-implantation of “periodontally compromised” roots. An experimental study in the dog. *J Clin Periodontol* 2003; 30(10):855–61.
11. Nuzzolese E, Cirulli N, Lepore MM, D’Amore A. Intentional dental reimplantation: a case report. *J Contemp Dent Pract* 2004; 5(3):121–30.