

# Rationale for Socket Preservation after Extraction of a Single-Rooted Tooth when Planning for Future Implant Placement

Tassos Irinakis, DDS, Dip Perio, MSc, FRCD(C)

## Auteur-ressource

Dr Irinakis

Courriel : [irinakis@interchange.ubc.ca](mailto:irinakis@interchange.ubc.ca)



## SOMMAIRE

Après l'extraction d'une dent, il arrive fréquemment que la crête alvéolaire diminue de volume et que sa morphologie change. En général, ces changements sont cliniquement importants et ils peuvent rendre difficile l'insertion d'un pont classique ou d'une couronne implantoportée. Et, si la résorption osseuse est suffisamment importante, la mise en place d'un implant peut même devenir extrêmement difficile. Le maintien de la crête alvéolaire après l'extraction réduit au minimum la résorption de la crête résiduelle et permet donc l'insertion d'un implant répondant aux critères esthétiques et fonctionnels. De plus, grâce aux progrès récents dans le domaine des matériaux et des techniques de greffe osseuse, le dentiste peut aujourd'hui mettre en place des implants à des endroits qui auraient auparavant été jugés trop affaiblis. Le présent article traite du profil de guérison des alvéoles, avec et sans l'utilisation de matériaux de régénération, et expose les raisons justifiant la préservation des dimensions de l'alvéole d'extraction. L'auteur passe en revue les données histologiques et cliniques, pour expliquer en détail les fondements en faveur de la préservation de l'alvéole.

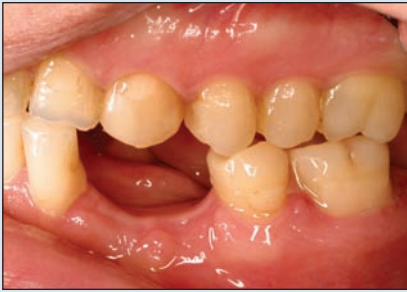**Mots clés MeSH :** alveolar bone loss/prevention & control; bone regeneration; tooth extraction/adverse effects; wound healing

© J Can Dent Assoc 2006; 72(10):917-22  
Cet article a été révisé par des pairs.

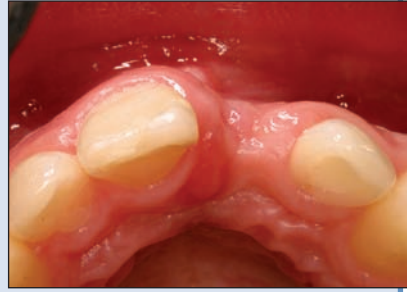Loss of alveolar bone may be attributed to a variety of factors, such as endodontic pathology, periodontitis, facial trauma and aggressive maneuvers during extractions. Millions of teeth are still extracted annually in North America. Most extractions are done with no regard for maintaining the alveolar ridge.<sup>1,2</sup>

Whether due to caries, trauma or advanced periodontal disease, tooth extraction and subsequent healing of the socket commonly result in osseous deformities of the alveolar ridge, including reduced height (Fig. 1) and reduced width (Fig. 2) of the residual ridge.<sup>2</sup> The severity of the healing pattern may pose a problem for the clinician in 2 ways: it creates an esthetic problem in the fabrication of

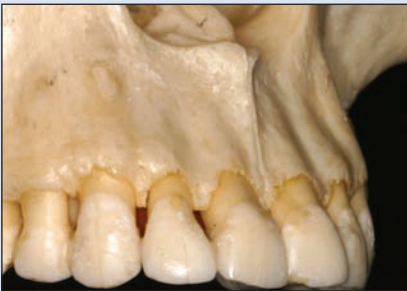an implant-supported restoration or a conventional prosthesis; and it may make the placement of an implant challenging if not unfeasible.<sup>3</sup> However, it is possible to minimize such problems by simply carrying out ridge preservation procedures in extraction sockets using grafting materials with or without barrier membranes.<sup>4,5</sup> Several studies, clinical case series and literature reviews in peer-reviewed journals were examined in detail to establish a rationale for using socket preservation as a therapeutic option following tooth extraction. This review offers information that can be useful to the clinician who chooses to implement this procedure in his or her practice, but it should not be viewed as a "recipe" for socket preservation.



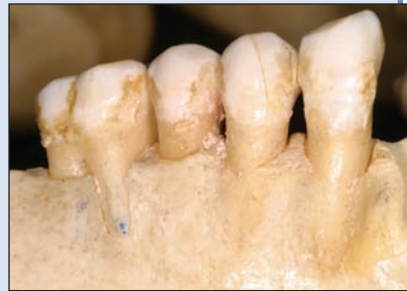**Figure 1:** Reduced height of the alveolar ridge following extraction of the lower left canine and first premolar.



**Figure 2:** “Collapse” of the buccal socket wall 2 months after extraction of the upper left central incisor. Bone grafting will be necessary if the patient wants an implant.



**Figure 3:** The thin, fragile facial socket wall of the upper anterior teeth is susceptible to damage during extraction maneuvers.



**Figure 4:** When a dehiscence is present, the buccolingual dimension of the postextraction ridge is likely to pose challenges for future implant placement.

### Socket–Alveolus Healing

Jahangiri and others<sup>6</sup> provide a current perspective on residual ridge remodelling, beginning with the cascade of inflammatory reactions that is activated immediately after tooth extraction. The socket fills with blood from the severed vessels, which contain proteins and damaged cells. These cells initiate a series of events that will lead to the formation of a fibrin network, which, along with platelets, forms a “blood clot” or “coagulum” within the first 24 hours.<sup>7</sup> Acting as a physical matrix, the coagulum directs the movement of cells, including mesenchymal cells, as well as growth factors. Neutrophils and later macrophages enter the wound site and digest bacteria and tissue debris to sterilize the wound. They release growth factors and cytokines that will induce and amplify the migration of mesenchymal cells and their synthetic activity within the coagulum.<sup>8</sup>

Within a few days, the blood clot begins to break down (fibrinolysis). The proliferation of mesenchymal cells leads to gradual replacement of the coagulum by granulation tissue (2–4 days).<sup>9</sup> By the end of 1 week, a vascular network is formed and by 2 weeks the marginal portion of the extraction socket is covered with young connective tissue rich in vessels and inflammatory cells.<sup>10</sup> By 4–6 weeks, most parts of the alveolus are filled with woven bone, while

the soft tissue becomes keratinized. At 4–6 months, the mineral tissue within the original socket is reinforced with layers of lamellar bone that is deposited on the previously formed woven bone.<sup>8–10</sup> Although bone deposition in the socket will continue for several months, it will not reach the coronal bone level of the neighbouring teeth.<sup>11</sup>

### Patterns of Jaw Resorption

Clinical and cephalometric studies from the 1950s to the 1970s described the resorption process in the postextraction anterior ridge of the edentulous mandible.<sup>12–15</sup> Atwood<sup>13</sup> divided factors affecting the rate of resorption into 4 categories: anatomic, metabolic, functional and prosthetic. Tallgren<sup>16</sup> demonstrated 400% higher residual ridge resorption in the mandible compared with the maxilla.

Regarding the surfaces most affected by extractions, some classic studies have demonstrated that postextraction alveolar resorption is significantly larger in the buccal aspect in both jaws.<sup>17–20</sup> This can easily be understood if one looks closely at the labial anatomy of the alveolar bone surrounding the upper

and lower teeth. The margins of the facial alveoli are thin, mostly cortical (though in rare cases, they contain cancellous bone), knife-edged and frail (**Fig. 3**). When exposed to the trauma caused by extraction maneuvers, the jaw bone is predisposed to resorptive patterns that may lead to unfavourable conditions for implant placement.<sup>2</sup> Commonly, postextraction osseous remodelling also takes place in the presence of dehiscences and fenestrations that magnify the problem, the end result being buccal concavity in the alveolar bone (**Fig. 4**).

The degree of residual ridge resorption is closely related to the time since tooth extraction<sup>14,21,22</sup> — in both maxilla and mandible. The loss of tissue contour is greatest in the early postextraction period (within 6 months).<sup>17–19</sup> Apparently, the healing of sockets in the maxilla progresses faster (because of the greater vascular supply) than those in the mandible, which could lead to a faster resorption pattern.<sup>23</sup>

Several recent studies have examined resorption patterns following single-tooth extraction. Using subtraction radiography, Schropp and others<sup>11</sup> assessed, in a 12-month prospective study, bone formation in the alveolus and changes in the contour of the alveolar process following single-tooth extraction. The width of the alveolar ridge decreased 50%

**Table 1** Advantages, disadvantages and examples of the 2 major membrane categories used in guided bone regeneration procedures including socket preservation

Membrane category	Advantages	Disadvantages	Commercial examples
Nonresorbable	<ul style="list-style-type: none"> <li>Numerous studies demonstrate their success</li> <li>May be titanium reinforced</li> <li>Remain intact until removal</li> <li>Easily attached with titanium or resorbable tacks</li> <li>Greater bone fill if membrane not exposed</li> <li>Minimal tissue response if membrane not exposed</li> </ul>	<ul style="list-style-type: none"> <li>Require a second surgery for removal</li> <li>Increase patient morbidity</li> <li>If exposed, must be removed</li> <li>Can be technique sensitive</li> </ul>	<ul style="list-style-type: none"> <li>ePTFE membranes, e.g., Gore-Tex (Gore Medical, Flagstaff, Ariz.)</li> <li>Titanium-reinforced Gore-Tex</li> </ul>
Resorbable	<ul style="list-style-type: none"> <li>Numerous studies demonstrate their success</li> <li>Does not require surgical removal</li> <li>Decreased patient morbidity</li> <li>Improved soft-tissue healing</li> <li>Tissue-friendly reaction to membrane exposure</li> <li>Cost effective; one surgery only</li> <li>Does not have to be removed if exposed</li> </ul>	<ul style="list-style-type: none"> <li>Uncertain duration of barrier membrane function</li> <li>Difficult to tack down</li> <li>Slightly less bone fill than nonresorbable membranes</li> <li>Inflammatory response from tissues may interfere with healing and GBR</li> <li>Can be technique sensitive</li> </ul>	<ul style="list-style-type: none"> <li>Neomem (bovine collagen matrix; Citagenix Inc., Laval, Que.)</li> <li>Bio-Gide (porcine collagen matrix; Geistlich AG, Wolhusen, Switzerland)</li> <li>Ossix (cross-linked collagen barrier; Implant Innovations Inc., Palm Beach Gardens, Fla.)</li> </ul>

ePTFE = expanded polytetrafluoroethylene; GBR = guided bone regeneration

(from 12 mm to 5.9 mm, on average), and two-thirds of the reduction occurred within the first 3 months. The percentage reduction was somewhat larger in the molar compared with the premolar region. Changes in bone height, however, were only slight (less than 1 mm). The level of bone regenerated in the extraction socket never reached the coronal level of bone attached to the tooth surfaces distal and mesial to the extraction site. The bone surface becomes “curved” apically.

Lekovic and coworkers<sup>3</sup> evaluated the clinical effectiveness of a bioabsorbable membrane in preserving alveolar ridges following single-tooth extraction in a split-mouth prospective study. At the 6-month re-entry appointment, they found an average loss of alveolar height and width of 1.50 mm and 4.56 mm, respectively, in the healed sockets.

### Using Membranes and Bone Grafts in Sockets

In the study by Lekovic,<sup>3</sup> the average loss of alveolar height and width in sockets that were left to heal with only a membrane covering them was 0.38 mm and 1.32 mm, respectively, considerably less than the average loss in sockets that healed naturally. In addition, the quality of the bone in sockets that have healed in the presence of a barrier membrane is excellent for implant placement.<sup>24</sup>

A wide range of barrier membranes have been used in numerous studies over the years, e.g., expanded polyte-

trafluoroethylene (ePTFE), collagen, polyglycolic acid and polyglactin 910. However, these can be grouped into 2 major categories: nonresorbable and resorbable membranes. The advantages and disadvantages of various membranes are presented in **Table 1** along with examples of commercial products. As the time for resorption of these membranes differs, the clinician should follow manufacturers’ directions.

The literature justifies the use of bone grafting materials in freshly extracted sockets.<sup>25,26</sup> When demineralized freeze-dried bone allograft (DFDBA) was used in conjunction with a collagen membrane, the width of the alveolar ridge decreased from 9.2 mm to 8.0 mm, while the width of the socket sites that healed naturally decreased from 9.1 mm to 6.4 mm on average.<sup>25</sup> In addition, the average loss of bone height in the latter group was 1 mm, while the grafted sites actually gained height. Even with no barrier membrane, a socket fill of nearly 85% can be achieved by placing porous bovine bone mineral in fresh extraction sites.<sup>26</sup>

### Bone-to-Implant Contact in Grafted Sockets

Some researchers might argue that the quality of the bone in grafted sockets may not be adequate for implant placement. Thus, various grafting materials have been used to preserve the socket or augment the lateral ridge before

**Table 2** Sources of grafting material for guided bone regeneration

Type of bone graft	Source of the grafting material
Autogenous grafts (autografts)	Material is transferred from one position to another within the same individual. Graft may be intraoral or extraoral depending on the site of harvest.
Allografts	Material is transferred from a donor of the same species. The most common grafts are freeze-dried bone grafts, which may be mineralized or demineralized.
Xenografts	Material is transferred from a donor of another species, processed appropriately. Primarily porous deproteinized bovine bone mineral.
Alloplasts	Synthetic materials, usually inert, used as a substitute for bone grafts.

implant placement (Table 2). When placing xenografts (Fig. 5) or DFDBA in fresh extraction sockets, Becker and others<sup>27</sup> found that there was minimal vital bone-to-implant contact (BIC). However, in this study, the histologic core samples were taken within 3–6 months of extraction when it is common to wait 6–9 months to place implants when using these materials. Thus, the cores may have been taken too early to provide appropriate information. In a different study examining the healing of sockets filled with bioactive glass (alloplastic synthetic bone substitute), a very long healing time was required for even a small amount of new bone to be incorporated into the graft.<sup>28</sup>

Several studies have investigated BIC between regenerated or natural bone and rough or machined-surface implants. Trisi and colleagues<sup>29</sup> examined the posterior maxilla, where bone is generally of poor quality, investigating the BIC at 2 and 6 months. For rough-surfaced implants (dual acid-etched), there was 48% BIC at 2 months and 72% BIC at 6 months, compared with only 19% and 34%, respectively, for machined-surface implants. Similar results were noted in an animal study, in which there was 74% BIC in type IV bone (poor-quality bone) at 6 months on titanium porous oxide (TiUnite, Nobel Biocare, Gothenburg, Sweden) implants.<sup>30</sup>

When sockets are filled with grafting material, graft remnants usually remain at the time of implant placement. In one study,<sup>31</sup> bovine bone mineral contained about 30% particles at 6 months. In a different study<sup>32</sup> in which DFDBA was used, the rate at which graft material was replaced by new vital bone was very slow and incomplete even at 4 years; however, from a clinical point of view, the load-bearing capacity of the regenerated bone appeared to be similar to that of normal bone. Valentini and colleagues<sup>33</sup> found that BIC at sites grafted with bovine bone mineral was greater than or equal to that in nongrafted sites; histologic analysis 6 months after grafting showed a BIC of 73% in grafted vs. 63% in nongrafted areas. Comparison of the torque necessary to remove implants 6 months after placement showed no statistically significant differences between grafted and nongrafted sites, supporting the successful osseointegration of implants in grafted sites.<sup>34</sup>

Success rates are also satisfactory when placing implants in previously grafted bone. In a retrospective study of 607 titanium plasma sprayed implants placed in regenerated bone (with DFDBA), 97.2% of maxilla implants and 97.4% of mandible implants were successful for an average of 11 years.<sup>35</sup> Even higher success rates in augmented bone have been reported by Simion and coworkers.<sup>36</sup> These numbers compare very favourably with the success rates for implants placed in pristine bone.<sup>37–41</sup>

## Conclusions

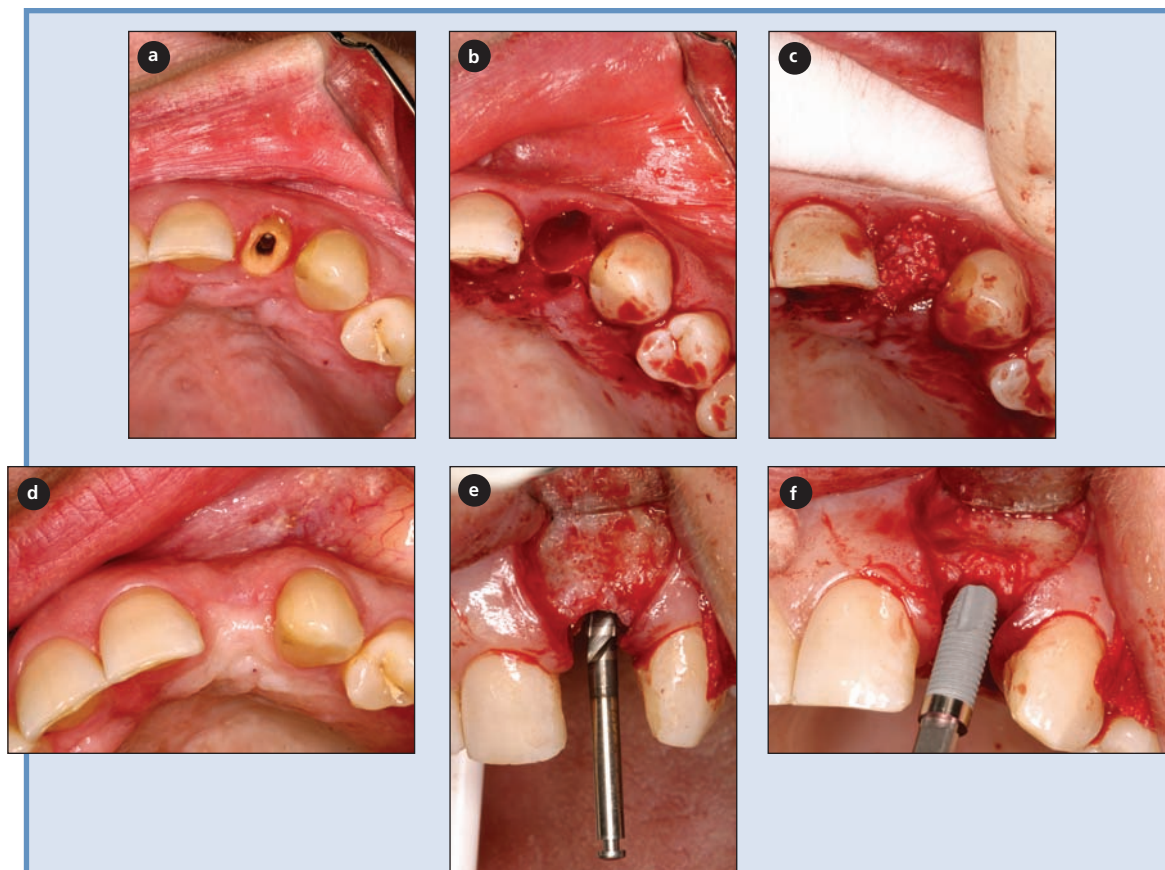
The success of osseointegrated dental implants depends on whether there is a sufficient volume of healthy bone at the recipient site at the time of implant placement. The placement of an implant at a site with a thin crestal ridge (e.g., postextraction ridge) could result in a significant buccal dehiscence. Thus, it seems prudent to prevent alveolar ridge destruction and make efforts to preserve it during extraction procedures.

Maintenance of an extraction socket for future implant therapy does not exclude immediate implant placement, but knowledge and experience are needed to determine the best treatment modality. Postextraction treatment options may include, but are not limited to, immediate implant placement; natural socket healing and delayed implant placement; natural healing and future osseous ridge augmentation (for implant or fixed partial denture); natural healing and future soft tissue ridge augmentation (for fixed partial denture); natural healing and removable partial denture.

There are various reasons why the surgeon may not wish to follow a particular treatment option. These reasons could also be viewed as limitations to socket preservation with bone grafting. Examples of potential problems are lack of adequate apical bone to begin with for primary anchorage of the implant; lack of buccal socket wall; area where esthetics are important and the surgeon prefers to wait for tissue settlement; the indications for immediate implant placement are stronger; lack of experience of the dentist in selecting appropriate materials and techniques; indecisive patient; inability of patient to cover the cost.

Regardless of the reasons for socket preservation, there seems to be a consensus that sufficient alveolar bone vo-





**Figure 5:** Upper lateral incisor (a) that was extracted using periosteal elevators (thus avoiding trauma to the socket walls); its socket (b) was then filled with porous bovine bone mineral (c). Images d to f were taken after 6 months of healing and show successful preservation of the ridge for placement of a narrow-platform implant.

lume and favourable architecture of the alveolar ridge are essential to achieve ideal functional and esthetic prosthetic reconstruction following implant therapy.<sup>1</sup> Preserving or reconstructing the extraction socket of a failed tooth according to the principles of guided bone regeneration enhances our ability to provide esthetically pleasing restorations to our patients without violating the predictability and function of those prostheses. ❖

## THE AUTHOR



**Dr. Irinakis** is associate clinical professor and director of graduate periodontics and implant surgery at the University of British Columbia, Vancouver, British Columbia. He is also in part-time private practice in periodontics and implant dentistry in Vancouver and Coquitlam, B.C.

**Correspondence to:** Dr. Tassos Irinakis, Faculty of Dentistry, University of British Columbia, 2199 Wesbrook Mall, Vancouver, BC V6T 1Z3.

The author has no declared financial interests in any company manufacturing the types of products mentioned in this article.

## References

1. Marcus SE, Drury TF, Brown LJ, Zion GR. Tooth retention and tooth loss in the permanent dentition of adults: United States, 1988–1991. *J Dent Res* 1996; 75(Spec no.):684–95.
2. Meall RA, Rosenfeld AL. Influence of residual ridge resorption patterns on implant fixture placement and tooth position. 1. *Int J Periodontics Restorative Dent* 1991; 11(1):8–23.
3. Lekovic V, Camargo PM, Klokkevold PR, Weinlaender M, Kenney EB, Dimitrijevic B, and other. Preservation of alveolar bone in extraction sockets using bioabsorbable membranes. *J Periodontol* 1998; 69(9):1044–9.
4. Zubillaga G, Von Hagen S, Simon BI, Deasy MJ. Changes in alveolar bone height and width following post-extraction ridge augmentation using a fixed bioabsorbable membrane and demineralized freeze-dried bone osteoinductive graft. *J Periodontol* 2003; 74(7):965–75.
5. Winkler S. Implant site development and alveolar bone resorption patterns. *J Oral Implantol* 2002; 28(5):226–9.
6. Jahangiri L, Devlin H, Ting K, Nishimura I. Current perspectives in residual ridge remodeling and its clinical implications: a review. *J Prosthet Dent* 1998; 80(2):224–37.
7. Amler MH. The time sequence of tissue regeneration in human extraction wounds. *Oral Surg Oral Med Oral Pathol* 1969; 27(3):309–18.
8. Lin WL, McCulloch CA, Cho MI. Differentiation of periodontal ligament fibroblasts into osteoblasts during socket healing after tooth extraction in the rat. *Anat Rec* 1994; 240(4):492–506.

9. Araujo MG, Berglundh T, Lindhe J. On the dynamics of periodontal tissue formation in degree III furcation defects. An experimental study in dogs. *J Clin Periodontol* 1997; 24(10):738–46.
10. Cardaropoli G, Araujo M, Lindhe J. Dynamics of bone tissue formation in tooth extraction sites. An experimental study in dogs. *J Clin Periodontol* 2003; 30(9):809–18.
11. Schropp L, Wenzel A, Kostopoulos L, Karring T. Bone healing and soft tissue contour changes following single-tooth extraction: a clinical and radiographic 12-month prospective study. *Int J Periodontics Restorative Dent* 2003; 23(4):313–23.
12. Atwood DA. Some clinical factors related to rate of resorption of residual ridges. 1962. *J Prosthet Dent* 2001; 86(2):119–25.
13. Atwood DA. A cephalometric study of the clinical rest position of the mandible. Part II. The variability in the rate of bone loss following the removal of occlusal contacts. *J Prosthet Dent* 1957; 7:544–52.
14. Tallgren A. The continuing reduction of the residual alveolar ridges in complete denture wearers: a mixed-longitudinal study covering 25 years. *J Prosthet Dent* 1972; 27(2):120–32.
15. Carlsson GE, Bergman B, Hedegard B. Changes in contour of the maxillary alveolar process under immediate dentures. A longitudinal clinical and x-ray cephalometric study covering 5 years. *Acta Odontol Scand* 1967; 25(1):45–75.
16. Tallgren A. Changes in adult face height due to aging, wear and loss of teeth and prosthetic treatment. *Acta Odontol Scand* 1957; 15(suppl. 24): 73–122.
17. Pietrokovski J, Massler M. Alveolar ridge resorption following tooth extraction. *J Prosthet Dent* 1967; 17(1):21–7.
18. Johnson K. A study of the dimensional changes occurring in the maxilla following tooth extraction. *Aust Dent J* 1969; 14(4):241–4.
19. Lam RV. Contour changes of the alveolar processes following extractions. *J Prosthet Dent* 1960; 10:25–32.
20. Carlsson GE, Persson G. Morphological changes of the mandible after extraction and wearing of dentures. A longitudinal, clinical, and x-ray cephalometric study covering 5 years. *Odontol Revy* 1967; 18(1):27–54.
21. Humphries S, Devlin H, Worthington H. A radiographic investigation into bone resorption of mandibular alveolar bone in elderly edentulous adults. *J Dent* 1989; 17(2):94–6.
22. Ulm C, Solar P, Blahout R, Matejka M, Gruber H. Reduction of the compact and cancellous bone substances of the edentulous mandible caused by resorption. *Oral Surg Oral Med Oral Pathol* 1992; 74(2):131–6.
23. Soehren SE, Van Swol RL. The healing extraction site: a donor area for periodontal grafting material. *J Periodontol* 1979; 50(3):128–33.
24. Carmagnola D, Adriaens P, Berglundh T. Healing of human extraction sockets filled with Bio-Oss. *Clin Oral Implants Res* 2003; 14(2):137–43.
25. Iasella JM, Greenwell H, Miller RL, Hill M, Drisko C, Bohra AA, and other. Ridge preservation with freeze-dried bone allograft and a collagen membrane compared to extraction alone for implant site development: a clinical and histologic study in humans. *J Periodontol* 2003; 74(7):990–9.
26. Artzi Z, Tal H, Dayan D. Porous bovine bone mineral in healing of human extraction sockets. Part 1: Histomorphometric evaluations at 9 months. *J Periodontol* 2000; 71(6):1015–23.
27. Becker W, Clokie C, Sennerby L, Urist MR, Becker BE. Histologic findings after implantation and evaluation of different grafting materials and titanium micro screws into extraction sockets: case reports. *J Periodontol* 1998; 69(4):414–21.
28. Norton MR, Wilson J. Dental implants placed in extraction sites implanted with bioactive glass: human histology and clinical outcome. *Int J Oral Maxillofac Implants* 2002; 17(2):249–57.
29. Trisi P, Lazzara R, Rebaudi A, Rao W, Testori T, Porter SS. Bone-implant contact on machined and dual acid-etched surfaces after 2 months of healing in the human maxilla. *J Periodontol* 2003; 74(7):945–56.
30. Huang YH, Xiropaidis A, Sorensen RG, Albandar JM, Hall J, Wikesjo UM. Bone formation at titanium porous oxide (TiUnite) oral implants in type IV bone. *Clin Oral Implants Res* 2005; 16(1):105–11.
31. Zitzmann NU, Scharer P, Marinello CP, Schupbach P, Berglundh T. Alveolar ridge augmentation with Bio-Oss: a histologic study in humans. *Int J Periodontics Restorative Dent* 2001; 21(3):288–95.
32. Simion M, Trisi P, Piattelli A. GBR with an e-PTFE membrane associated with DFDBA: histologic and histochemical analysis in a human implant retrieved after 4 years of loading. *Int J Periodontics Restorative Dent* 1996; 16(4):338–47.
33. Valentini P, Abensur D, Densari D, Graziani JN, Hammerle C. Histological evaluation of Bio-Oss in a 2-stage sinus floor elevation and implantation procedure. A human case report. *Clin Oral Implants Res* 1998; 9(1):59–64.
34. Kohal RJ, Mellas P, Hurzeler MB, Trejo PM, Morrison E, Caffesse RG. The effects of guided bone regeneration and grafting on implants placed into immediate extraction sockets. An experimental study in dogs. *J Periodontol* 1998; 69(8):927–37.
35. Fugazzotto PA. Success and failure rates of osseointegrated implants in function in regenerated bone for 72 to 133 months. *Int J Oral Maxillofac Implants* 2005; 20(1):77–83.
36. Simion M, Jovanovic SA, Tinti C, Benfenati SP. Long-term evaluation of osseointegrated implants inserted at the time or after vertical ridge augmentation. A retrospective study on 123 implants with 1–5 year follow-up. *Clin Oral Implants Res* 2001; 12(1):35–45.
37. Karoussis IK, Bragger U, Salvi GE, Burgin W, Lang NP. Effect of implant design on survival and success rates of titanium oral implants: a 10-year prospective cohort study of the ITI Dental Implant System. *Clin Oral Implants Res* 2004; 15(1):8–17.
38. Buser D, Mericske-Stern R, Bernard JP, Behneke A, Behneke N, Hirt HP, and others. Long-term evaluation of non-submerged ITI implants. Part 1: 8-year life table analysis of a prospective multi-center study with 2359 implants. *Clin Oral Implants Res* 1997; 8(3):161–72.
39. Romeo E, Chiapasco M, Ghisolfi M, Vogel G. Long-term clinical effectiveness of oral implants in the treatment of partial edentulism. Seven-year life table analysis of a prospective study with ITI dental implants system used for single-tooth restorations. *Clin Oral Implants Res* 2002; 13(2):133–43.
40. Ferrigno N, Laureti M, Fanali S, Grippaudo G. A long-term follow-up study of non-submerged ITI implants in the treatment of totally edentulous jaws. Part I: Ten-year life table analysis of a prospective multicenter study with 1286 implants. *Clin Oral Implants Res* 2002;13(3):260–73.
41. Fugazzotto PA, Beagle JR, Ganeles J, Jaffin R, Vlassis J, Kumar A. Success and failure rates of 9 mm or shorter implants in the replacement of missing maxillary molars when restored with individual crowns: preliminary results 0 to 84 months in function. A retrospective study. *J Periodontol* 2004; 75(2):327–32.