

Aspiration of an Extracted Molar: Case Report

Juan C. Ospina, MD, Jeffrey P. Ludemann, MD, FRCSC

Auteur-ressource

Dr Ludemann

Courriel :

jludemann@cw.bc.ca



SOMMAIRE

On présente ici un cas d'aspiration d'une molaire extraite. Le principal objectif de l'article est d'offrir aux collègues dentistes un outil éducatif sur le cas d'aspiration d'un corps étranger pour aider à prévenir le diagnostic tardif de telles situations à l'avenir.

© J Can Dent Assoc 2005; 71(8):581-3
Cet article a été révisé par des pairs.

Mots clés MeSH : bronchi; bronchoscopy; foreign bodies/therapy; tooth

Foreign-body aspiration is serious and potentially fatal. Early diagnosis is key to the prevention of complications.^{1,2} Correct interpretation and integration of history, physical examination and radiographic evidence are necessary to achieve an early diagnosis of foreign-body aspiration.³

Case Report

A dentist extracted a molar from an 8-year-old boy under local anesthesia.

According to the patient and his mother, at the moment of extraction of the molar, he cried then had a severe coughing fit. The dentist told them that the molar had probably been swallowed. The patient was prescribed amoxicillin for 7 days and sent home without investigation.

For a few days, the patient had occasional coughing paroxysms, but otherwise felt well. Then, 12 days after the extraction, he developed fever (39°C) and right pleuritic pain. He presented to his community emergency room, where he was found to have crackles in the right pulmonary base, but no respiratory distress and normal oxygen saturation. Chest radiographs (Figs. 1 and 2) revealed a molar in the bronchus intermedius, atelectasis in the right-middle and lower lobe, and mediastinal shift to the right.

He was transferred to BC Children's Hospital and underwent rigid laryngobronchoscopy under general anesthesia with spontaneous respirations. Telescopic examination revealed a small amount of granulation tissue surrounding the molar in

the bronchus intermedius. The molar was grasped with sharp-toothed optical forceps and carefully removed. The bronchoscope was reinserted and a large amount of mucopurulent fluid was suctioned from the bronchi distal to the granulation tissue.

The patient was treated with intravenous clindamycin and cefuroxime, plus inhaled steroids and chest physiotherapy. By the next day, his pleuritic pain, cough and fever had resolved and radiographs revealed complete pulmonary re-expansion. He was discharged home on amoxicillin/clavulanic acid and inhaled steroids for 7 days and made a complete recovery.

Discussion

Most cases of aspiration of teeth and other dental material occur secondary to blunt maxillofacial trauma.^{4,5} Aspiration of deciduous teeth is surprisingly uncommon, especially considering how often young children aspirate nuts, raw carrot fragments and other small, hard objects.³

In 1920, Hedblom⁶ reported 32 cases of aspiration of extracted teeth. Subsequently, few such reports have appeared in the literature. Nonetheless, aspiration of extracted teeth remains an important and serious clinical situation.

In this report, the key sign that the patient had aspirated the molar was his coughing paroxysm. When a dental patient has a coughing paroxysm and not all teeth and foreign objects can be accounted for, chest radiography is

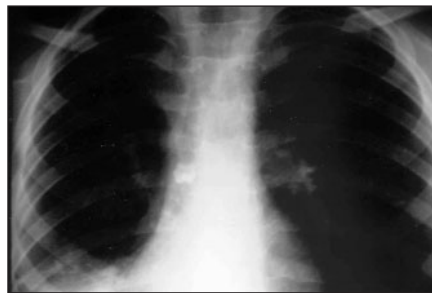

Figure 1: Anteroposterior chest radiograph showing a molar in the bronchus intermedium; atelectasis in the right-middle and lower lobe; and a mediastinal shift to the right.

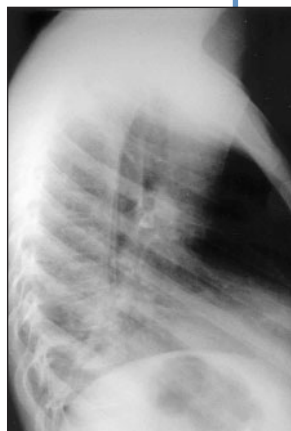


Figure 2: The molar is at the centre of this lateral chest radiograph; distal atelectasis is also apparent.

mandatory. Teeth and metal objects are clearly visible on radiographs. However, when aspiration of a radiolucent material is suspected, diagnosis will be more difficult and must be based on integration of history, physical exam and radiology, along with an understanding of the natural history of bronchial foreign bodies.

As Jackson and Jackson⁷ initially described in the early 1900s, there are 3 clinical phases in bronchial foreign-body aspiration. The initial *acute phase* is characterized by a coughing paroxysm that lasts at least a few minutes.

Next is a *quiescent phase*, in which the patient is relatively asymptomatic. During this phase, however, the foreign body creates a bronchial check-valve, allowing ingress of air during inspiration, but partly preventing egress of air during expiration. This results in an expiratory wheeze that is loudest over the ipsilateral lung. It also results in obstructive emphysema, which may be seen radiographically on expiratory films as ipsilateral pulmonary hyperinflation and contralateral mediastinal shift. These clinical findings would have been noted in this case, had they been sought after the patient's initial coughing fit.

About one week later, once the bronchial mucosa becomes tightly swollen around the foreign body, a stop-valve is created and the distal pulmonary tissue collapses and becomes infected. This is the *complication phase*. If prolonged, it may result in chronic bronchitis and bronchopneumonia.

Since 1974, there have been 3 reports of cases in which diagnosis of adult patients with an aspirated tooth was delayed until the complication stage. One patient failed initial antibiotic therapy for endobronchial actinomycosis,⁸ one patient was initially misdiagnosed with bronchial cancer,⁹ and one patient had a respiratory arrest and died of sepsis 12 days later.¹⁰ In each case, chest radiographs revealing the bronchial tooth had initially been misread.

The sooner a bronchial foreign body is diagnosed, the easier it is to remove. In this case, the surrounding bronchial granulation tissue, fortunately, did not bleed significantly or obscure the tooth. Although most bronchial foreign bodies are prone to fragmentation and must be removed with "peanut forceps," in this case, sharp-toothed forceps were ideal for grasping the root of the molar. Generally, a rigid bronchoscope is the best tool for removal of a bronchial foreign body.³ However, if a patient has aspirated a tooth because of maxillofacial trauma and rigid bronchoscopy is contraindicated, then the tooth may be removed with a flexible bronchoscope or, if necessary, tracheotomy.^{4,5} Finally, even before the age of antibiotics, Jackson and Jackson⁷ found that once a bronchial foreign body and distal secretions have been removed, 99% of patients will recover completely.

Conclusion

When a dental patient has a coughing paroxysm and not all teeth and foreign objects can be accounted for, chest radiography is mandatory. Urgent medical evaluation and treatment may be necessary. ♦

THE AUTHORS



Dr. Ospina was pediatric otolaryngology fellow at the BC Children's Hospital, Vancouver, British Columbia, when the article was written.



Dr. Ludemann is a clinical assistant professor of otolaryngology at the University of British Columbia, and attending physician at the ENT clinic of the BC Children's Hospital, Vancouver, British Columbia.

Correspondence to: Dr. Jeffrey P. Ludemann, BC Children's Hospital, 4480 Oak St., Vancouver, BC V6H 3V4. E-mail: jludemann@cw.bc.ca.

The authors have no declared financial interests.

References

1. Reilly J, Thompson J, MacArthur C, Pransky S, Beste D, Smith M, and others. Pediatric aerodigestive foreign body injuries are complications related to timeliness of diagnosis. *Laryngoscope* 1997; 107(1):17–20.
2. Esclamado RM, Richardson MA. Laryngotracheal foreign bodies in children. A comparison with bronchial foreign bodies. *Am J Dis Child* 1987; 141(3):259–62.
3. Ludemann JP, Hughes CA, Holinger LD. Management of foreign bodies of the airway. In: Shields TW, LoCicero J, Ponn RB, editors. *General thoracic surgery*. 5th ed. Philadelphia: Lippencott Williams & Wilkens; 2000. p. 853–61.
4. Tal-Or E, Schwarz Y, Bloom Y, Kluger Y, Roodik V, Sorkin P. Aspirated tooth removal from airway through tracheotomy and flexible bronchoscopy. *J Trauma* 1996; 40(6):1029–30.
5. Fieselmann JF, Zavala DC, Keim LW. Removal of foreign bodies (two teeth) by fiberoptic bronchoscopy. *Chest* 1977; 72(2):241–3.
6. Hedblom CA. Foreign bodies of dental origin in a bronchus pulmonary complication. *Ann Surg* 1920; 71:568–80.
7. Jackson C, Jackson CL. *Bronchoscopy, esophagoscopy and gastroscopy: a manual of peroral endoscopy and laryngeal surgery*. 3rd ed. Philadelphia: W.B.

Saunders Company; 1934.

8. Bergthorsdottir R, Benediktsdottir KR, Thorsteinsson SB, Baldursson O. Endobronchial actinomycosis secondary to a tooth aspiration. *Scan J Infect Dis* 2004; 36(5):384–6.

9. Ochmanski W, Krawczyk K. [Foreign body imitating bronchial neoplasm] *Przegląd Lek* 1997; 54(1):70–2 [Polish].

10. Allison MJ, Pezzia A, Gerszten E, Giffler RF, Mensoza D. Aspiration pneumonia due to teeth — 950 AD and 1973 AD. *South Med J* 1974; 67(4):479–83.