

Sporadic Burkitt's Lymphoma of the Jaws: The Essentials of Prompt Life-saving Referral and Management

(Lymphome de Burkitt sporadique des mâchoires :
nécessité d'une prise en charge rapide par un spécialiste)

- Ahmed Jan, DDS •
- Kashyap Vora, BDS, FDS RCS (Eng) •
- George K.B. Sándor, MD, DDS, PhD, FRCD(C), FRCSC, FACS •

S o m m a i r e

Le lymphome de Burkitt est un lymphome indifférencié non hodgkinien des cellules B. On en reconnaît 3 sous-types cliniques : Africain (endémique), Américain (sporadique) et une forme associée au VIH. Le lymphome sporadique de Burkitt est une tumeur maligne rare dans les populations occidentales. Le présent rapport examine un cas de lymphome sporadique de Burkitt des mâchoires, accompagné d'une diffusion rapide alarmante associée à l'insuffisance rénale aiguë. Ce type de progression rapide indique la nécessité d'un diagnostic rapide et de l'orientation prompte du patient vers un spécialiste afin d'assurer sa survie. Parmi les caractéristiques cliniques du lymphome de Burkitt des mâchoires, on compte des dents en supraocclusion, déplacées ectopiquement et extrêmement mobiles. Le but de ce rapport de cas et du recensement de la littérature est d'illustrer les caractéristiques cliniques et histopathologiques du lymphome de Burkitt afin d'aider les cliniciens à le reconnaître facilement et de diriger rapidement le patient vers un spécialiste, assurant ainsi sa survie.

Mots clés MeSH : Burkitt lymphoma/diagnosis; case report; mandibular neoplasms/pathology

© J Can Dent Assoc 2005; 71(3):165-8
Cet article a été révisé par des pairs.

Burkitt's lymphoma is a malignant tumour of B-cell lymphocyte origin and is classified as a non-Hodgkin's lymphoma (NHL). Three clinical variants are recognized: African (endemic), American (sporadic) and HIV associated.¹ Sporadic Burkitt's lymphoma is a rare malignancy among western populations. In most series, the annual incidence is 2–3 cases per million.²

During the early 20th century, Sir Albert Cook, while in East Africa, described a common malignancy among young African children that predominantly affected the jaws and occasionally various abdominal organs. Half a century later, a surgeon, Denis Burkitt, who was working in Kampala, Uganda, noticed the same lesions on the faces of young African children, with occasional intestinal involvement. In 1958, Burkitt published his findings, calling the lesion "a sarcoma involving the jaws."³ Epstein and others first

demonstrated a herpes virus in a biopsy sample derived from Burkitt's lymphoma in 1964. The virus was later designated Epstein-Barr virus (EBV) and was considered a potential etiologic factor of Burkitt's lymphoma.⁴

Burkitt's lymphoma is probably the fastest growing malignant neoplasm to affect humans. It can double in size in 24 hours with 80% of its cells undergoing mitosis at any point.⁵ The symptoms are rapidly progressive. Multifocal extranodal involvement is common to all subtypes of Burkitt's lymphoma.¹

Burkitt's lymphoma is thought to account for 40% of all childhood NHL.² Its incidence is greatly dependent on geographic location; in equatorial Africa, it accounts for 50% to 75% of all malignancies in children.⁶ Sporadic Burkitt's lymphoma is not as common. Its annual incidence is 2–3 cases

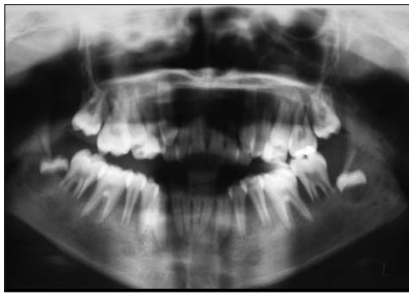


Figure 1: Orthopantomogram showing the displaced teeth germs of the lower third molars coronally and medially relative to their bony crypts. Severe alveolar bone resorption is visible around the lower second molars.

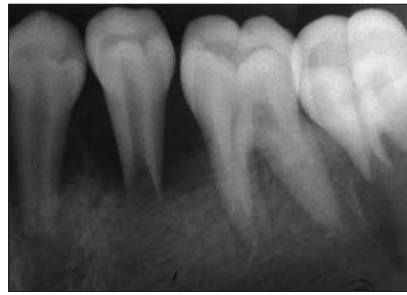


Figure 2: Periapical radiograph showing severe alveolar bone resorption around the lower second premolars.

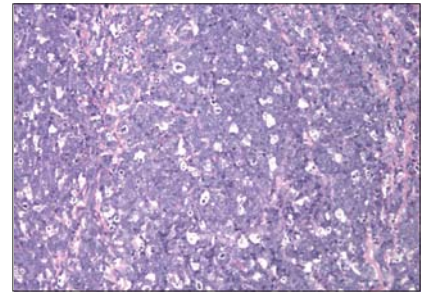


Figure 3: Diffuse sheets of monomorphic lymphoid cells with scattered macrophages producing a "starry sky appearance."

per million. Burkitt's lymphoma accounts for 40% of HIV-associated NHL.²

Endemic Burkitt's lymphoma is usually diagnosed between the ages of 5 and 7 years and involves the jaws as well as other facial bones in 60% to 80% of cases. Less commonly, it involves the abdomen and bone marrow. Endemic Burkitt's lymphoma is virtually always associated with EBV, as positive titres are found in over 90% of cases.⁷

In contrast, sporadic Burkitt's lymphoma is associated with slightly older children (average age 12 years). The abdomen is the most common site of presentation. About 25% of sporadic Burkitt's lymphoma cases involve the head and neck, most commonly in the form of cervical lymphadenopathy. Maxillofacial bony involvement occurs in fewer than 30% of cases. EBV-positive titres are found in only 20% of cases.⁷

Adult Burkitt's lymphoma patients are almost always afflicted with AIDS. Burkitt's lymphoma accounts for 40% of HIV-associated NHL cases.² Like sporadic Burkitt's lymphoma, the HIV-associated variant often involves the abdomen and it involves the bone marrow in 30% of cases. Unlike endemic Burkitt's lymphoma, EBV titres are elevated in only 30% of cases of adult HIV-associated Burkitt's lymphoma.²

Case Report

A 13-year-old white girl was referred to the oral and maxillofacial surgery service of The Hospital for Sick Children in Toronto with the chief complaint of spontaneous intermittent pain in her lower back teeth and inability to chew food comfortably. A month earlier, she had complained to her parents of progressively loosening teeth. The pain had been present for 2 weeks. She was referred by her general dentist to a periodontist, who immediately referred the patient for oral and maxillofacial surgical assessment. The past medical history revealed a diagnosis of microcytic hypochromic anemia and infectious mononucleosis 3 weeks before presentation. Results of a complete blood count and serology were consistent with these 2 diagnoses.

Physical examination revealed a lethargic young woman with obvious pallor. Bilateral palpable mobile submandibular lymph nodes were found in her head and neck. The mandibular

and maxillary divisions of the trigeminal and facial nerves were intact. Generalized teeth mobility ranged from 1+ in upper and lower anterior teeth to 3+ in lower second premolar and second molars. This was noted despite the absence of any visible plaque on the teeth surfaces. Severe buccal expansion of the alveolus next to the lower posterior teeth was noted. Both lower second molars were supra-erupted and in premature occlusal contact with the upper first molars causing a massive open bite. The left lower second molar was more supra-erupted than the right. The gingiva was pale, pink and swollen with spontaneous areas of bleeding.

An orthopantomogram and intraoral periapical radiographs were taken. Severe alveolar bone loss around the lower second premolars as well as the lower second molars was noted (Figs. 1 and 2). These teeth were floating. The developing lower third molars were displaced coronally and medially relative to their crypts, indicating possible infiltration of these structures (Fig. 1).

Based on the clinical examination and past medical and dental history, a decision was made to extract the lower left second molar and perform an incisional biopsy of the soft tissue in the tooth socket.

Histopathology

The histopathology was consistent with diagnosis of a high-grade B-cell NHL with features of Burkitt's lymphoma. Routine hematoxylin- and eosin-stained sections revealed fibrofatty tissue diffusely infiltrated with sheets of a monomorphic population of lymphoid cells. Numerous scattered phagocytic cells all around the section imparted a "starry-sky appearance" (Fig. 3). Immunohistochemical staining was positive for CD20, CD22 and CD79, which are specific for B-cell lymphocytes. CD10 was focally positive, which is consistent with the early phases of B-cell proliferation. MIB1 staining was positive in more than 95% of cells, revealing increased nuclear DNA synthesis.

Definitive Referral

The patient was immediately referred to the hematology–oncology department for assessment and definitive care.

Further laboratory results revealed a secondary diagnosis of acute renal failure necessitating emergency life-saving dialysis. The effects of the patient's renal failure were corrected by the dialysis, she responded well to subsequent chemotherapy and is currently in remission.

Discussion

The differential diagnosis of hypermobile teeth with absent local factors includes: generalized juvenile periodontitis, HIV periodontitis, Langerhan's cell histiocytosis, Papillon-Lefèvre syndrome, hypophosphatasia, cyclic neutropenia, vitamin-D resistant rickets, acrodynia, leukemia and lymphoma. Head and neck involvement occurs in only 25% of sporadic Burkitt's lymphoma cases and most commonly in the form of cervical lymphadenopathy,² which can make the diagnosis quite challenging in contrast to endemic Burkitt's lymphoma.

The clinical findings may vary according to the anatomical site of involvement and the timing of presentation. The range may be from no signs and symptoms to airway obstruction, intestinal obstruction and biliary obstruction. Inferior alveolar nerve parasthesia has also been reported to be the only presenting sign of sporadic Burkitt's lymphoma.⁸ Signs and symptoms of oral Burkitt's lymphoma, including mobile teeth, toothache, oral masses, gingival enlargement, pain, jaw expansion, swelling and sensory disturbances, have been recorded by some workers with pain being the most common presenting symptom.⁷ In this case, pain was also the predominant presenting symptom and generalized mobility of teeth with the absence of any obvious causative factor was the most striking sign. The unusual aspect of this case was the severity of disease, exemplified by the rapidity of the development of acute renal failure, which left untreated would have resulted in a terminal outcome.

Although EBV is strongly considered as a potential etiologic factor of Burkitt's lymphoma, its precise role is not well understood, especially in sporadic Burkitt's lymphoma. EBV is an enveloped herpes virus that contains double-strand linear DNA of 170 to 175 kb in the nucleocapsid.⁹ After entering the oropharynx and adjacent structures, this virus preferentially infects B-cells via the C3d complement receptor, CD21. Primary infection during early childhood is mostly asymptomatic, whereas infection during adolescence results in acute infectious mononucleosis in 30% to 50% of cases.¹⁰ Immunodeficiencies may allow viral reactivation and the excessive proliferation of EBV-infected B-cells, which may lead to the development of EBV positive B-lymphoproliferative diseases or lymphomas.¹¹

Approximately 90% of African Burkitt's lymphoma tumours contain EBV DNA, whereas only 20% of sporadic Burkitt's lymphomas are EBV associated. However, disrupted and aberrant expressions of the viral genome have recently been discovered in the United States in cases of sporadic Burkitt's lymphoma that were diagnosed as EBV negative in standard screening. This suggests that the viral genome itself may be dispensable at some stage of the tumour's

development. There may be greater involvement of EBV in sporadic Burkitt's lymphoma than previously documented, suggesting that EBV DNA may, in some instances, be lost after initiation of the neoplasm. Although screening tests may be insufficient to determine the EBV status of all neoplasms,¹² the data suggest that EBV may play a prominent role in the pathogenesis of Burkitt's lymphoma.¹³

The overexpression of *c-myc* oncogene and the functional loss of wild type p53 gene are considered as possible etiologic factors as well. Immunodeficient patients, particularly those with AIDS, and cardiac or renal transplant patients are more susceptible to developing NHL.¹⁴ Burkitt's lymphoma may be the first manifestation of AIDS in many cases.¹⁵

Investigations for suspected Burkitt's lymphoma should include an incisional biopsy to establish a definitive diagnosis. In the maxillofacial region, plain radiography is usually sufficient but may be augmented by computed tomography and magnetic resonance imaging. In most institutions, lumbar puncture to examine the cerebrospinal fluid is a routine measure to look for malignant cells in the central nervous system.²

Burkitt's lymphoma is one of the first human malignancies shown to be curable by chemotherapy alone. A combination of cyclophosphamide, doxorubicin, vincristine and prednisone is one example of a drug therapy. Radiotherapy is reserved for overt central nervous system disease that is resistant to chemotherapy and is reported to be useful in certain emergencies, such as airway obstruction.⁷ Bone marrow transplantation may be necessary after completion of chemotherapy cycles. The surgical management of Burkitt's lymphoma is limited to biopsy.⁷

The prognosis of Burkitt's lymphoma depends on the extent of the disease, the patient's age and the timing of diagnosis.³ It is excellent in children, where it approaches 100% disease-free survival in early stages and 75% to 85% of patients survive free of disease in later life.⁷ Adults are less fortunate, with a survival rate of 50% to 75%.⁷ Adults are almost always HIV-positive patients and may die of other causes.¹⁶

Conclusion

The role of the dentist in the early diagnosis and prompt referral of patients with Burkitt's lymphoma cannot be overemphasized. Life-threatening complications occur suddenly and unexpectedly in the development of Burkitt's lymphoma. These complications include airway obstruction, abdominal obstruction and acute renal failure, as in this case report.

Dentists must be suspicious when faced with a child patient presenting with unexplained hypermobility of teeth, supra-eruption of permanent teeth and severe alveolar bone resorption around these teeth, where the local etiologic factors of periodontal disease are not present. The unexplained displacement of developing teeth from their crypts is another worrisome sign. Unexplained paresthesia of the mandibular branch of the trigeminal nerve is also ominous. When any of these symptoms or signs exists, the dentist must have a high index of suspicion and act promptly. Failure to refer such a patient in a timely manner may rapidly lead to disastrous consequences. ♦



Dr. Jan is an intern in oral and maxillofacial surgery, University of Toronto, Toronto, Ontario.



Dr. Vora is a fellow in oral and maxillofacial surgery, The Hospital for Sick Children and University of Toronto, Toronto, Ontario.



Dr Sándor is an associate professor and director, graduate program in oral and maxillofacial surgery and anesthesia, University of Toronto, and coordinator of oral and maxillofacial surgery at The Hospital for Sick Children and Bloorview MacMillan Children's Centre, Toronto, Ontario, and docent in oral and maxillofacial surgery, University of Oulu, Oulu, Finland.

Correspondence to: Dr. George K.B. Sándor, The Hospital of Sick Children, S-527, 555 University Ave, Toronto ON M5G 1X8. E-mail: george.sandor@utoronto.ca.

The authors have no declared financial interests.

References

1. Neville BW, Damm DD, Allen CM, Bouquot JE. Oral and maxillofacial pathology. 2nd ed. Philadelphia: W.B. Saunders; 2002. p. 608.
2. Banthia V, Jen A, Kacker A. Sporadic Burkitt's lymphoma of the head and neck in the pediatric population. *Int J Pediat Otorhinolaryngol* 2003; 67(1):59–65.
3. Burkitt D. A sarcoma involving the jaws of African children. *Br J Surg* 1958; 46(197):218–23.
4. Epstein MA, Achong BG, Barr YM. Virus particles in cultured lymphoblasts from Burkitt's lymphoma. *Lancet* 1964; 15:702–3.
5. Durmus E, Oz G, Guler N, Avunduk M, Caliskan U, Blanchaert RH Jr. Intraosseous mandibular lesion. *J Oral Maxillofac Surg* 2003; 61(2):246–9.
6. Shapira J, Peylan-Ramu N. Burkitt's lymphoma. *Oral Oncol* 1998; 34(1):15–23.
7. Ardekian L, Rachmiel A, Rosen D, Abu-el-Naaj I, Peled M, Laufer D. Burkitt's lymphoma of the oral cavity in Israel. *J Craniomaxillofac Surg* 1999; 27(5):294–7.
8. Landesberg R, Yee H, Datikashvili M, Ahmed AN. Unilateral mandibular lip anesthesia as the sole presenting symptom of Burkitt's lymphoma: case report and review of literature. *J Oral Maxillofac Surg* 2001; 59(3):322–6.
9. Bornkamm GW, Hammerschmidt W. Molecular virology of Epstein-Barr virus. *Philos Trans R Soc London B Biol Sci* 2001; 356(1408):437–59.
10. Cohen JI. Epstein-Barr virus infection. *New Engl J Med* 2000; 343(7):481–92.
11. Ohga S, Nomura A, Takada H, Hara T. Immunological aspects of Epstein-Barr virus infection. *Crit Rev Oncol Hematol* 2002; 44(3):203–15.
12. Razzouk BI, Srinivas S, Sample CE, Singh V, Sixbey JW. Epstein-Barr virus DNA recombination and loss in sporadic Burkitt's lymphoma. *J Infect Dis* 1996; 173(3):529–35.
13. Sandlund JT, Downing JR, Crist WM. Non-Hodgkin's lymphoma in childhood. *N Engl J Med* 1996; 334(19):1238–48.
14. Tsui SH, Wong MH, Lam WY. Burkitt's lymphoma presenting as mandibular swelling — report of a case and review of publications. *Br J Oral Maxillofac Surg* 2000; 38(1):8–11.
15. Carbone A. Emerging pathways in the development of AIDS-related lymphomas. *Lancet Oncol* 2003; 4(1):22–9.
16. Carbone A. AIDS-related non-Hodgkin's lymphomas: from pathology and molecular pathogenesis to treatment. *Hum Pathol* 2002; 33(4):392–404.