

Self-Inflicted Cosmetic Tongue Split: A Case Report

(Se fourcher la langue à des fins cosmétiques : un rapport de cas)

• Tim Bressmann, PhD •

S o m m a i r e

L'objectif de cette étude de cas était d'obtenir des renseignements de première main au sujet des conséquences fonctionnelles d'une intervention cosmétique visant à fourcher la langue sur la prononciation et la motilité linguale. Un patient qui avait pratiqué l'opération sur lui-même a été interviewé et a subi une évaluation de la motilité linguale, de même qu'un examen échographique. La motilité de sa langue était légèrement réduite en raison de la cicatrisation des tissus. La prononciation a été évaluée comme tout à fait intelligible et hautement acceptable par 4 évaluateurs, même si 2 ont remarqué des distorsions légères des consonnes sifflantes s et z. L'échographie en 3 dimensions a montré que la synergie entre les 2 côtés de la langue était préservée. Un sillon postérieur notablement profond au niveau du muscle génioglosse a indiqué une compensation pour la réduction de la longueur de la langue. On a conclu que l'intervention visant à fourcher la langue n'avait pas compromis de manière significative l'intelligibilité de la parole du participant, ni la motilité de sa langue.

Mots clés MeSH : self mutilation/complications; speech; tongue/injuries

© J Can Dent Assoc 2004; 70(3):156-7
Cet article a été révisé par des pairs.

Cosmetic “body modifications” include piercing of the tongue, lips, face and genitals; deliberate scarring; “branding” with hot irons; the subcutaneous implantation of studs; and the tongue split. The body artists who perform these operations are medically untrained. Both they and their clients regard body modifications as not very invasive or dangerous. However, there is increasing evidence in the literature that tongue and lip piercings may lead to tooth fractures,^{1,2} gingival recession,^{3,4} severe wound inflammation,^{5,6} allergic reactions,⁷ brain abscesses⁸ and endocarditis.^{9,10} The cosmetic tongue split operation is a relatively recent fashion trend. In this procedure, the anterior tongue blade is cut apart along the midline and cauterized to prevent reattachment of the separated sides. So far, functional consequences of this operation have only been addressed in one previous publication: Benecke¹¹ describes the case of a young woman who underwent a tongue split procedure along with a number of other body modifications.

The author comments that speech and swallowing were unaffected by the procedure, but this is only an impressionistic assessment. As body modifications seem to become only more fashionable and popular, it is important to gain knowledge about possible adverse effects of tongue split operations on speech and tongue movement. In particular, dentists, oral

surgeons and speech-language pathologists need to know if there is a new group of clients in the making. The purpose of this case study was to obtain first-hand information about the functional consequences of a cosmetic tongue split operation for speech and tongue motility.

Case Presentation

The participant was a 33-year-old man who works as a self-employed body artist and specializes in facial and genital piercing, scarring, branding and jewellery implantation, but has no formal medical training. The patient reported no previous history of speech, language or hearing disorders. He had performed the tongue split procedure on himself 2 years previous to the interview in his home during a social get-together. The operation had been performed under a light topical anesthetic with a surgical scalpel. He had cut his tongue blade along the lingual midline and cauterized the wound with a red-hot steel bead.

The participant reported that the wound healing and swelling had been uncomplicated. On extreme tongue protrusion and lateralization, he occasionally experienced shooting pains in the left side of the tongue, due to an irritation of the lingual nerve. He had only noted speech problems during the acute healing phase. Following the tongue split, the participant

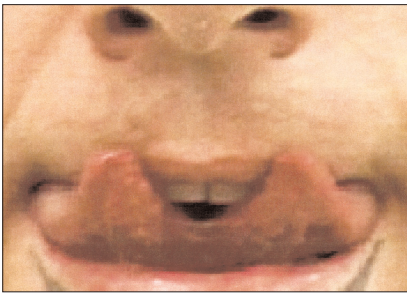


Figure 1: View of the tongue split during lingual elevation towards the prolabium.

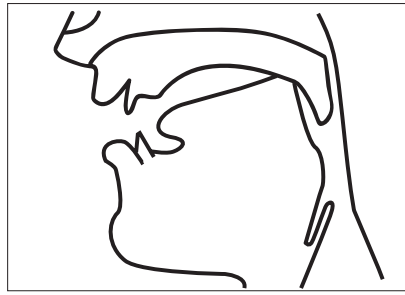

Figure 2a: Midsagittal diagram of the position of the tongue during the production of 'ng'. The dorsum of the tongue is raised posteriorly towards the soft palate. The tip of the tongue is retracted.

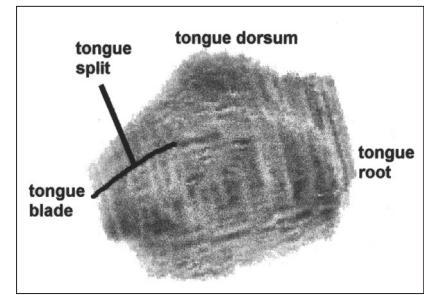


Figure 2b: Three-dimensional ultrasound scan of dorsal elevation of the tongue during sustained 'ng'. The synergy of the 2 sides of the tongue is preserved. The midline split of the tongue blade can be visualized (indicated with a black line).

observed contraction and stiffening of the scars and had tried to counteract this by stretching exercises. Despite these efforts, he estimated that the tongue blade was now about 7 mm shorter in length than before the operation.

In a clinical assessment of tongue motility, the participant demonstrated sufficient lingual movement range. The blade of the tongue appeared shortened, particularly in lingual elevation towards the prolabium (Fig. 1). The participant could not demonstrate independent antagonistic movement of the 2 sides of the tongue. Four speech-language pathologists with over 10 years of professional experience reviewed a digitized 30-second sample of the participant's spontaneous speech, and assessed speech intelligibility and acceptability as a percentage. They also commented on specific articulatory distortions. The mean of the 4 intelligibility ratings was 99.25% (standard deviation [SD] = 1.5). The mean of the 4 ratings of speech acceptability was 96.25% (SD = 4.79).

Two of the raters perceived slight distortions of the sibilants /s/ and /z/. To visualize the split tongue during speech sounds, 3-dimensional ultrasound scans were made while the participant sustained the sounds 'sh', 's', 'r', 'l', 'n', and 'ng' (the velar nasal sound in the word "long").

The ultrasound scans were made with a General Electric Logiq α100 MP ultrasound machine (General Electric Medical Systems, Milwaukee, Wis.), using a 6.5 MHz endocavity ultrasound transducer E72 (General Electric Medical Systems) and the 3D-Echotec Freescan software (3D Echotec GmbH, Halbergmoos, Germany).

The ultrasound examination demonstrated that the synergy of the 2 sides of the tongue was unaltered. The midline scar could be visualized during retraction of the tongue tip (Figs. 2a and 2b). A higher arching of the anterior dorsum of the tongue in alveolar sounds indicated a compensatory increase in medial compression of the 2 disconnected sides of the tongue blade.

Conclusion

The tongue split operation has high risks for inflammation, dehiscence, infection and injury to supplying nerves or arteries. It is certainly not to be recommended, particularly when it

is done in a "do it yourself" fashion, as is suggested on Web sites and in fanzine publications. However, apart from the slight sibilant distortions and the shortening of the tongue blade, the overall functional outcome was surprisingly good in the presented case. ♦

Remerciements : Cette recherche a été appuyée en partie par une subvention de contrepartie des nouveaux employés Connaught de l'Université de Toronto (numéro de subvention 419993).



Le Dr Bressmann est professeur adjoint, Département d'orthophonie de cycle supérieur, Université de Toronto, Toronto (Ontario).

Écrire au : Dr Tim Bressmann, Département d'orthophonie de cycle supérieur, Université de Toronto, 500, avenue University, Toronto ON M5G 1V7.

Courriel : tim.bressmann@utoronto.ca.

L'auteur n'a aucun intérêt financier déclaré.

Références

1. Bassiouny MA, Deem LP, Deem TE. Tongue piercing: a restorative perspective. *Quintessence Int* 2001; 32(6):477-81.
2. Botchway C, Kuc I. Tongue piercing and associated tooth fracture. *J Can Dent Assoc* 1998; 64(11):803-5.
3. Kretchmer MC, Moriarty JD. Metal piercing through the tongue and localized loss of attachment: a case report. *J Periodontol* 2001; 72(6):831-3.
4. Er N, Ozkavaf A, Berberoglu A, Yamalik N. An unusual cause of gingival recession: oral piercing. *J Periodontol* 2000; 71(11):1767-9.
5. Keogh II, O'Leary G. Serious complication of tongue piercing. *J Laryngol Otol* 2001; 115(3):233-4.
6. Dyce O, Bruno JR, Hong D, Silverstein K, Brown MJ, Mirza N. Tongue piercing. The new "rusty nail"? *Head Neck* 2000; 22(7):728-32.
7. Smith RA, Wang J, Sidal T. Complications and implications of body piercing in the head and neck. *Curr Opin Otolaryngol Head Neck Surg* 2002; 10:199-205.
8. Martinello RA, Cooney EL. Cerebellar brain abscess associated with tongue piercing. *Clin Infect Dis* 2003; 36(2):e32-4.
9. Tronel H, Chaudemanche H, Pechier N, Doutrelant L, Hoen B. Endocarditis due to *Neisseria mucosa* after tongue piercing. *Clin Microbiol Infect* 2001; 7(5):275-6.
10. Akhondi H, Rahimi AR. Haemophilus aphrophilus endocarditis after tongue piercing. *Emerg Infect Dis* 2002; 8(8):850-1.
11. Benecke M. First report of nonpsychotic self-cannibalism (autophagy), tongue splitting, and scar patterns (scarification) as an extreme form of cultural body modification in a Western civilization. *Am J Forensic Med Pathol* 1999; 20(3):281-5.