

Unusual Post-Extraction Hemorrhage in a Cardiac Patient: A Case Report

(Hémorragie inhabituelle après l'extraction d'une dent chez un patient souffrant de cardiopathie : une étude de cas)

- Ajit Auluck, BDS •
- Keerthilatha M. Pai, MDS •
- Kadengodlu Seetharam Bhat, MDS •
- Paul S. Thoppil, MD, DM •

S o m m a i r e

Les dentistes connaissent la nécessité de l'antibiothérapie prophylactique contre l'endocardite infectieuse chez le patient atteint d'une cardiopathie congénitale cyanogène (CCC), mais tous les dentistes ne sont pas au fait de la tendance au saignement qu'elle entraîne chez ces patients. Nous étudions un cas d'hémorragie après extraction chez un patient atteint du syndrome d'Eisenmenger et nous soulignons l'importance d'une évaluation hématologique plus poussée avant la chirurgie buccale chez les patients atteints de CCC.

Mots clés MeSH : Eisenmenger complex/complications; oral hemorrhage/adverse effects; tooth extraction/adverse effects

© J Can Dent Assoc 2004; 70(11):769-73
Cet article a été révisé par des pairs.

An untreated ventricular septal defect may result in Eisenmenger's syndrome, which is defined as "elevation of pulmonary arterial pressure to the systemic level caused by increased pulmonary vascular resistance with reversal or bi-directional shunting through a large intracardiac or extracardiac congenital heart defect."¹ In Eisenmenger's syndrome, deoxygenated venous blood returning to the heart is pumped out into the systemic circulation without passing through the lungs for oxygenation, which results in central cyanosis.² Chronic hypoxia, caused by cyanosis, results in increased erythropoietin secretion by the kidneys and, subsequently, polycythemia.³ The type and magnitude of hematologic abnormalities in patients with cyanotic congenital heart disease (CCHD) are directly proportional to the degree of polycythemia.³

Cardiac patients usually undergo dental treatment only after a physician's consent, and treatment follows established protocols for infective endocarditis antibiotic prophylaxis and withdrawal of anticoagulants, which are set, reviewed and updated periodically by scientific authorities. However, these measures alone cannot ensure safe extraction in a patient with

CCHD. Review of the literature reveals that excessive bleeding can occur in such patients for reasons other than the use of acetylsalicylic acid and anticoagulant therapy. Hematologic abnormalities can be thrombocytopenia, accelerated fibrinolysis or decreased production of coagulation factors leading to increased prothrombin time and thromboplastin time.⁴ This case report highlights a hemorrhagic tendency encountered in a patient with a ventricular septal defect with Eisenmenger's syndrome. With an increasing number of patients with Eisenmenger's syndrome surviving to adulthood,^{5,6} it is more likely that dentists will encounter such patients in their practice, underlining the importance of their awareness of this condition.

Case Report

A 30-year-old man presented with bleeding from the lower left molar region over 2 days. The patient was known to have congenital heart disease. Two days earlier, a local dentist had extracted his lower left first molar after routine antibiotic prophylaxis for infective endocarditis. However, the dentist did not order any hematologic investigations. Bleeding

Table 1 Summary of hematologic investigations

Investigation	Normal range ^a	Patient's value	Evaluation
Hemoglobin	8.1–11.2 mmol/L	15.45 mmol/L	Increased
PCV	0.40–0.54 L/L	0.80 L/L	Increased
TLC	4.0–11.0 × 10 ⁹ /L	3.6 × 10 ⁹ /L	Normal
RBCs	4.5–6.5 × 10 ¹² /L	9.9 × 10 ¹² /L	Increased
Platelet count	150–400 × 10 ⁹ /L	96 × 10 ⁹ /L	Decreased
Bleeding time	1–6 min (Ivy method)	5 min	Normal
PT	< 3.0 (INR)	3.13 (INR)	Increased
aPTT	25–35 s	43.0 s (control 32 s)	Increased
Biochemical investigations			
AST	5–40 U/L	61 U/L	Increased
ALT	5–40 U/L	27 U/L	Normal
ALP	40–140 U/L	689 U/L	Increased

^aFor males.

ALP = alkaline phosphatase; ALT = alanine transaminase; aPTT = activated partial thromboplastin time; AST = aspartate transaminase; PCV = packed cell volume; PT = prothrombin time; RBCs = red blood cells; TLC = total leucocyte count.

occurred that evening and the patient noticed blood-tinted saliva and droplets of blood oozing from the extraction socket. The next day, the patient returned to the dentist, who debrided and sutured the socket area. The patient appeared normal after this treatment, but had a recurrent episode of bleeding after a few hours. He then reported to our department for evaluation.

The patient was of moderate build, fairly well nourished and with vital signs within normal limits. There was clubbing of fingers. Liver, spleen and lymph nodes were not palpable and no signs of pedal edema or ascites were observed.

An intraoral periapical radiograph of the region ruled out the presence of root fragments. The extraction area was again debrided under local anesthesia without adrenaline, irregular bony margins were smoothed and the area was closed with interrupted sutures. Pressure packs and local hemostatic hemocoagulase were used to control bleeding and the patient was discharged. The patient reported again the next day with bleeding from the same area. Examination revealed petechiae over the skin of his arms and thorax. Ethamsylate was administered and the bleeding was controlled temporarily. The patient was referred for cardiac consultation and hematologic tests were ordered. The next day, the patient had another episode of bleeding and was admitted to hospital.

Cardiologist's Report

The patient had grade III carpopedal clubbing and central cyanosis. He had a grade III left parasternal heave with a right ventricular fourth heart sound and an accentuated pulmonary component in the second heart sound along with pansystolic murmur with tricuspid regurgitation. An electrocardiogram suggested right ventricular hypertrophy, right axis deviation and secondary ST-T changes. It revealed a large (2.2 cm) ventricular septal defect; right-to-left shunting; a right ventricular thickness of 1.3 cm; and grade II tricuspid regurgitation. Cardiac catheterization revealed a pulmonary-to-systemic

flow ratio of 0.8 and a pulmonary vascular resistance of 520 dynes × s × cm⁻⁵.

Hematologic Investigation

Tests revealed a high hemoglobin concentration (15.45 mmol/L), a high red blood cell count (9.9 × 10¹²/L), a packed cell volume of 0.80 L/L, a prothrombin time of 3.13 (INR), an activated partial thromboplastin time of 43 s (with a control of 32 s) and a reduced level of platelets (96 × 10⁹/L) (Table 1). Biochemical investigations revealed an increased level of aspartate transaminase (61 U/L) and alkaline phosphatase (689 U/L). White blood cell counts were normal.

Subsequently, 2 units of fresh frozen plasma were infused, after which the bleeding stopped completely.

Discussion

Hemostatic abnormalities in patients with CCHD are well documented. Bleeding tendency is usually mild to moderate and is characterized by easy bruising, petechial hemorrhage and gingival bleeding.⁷ In patients with congenital cardiac defects, infective endocarditis prophylaxis and determination of bleeding tendency are the most important factors that dental practitioners must consider.⁸

In Eisenmenger's syndrome, pulmonary hypertension causes the heart to circulate deoxygenated blood resulting in chronic hypoxia. Hypoxia triggers the secretion of erythropoietin from the kidneys, which causes erythrocytosis and subsequent polycythemia and an increase in the hematocrit³ (Fig. 1). Because bleeding in patients with CCHD has a systemic cause, the use of a topical hemostatic agent results in only temporary cessation of bleeding, as observed in our case; hence the role of local hemostatics is limited.

In CCHD, abnormal hemostasis has a multifactorial etiology. It may be caused by a decrease in the coagulation factors synthesized in the liver, i.e., vitamin-K-dependent factors II, V, VII, IX and X, which can be explained by deficient synthesis

resulting from hypoxic damage to the liver and sluggishness of microcirculation caused by high blood viscosity⁹ (Fig. 1). This explains the elevated levels of liver enzymes and the increase in prothrombin time and activated partial thromboplastin time observed in our patient. It also emphasizes the need for specific

assays (Box 1), which had not been performed in our patient. Our patient's abnormal hemostasis was a result of deficient clotting factors, which was corrected by transfusion of fresh frozen plasma.

In patients with CCHD, platelets have both qualitative and quantitative abnormalities. Platelet count and hematocrit are inversely related; thus an increased hematocrit is associated with thrombocytopenia.^{3,9} Low platelet counts are attributed to either shortened half life of the platelets³ or decreased production of platelets as megakaryocytes escape fragmentation in lungs owing to a right-to-left shunt.¹⁰ An elevated PCV and reduction in platelet count was found in our patient (Table 1).

In patients with CCHD, polycythemia occurs with overproduction of platelet micro-particles, probably due to high shear stress caused by increased blood viscosity, which might play an important role in the coagulation abnormalities identified in such patients.¹¹ In their study of 33 patients, Bhargava and others¹² concluded that there was reduction in platelet adhesiveness to glass and impaired availability of platelet factor 3 in nearly 50% of patients and poor clot retraction in 84% of patients. There is also a deficit in the platelet adhesion receptor glycoprotein Ib, which can also contribute to hemostatic complications.¹³ Qualitative platelet defects associated with CCHD include abnormal aggregation of platelets in response to adenosine diphosphates, epinephrine and collagen, which is directly related to the degree of polycythemia.³ Tests to confirm these findings were not performed in our patient, as temporary cessation of bleeding indicated that the hemostatic defect was not due primarily to platelet abnormalities but to a coagulation defect. However, tests to rule out qualitative platelet defects are recommended in CCHD patients (Box 1).

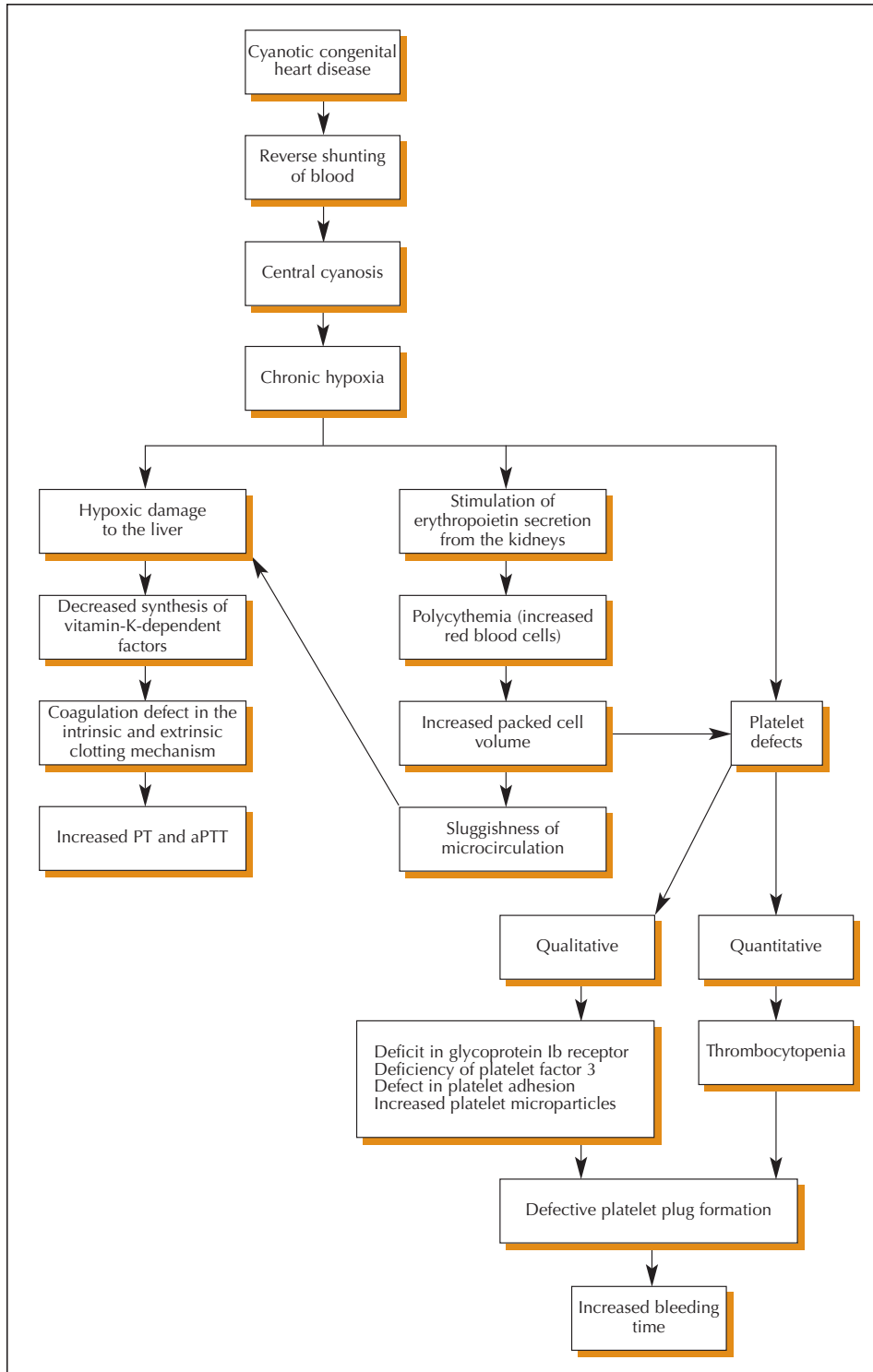


Figure 1: Clinicopathologic processes responsible for abnormal hemostasis in patients with cyanotic congenital heart disease. (Disseminated intravascular coagulation and abnormality in von Willebrand factor also contribute to hemostatic abnormalities.) aPTT = activated partial thromboplastin time; PT = prothrombin time

Box 1 Recommended investigations for patients with cyanotic congenital heart disease

Screening tests

Hematologic investigations

- Complete blood count (CBC)
- Platelet count
- Peripheral smear
- Bleeding time
- Prothrombin time (PT)
- Activated partial thromboplastin time (aPTT)
- Clot retraction

Biochemical investigations

- Aspartate transaminase (AST)
- Alanine transaminase (ALT)
- Alkaline phosphatase (ALP)

Specific tests^a

- Specific factor assay
- D-dimer level
- Antithrombin III level
- Ristocetin aggregation test
- von Willebrand assay

^aA dentist routinely prescribes screening tests. A negative screening test does not preclude the need for specific tests before major surgical procedures or in cases of continuous postoperative bleeding.

A variant of von Willebrand disease, characterized by a deficiency of the high molecular weight forms of the von Willebrand factor in plasma, has also been reported.^{3,11,12} Cyanosis, turbulent blood flow and pulmonary vascular disease appear to be independently associated with a reduction in or the absence of large von Willebrand factor multimeric forms.^{14,15} It remains to be determined whether the von Willebrand abnormality has a central role in the clinical hemostatic disturbance experienced by patients with CCHD.⁷ Although rare, specific tests to rule out von Willebrand disease are recommended in CCHD patients after consultation with a physician.

Abnormal hemostasis resulting from a state of consumptive coagulopathy or disseminated intravascular coagulation has also been observed in some patients with elevated D-dimer levels. D-dimers are specific degradation products of cross-linked fibrin¹⁶ and indicate prior thrombin generation and subsequent lysis. Chan and others¹⁷ observed an increase in thrombin generation and consumptive coagulopathy as indicated by high levels of thrombin-antithrombin complexes in cyanotic and acyanotic heart disease patients. Therefore, assessment of D-dimer and antithrombin levels can be performed to rule out disseminated intravascular coagulation and increased fibrinolytic activity.

In most patients, preoperative abnormalities in screening tests predict a subclinical hemorrhagic tendency,⁹ but normal test results do not exclude the possibility of a major postoperative bleeding diathesis.¹⁸ This emphasizes the need for specific tests (**Box 1**), which should be performed with a physician's consent in patients with continuous postoperative bleeding tendency after minor orosurgical procedures despite normal screening tests or before any major orosurgical procedure.

In the management of such patients, nonsteroidal anti-inflammatory drugs, such as acetylsalicylic acid, should be avoided, as they block the cyclooxygenase pathway and inhibit platelet aggregation, thus enhancing intrinsic hemostatic defects caused by existing platelet abnormalities in patients with CCHD.⁸ Corticosteroids and anticoagulants also increase the risk of bleeding, and these drugs should be avoided.

Before a major orosurgical procedure, if the hematocrit is high, prophylactic phlebotomy is recommended, with a physician's consent, to reduce the hematocrit level to below 65%. This improves hemostasis and decreases the risk of post-surgical hemorrhage.¹⁹ Units of phlebotomized blood should be stored for potential autologous transfusion in the future. In addition to bringing the hematocrit under control, prophylactic platelet transfusion can be performed; if it does not stop bleeding, fresh frozen plasma can be infused. Aprotinin, epsilon aminocaproic acid, tranexamic acid and desmopressin can also be used to control bleeding in CCHD patients.

In patients with Eisenmenger's syndrome, dental extractions and other minor orosurgical procedures should be performed under conscious sedation.²⁰

Conclusion

This article emphasizes the need for and the importance of preoperative hematologic screening in patients with CCHD to prevent postoperative bleeding by predicting subclinical hemorrhagic tendencies. A detailed case history, symptoms of CCHD and abnormalities in such screening tests as complete blood count, hematocrit, prothrombin time and activated partial thromboplastin time should alert the dentist to such tendencies. In view of the nature of the problem, a team approach involving the dentist and the physician in the management of such patients is necessary to provide them with better and safer care. ❖



Le Dr Auluck est étudiant de cycle supérieur, médecine et radiologie buccales, Collège des sciences dentaires de Manipal, Manipal, Inde.



La Dre Pai est professeure et directrice, médecine et radiologie buccales, Collège des sciences dentaires de Manipal, Manipal, Inde.



Le Dr Bhat est professeur émérite, Collège des sciences dentaires de Manipal, Manipal, Inde.



Le Dr Thoppil est professeur adjoint, Collège médical Kasturba, Manipal, Inde.

Écrire au : Dr Ajit Auluck, Département de médecine et de radiologie buccales, Collège des sciences dentaires de Manipal, Manipal – 576104, Karnataka, Inde. Courriel : drajitauluck@yahoo.co.in.

Les auteurs n'ont aucun intérêt financier déclaré.

Références

1. Berman EB, Barst RJ. Eisenmenger's syndrome: current management. *Progr Cardiovasc Dis* 2002; 45(2):129–38.
2. Engel TR. Cardiovascular diseases. In: Rose LF, Kaye D, editors. Internal medicine for dentistry. 2nd ed. Toronto: Mosby; 1990. p. 443.
3. Tempe DK, Virmani S. Coagulation abnormality in patients with cyanotic congenital heart disease. *J Cardiothoracic Vasc Anesth* 2002; 16(6):752–65.
4. Perloff JK. Noncardiac surgery in adults with congenital heart disease. In: Perloff JK, Child JS, editors. Congenital heart disease in adults. Philadelphia: WB Saunders; 1991. p. 239.
5. Oya H, Nagaya N, Uematsu M, Satoh T, Sakamaki F, Kyotani S, and others. Poor prognosis and related factors in adults with Eisenmenger's syndrome. *Am Heart J* 2002; 143(4):739–44.
6. Cantor WJ, Harison DA, Moussadi JS, Connelly WS, Webb GD, Liu P, and others. Determinants of survival and length of survival in adults with Eisenmenger's syndrome. *Am J Cardiol* 1999; 84(6):677–81.
7. Perloff JK. Systemic complications of cyanosis in adults with congenital heart disease. Haematologic derangements, renal functions, and urate metabolism. *Cardiol Clin* 1993; 11(4):689–99.
8. Greenwood M, Meechan JG. General medicine and surgery for dental practitioners. Part 1: cardiovascular system. *Br Dent J* 2003; 194(10):537–42.
9. Goel M, Shome DK, Singh ZN, Bhattacharjee J, Khalil A. Haemostatic changes in children with cyanotic and acyanotic congenital heart disease. *Indian Heart J* 2000; 52 (5):559–63.
10. Vasquez-Abad D, Martinez-Lavin M. Macrothrombocytes in the peripheral circulation of patients with cardiogenic hypertrophic osteoarthropathy. *Clin Exp Rheumatol* 1991; 9(1):59–62.
11. Horigome H, Hiramatsu Y, Shigeta O, Nagasawa T, Matsui A. Overproduction of platelet microparticles in cyanotic congenital heart disease with polycythemia. *J Am Coll Cardiol* 2002; 39(6):1072–7.
12. Bhargava M, Sanyal SK, Thapar MK, Kumar S, Hooja V. Impairment of platelet adhesiveness and platelet factor 3 activity in cyanotic congenital heart disease. *Acta Haematol* 1976; 55(4):216–23.
13. Rinder CS, Gaal D, Student LA, Smith BR. Platelet-leukocyte activation and modulation of adhesion receptors in pediatric patients with congenital heart disease undergoing cardiopulmonary bypass. *J Thorac Cardiovasc Surg* 1994; 107(1):280–8.
14. Gill JC, Wilson AD, Endres-Brooks J, Montgomery RR. Loss of the largest von Willebrand factor from the plasma of patients with congenital cardiac defects. *Blood* 1986; 67(3):758–61.
15. Rabinovitch M, Andrew M, Thom H, Trusler GA, Williams WG, Rowe RD, and other. Abnormal endothelial factor VIII associated with pulmonary hypertension and congenital heart defects. *Circulation* 1987; 76(5):1043–52.
16. Lip GY, Lowe GD. Fibrin D-dimer: a useful clinical marker of thrombogenesis? *Clin Sci (Lond)* 1995; 89(3):205–14.
17. Chan AK, Leaker M, Burrows FA, William WG, Gruenwald CE, Whyte L, and others. Coagulation and fibrinolytic profile of paediatric patients undergoing cardiopulmonary bypass. *Thromb and Haemost* 1997; 77(2):270–7.
18. Colon-Otero G, Gilchrist GS, Holcomb GR, Ilstrup DM, Bowie EJ. Preoperative evaluation of hemostasis in patients with congenital heart disease. *Mayo Clin Proc* 1987; 62(5):379–85.
19. Milam JD, Austin SF, Nihill MR, Keats AS, Cooley DA. Use of sufficient hemodilution to prevent coagulopathies following surgical correction of cyanotic heart disease. *J Thorac Cardiovasc Surg* 1985; 89(4): 623–9.
20. Bozich JG, Albert TW. Multiple dental extractions using general anesthesia for a patient with Down and Eisenmenger syndromes and periodontal disease. *Spec Care Dentist* 1990; 10(2):51–4.