

The Klippel-Feil Syndrome: A Case Report

(Le syndrome de Klippel-Feil : une étude de cas)

- Manuel O. Lagravère, DDS, MSc •
- María I. Barriga, DDS •
- Carla Valdizán, DDS •
- Augusto Saldarriaga, DDS •
- Juan F. Pardo, DDS •
- Martha Flores, DDS •

S o m m a i r e

On peut observer l'absence de cou et la fusion des vertèbres cervicales dans plusieurs malformations congénitales et syndromes bien définis. On soupçonnait qu'un garçon de 8 ans présentant une absence de cou, une implantation basse des cheveux, la surdité et une limitation des mouvements cervicaux pouvait être atteint d'une telle malformation. Les examens cliniques et radiologiques ont conduit au diagnostic du syndrome de Klippel-Feil.

Mots clés MeSH : cervical vertebrae/abnormalities; Klippel-Feil Syndrome; malocclusion

© J Can Dent Assoc 2004; 70(10):685-8
Cet article a été révisé par des pairs.

Klippel-Feil syndrome (KFS) was first described by Maurice Klippel and Andre Feil¹ in 1912 in a patient with congenital fusion of cervical vertebrae. KFS is a complex syndrome of osseous and visceral anomalies that include the classical clinical triad of short neck, limitation of head and neck movements and low posterior hairline.² It is associated with several defects, such as deafness, either conductive or neural; congenital heart defects, the most common being a ventricular septal defect; mental deficiency; cleft palate; rib defects; the Sprengel sequence (elevated scapula); and scoliosis.^{1,3} Patients with KFS exhibit a smaller lower third of the face and facial asymmetry with no dental implications.³ KFS occurs in 1 of every 42,000 births, and 60% of cases are in females.⁴

KFS is listed in the Online Mendelian Inheritance in Man database⁵ as being of sporadic autosomal dominant inheritance with reduced penetrance and variable expression. The differential diagnosis of this condition includes spondylocostal dysostoses, Poland syndrome, spondyloepiphyseal dysplasia and congenital and short-rib polydactyl syndromes.³ Almost all cases of this syndrome occur sporadically; nevertheless, close evaluation of the immediate family is recommended.⁴ Although the prevalence of KFS is very low, it has been related

to various anomalies and to fetal alcohol syndrome.^{6,7} It has even been speculated that KFS may originate from fetal alcohol syndrome.⁷

The bony malformations present in patients with KFS may entrap and damage the brain and spinal cord.¹ Disorders of the lower vertebral region may become symptomatic during the rapid growth of adolescence or in adult life.⁸

In this report, we present clinical and radiographic findings in an 8-year-old boy with KFS.

Case Report

A Peruvian boy, 8 years old, was brought to the Clínica Estomatológica Central at the Universidad Peruana Cayetano Heredia, Lima-Peru, by his mother for a dental checkup. During evaluation, the mother indicated that at birth he had had a heart murmur and at the age of 3 months, he was operated on for inguinal hernia. Later, at 5 years of age, he was treated for nasal septum deviation. She also indicated that her son had 2 fused cervical vertebrae discovered by his pediatrician; this was later confirmed by a cervical radiograph.

The boy was alert, cooperative and cheerful. Physical examination revealed a short neck, low-set posterior hairline, partly limited neck motion, deafness in the right ear, small

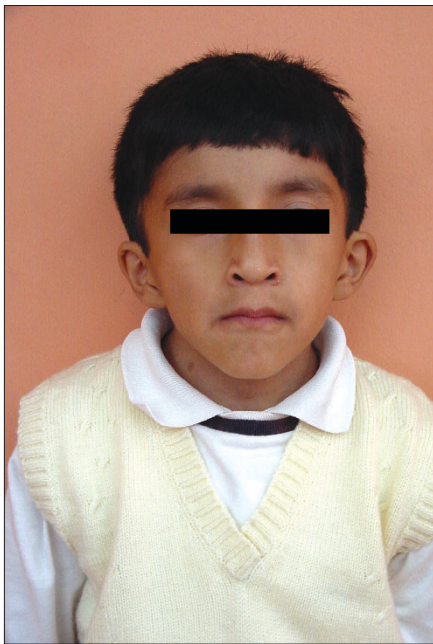

Figure 1a: Clinical photograph showing short neck, facial asymmetry and low-set posterior hairline.

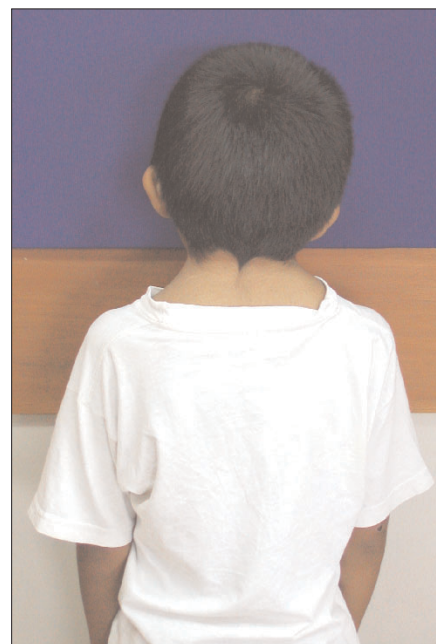

Figure 1b: Clinical photograph showing back view of low neck.

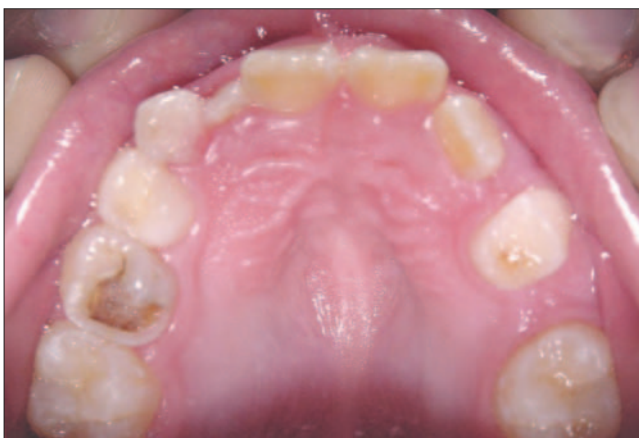

Figure 2a: Upper arch intraoral features at first examination.

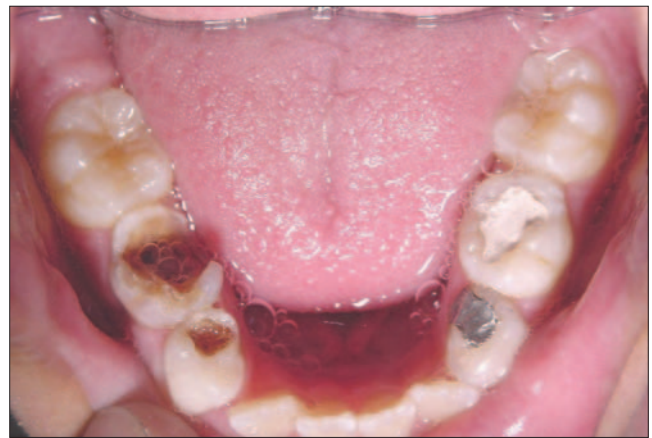

Figure 2b: Lower arch intraoral features at first examination.

lower facial third and facial asymmetry (Figs. 1a and 1b). It also revealed the presence of digital sucking habits.

Intraoral examination showed multiple dental carious lesions and severe anterior crowding (Figs. 2a and 2b), vertical open bite, deep palate, mouth breathing and poor oral hygiene.

A panoramic radiograph showed normal tooth development with premature absence of the primary upper left second molar and canine; and both lower canines (Fig. 3). Bitewing radiographs showed carious lesions with probable pulpal compromise on teeth 55, 75 and 84.

The patient was referred to the departments of pediatrics, genetics, otorhinolaryngology and orthodontics for examination. After examining the boy and family members, the geneticist diagnosed the boy with sporadic KFS with a normal chromosomal karyotype. Otorhinolaryngology examination

confirmed partial deafness of the right hearing complex and deviation of the nasal septum.

After orthodontic consultation, the boy was classified with Class I malocclusion with severe crowding. A transpalatal arch or a removable maintainer used jointly with a fixed lingual arch was recommended to prevent more space loss. Occlusal guidance with extraction of the primary molars and fixed orthodontic treatment was also suggested for future correction of the patient's open bite and severe crowding. Careful evaluation of the patient's vertical growth rate will be monitored and precautions taken if necessary.

The treatment plan focused on both prevention and therapy. Special attention was paid to keeping every appointment short due to the patient's condition. In terms of prevention, the boy received a prophylactic treatment and oral hygiene instruction emphasizing the importance of brushing

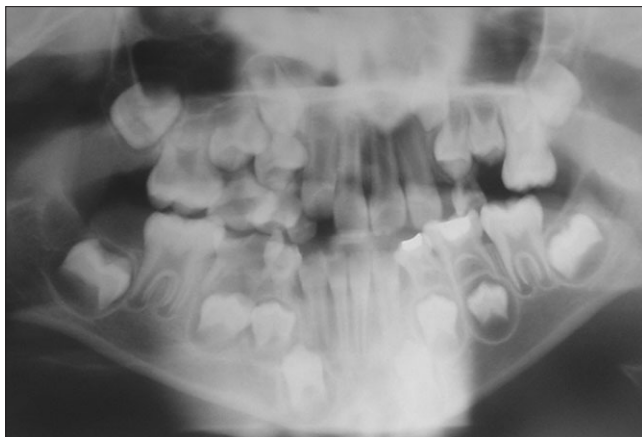


Figure 3: Panoramic radiograph at the first examination.

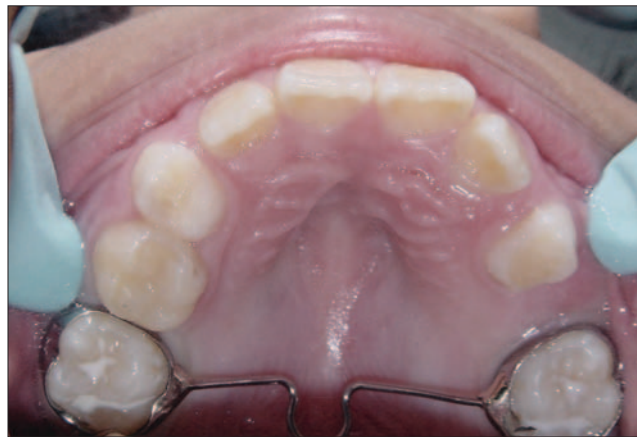

Figure 4a: Upper arch intraoral features at end of treatment.

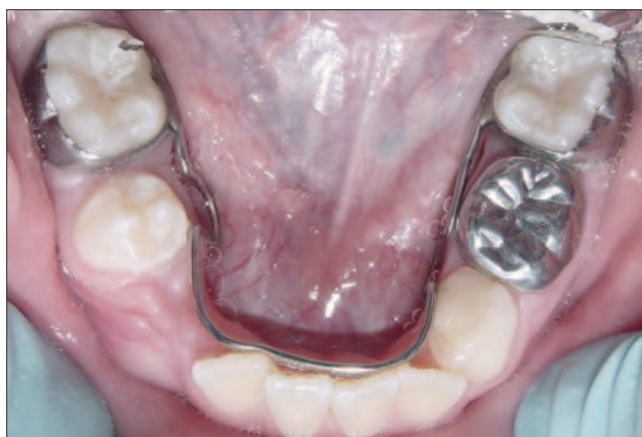

Figure 4b: Lower arch intraoral features at end of treatment.

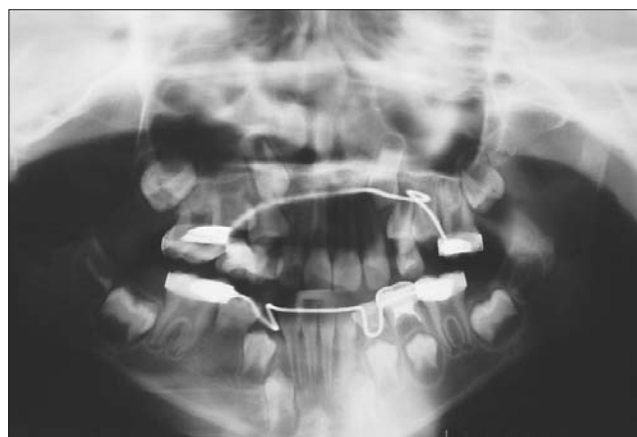

Figure 5: Panoramic radiograph at end of treatment.

correctly, using dentifrice and rinsing the mouth with fluoride. Sealants were applied to the permanent first molars and topical fluoride treatments were provided every 2 months.

Pulpotomies were performed, with formocresol for 5 minutes, on teeth 55, 75 and 84. The lower right primary second molar was extracted. The carious lesions of teeth 64 and 74 were restored with glass ionomer cement (Vitremer, 3M ESPE, St. Paul, Minn.).

The patient was transferred to the orthodontic service of the Clínica Estomatológica Central for evaluation and future treatment. After consultation, fixed lingual and transpalatal arches were placed (Figs. 4a, 4b and 5).

Discussion

Cervical vertebral segmentation anomalies are referred to as the Klippel-Feil anomaly whether they involve fusion of 2 segments or the entire cervical spine. KFS appears to be a failure of the normal segmentation and fusion processes of the mesodermal somites, which occur between the third and seventh week of embryonic development. Webbing of the neck, elevation of the scapula and congenital heart defects are frequently associated with this spinal anomaly.^{1,3,9}

Gunderson and others¹⁰ distinguished 3 types of cervical vertebral fusion defect related to Klippel-Feil anomalies: type I – massive fusion of many cervical and upper thoracic vertebrae into bony blocks; type II – fusion of only 1 or 2 interspaces, usually C2-C3 or C5-C6, but there can be intrafamilial variability; type III – both cervical fusion and lower thoracic or lumbar fusion, often associated with multiple organ anomalies and subsequent neurologic compromise. A fourth type of Klippel-Feil anomaly has been suggested to be associated with sacral agenesis.³

Our patient presented with a short neck, limited neck movements and a low-set posterior hairline. His symptoms included heart murmur and fusion of the C2-C3 vertebrae without elevation of the scapula. With these features, our patient fits the type II category of KFS well (Fig. 6).

Several authors report the association of partial or complete conductive hearing impairment, underdeveloped low-set ears and facial asymmetry in patients with type II KFS.^{11,12} These findings are in accordance with the presence of deafness in the right ear, low-set ears and facial asymmetry found in our patient. Because of the high incidence of hearing loss in patients with KFS, audiologic examinations are recommended. Speech

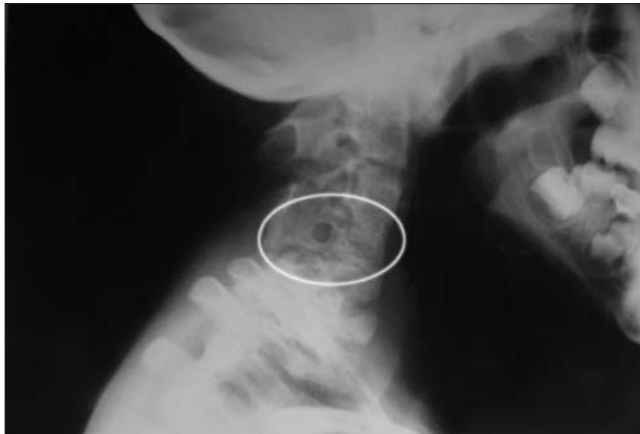

Figure 6: Radiograph showing fusion of cervical vertebrae.

problems can be reduced or avoided when hearing deficiency is recognized at an early age.^{13,14}

Clinicians should be aware of the characteristics of KFS when making an oral diagnosis and planning treatment. Dental professionals should check for the presence of a submucous cleft^{13,15-17} and congenitally missing teeth¹⁸ as the incidence of these characteristics is high in KFS patients. Orthodontic evaluation should consist of radiographs (cephalometric and panoramic) and model casts for assessment of tooth-size discrepancies.¹⁸

Considering these factors, our patient was evaluated and treated carefully. Poor oral hygiene and the presence of multiple carious lesions put this patient in a high-risk category. For that reason, glass ionomer cement was used because it releases fluoride into the oral cavity.¹⁹⁻²³ Formocresol was used in the pulpotomy treatment as its efficiency as a medicament for primary molar pulpotomy procedures has been well demonstrated.²⁴⁻²⁶

Rarely, breathing disorders in sleep, such as fatal obstruction sleep apnea, stridor or bradypnea, are seen and all children diagnosed with KFS should be regularly followed for these problems.²⁷ Mouth breathing and facial asymmetries are frequently observed in patients with KFS. Special precautions should be taken when considering sedation or anesthesia in the pediatric dental office as these patients should not be intubated.¹³ ♦

Remerciements : Les auteurs sont reconnaissants envers la Dre María Quiroga de Michelena, généticienne de l'Instituto de Genética de l'Universidad Peruana Cayetano Heredia, pour son aide précieuse dans la diagnostic génétique.



Le Dr Lagravère est un ancien professeur adjoint, Département des enfants et des adolescents, Universidad Peruana Cayetano Heredia, Pérou; et étudiant de doctorat, programme supérieur d'orthodontie, Université de l'Alberta, Edmonton (Alberta).



La Dre Barriga est une ancienne aide-enseignante, Département des enfants et des adolescents, Universidad Peruana Cayetano Heredia, Pérou.

La Dre Valdizán exerce dans un cabinet privé à Lima (Pérou).

Le Dr Saldarriaga exerce dans un cabinet privé à Lima (Pérou).

Le Dr Pardo exerce dans un cabinet privé à Lima (Pérou).

La Dre Flores est professeure adjointe, Département des enfants et des adolescents, Universidad Peruana Cayetano Heredia, Pérou.

Écrire au : Dr Manuel O. Lagravère, Faculté de médecine et de médecine dentaire, salle 4051A, Centre de médecine dentaire/pharmacie, Université de l'Alberta, Edmonton AB T6G 2N8. Courriel : mlagravere@ualberta.ca.

Les auteurs n'ont aucun intérêt financier déclaré dans la ou les sociétés qui fabriquent les produits mentionnés dans cet article.

Références

1. Jones KL. Smith's recognizable patterns of human malformation. 5th ed. Philadelphia: WB Saunders Company; 1997.
2. Nagib MG, Maxwell RE, Chou SN. Identification and management of high-risk patients with Klippel-Feil syndrome. *J Neurosurg* 1984; 61(3):523-30.
3. Rimoin DL, Connor JM, Pyeritz RE. Emery and Rimoin's principles and practice of medical genetics. 3rd ed. New York: Churchill Livingstone; 1996.
4. Boraz RA, Irwin DH, Van Blarcom C. The dental rehabilitation of a patient with Klippel-Feil syndrome and Sprengel's deformity. *Spec Care Dentist* 1986; 6(1):22-4.
5. McKusick VA. Klippel-Feil Syndrome: Online Mendelian Inheritance in Man, John Hopkins University; 2004. Available from: URL: <http://www.ncbi.nlm.nih.gov/entrez/query.fcgi?db=OMIM> (accessed 28 Sept. 2004).
6. Lowry RB. The Klippel-Feil anomalad as part of the fetal alcohol syndrome. *Teratology* 1977; 16(1):53-6.
7. Schilgen M, Loeser H. Klippel-Feil anomaly combined with fetal alcohol syndrome. *Eur Spine J* 1994; 3(5):289-90.
8. Singh S, Shakthi K, Venugopala D, Korath M, Govindan A, Jagadeesan K. Klippel Feil syndrome. *Bombay Hosp J* 1999; 41(3):582-5.
9. Caffey J. Caffey's pediatric X-ray diagnosis: an integrated imaging approach. 8th ed. Chicago: Year Book Medical Publishers; 1985.
10. Gunderson CH, Greenspan RH, Glaser GH, Lubs HA. The Klippel-Feil syndrome: genetic and clinical reevaluation of cervical fusion. *Medicine (Baltimore)* 1967; 46(6):491-512.
11. Clarke RA, Singh S, McKenzie H, Kearsley JH, Yip MY. Familial Klippel-Feil syndrome and paracentric inversion inv(8)(q22.2q23.3). *Am J Hum Genet* 1995; 57(6):1364-70.
12. McGaughan JM, Kuna P, Das V. Audiological abnormalities in the Klippel-Feil syndrome. *Arch Dis Child* 1998; 79(4):352-5.
13. Nagib MG, Maxwell RE, Chou SN. Klippel-Feil syndrome in children: clinical features and management. *Childs Nerv Syst* 1985; 1(5):255-63.
14. Hensinger RN, Lang JE, MacEwen GD. Klippel-Feil syndrome; a constellation of associated anomalies. *J Bone Joint Surg Am* 1974; 56(6):1246-53.
15. Helmi C, Pruzansky S. Craniofacial and extracranial malformations in the Klippel-Feil syndrome. *Cleft Palate J* 1980; 17(1):65-88.
16. Selle G, Jacobs HG. Cleft palate in two syndromes. *Cleft Palate J* 1977; 14(3):230-3.
17. Miyamoto RT, Yune HY, Rosevear WH. Klippel-Feil syndrome and associated ear deformities. *Am J Otol* 1983; 5(2):113-9.
18. Ozdililer E, Akcam MO, Sayin MO. Craniofacial characteristics of Klippel-Feil syndrome in an eight year old female. *J Clin Pediatr Dent* 2000; 24(3):249-54.
19. Dhondt CL, De Macey EA, Verbeeck RM. Fluoride release from glass ionomer activated with fluoride solutions. *J Dent Res* 2001; 80(5):1402-6.
20. Carvalho AS, Cury JA. Fluoride release from some dental materials in different solutions. *Oper Dent* 1999; 24(1):14-9.

21. Forsten L. Short- and long-term fluoride release from glass ionomer based liners. *Scand J Dent Res* 1991; 99(4):340-2.
22. Forsten L. Fluoride release and uptake by glass-ionomers and related materials and its clinical effect. *Biomaterials* 1998; 19(6):503-8.
23. Damen JJ, Buijs MJ, ten Cate JM. Uptake and release of fluoride by saliva-coated glass ionomer cement. *Caries Res* 1996; 30(6):454-7.
24. Waterhouse PJ. Formocresol and alternative primary molar pulpotomy medicaments: a review. *Endod Dent Traumatol* 1995; 11(4):157-62.
25. Morawa AP, Straffon LH, Han SS, Corpron RE. Clinical evaluation of pulpotomies using dilute formocresol. *ASDC J Dent Child* 1975; 42(5):360-3.
26. Nunn JH, Smeaton I, Gilroy J. The development of formocresol as a medicament for primary molar pulpotomy procedures. *ASDC J Dent Child* 1996; 63(1):51-3.
27. Rosen CL, Novotny EJ, D'Andrea LA, Petty EM. Klippel-Feil sequence and sleep-disordered breathing in two children. *Am Rev Respir Dis* 1993; 147(1):202-4.