

Outcomes of Vital Primary Incisor Ferric Sulfate Pulpotomy and Root Canal Therapy

(Comparaison entre des incisives primaires à pulpe vivante traitées par pulpotomie au sulfate ferrique ou par traitement de canal)

- Michael J. Casas, DDS, MSc, FRCD(C) •
- David J. Kenny, BSc, DDS, PhD, FRCD(C) •
- Douglas H. Johnston, BSc, DDS, MSc, FRCD(C) •
- Peter L. Judd, BSc, DDS, MSc, FRCD(C) •
- Michael A. Layug, BSc, DDS, MSc, FRCD(C) •

S o m m a i r e

Objectif : Comparer 2 techniques (pulpotomie au sulfate ferrique [SF] et traitement de canal [TC]), pour le traitement d'une exposition pulpaire d'origine carieuse sur des incisives primaires.

Méthodologie : Au total, 133 incisives de 50 enfants ont été réparties au hasard entre les 2 traitements – pulpotomie au SF (64) ou TC (69).

Résultats : Deux ans après le traitement, 77 incisives (41 pulpotomie au SF, 36 TC) ont fait l'objet d'un examen clinique et radiographique. Aucun signe clinique de morbidité n'a été observé sur 78 % des incisives traitées par pulpotomie au SF et 100 % des dents traitées par TC. Deux dentistes pédiatriques indépendants ont évalué les radiographies périapicales des incisives traitées, lesquelles ont été réparties entre 4 catégories selon l'issue du traitement : N – incisive traitée normale; H – changement radiographique non pathologique observé; P_O – changement pathologique ne nécessitant pas une extraction immédiate; P_X – changement pathologique nécessitant une extraction immédiate. Une analyse de survie a aussi été faite. Un taux modéré de concordance a été rapporté entre les évaluateurs, dans le cas des incisives classées dans la catégorie P_X (K = 0,54), et une fiabilité intra-évaluateur significative a été observée pour les incisives classées dans la catégorie P_X (K = 0,61). Enfin, aucune différence n'a été rapportée entre la proportion d'incisives classées dans la catégorie P_X au rappel après 2 ans, selon qu'elles ont été traitées par pulpotomie au SF ou TC ($\chi^2 = 0,6$). Cependant, les incisives traitées par TC ont affiché un taux de survie à 2 ans nettement supérieur à celui des dents traitées par pulpotomie au SF ($p = 0,04$).

Conclusions : Aucune différence importante n'a été observée entre l'issue du traitement après 2 ans, selon que les incisives ont été traitées par TC ou par pulpotomie au SF. Les incisives traitées par TC ont toutefois présenté un taux de survie à 2 ans statistiquement supérieur à celui des incisives traitées par pulpotomie au SF.

Mots clés MeSH : dental pulp exposure/therapy; pulpotomy/methods; root canal therapy

© J Can Dent Assoc 2004; 70(1):34-8
Cet article a été révisé par des pairs.

Formocresol (FC) pulpotomy and zinc-oxide eugenol (ZOE) root canal therapy (RCT) have both been advocated as techniques for managing inflamed vital pulp in primary incisors.^{1,2} Concerns about the safety of FC for vital pulp therapy have led to investigations of alternative techniques and materials.³ Ferric sulfate (FS) pulpotomy has resulted in outcomes comparable to those of FC pulpotomy in

primary molars.^{4,5} One study of RCT demonstrated favourable outcomes in vital primary incisors.¹ No prospective investigations have directly compared outcomes of RCT and FS treatments for vital pulp exposure in primary incisors. This investigation compared outcomes 2 years after FS pulpotomy or RCT with ZOE.

Methods

The subjects selected for this investigation were treated at The Hospital for Sick Children, Toronto, Ontario, between October 1998 and March 1999. Healthy children with 1 or more carious primary incisors, where removal of dental caries was likely to expose vital pulp, were invited to participate in the study. The procedures, possible discomforts or risks as well as possible benefits were explained fully to the subjects and their parents or guardians, and informed consent was obtained and recorded before their participation in this investigation. The Research Ethics Board at The Hospital for Sick Children approved this investigation.

A total of 133 primary incisors in 50 subjects (29 male, 21 female) were identified for this study. FS pulpotomy was carried out in 64 primary incisors in 24 subjects (13 male, 11 female). RCT was the treatment for 69 primary incisors in 26 subjects (16 male, 10 female). Of the enrolled participants, 64% returned for at least 1 evaluation. The final sample consisted of 77 incisors (41 FS, 36 RCT) in 23 subjects for whom clinical and radiographic data were available for analysis at the 2-year reassessment.

After induction of general anesthesia, periapical radiographs were acquired for each incisor tooth that was likely to have carious pulp exposure. Incisors included in the study exhibited no radiographic evidence of physiologic or pathologic root resorption, periapical radiolucencies or pulp stones. Incisors with an associated swelling or sinus tract were excluded.

Three pediatric dentists (DJK, DHJ, PLJ) completed all treatment over 22 weeks. All incisors were treated under rubber dam isolation. Children whose incisors met the inclusion criteria were randomly selected to receive FS pulpotomy or RCT. Treatment data were recorded daily on preprinted data collection sheets and entered into a database. Quality assurance checks were performed by 1 of the investigators (MAL), who did not provide treatment or review postoperative radiographs, to ensure that the investigators who provided treatment complied with the randomization protocol.

Primary Incisor Root Canal Therapy Procedure

The RCT technique used was described by Payne and others.¹ Access into the pulp chamber was achieved using a sterile #56 fissure bur in a high-speed handpiece, then refined with sterile round burs in a low-speed handpiece. The coronal pulp was amputated with a round bur. Radicular pulp tissue was removed by inserting two #15 or #20 Hedström files, one at a time, down opposite sides of the root canal to a point close to, but short of the apex. The files were then rotated 2 or 3 times to engage the pulp tissue and remove it. In most cases, the pulp tissue was removed *en bloc* on the first attempt. If the first attempt was unsuccessful, the procedure was repeated until all of the pulp tissue was removed.

The canal was then irrigated and gently air-dried using an air-water syringe. The canals were obturated using a viscous mixture of Sedanol (Dentsply DeTrey, Addlestone, UK), a fine-grained, non-reinforced ZOE preparation. The

paste was delivered to the root canal with a spiral paste filler (Lentulo, Dentsply DeTrey) inserted into the canal to a point just short of the apex. On completion of canal obturation, the incisor was immediately restored with an acid-etch resin restoration (Spectrum TPH, L.D. Caulk, York, Penn.).⁶

Ferric Sulfate Pulpotomy Procedure

The FS pulpotomy procedure was similar to the technique described by Coll and others.² Access to the pulp chamber was achieved using a sterile #56 fissure bur mounted in a high-speed handpiece, then refined with round burs in a low-speed handpiece. The coronal pulp was removed using a sterile low-speed round bur (#6 or #8). A 15.5% FS solution in an aqueous vehicle (Astringedent, Ultradent Products Inc., Salt Lake City, Utah) was gently applied to the radicular pulp for 15 seconds with the syringe applicator supplied by the manufacturer. The pulp chamber was flushed with water supplied by an air-water syringe. If the bleeding had not stopped after the initial application of FS, the incisor was eliminated from the study. If hemostasis was achieved, the pulp chamber was sealed with a fortified ZOE mixture supplied in premeasured capsules (L.D. Caulk, Milford, Del.). The incisor was then immediately restored with an acid-etch resin restoration (Spectrum TPH, L.D. Caulk).

Clinical and Radiographic Evaluation

All subjects were offered clinical and radiographic assessments 12 and 24 months after treatment. Subjects who returned for a follow-up examination were asked to report any history of pain related to the treated incisors. Each incisor was classified as present, exfoliated, lost to trauma or extracted. If the incisor was still present, the following observations were recorded: missing restoration, recurrent caries, mobility and percussion sensitivity. The surrounding gingiva and mucosa were also examined for any signs of erythema, swelling, parulis or the presence of a fistulous tract.

Periapical radiographs were taken of all treated incisors. The radiographs were taken on size 0 film using a Rinn holder (Dentsply Rinn, Elgin, Ill.) and bisecting angle technique. All radiographs taken during follow-up sessions were screened for their diagnostic quality before being included in the radiographic evaluation. Acceptable radiographs had nondistorted images of the treated incisors and the osseous structures immediately adjacent to the roots. Radiographs that did not meet these criteria were excluded.

Two independent pediatric dentists who were not otherwise involved in the investigation evaluated the radiographs. Before the review, the raters participated in a calibration exercise using sample radiographs of incisors that had received FS pulpotomies and RCT. The raters were encouraged to reach consensus on radiographic assessment. After the calibration exercise, the raters were separated and evaluated the radiographs alone under standardized viewing conditions. The raters' scores were subjected to inter-rater reliability testing. One reviewer reassessed a subset of the radiographs 2 weeks after the initial assessment so that intra-rater reliability could be calculated.

Table 1 Pathologic findings by radiographic assessment at 2-year follow-up examination of vital incisors treated by FS pulpotomy or RCT

Pathologic finding	FS pulpotomy (n = 12)		RCT (n = 11)	
	Number	%	Number	%
Pulp canal obliteration	3	25	n/a	n/a
Widened periodontal ligament space	8	67 ^a	2	18
Periapical radiolucency	7	58	3	27
Internal resorption	2	17	n/a	n/a
External resorption	4	33	3	27
Caries	4	33	4	36

FS = ferric sulfate; RCT = root canal therapy; n/a = not applicable

^a $\chi^2 = 5.4$; $p < 0.02$

Table 2 Classification by radiographic assessment of incisors treated by FS pulpotomy or RCT at 2-year follow-up examination

Category ^a	FS pulpotomy (n = 12)		RCT (n = 11)	
	Number	%	Number	%
N	2	17	8	73
H	3	25	0	0
P _O	2	17	1	9
P _X	5	42	2	18

FS = ferric sulfate; RCT = root canal therapy

^aN = normal incisor; H = changes associated with normal physiologic root resorption; P_O, pathologic change present, but not requiring immediate extraction; and P_X, pathologic change present and immediate extraction recommended.

All radiographs included in this investigation were subjected to identical evaluation criteria regardless of treatment. The raters were asked to determine the presence or absence of widened periodontal ligament space, furcation or periapical radiolucency, pulp canal obliteration and pathologic internal or external root resorption. The raters classified each incisor according to 1 of 4 outcomes: N, normal incisor without evidence of radiographic change; H, radiographic changes associated with normal physiologic root resorption; P_O, pathologic radiographic change present, but not requiring immediate extraction; and P_X, pathologic radiographic change present and immediate extraction recommended.⁷

Data Analysis

In subjects with more than 1 treated incisor, a single incisor was randomly selected for analysis to preserve the statistical independence of the observations. Discrete variables for radiographic findings and treatment outcomes were tested for statistical differences using the χ^2 test. Percentages were used to summarize categorical data. A Wilcoxon test was conducted to compare the survival of incisors treated by FS pulpotomy with those undergoing RCT. Graphical representations of survival were produced for both groups using the Kaplan-Meier method. Inter-rater and intra-rater agreement for dichotomous responses were measured using the Kappa statistic.

Results

Clinical and Radiographic Findings

Twelve subjects (41 incisors) in the FS-treated group returned for assessment when contacted 2 years after treatment; the

average recall interval was 25.8 ± 3.1 months. Their average age at time of treatment was $3.3 \text{ years} \pm 0.8$ years (standard deviation [SD]). Clinical examination revealed associated gingival swelling or parulis in 9 of the 41 FS-treated incisors (22%). No subjects reported pain from FS-treated incisors at the 2-year recall appointment.

Eleven subjects (36 incisors) in the RCT group attended a recall examination when contacted 2 years after initial treatment; the average recall interval was 26.8 ± 2.2 months. Their average age at time of treatment was 3.1 ± 0.7 years. There were no soft tissue swellings or fistulae or reports of pain associated with any of the 36 RCT-treated incisors. Radiographic findings for FS and RCT incisors are listed in Table 1.

At the 2-year assessment, FS-treated incisors had a significantly higher prevalence of widened periodontal ligament space ($\chi^2 = 5.4$; $p = 0.02$) than RCT-treated incisors. No statistically significant differences in external root resorption, periapical radiolucencies or coronal caries were detected.

Nonpathologic radiographic outcomes (categories N and H) were observed in only 42% of the incisors treated with FS and 73% of RCT incisors (Table 2). There were no significant differences between the 2 treatments in the number of incisors classified P_X at 2 years after treatment ($\chi^2 = 0.6$) (Table 2). FS-treated incisors had 59% acceptable outcomes on radiographic examination, which was not statistically different from the 82% acceptable outcomes for RCT incisors (χ^2 [Yates corrected] = 0.59; $p > 0.05$). A sample-size estimate predicted that 54 RCT and 17 FS incisors would be required to demonstrate a statistically significant difference in outcomes between the 2 groups at 2 years.

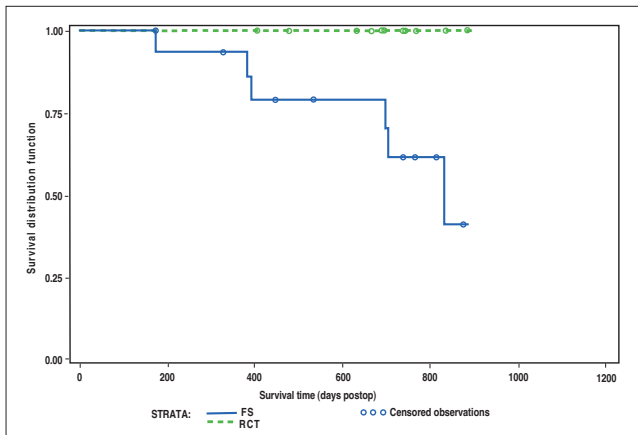


Figure 1: Kaplan-Meier survival curves for FS- and RCT-treated incisors

Measures of Reliability

The level of agreement between the raters was moderate in classifying incisors in the P_X category ($K = 0.54$ using Landis and Koch's⁸ interpretation of reliability). Raters agreed on combinations of radiographic features that indicated when extraction of an incisor was indicated. Intra-rater reliability was substantial for classifying an incisor as P_X ($K = 0.61$).

Survival Analysis

Any incisor rated P_X , exfoliated prematurely or extracted during the recall interval of the investigation was classified as not meeting the criteria for survival. Survival analysis was carried out for 16 subjects in the FS group and 13 subjects in the RCT group who had a follow-up visit at any point in the investigation. In 63% (10/16 observations) of FS-treated incisors and 85% (11/13 observations) of RCT-treated incisors, the tooth survived until the completion of the investigation. Kaplan-Meier survival curves for both groups are similar until about 7 months after treatment (Fig. 1). Beyond 7 months, the survival curve for the FS pulpotomy incisors diverges from the RCT curve and demonstrated an overall statistically lower survival (Wilcoxon, $p = 0.04$).

Discussion

This investigation provided an opportunity to replicate the work of Payne and others¹ for RCT using an identical prospective study design and evaluation method for outcome classification. Of the incisors treated by RCT, 82% had acceptable outcomes, comparable with the 90% reported by Payne and others.¹ However, this assessment is the only prospective clinical outcome study that compares FS pulpotomy with another non-aldehyde form of primary incisor pulp treatment.

Based on clinical examination alone, RCT produced very favourable outcomes. At the 2-year follow-up, no pathosis was detected in any of the RCT-treated incisors on clinical examination; 78% of FS-treated incisors had no pathosis on clinical examination at 2-year follow-up. However, radiographic examination showed favourable outcomes for 59% of the FS group and 82% of the RCT-treated incisors. This suggests that radiographic follow-up of primary incisor pulp therapy is

indicated, as the clinical appearance alone may not reveal the true status.

The most common pathologic finding for FS pulpotomy-treated incisors was widened periodontal ligament space (in 67% of FS-treated incisors but only 18% of RCT incisors).

Internal resorption was observed in 17% of FS-treated incisors, and was sufficiently severe in some incisors to be rated unacceptable. These incisors did not meet the criteria for survival on the basis of clinical examination.

Unlike FC, FS is not a tissue fixative. FS produces hemostasis at the amputated pulp stump by mechanically sealing cut blood vessels. This leaves vital pulp tissue in contact with ZOE. The irritating properties of eugenol have been shown to result in internal resorption when it is applied to the vital pulp of primary molars.^{9,10} Fixation of pulpal tissue by FC may prevent pulpal reaction to eugenol, thereby reducing the prevalence of internal resorption in FC pulpotomies. Future investigations of FS pulpotomy would benefit from the use of materials that do not stimulate internal resorption.

Nonpathologic radiographic outcomes (categories N and H) were observed in only 42% of the incisors treated with FS and 73% of RCT incisors. Teeth with radiographic evidence of pathosis were classified into P_O and P_X outcomes as clinicians do not regard all pathologic changes as an absolute indication for extraction of pulp-treated incisors. Pediatric dentists are likely to leave pulp-treated primary incisors that exhibit a limited degree of radiolucency or pathologic root resorption in the absence of clinical signs and symptoms in situ. Pathosis confined within the tooth, such as internal resorption or pulp canal obliteration, should not be considered harmful to the underlying permanent tooth and are acceptable outcomes following pulp therapy.^{4,5} Protocols that classify incisor outcomes as acceptable (normal or minor pathosis present) or unacceptable (major pathosis present) are more clinically relevant than protocols that classify outcomes as normal versus pathologic or successful versus unsuccessful as they more closely mimic clinical decision-making.¹

A limitation of this investigation is the sample size available for assessment of treatment outcomes at 2 years. Fifty-six of 133 incisors were lost to follow-up over the period of the investigation. To ensure independence of the observations for appropriate application of statistical analysis, each of 23 subjects (41 FS and 36 RCT incisors) contributed only a single incisor to the analysis of treatment outcomes. This effectively reduced the final sample size to 23 incisors (12 FS and 11 RCT). Sample wastage and the requirement for statistical independence of observations are important limitations to assessment of treatment outcomes. Survival analysis, as employed in this investigation, can use data more efficiently than traditional outcome analysis and is preferable for clinical trials of this type.

This investigation replicated the findings of 2 previous outcome studies of vital incisor RCT.^{1,7} Vital RCT and FS pulpotomy have the advantage of avoiding the use of aldehydes in children. However, the survival of RCT-treated

incisors is significantly greater than those treated by FS pulpotomy.

Conclusions

Treatment of exposed vital pulp by RCT with ZOE resulted in a significantly greater survival rate for primary incisors at 2 years after treatment than FS pulpotomy. Clinicians who wish to avoid the use of aldehydes should select RCT for restoring vital primary incisors with carious pulp exposures. ♦

Remerciements : Les chercheurs souhaitent remercier les Drs Edward Barrett et Randi Fratkin pour avoir effectué l'examen radiographique.



Le Dr Casas est dentiste pédiatrique, membre du personnel de l'Hôpital pour enfants, Toronto (Ontario), et professeur agrégé de médecine dentaire, Université de Toronto.



Le Dr Kenny est directeur des recherches dentaires et des études supérieures, Hôpital pour enfants, et professeur agrégé de médecine dentaire, Université de Toronto.



Le Dr Johnston est dentiste en chef, Hôpital pour enfants, et professeur agrégé de médecine dentaire, Université de Toronto.



Le Dr Judd est directeur de la Division de dentisterie pédiatrique, Hôpital pour enfants, et professeur agrégé de médecine dentaire, Université de Toronto.



Le Dr Layug était étudiant diplômé au Département de dentisterie pédiatrique, Faculté de médecine dentaire, Université de Toronto, lors de cette étude. Il est à présent chargé de clinique en dentisterie, Université de Toronto.

Écrire au : Dr Michael J. Casas, Hôpital pour enfants, S524-555, av. University, Toronto ON M5G 1X8. Courriel : mcasas@sympatico.ca.

Les auteurs n'ont aucun intérêt financier déclaré dans la ou les sociétés qui fabriquent les produits mentionnés dans cet article.

Références

1. Payne RG, Kenny DJ, Johnston DH, Judd PL. Two-year outcome study of zinc oxide-eugenol root canal treatment for vital primary teeth. *J Can Dent Assoc* 1993; 59(6):528-30, 533-6.
2. Coll JA, Josell S, Nassof S, Shelton P, Richards MA. An evaluation of pulpal therapy in primary incisors. *Pediatr Dent* 1988; 10(3):178-84.
3. Ranly DM, Garcia-Godoy F. Current and potential pulp therapies for primary and young permanent teeth. *J Dent* 2000; 28(3):153-61.
4. Casas MJ, Layug, MA, Kenny DJ, Johnston, DH, Judd, PL. Two-year outcomes of primary molar ferric sulfate pulpotomy and root canal therapy. *Pediatr Dent* 2003; 25(2):97-101.
5. Fuks AB, Holan G, Davis JM, Eidelman E. Ferric sulfate versus dilute formocresol in pulpotomized primary molars: long-term follow-up. *Pediatr Dent* 1997; 19(5):327-30.
6. Judd PL, Kenny DJ, Johnston DH, Yacobi R. Composite short-post technique for primary anterior teeth. *J Am Dent Assoc* 1990; 120(5):553-5.
7. Yacobi R, Kenny DJ, Judd PL, Johnston DH. Evolving primary pulp therapy techniques. *J Am Dent Assoc* 1991; 122(2):83-5.

8. Landis J, Koch G. The measurement of observer agreement for categorical data. *Biometrics* 1977; 33(1):159-74.
9. Berger JE. Pulp tissue reaction to formocresol and zinc oxide-eugenol. *ASDC J Dent Child* 1965; 32:13-28.
10. Hansen HP, Ravn JJ, Ulrich D. Vital pulpotomy in primary molars. A clinical and histologic investigation of the effect of zinc oxide-eugenol cement and Ledermix. *Scand J Dent Res* 1971; 79(1):13-25.